This is a digital copy of a book that was preserved for generations on library shelves before it was carefully scanned by Google as part of a project to make the world's books discoverable online.

It has survived long enough for the copyright to expire and the book to enter the public domain. A public domain book is one that was never subject to copyright or whose legal copyright term has expired. Whether a book is in the public domain may vary country to country. Public domain books are our gateways to the past, representing a wealth of history, culture and knowledge that's often difficult to discover.

Marks, notations and other marginalia present in the original volume will appear in this file - a reminder of this book's long journey from the publisher to a library and finally to you.

Usage guidelines

Google is proud to partner with libraries to digitize public domain materials and make them widely accessible. Public domain books belong to the public and we are merely their custodians. Nevertheless, this work is expensive, so in order to keep providing this resource, we have taken steps to prevent abuse by commercial parties, including placing technical restrictions on automated querying.

We also ask that you:

+ *Make non-commercial use of the files* We designed Google Book Search for use by individuals, and we request that you use these files for personal, non-commercial purposes.
+ *Refrain from automated querying* Do not send automated queries of any sort to Google's system: If you are conducting research on machine translation, optical character recognition or other areas where access to a large amount of text is helpful, please contact us. We encourage the use of public domain materials for these purposes and may be able to help.
+ *Maintain attribution* The Google "watermark" you see on each file is essential for informing people about this project and helping them find additional materials through Google Book Search. Please do not remove it.
+ *Keep it legal* Whatever your use, remember that you are responsible for ensuring that what you are doing is legal. Do not assume that just because we believe a book is in the public domain for users in the United States, that the work is also in the public domain for users in other countries. Whether a book is still in copyright varies from country to country, and we can't offer guidance on whether any specific use of any specific book is allowed. Please do not assume that a book's appearance in Google Book Search means it can be used in any manner anywhere in the world. Copyright infringement liability can be quite severe.

About Google Book Search

Google's mission is to organize the world's information and to make it universally accessible and useful. Google Book Search helps readers discover the world's books while helping authors and publishers reach new audiences. You can search through the full text of this book on the web at `http://books.google.com/`

No. .....

BOSTON
MEDICAL LIBRARY
ASSOCIATION,
19 BOYLSTON PLACE.

ANNUAL

OF THE

UNIVERSAL MEDICAL SCIENCES

A YEARLY REPORT OF THE PROGRESS OF THE GENERAL SANITARY SCIENCES THROUGHOUT THE WORLD.

EDITED BY

CHARLES E. SAJOUS, M.D.,

AND

SEVENTY ASSOCIATE EDITORS,

ASSISTED BY

OVER TWO HUNDRED CORRESPONDING EDITORS, COLLABORATORS, AND CORRESPONDENTS.

Illustrated with Chromo-Lithographs, Engravings and Maps.

VOLUME IV.

1895.

THE F. A. DAVIS COMPANY, PUBLISHERS,

PHILADELPHIA, NEW YORK, CHICAGO.

LONDON: F. J. REBMAN.

AUSTRALIAN AGENCY: MELBOURNE, VICTORIA.

BOSTON MEDICAL
AUG 28 1895
LIBRARY ASS'N.

COPYRIGHT, 1895,
BY
THE F. A. DAVIS COMPANY.

[Registered at Stationers' Hall, London, Eng.]

CATALOGUED
AUG 28 1895
E. H. B.

Philadelphia, Pa., U. S. A.
The Medical Bulletin Printing-House,
1916 Cherry Street.

TABLE OF CONTENTS OF VOLUME FOURTH.

DISEASES OF THE SKIN, ... Section A

BY ARTHUR VAN HARLINGEN, M.D.,
PHILADELPHIA,
Professor of Diseases of the Skin in the Philadelphia Polyclinic;
Dermatologist to the Howard Hospital.

OPHTHALMOLOGY, ... Section B

BY CHARLES A. OLIVER, A.M., M.D.,
PHILADELPHIA,
Attending Surgeon to Wills Eye Hospital; Ophthalmic Surgeon to
the Philadelphia Hospital, etc.;
ASSISTED BY
WM. CAMPBELL POSEY, A.B., M.D.,
PHILADELPHIA.
Assistant Surgeon to Wills Eye Hospital; Ophthalmic Surgeon to
the Howard Hospital.

OTOLOGY, ... Section C

BY CHARLES S. TURNBULL, A.M., M.D., PH.D.,
PHILADELPHIA,
Oculist and Aurist to the German Hospital,
AND
ARTHUR AMES BLISS, A.M., M.D.,
PHILADELPHIA,
Laryngologist to the German Hospital; Laryngologist and Aurist to the
Pennsylvania Institution for the Deaf and Dumb.

DISEASES OF THE NASAL AND ACCESSORY CAVITIES,
PHARYNX, LARYNX, TRACHEA, AND ŒSOPHAGUS, Section D

BY CHARLES E. SAJOUS, M.D.,
PARIS,
Formerly Physician-in-Charge of the Laryngological Department of the
Jefferson College Hospital, and Lecturer in the Jefferson Medical
College, Philadelphia, etc.

INTUBATION OF THE LARYNX, ... Section E

BY JOSEPH O'DWYER, M.D.,
NEW YORK,
Visiting Physician to the New York Foundling Hospital and St. Vin-
cent's Hospital; Consulting Physician to the Seton Hospital for
Consumptives.

DISEASES OF THE THYROID GLAND, ... Section F

BY J. PAYSON CLARK, M.D.,
BOSTON,
Physician for Diseases of the Throat in the Massachusetts General Hospital.

LEGAL MEDICINE AND TOXICOLOGY, ... Section G

BY FRANK WINTHROP DRAPER, A.M., M.D.,
BOSTON,
Professor of Legal Medicine in the Medical Department of Harvard University; Medico-Legal Pathologist to the Boston City Hospital.

MEDICAL DEMOGRAPHY, ... Section H

BY F. LEVISON, M.D.,
COPENHAGEN.

BACTERIOLOGY, ... Section I

BY HAROLD C. ERNST, A.M., M.D.,
BOSTON,
Assistant Professor of Bacteriology in Harvard University; Physician to the Out-Patient Department of the Massachusetts General Hospital.

VOLUME INDEX, ... Section J

REFERENCE LIST OF JOURNALS.

CONTENTS OF THE ENTIRE SERIES.

Volume I.

Diseases of the Lungs and Pleura. *Wilson and Eshner* . . . . . Section A
Diseases of the Heart and Blood-vessels. *Vickery* . . . . . Section B
Diseases of the Mouth, Stomach, Liver, and Pancreas. *Rubino* . . . . . Section C
Cholera; Diseases of the Intestines and Peritoneum. *Griffith and Hunt* . . Section D
Animal Parasites and their Effects. *Dolley* . . . . . Section E
Diseases of the Kidneys, Bladder, and Adrenals; Urinalysis. *Lannois* . Section F
Diabetes Mellitus. *Lépine* . . . . . Section G
Fevers. *Semeleder* . . . . . Section H
Diphtheria, Croup, Pertussis, and Parotitis. *J. Lewis Smith and Warner* . . Section I
Scarlet Fever, Measles, Varicella, and Rötheln. *Witherstine* . . . . . Section J
Rheumatism and Gout. *Davis* . . . . . Section K
Diseases of the Blood and Spleen. *Henry and Stengel* . . . . . Section L
Volume Index. *Devereux* . . . . . Section M

Reference List of Journals.

Volume II.

Diseases of the Brain. *Gray, Pritchard, and Shultz* . . . . . Section A
Diseases of the Spinal Cord. *Obersteiner* . . . . . Section B
Peripheral Nervous Diseases, Muscular Dystrophies, and General Neuroses. *Sollier* . . . . . Section C
Traumatic Neuroses. *Booth* . . . . . Section D
Mental Diseases. *Rohé* . . . . . Section E
Inebriety, Morphinism, and Kindred Disorders. *Norman Kerr* . . . . . Section F
Diseases of the Uterus, Tubes, Ovaries, and Pelvic Tissues. *Montgomery.* Section G
Diseases of the Vagina and External Genitals. *Baldy and Dorland* . . . Section H
Diseases of Pregnancy. *Lutaud* . . . . . Section I
Obstetrics and Puerperal Diseases. *Budin and Merle* . . . . . Section J
Diseases of the Newborn; Teratology. *Currier* . . . . . Section K
Dietetics of Infancy and Childhood; Infantile Disorders. *Edwards* . . Section L
Volume Index. *Devereux* . . . . . Section M

Reference List of Journals.

Volume III.

Surgery of the Brain, Spinal Cord, and Nerves. *Pilcher and Lloyd* . . . . Section A
Thoracic Surgery. *Gaston* . . . . . Section B
Surgery of the Abdomen. *Bull and Coley* . . . . . Section C
Diseases of the Rectum and Anus. *Kelsey* . . . . . Section D
Surgical Diseases of the Genito-Urinary Apparatus in the Male. *Keyes and Fuller* . . . . . Section E
Syphilis. *White and Furness* . . . . . Section F
Orthopædic Surgery. *Sayre* . . . . . Section G
Amputations, Resections, and Plastic Surgery; Diseases of Bones and Joints. *Conner and Freeman* . . . . . Section H
Fractures and Dislocations. *Stimson* . . . . . Section I
Diseases and Injuries of Arteries and Veins. *Fenger* . . . . . Section J
Oral Surgery. *Matas* . . . . . Section K
Tumors and Surgical Mycoses. *Laplace* . . . . . Section L
Surgical Diseases. *Tiffany and Warfield* . . . . . Section M
Surgical Dressings and Antiseptics. *Van Imschoot* . . . . . Section N
Anæsthetics. *Buxton* . . . . . Section O
Volume Index. *Devereux* . . . . . Section P

Reference List of Journals.

Volume IV.

Diseases of the Skin. *Van Harlingen* . . . . . Section A
Diseases of the Eye. *Oliver* . . . . . Section B
Diseases of the Ear. *Turnbull and Bliss* . . . . . Section C
Diseases of the Nasal and Accessory Cavities, Pharynx, Larynx, Trachea, and Œsophagus. *Sajous* . . . . . Section D
Intubation of the Larynx. *O'Dwyer* . . . . . Section E
Diseases of the Thyroid Gland. *Clark* . . . . . Section F
Legal Medicine and Toxicology. *Draper* . . . . . Section G
Medical Demography. *Levison* . . . . . Section H
Bacteriology. *Ernst* . . . . . Section I
Volume Index. *Devereux* . . . . . Section J

Reference List of Journals.

Volume V.

General Therapeutics and Pharmaceutical Chemistry. *Dujardin-Beaumetz and Dubief* . . . . . Section A
Experimental Therapeutics. *Hare and Cerna* . . . . . Section B
Electro-Therapeutics. *Rockwell* . . . . . Section C
Gynæcological Electro-Therapeutics. *Apostoli and Grand* . . . . . Section D
Hydrotherapy, Climatology, and Balneology. *Baruch and Daniels* . . . . Section E
Hygiene and Epidemiology. *Wyman and Banks* . . . . . Section F
Anatomy. *Testut and Vialleton* . . . . . Section G
Normal Histology and Microscopical Technology. *Sajous* . . . . . Section H
Physiology. *Howell and Dreyer* . . . . . Section I
General Index. *Kyle and Devereux* . . . . . Section J

Reference List of Journals.

BOSTON MEDICAL
AUG 28 1895
LIBRARY ASS'N.

DISEASES OF THE SKIN.

By ARTHUR VAN HARLINGEN, M.D.,
PHILADELPHIA.

Acne.—Crocker, [1077 Feb. 21, '94] in a clinical lecture on "Acne Vulgaris, Acne Rosacea, and Acne Varioliformis," speaks of the variety of the latter affection. It attacks the border of the scalp, going a little way back into the scalp itself. The other forms of acne do not go into the scalp; so that a scar having acneiform eruption affecting the forehead and temples and going back into the hair is pretty sure to be acne varioliformis [carefully excluding similar syphilitic eruptions.—A. V. H.]. The disease, if of long standing, may spread to the face, and even to the body and limbs, but very rarely. In acne vulgaris Crocker begins with the following mixture, especially if the tongue is much coated and show prominent papillæ: ℞ Sodii bicarb., 10 grains (0.65 gramme); ext. cascara sagradæ liq., 10 to 20 minims (0.65 to 1.3 grammes); tinct. nucis vomicæ, 7 to 10 minims (0.45 to 0.65 gramme); aq. menth. pip., ad 1 fluidounce (31 cubic centimetres). M. After this has been taken for a week or ten days, if there is any indication for iron, a pill of reduced iron of two or three grains (0.13 or 0.2 gramme) may be given after dinner or oftener.

Fordyce [61 Oct. 7, '93] calls attention to the case described by Bronson and himself in 1891, under the title of *acne pilaris* (acne varioliformis), and which was at that time shown to originate in or about the coil glands. This case should be included under the title "hydradenitis." Fordyce has since examined papules and pustules from two typical cases of true acne varioliformis, and has traced the origin of the disease to an inflammation about the middle and upper portions of the hair-follicles and their sebaceous glands, while the coil glands are not implicated. Numerous staphylococci were found at so early a stage of the disease as to induce Fordyce to believe that the affection is an inflammation of the pilosebaceous system, of microbic origin, leading to the

destruction of these organs. He considers Bazin's designation, "acne pilaris," to be correct. In the discussion following, Crocker, of London, called attention to the little horny pig, which appears at the orifice of the follicle, and which, he thinks, acts as an irritative. He finds tincture of iron and iodide of potassium useful, with antiseptics and, particularly, mercurial ointments locally.

W. Dubreuilh [25 Aug., '94; 697 Apr., '96] has obtained specimens of lesions corresponding clinically to the various forms described by previous authors, and has been able to demonstrate the identity of the diseases described under the names of *acné pilaire* (Bazin, 1860); *acne frontalis seu varioliformis* (Hebra); *lupoid, or atrophic, acne* (D. Bulkley); *acne necrotica* (Boeck). They differ only in the extent and depth of the lesions. In its ordinary form the primary lesions consist of papules of the size of a lentil or a little larger. They appear to be of this volume from the first, and do not subsequently increase in size. They are moderately raised, of bright-rose color, and firm to the touch, with margins a little diffuse. The summit of the papules is generally pierced by a hair. After a few days, or even hours, the apex presents a circular, yellowish, waxy-looking spot, which consists of a soft, adherent crust still covered with epidermis. When completely developed the papule is of a red color, measures five to six millimetres in diameter, and its summit is occupied by a crust two to four millimetres wide, circular, yellow or brownish in color, adherent, slightly depressed below the surrounding parts, and traversed at its centre by a hair or by several hairs with one central. The crust is soft and greasy to touch, like wax; on removing it there is left a punched-out cavity with oozing base or containing a trace of thick pus. Sometimes violet hæmorrhagic points are observed in the crusts (Boeck). At the end of one to three weeks the crust becomes drier and harder, more depressed, and less firmly adherent. The papule itself becomes brown or violet in color and less prominent, till finally the infiltration disappears, leaving simply a brown or violaceous areola round the crust. The crust at last falls, leaving a cicatrix below, which corresponds with it in form and size, is fine and supple, and depressed like the scar of variola. At first pigmented, it becomes white in course of time. An important characteristic is that it is not bald, but remains always pierced by one or more hairs. The cicatrices may be extremely numerous; so

that not a cubic centimetre of healthy skin may remain on the face. The disease is less rare than generally supposed (24 cases out of a total of 4500). The proportion of male to female patients is 10 to 14; the age, 24 years to 72 years. It is equally common in rich and poor. In nearly all cases there are digestive troubles. Sometimes the eruption appears at the menopause. Dubreuilh does not agree with Besnier that it bears any relation to arthritism. The earliest morbid phenomenon consists in the formation of a dermo-epidermal eschar. In the youngest lesions excised there is already a line of demarkation more or less pronounced. The papular formation is probably only a secondary reactional inflammation. It seems to be not of vascular origin, for the necrosis does not follow a vascular congestion, and there are no thrombi outside the eschar. It is certainly not of nervous origin. The necrosis, from the first in the form of a plaque around a follicular orifice, suggests that it may be microbic, perhaps aided by auto-intoxication from digestive disturbance. Diagnosis has chiefly to be made from divers syphilides. The disease must also be distinguished from disseminated suppurative hydro-adenitis.

Treatment is generally easy in respect to the existing lesions, but it is difficult to prevent the successive outbreaks. An ointment of sulphur (about 1 drachm to 1 ounce—4 grammes to 31 grammes) produced a cure of existing lesions frequently in a few days, or at least a week or so, and the author has found no need for more heroic treatment. In many cases where the disease has been considered syphilitic iodide of potassium internally has been said to give excellent results, but it does not prevent further outbreaks, and a larger dose is required with each fresh crop. Dubreuilh believes, however, that he has been able to control to some extent the appearance of fresh lesions by the administration of ichthyol in doses of 0.30 to 0.50 gramme (4½ to 7¾ grains) per diem, or, where ichthyol is badly supported, naphthol in 0.10-gramme (1¾ grains) doses after each meal.

M. Kaposi $\frac{45}{B.26,H.1}$; $\frac{697}{Aug.,'94}$ gives the characteristics of an aberrant form, termed by him *acne urticata*. It occurs on the face, chiefly on the forehead, nose, cheeks, and chin; afterward, on the hands and extensor aspects of the upper and lower extremities. Its duration is a matter of years, and relapses are frequent. It is accompanied by burning, itching, and even pain. The eruption

consists of wheals varying from a bean to a sixpence in size; they are often scabbed owing to scratching. The wheals subside in the course of two to four days; the scratched superjacent skin may become the seat of pustules; and at the end of a fortnight the site of the eruption is marked by pigmentation and streaky scars. Kaposi has only seen a few cases,—one dysmenorrhœic female, and two dyspeptic males had the eruption for more than fifteen years. Owing to its chronicity and the severity of the subjective phenomena it frequently affects the general health, causing sleeplessness, and greatly depresses the patients, who despair of cure.

Stephen Mackenzie [697 Oct.,'94] discussed, at the meeting of the British Medical Association, the question whether any constitutional condition favors the local peculiarity of the skin in the causation of acne. Anæmia, dyspepsia, constipation, amenorrhœa, and dysmenorrhœa were alleged to aid in the production of acne, it being asserted by many that acne could not be cured without attention to these derangements.

He stated that they were all exceedingly common functional derangements or disorders occurring simultaneously with acne, but no more a cause of it than of psoriasis or scabies. Reverting to the local causes, he pointed out that acne occurred in parts where the sebaceous glands were large and numerous and associated with relatively imperfectly developed hairs; that it did not occur on the scalp or on the parts of the face where the hairs grew strong, but was found on parts where the transition took place from thick strong hairs to lanugo hairs. A great physiological excitation of the pilosebaceous glands took place at puberty, and in the heightened activity alterations from health occurred, the ducts became blocked, inflammation followed, and, if pus-cocci were present, pustulation occurred. The treatment resolved itself into (1) preventive treatment; (2) the treatment of the established disease. In the prevention of acne in those predisposed to the disease three things were to be done: 1. To remove superfluous sebum and epithelial accumulations in the ducts of the glands. 2. To stimulate the sebaceous glands into healthy activity. 3. To keep the skin aseptic, so as to prevent the pus-cocci from gaining admission to the follicles. The soaps with an alkaline basis were the most efficient, as they were the most powerful. The most useful soaps were the sulphur, camphor-sulphur, sulphur-camphor Peruvian

balsam, and creolin cake soaps; whilst, of the powdered soaps, the alkaline, brimstone, and creolin, and the neutral salicylic acid-sulphur, and salicylic acid-resorcin-sulphur soaps were the best.

When the disease is developed all comedones should be repressed, all pustules opened. Stimulating soaps or applications should then be used,—ointments by night and lotions in the daytime. Sulphur was the most important constituent of both. When there was much inflammation around the acne lesions soothing treatment was necessary, while zinc and belladonna locally applied were sometimes of much service. When the more active lesions were remedied the preventive treatment came into play, and it must be impressed on the patients that, unless they were willing to take the trouble to carry it out in a thorough and continuous manner, they could not expect to be free from acne. In the discussion following the reading of the paper, P. Abraham spoke in strong terms of Walter Smith's excellent method of applying pure carbolic acid to each pustule. The results were most satisfactory, and very bad cases were soon cured if the applications were carefully made.

Malcolm Morris also considered it a local disease whose anatomical element was the sebaceous gland, the physiological element being the oversecretion of fat, while probably there was a third bacteriological element. Radcliffe Crocker could not consent to abandon internal treatment entirely, and still believed that attention to the condition of the alimentary canal and other disorders, as well as well-directed local treatment, was a quicker and more efficient method than local treatment only. All soaps, efficiently applied, were useful, and he was a strong advocate for thorough disinfection of the pustules after being opened. Unna had found resorcin-sublimate paste of great value. Leslie Roberts agreed with Mackenzie. At bottom, acne was an epithelial secretion of fat beyond what could be consumed by the integument. In consequence of this a deposit of unused fat collected in the ducts of the gland. The deposit, or comedo, became the seat of microbes and microbic change. During the last two years Unna had demonstrated a bacillus which he claimed to be the "acne bacillus," but, in Leslie Roberts's opinion, there was not a sufficient basis of fact for this belief. Frank Payne said that acne, in its origin in the form of comedones, was a developmental affection

residing not in sebaceous glands alone, but in rudimentary hairs, such as occurred on the face, the shoulders, chest, and other parts. These imperfect hair-follicles produced numerous abortive hair-shafts, and their glands, being also imperfect, produced imperfect sebum, which was too thick to be diffused along the hairs, but clogged up the follicles. Hence this condition could not be removed by constitutional treatment, though its morbid products might be removed and its consequences. The second factor in ordinary acne was inflammation, which was produced by micro-organisms entering the morbid follicles. Hence the local treatment, so ably described by Mackenzie, was the right one. Henry Waldo observed that the injurious effect of diet could often be controverted by a proper amount of exercise. Stopford Taylor had found the linimentum saponis superior to medicated soaps because it could have almost any drugs incorporated with it and could be used pure or diluted. Nothing, in his experience, removed the seborrhœa sooner. For destroying the pus-organisms in acne, as in other diseases, he found the ammoniated mercury ointment—5 grains or 10 grains to 1 ounce (0.32 or 0.65 gramme to 30 grammes)—of great value. Face wounds healed so quickly that it was better to break up the acne nodule than to puncture it with a needle. Constipation, in his opinion, was the most important factor, and that nerve-influence considerably affected acne was witnessed during menstruation and dyspepsia.

Dyer $_{\text{June,'94}}^{12}$ believes that an artificial type of acne may be seen on the chest, abdomen, and back, the cheeks, forehead, and chin being affected in those who are taking iodide, while the chin is covered when the cause is either menstrual or intestinal. That associated with rosacea begins around the nose. In the cachectic type or in those who are hard students or of a nervous temperament, it is more frequently witnessed on the forehead. Those who present lesions upon the entire face are generally found to suffer from habitual constipation. The treatment should be based upon these facts.

Philippson $_{\text{July,'94}}^{28}$ says that the causation of acne is still so uncertain that the treatment must be symptomatic. He opens the pustules and presses out the contents, then cuts through the induration and lays over this a 50-per-cent. salicylic plaster, using compresses of lead-water and acetic acid to soften the skin, cause

the pustules to disappear, and relieve the irritation. For the milder forms he recommends soap, salicylic acid, naphthol, resorcin, and sulphur. J. F. Payne [697 May,'94] has used the current from a dry Leclanché battery to remove indurated lesions left in the cheeks after thirteen years of the disease. The strength of the current did not exceed 3 milliampères, but the treatment was repeated in cases of large nodules. The needle connected with the negative pole was inserted deep into the centre of the induration. There was no return in the points treated and no resultant scarring.

Purdon, of Belfast, [16 May,'94] advocates the following plan of treatment in acne rosaceæ, the dietary and any gastric derangement having been attended to: Bathe affected parts with spirits of horse-radish, say, in the morning; and at bed-time rub in pretty firmly a pomade of sulphur with a small quantity of carbolic acid. In place of the latter, good results are sometimes obtained by substituting 10 grains (0.65 gramme) of the green iodide of mercury to the ounce (30 grammes). All comedones should be squeezed out with an "extractor." As a "reducing" agent ichthyol is often better than sulphur.

Adenoma Sebaceum.—Pollitzer [242 Dec.,'93] describes the first case of this disease reported from America, occurring in a robust man aged 25 years. The affection had been noticed for six or seven years. The patch, which was about one and one-half inches long and one-fourth of an inch wide, extended from just above the left frontal eminence downward and inward to a point about three-fourths of an inch above the eyebrow. It was made up of about thirty discrete papules, most of them as large as a medium-sized barley-corn; at the summit of each was a dilated sebaceous follicle. There were two small cysts in the patch. It presented a diffused bright-red appearance, but no telangiectatic vessels were to be seen. The diagnosis of adenoma of the sebaceous glands was verified by microscopical examination. The sections proved to be almost entirely made up of sebaceous gland-tissue, resembling, both in the appearance of the cells and in their arrangement, the normal gland. The cysts were found to be true sebaceous cysts. There were no signs of dilated blood-vessels. Two club-shaped processes of epithelium were seen, shooting out from the side of the root-sheath of a hair; near the end of one of them a small island of epithelial cells appeared, as if cut off from the growing

shoot. These, Pollitzer considers, would, as they underwent their physiological fatty degeneration, necessarily give rise to a sebaceous cyst. In some of the sections peculiar epithelial structures, suggesting the condition described by Török as syringo-cyst adenoma, were seen. Pollitzer is of the opinion that these structures represented groups of embryonically misplaced epithelial cells, which had proliferated and undergone colloidal degeneration in the middle of each group. The treatment consisted in oblique-crossed scarification, repeated three or four times, at intervals of about a fortnight, which resulted in the production of a smooth, scarcely perceptible scar.

Alopecia.—Jackson [814 Nov.,'98] reports 100 cases of loss of hair, of which 65 were men and 35 women. The ages at the beginning varied from 10 to 20 years in 7 men and 7 women; from 20 to 30 years in 44 men and 11 women; from 30 to 40 years in 12 men and 11 women; from 40 to 50 years in 1 man and 3 women; it was over 50 years in 2 women. The greatest number of cases began in the 25th and 26th year, viz., 9 in each year; the next most frequent age was 22 years (8 cases). The baldness or loss of hair took the form of a general thinning in 6 men and 19 women. It affected the crown and temples in 13 men; the crown alone in 32 men and 10 women; the temples in 4 men and 2 women; the temples and tonsure in 5 men; the tonsure in 4 men and 2 women; the occiput in 1 woman; the parietal region in 1 man and 1 woman.

The defluvium capillerium following fevers, etc., came on in one to five months after convalescence. The scalp and hair were found to be diseased in 88 per cent. of the cases, as follows: Atrophied and bound down, 2 cases; cavities, 4 cases; eczema capitis eight years before fall of hair, 1 case; seborrhœa congestiva, 2 cases; sweating of head, 5 cases; heat of head, 4 cases; pityriasis, 10 cases; seborrhœa oleosa, 3 cases; seborrhœa secca, 55 cases; fragilitas ossium, 2 cases.

In 46 per cent. of the cases there was a history of baldness in the family; but, as Jackson included collateral and ancestral relatives, this figure has not much significance. A number of other tables are given and conclusions drawn which I am inclined to think too hastily deduced from such a comparatively small number of cases.

Rogers [2 Apr.28,'94] reports an unusual case of alopecia which began

as a patch the size of a penny on the right parietal region. Under treatment a new growth of hair soon occurred. A thinning of the hair around the new hair then commenced and has extended till now the patient presents the unusual appearance of a tuft of natural hair where the alopecia originally was, connected with a band of natural hair running from ear to ear, while all the rest of the hair is thinned.

Alopecia Areata.—Bissett [284 Feb., '94] mentions a case of alopecia areata in a boy of 15 years, which was preceded by sharp pains over the whole scalp, which became entirely bald; loss of eyebrows and eyelashes followed, and within six months complete generalized alopecia supervened, which, with several abortive attempts at partial restoration, continued until the patient came under observation, five years later. At this time a certain degree of anæsthesia and analgesia was observed, but no further description of the patient's condition is noted. Phineas Abraham [22 Nov. 22, '98] is inclined to believe that ringworm and alopecia areata are, in many cases, connected. In 137 cases coming under his notice, 32 per cent. gave a history of ringworm, either personal or occurring in some member of the household. Seborrhœa of a severe type had preceded the alopecia in a number of cases. Only 13 of 137 cases gave a history of neuralgia or previous neuroses, and in those who complained of severe headaches he found the short club-shaped hairs just as frequently as in the others. Abraham impregnated an area of the scalp with a germicide by using atmospheric pressure, the spots implicated showing increased hyperæmia.

Whitehouse [245 Oct., '98] reports the case of a boy, aged 7 years, who presented a perfectly-bald spot on the top of the head about two inches in diameter, with the typical features of alopecia areata, including the characteristic fringe of "exclamation point" stubbed hairs from one-thirty-second to one-sixteenth inch in length. The history of the case, however, was not that of alopecia areata. The disease had begun six months previously as a small scaly papule, which gradually enlarged to the size of a little-finger nail before the hair fell out. The area was, at that time, red and scaly, but, as it became larger, the patch became smooth and shiny. There was a distinct history of contagion, several children in the house and a domestic cat having ringworm. Microscopical examination

and cultivation in glycerin showed numerous spores in some of the root-sheaths, but no mycelium and no involvement of the hair-shaft. Bulkly pronounced the fungus tricophyton.

Leistikow $^{116}_{\text{Jan.,'94}}$; $^{2}_{\text{Mar.3}}$ for the last four years has used chrysarobin almost exclusively in alopecia areata. The results in total alopecia have been satisfactory, though not reliable; in the partial affection the cures were 58 per cent., but among these relapses occurred in 30 per cent.; of these patients two-thirds were lost sight of, but the remainder were again cured and remained free. Formerly he only used the chrysarobin as a 5- to 10-per-cent. ointment, applied once or twice daily, but now he prepares a stick composed of chrysarobin, 30; colophonium, 5; cera flava, 35; olive-oil, 30 parts; the application thus being more simple. Every evening the stick is rubbed over the affected part, which is washed clean with olive-oil in the morning. In some days the skin often becomes irritable and red, when zinc ointment is substituted for a time. The author considers chrysarobin the best remedy in this affection.

Ferras $^{287}_{\text{V.4,No.10}}$ holds that alopecia should be treated not only by local applications, but by remedies which influence the entire system. He commends baths, thirty to forty minutes' duration, of strong sulphur-water. These are followed by massage for ten or twenty minutes and hot spray lasting for from three to five minutes. A half-pint ($\frac{1}{4}$ litre) of sulphur-water is taken morning and evening. Locally, he commends the use of tincture of iodine and hot sulphur-water sprays.

Angiokeratoma.—Zeisler $^{61}_{\text{Oct.7,'98}}$ reports a case of this affection which displayed itself in the gradual appearance of numerous small nævi [telangiectases?—A. V. H.] and pedunculated tumors of nævoid aspect varying from pea to hazel-nut size, with occasional nævoid patches from one-sixth to an inch or more in diameter, slightly raised above the surface. The patches and tumors were scattered over the limbs, with one or two in the ears. There were numerous nævoid warts on the palmar surface of the fingers and springing from beneath the nails. The abdomen, thorax, and upper arms were free. Patches of vitiligo were also observed on the thorax and other parts which were free from the angiokeratomata. Microscopical examination showed the warts to consist of an outward layer of thickened epidermis surrounding a very vascular centre. In the discussion upon Zeisler's paper

Crocker, of London, said that Cottle[412/77] had first described the affection, giving a colored plate in illustration.

Angioma Serpiginosum.—White[245/Nov.,Dec.,'94] records an interesting and instructive case of angioma serpiginosum occurring in a boy of 12 years. At birth a purplish-red mark was seen below the right shoulder-blade, semilunar in shape, which slowly increased in an upward direction until the boy was 4 years of age, when it was noticed that another lesion was appearing near the site of the original one, others following until they increased to twenty-four in number. Beginning in the form of small elevated points, of a bright-red color, they increased in size to one-eighth of an inch in diameter. At this stage they were elevated from one-eighth to one-twelfth of an inch above the general surface. Upon reaching this size they underwent involution and slowly sank down as the lesion spread peripherally, forming rings and spreading as an annular elevated margin, until, by confluence with other lesions, the circular shape was lost. The microscopical appearance of this condition revealed it to be one of a possible angiosarcoma.

Atheroma.—Zmigrodski, of St. Petersburg,[2156/p.106; 697/Mar.,'94] details an extremely rare instance of atheroma developing in a situation normally devoid of any hair-growth on sebaceous glands. A crown official, aged 58 years, consulted the author on account of a painful inflammation of his left forefinger, caused by an accidental prick a fortnight previously, the needle injuring an area in which an indolent tumor had been present for about the two last years. The examination revealed an elastic, somewhat fluctuating swelling of the size of a small nut, situated on the palmar surface of the terminal phalanx of the digit, near its radial edge. An incision proved that the tumor was a thick-walled cyst with fluid atheromatoid contents and pus. The cyst was easily extirpated, the wound rapidly healing. On microscopical examination, the tumor was found to be actually nothing else than a most typical atheroma, its wall (one-half millimetre thick) consisting of several strata of fibrous connective tissue with an enormous number of elastic fibres. The inner layers were vascular and infiltrated with granulation elements, the internal surface of the sac being lined with flat epithelial cells, arranged in numerous layers and undergoing fatty degeneration. There was further detected a solitary bundle of non-striated muscle-fibres, traversing the

external surface of the cyst. The author believes that the "retention cyst" had formed either from an isolated eratic sebaceous gland or from a sudoriparous one. The presence of the muscle-bundle seems to speak in favor of the former proposition. Two similar cases have been reported by Küster and Hahn.

Montgomery [9 Feb.17,'94] believes atheroma to be a better name than sebaceous cyst on account of the latter name implying that all such tumors are retention cysts of sebaceous glands, and this he states is not so. The wen, or atheroma, is a globular cavity of connective tissue, lined with flat, stratified epithelium which has collected in this cavity, because after being formed it is not thrown off as is the manner in the outer layers of the skin.

Atrophy of Skin.—Robinson [6 Sept.1,'94] describes several cases of an affection of the scalp which he has seen in which one or more atrophic spots occurred upon the head. These areas, containing no hair whatever, resembled the scars left by lupus erythematosus. The patients were all women. The author is inclined to ascribe as an etiological factor in this malady the method of dressing the hair, and that an inflammation, which results in the atrophy, is caused by the manner in which they put the hair up tightly on pins. Millard [287 p.1332,'93] reports the case of a boy of 17 years, who displayed transverse atrophic striæ symmetrically dispersed on the anterior and external aspect of the thighs a little below the trochanters, following an attack of typhoid fever. The patient had grown six centimetres in height in eleven months, while the average normal growth at his age is only about six millimetres.

Burns.—Nagotte [336 No.7,'94] shows that the most rapid healing and the least deforming scar after a severe burn is to be obtained by surgical antisepsis. To secure this it is necessary in cases of extensive burns to administer an anæsthetic and to subject the wound to thorough, even rough, applications of the methods and solutions ordinarily employed in cleansing infected wounds. Once thoroughly disinfected, an effort should be made to procure healing under dry dressing. As remedies for maintaining disinfection, iodoform, thyol, ichthyol, and especially subnitrate of bismuth are commended. Wilbouchewitch [2031 '93] states that fresh, superficial burns, as well as deep ones, can heal under antiseptic treatment without the production of pus. If pus is produced and the wound is disinfected, the course remains the same as if non-

infected; but if the pus is of long standing and the wound begins to granulate, disinfection is not possible. To disinfect wide-spread burns an anæsthetic is often necessary, chloroform being most suitable. If the wound is non-purulent the unnecessary use of an antiseptic hinders the healing process. Burns heal rapidly under antiseptic treatment. Burns of the second degree require eight days; of the third degree, from two to three weeks. Burns of the second and third degree heal without trace remaining; of the fourth degree, cause a scar, which does not retract, while this will be smoother the less the amount of pus. Wertheimer[45 B.29,H.3] treats burns in children by first thoroughly washing the injured part with lukewarm boric-acid solution and applying broad strips of absorbent gauze soaked in lime-water and linseed-oil, each 50 parts; thymol, 0.05 to 0.10 part, covered with absorbent cotton and held in place by a moderately-firm gauze bandage. The dressing should be renewed every day. By the end of the second week the following ointment is employed: ℞ Bismuth subnitrate, 9 parts; boric acid, 4.5 parts; lanolin, 70 parts; olive-oil, 20 parts.

Cancer.—In the discussion over Lassar's contribution upon cancer of the skin, read before the Berlin Medical Society,[28 B.17,No.10; 80 Jan.15,'94] Köbner held that the cases presented by Lassar were not conclusive, since Langenbeck had presented a similar favorable result from arsenic treatment, the patient, however, dying a year later from recurrence. In Lassar's second case the diagnosis is not assured; in the third case the patient is not fully healed. Köbner holds that arsenic and all other remedies administered by the mouth are utterly without power, and that cure is never accomplished excepting when the ulcer is completely removed by means of a knife in the early part of its course. Only when patients present themselves too late for operation should resort be had to medical treatment.

Bergmann gave the history of three cases in which ten, seven, and five years respectively had passed without recurrence. In considering the radical cure of skin cancer it must be remembered that cicatrization is followed by destruction of cancer-cells. Such cicatrization may take place quite independently of any therapeutic treatment. Under some circumstances carcinoma will last twenty years and then undergo cicatrization. Small clusters of cells may remain latent for years. Following seborrhœa, ulcers develop

which closely resemble carcinoma. Before a physician recommends internal treatment he should remember that these skin cancers frequently do not recur when thoroughly removed by the knife. Lassar, in answer to these criticisms, stated that he exhibited his patients simply to show that by arsenic treatment carcinomatous nodules in the face were prevented from running their customary course.

Gavino [673 May,'94] has obtained a cure in cases of epithelial cancer of the skin by the following mixture: Fuming nitric acid, 10 grammes (2½ drachms); bichloride of mercury, 4 grammes (1 drachm); Berzelius paper, q. s. ad consist. syrup. The remedy is applied with a cotton-forceps, repeating the cauterization in ten or twelve days. This will be sufficient to cause the largest tumor to fall off, when cicatrization soon takes place. Until the present time, the speaker had had 100 per cent. of cures. A patient of Péan's having a tumor seventeen centimetres in diameter, upon which the surgeon did not wish to operate, was cured in about eighteen days by this means, the tumor dropping off entire, nothing remaining but the cicatrizing wound.

Chilblains.—Pilatte [3 Dec.20,'93; 2 Feb.24,'94] states that in those subject to chilblains there is always arterial hypotension with peripheral vasodilatation. The chief indication, therefore, is to improve the circulation. For this purpose he gives digitalis internally, from 0.50 to 1.50 grammes (7¾ to 23¼ grains) of a maceration of the leaves being administered on two days of a week. Caffeine and kola are sometimes substituted for the digitalis. He also uses digitalis as a local application as follows: ℞ Tincture of digitalis, 6 grammes (1½ fluidrachms); crystallized thymol, 3 grammes (46 grains); alcohol at 70°, glycerin, each 150 grammes (4¾ fluidounces). Careful drying of the hands and feet, followed by friction with eau-de-cologne or camphorated alcohol, is enjoined. For the relief of the itching, tincture of iodine lightly painted on every three or four days is particularly useful. Fatty substances, including vaselin, should never be applied. Hebbing, of Nuremburg, [697 July,'94] claims a success for the treatment of chilblains of the nose by applications of a continuous current of feeble intensity, the *séances* lasting ten minutes each.

Dermatitis Herpetiformis.—Winfield [245 Nov.,'93] reports four cases of Duhring's disease in which glycosuria was a symptom. He con-

cludes that the cutaneous manifestations of dermatitis herpetiformis are of nervous origin,—an opinion which has already, I believe, been expressed by Duhring and other American observers, and one in which I myself am strongly inclined to coincide. C. Boeck records [369 No. 6, 98] two cases of dermatitis herpetiformis circumscripta seu circinata of a type as yet unmentioned. In the first case, a woman of 30 years, on the dorsal surface of each hand there was a circular plaque of the size of a child's hand, with the central portion infiltrated and hyperæmic, and this surrounded by a peripheral portion of small translucent vesicles. Similar patches the size of a hazel-nut were on the first phalanges of the fingers, and were also surrounded by small vesicles. There was intense itching. The disease first appeared six years before and had reappeared each winter. In the second case, a man of 23 years, the affection was less characteristic; the plaques were very similar and had developed each winter for two years, especially on the right hand.

Dermatitis of Surgeons.—Under the title "Eczema of the Surgeon" Lassar [336 July 28, '94] calls attention to the fact that perfectly healthy young men who have never shown any signs of an unusually irritable skin exhibit, after the use of certain antiseptic remedies in the practice of their profession, a sudden outbreak of inflammation of the skin of the hands. The explanation of this is simple. Every human tissue has its bounds and limits of resistance. To cleanse the hands and finger-nails with hot water, soap, and cologne or lemon-juice is well enough; but to scrub with soft soap for hours, to dip the hands repeatedly in hot solutions of soda, creolin, or acetate of aluminium, is a proceeding which no surgeon's hands can stand. The softer the hands, the more elastic and manageable, and those surgeons will have the softest hands who use a good toilet soap and who, before drying them, rub in some unctuous substance.

Lassar thinks the following formula a good one: ℞ Olei olivæ, glycerinæ, lanolin., vaselin., each 2 drachms (8 grammes); resorcin., 10 grains (0.65 gramme). M. This soft ointment, which may be put in a lead tube and kept in the pocket (as Esmarch employs it), not only prevents the irritation of the skin, but also serves as a protection against infectious substances. When, however, dermatitis has once attacked the surgeon's hands, the main

object must be to restore the integument to its original condition. Unfortunately vexatious relapses occur. The lymphatics must be freed from their congested and, perhaps, infected condition, and the epidermis allowed to recover its normal character. Antibacterial treatment, followed by siccative applications, are the best. Lassar suggests that the hands should be well rubbed with tar and placed in a warm-water hand-bath for half an hour (preferably every evening). Then the tar should be washed off and the following paste applied over night: ℞ Pastæ acid. salicyl., 2 per cent. Or, the following: ℞ Pulv. zinc. oxid., 6 drachms (23 grammes); olei olivæ, 4 fluidrachms (16 grammes). M. These applications should be covered with a layer of cotton. Under the use of these remedies Lassar asserts that the itching quickly subsides, that the infiltration is absorbed, and the affection gradually mastered. He adds that the above method of treatment is essentially aided by the use (before the application of the tar) of the following: ℞ Beta-naphthol, 1 drachm (4 grammes); sulphuris sublimat., 4 drachms (16 grammes); saponis viridis, vaselin., each 2 drachms (8 grammes). After this has remained in contact with the skin for from ten to fifteen minutes it may be replaced by a 25-per-cent. chrysarobin ointment, and after a similar interval the tar may be applied, and, finally, the protective application for the night. A very good application of this sort is the following: ℞ Hydrarg. precip. alb., acid. pyrogallic., each 1 drachm (4 grammes); lanolin., 1 ounce (31 grammes). Should impetiginous crusts, pustules, etc., be present, these may be rapidly healed by the following ointment: ℞ Hydrarg. oxid. rub., 5 grains (0.32 gramme); sulphur. sublimat., 2 drachms (8 grammes); vaselin., 1 ounce (31 grammes); ol. bergamot., q. s. M. A light, non-heating bandage should be kept on over night. In obstinate cases scarification may be resorted to in order to remove exudation and to deplete the congested capillaries. Rotter recommended, in cases where there was much weeping: ℞ Formæ, 4 to 8 grains (0.26 to 0.52 gramme); zinci oxidi, talci, each 6 drachms (23 grammes); vaselini, 1½ ounces (50 grammes). M.

Matschke[116 Oct.,'98; 2 Nov.25,'98] has on four occasions suffered from iodoform dermatitis. After two surgical lesions iodoform was used in the form of powder and gauze respectively, and each time a severe local eczema, accompanied by marked itching, œdema, and vesicles,

took place. On the second occasion the hand also had accidentally come into contact with the same substance, leading to the identical affection in that position. The third occasion arose after the author had suddenly been called upon to use iodoform gauze, no other substance being available. This time the affection was even more troublesome, and resisted all treatment, until it yielded to a 15-per-cent. thiol compress. Finally the author, while removing a surgical dressing applied by a colleague, came into slight contact with iodoform gauze, the eczema being eventually transferred from the hands to the face also. The œdema, redness, and vesicles, etc., were this time more severe, being again ultimately benefited by thiol. On these two latter occasions the dermatitis was accompanied by erysipelas and led to prolonged pigmentation. From the two last attacks it appears that no breach in the skin is required to produce this inflammation, and successive attacks were more severe and persistent.

Dermatitis Exfoliativa.—Savill [36 Apr.,'95] states that this disease, so far as he is aware, is the only skin malady which, up to the present time, has been connected with epidemic causes. Although it is undoubtedly, under some conditions, contagious and epidemic, it nevertheless not infrequently occurs sporadically. In some respects it resembles eczema, and the author thus formulates the distinctive points:—

ECZEMA.	EPIDEMIC EXFOLIATIVE DERMATITIS.
1. Attacks all ages, and children are very liable.	1. Children almost exempt; old people specially prone.
2. Gout is a marked predisposing cause.	2. Gout offers no predisposition.
3. Constitutional disturbance always moderate, and never fatal.	3. Constitutional disturbance often severe, and may be fatal.
4. Dried crusts thrown off, but exfoliation of cuticle not a marked feature of the disease. Dermal thickening absent or moderate.	4. Epidermal exfoliation a constant feature. It may occur in some places without previous eruption. Dermal thickening generally present.
5. Course not definite.	5. Course fairly definite.
6. Not hitherto regarded as contagious or epidemic.	6. Undoubtedly contagious and epidemic under certain conditions.

Though an organism exhibiting apparently distinctive characters was isolated by Risien Russell, the later bacteriological researches made with the exudation have failed to isolate any absolutely distinctive microbe, chiefly on account of the contamination with staphylococci. In treatment the most efficacious form was

the creolin bath. This consisted of about 15 gallons (60 litres) of comfortably warm water at 95° F. (35° C.), to which 2½ pints (1¼ litres) of a 1-per-cent. solution of creolin were added. The patient took a bath regularly once a day—in very bad cases twice—remaining in it twenty minutes. It is best given at night, the patient being subsequently gently dried and put to bed. Creolin ointment (½, 1, and 2 per cent., rubbed up with lanolin and water in almost equal parts) ranks next to creolin baths in efficacy, especially if used in quite an early stage. In very severe "moist" cases, where large tracts of skin presented a raw, profusely exuding surface, it seemed to be more soothing and suitable than the baths, but it was astonishing, even in these, how well the baths were supported.

Carlsson [370 V.54,No.4; 673 Oct.,'94] had under his care a patient 47 years old, a phthisical workman, who four years before had suffered from a similar attack of skin disease as well as pneumonitis. He had twice suffered from hæmoptysis. On the eighth day of an attack of croupous pneumonia symptoms of delirium appeared, and three days later an intense scarlatinoid eruption was seen on the thorax. The following evening the temperature was 41° C. (105.8° F.). Two days afterward excessive desquamation took place three times in succession, the scales being of different size and form, the largest five centimetres long by two or three centimetres wide. The hair came off readily, as did some of the nails on the hands and feet. The first desquamation lasted only a single day. The patient died twelve days after the appearance of the erythema. The subjective symptoms were itching, roughness, and tension of the skin. At the autopsy cavities were found in both lungs, with fatty degeneration of the heart, beginning cirrhosis of the liver, and acute parenchymatous nephritis.

Henry Handford [697 Mar.,'94] reports a case of dermatitis exfoliativa pigmentosa in which the disease bore a close resemblance to the pityriasis rubra of Devergie, with the exception of the pigmentation, which was very intense. Arsenical pigmentation is not usually so intense or so widely diffused, and argyria was excluded by the freedom of the mucous membranes from disease and absence of a history of the ingestion of silver salts. The case was improved by quinine, warm baths, and Unna's liquid gelatin painted over the skin and fixed by bandages. After two months the skin became less infiltrated and moist, desquamation ceased, but the

pigmentation was unchanged. The disease displays a tendency to recurrence when the patient's work as a collier is resumed.

Eczema.—This, the commonest of all skin diseases, has been, during the past year, the subject of many contributions to medical literature. Many of these are of little value, but a comparison of the various papers which have appeared shows the direction toward which dermatological theories regarding the etiology and pathology of this disease are tending. Two views of the nature of eczema appear to be prevalent: one of these assigns a microbic origin to the disease, the other a neurotic.

Holstein [157/Mar.,'94] lays stress upon the neurotic origin of the affection. Nikolski [21/June 9,'94] presents a paper on "Chronic Eczema in its Relationship to Anæsthesia of the Skin," in which he calls attention to the intimate relation between the nervous system and the skin, which, as an organ of sensation, must have a trophic centre, situated either in the posterior cornua of the gray substance of the cord or in the intervertebral ganglia. Nikolski, in 1887, observed a case of chronic eczema of the palm of the hand with coincident analgesia, thermo-anæsthesia, and slight diminution of the tactile sensibility of the upper extremities. Altogether he has seen twelve cases of chronic eczema connected with anæsthesia of the skin, most of the cases being connected also with hysterical symptoms. On the other hand, evidence accumulates to prove that very many cases of eczema are of microbic origin. Ravogli [15/Feb.,'94] has made experiments which lead him to believe that the staphylococcus pyogenes albus is a cause of eczema, and Jakob Bernheim [50/Feb.5,'94] goes so far as to assert that the microbes of eczema may penetrate the internal organs and lead to fatal results, giving an elaborate account of a post-mortem examination which he thinks proves his thesis.

Unna [404/Sept.,'93] considers the cause of seborrhœic eczema as microbic, the serpiginous character of the eruption, its want of resemblance to other forms of dermatitis (chemical and mechanical), and the effect of parasiticidal therapeusis all tending to confirm this view. Owing to the presence of saprophytes, which thrive luxuriously wherever the skin is favorable to their growth, the isolation of the true parasites is attended with great difficulty. Unna, however, believes he has succeeded in defining two species: the flask bacilli (Malassez's spores) and the morococci (mulberry-cocci). The former chiefly congregate in the crusts and scales of the hairy

scalp, the latter in those of the body, more especially when the seborrhœic eczema is moist.

Unna [41 June,'94; 451 Sept.] recommends for general use the following paste: ℞ Oxide of zinc, 1½ drachms (6 grammes); precipitated sulphur, 1 drachm (4 grammes); powdered talc, ½ drachm (2 grammes); benzoated lard, 7 drachms (27 grammes). M. The affected parts are first washed with soft soap dissolved in alcohol to remove the scales and crusts. A small portion of the paste is then rubbed into the skin, taking care to leave some of the paste spread over the skin after the inunction is complete. If this is well borne, 5 to 10 per cent. of ichthyol may be added in cases where there is marked hyperæmia, or, in anæmic cases, 5 to 10 per cent. of resorcin.

In cases where a mild prolonged treatment is necessary from irritability of the skin, the following treatment is recommended: ℞ Resorcin, 2 drachms (8 grammes); glycerin, 2 drachms (8 grammes); alcohol, 4½ fluidounces (150 grammes). One part of this solution is added to four parts of boiling water, and in this thin layers of cotton-wool are soaked and then placed upon the affected skin at night, a piece of rubber tissue being bandaged over this dressing to prevent evaporation. In cases of generalized seborrhœic eczema the body is washed every evening with warm water, to each quart (litre) of which has been added from ½ to 1 drachm (2 to 4 grammes) of resorcin, according to the age of the patient. In addition, the patient should wear a flannel shirt steeped in the same solution, and the sulphur paste mentioned above should also be used.

In moist eczema about the ear and in the auricles, according to Chatellier, [24 Feb. 4,'94] the parts should be washed with a warm, weak solution of bichloride of mercury several times daily and then dusted with iodol. When the eczema is dry, an ointment of 15 grains (1 gramme) of iodol to 1 ounce (31 grammes) of lanolin may be used. In the external canal the desquamating epithelium should be removed by absorbent cotton twisted upon an applicator and the canal anointed by the same ointment made with paraffin-oil. The introduction of a tampon of wool will keep the oil in the canal. The dressing is to be renewed night and morning.

P. Cousin [2031 '98] says that treatment of eczema by India-rubber cloth has recently been revived by Tennesson, who previously cleans

the skin thoroughly by sponging it off with a weak boric-acid solution. The rubber cloth is very soft and flexible, and, where the eczema is acute weeping, he changes it as often as every hour or two, as soon as the surface begins to itch. The cloth is taken off, cleansed thoroughly with boiling water, and re-applied. It is generally better to have two cloths, so that the surface need not be left exposed a moment longer than is absolutely necessary. When the eczema has ceased to weep, and the diseased surface begins to be covered with a fine, dry, epidermic layer, the rubber cloth is to be discontinued and other means employed to complete the treatment.

Klotz [245 Mar.,'94] states that in the treatment of eczema it makes no difference whether the disease is of a parasitic, nervous, or trophic origin or due only to external irritation. The most necessary and important thing, especially in the eczema occurring in connection with pediculi capitis, is the immediate disinfection of the parts and protection against new infection. The crusts are removed by the use of soap and water at first and afterward with a 1 to 3000 or 1 to 5000 solution of corrosive sublimate. In the evening, and if possible in the morning, lint or cotton pads, thoroughly soaked with the solution and kept constantly moist, are to be applied from one-half to one hour. Then the parts are to be carefully dried, and a 10-per-cent. boric-acid-vaselin ointment rubbed into the skin and a bandage applied.

Malcolm Morris, in a paper on the management of eczema, [697 Sept.,'94] says that, the less internal medication used, the better. Of course, if some obvious indication is to be met the appropriate remedies should be used, but specific internal medication is worse than useless. In acute inflammatory eczema he gives 10 to 13 minims (0.65 to 0.84 gramme) vinum antimoniale, repeating the dose in an hour and, if need be, two hours later. The interval between the administrations is gradually increased, the dose being at the same time reduced till one of 6 minims (0.39 gramme) is reached. This should be given thrice in twenty-four hours until a distinct subsidence in the intensity of the inflammation is reached. The indication for antimony is the presence of arterial tension; on the other hand, depression is a distinct contra-indication of the drug. If a neurotic tendency is clearly present, sedatives and nerve-tonics must be used. Opium should be employed continuously until the

nerve-storm subsides. The constipating effect is to be combated by the use of saline aperients, such as Carlsbad salts. If opium disagree, some other sedative, as sulphonal, must be used. The indication for sedatives is great nervous excitement accompanied by sleeplessness. If the neurotic element show itself in the form of depression, quinine is the best tonic. Malnutrition, weakness, and anæmia are indications for codliver-oil and general tonic treatment on ordinary principles.

Morris thinks that diet has only an indirect influence in the course of eczema, and practically suggests the use of common sense in the regulation of the patient's regimen. As regards the local treatment the strength of the remedy must be tempered to the tolerance of the patient's skin. He begins with the use of a weak parasiticide and feels his way toward the use of stronger preparations with the most watchful care not to cause irritation. The best remedy for local use in dry, chronic eczema is sulphur and, next to that, resorcin. He begins with an ointment of 10 grains (0.65 gramme) of one of these drugs to 1 ounce (31 grammes) of oxide-of-zinc ointment. "Ichthyol," he says, "is a vascular sedative as well as a parasiticide, and is useful in acute eczema, as also are salicylic acid, boric acid, white precipitate, and carbolic acid." He uses Unna's plaster-mulls of carbolic acid, mercury, and oxide of zinc. When the discharge is profuse the part may be washed with a weak solution of boric acid and dried with muslin bags containing starch and powdered boric acid. To overcome the tendency to the recurrence of eczema in those predisposed to it, Morris suggests change of climate and rest of mind and body. Too bracing climates and sea-air are to be avoided. Sulphur, arsenic, and iron mineral waters are to be recommended.

Thibierge, [14] in an article on the treatment of eczema of the scalp, recommends phenosalyl (1 to 300), or solution of boric acid covered with some impermeable tissue to remove the crusts, followed by corrosive sublimate (1 to 4000). When the inflammation becomes less acute he employs: ℞ Olei morrhuæ, olei amygdalæ dulcis, āā, 1½ ounces (46.5 grammes); naphthollis seu resorcin, 15 grains to 1 drachm (1 to 4 grammes). M. Another formula is: ℞ Sulphuris, 1 to 4 drachms (4 to 16 grammes); naphthollis, 1 drachm (4 grammes); acidi salicylici, 15 grains (1 gramme); vaselini seu axungiæ, 1½ ounces (46.5 grammes). M.

When the seborrhœic element is marked he uses: ℞ Sulphuris, 1 to 4 drachms (4 to 16 grammes); balsami Peruviani, ½ to 2½ drachms (2 to 10 grammes); vaselini, axungiæ, each 1½ ounces (46.5 grammes). M.

Molènes $^{31}_{\text{Oct.18,'93}}$ gives a very interesting *résumé* of the internal treatment and regimen appropriate to eczema, referring to Schweninger's remarkable writings on this subject. Rose $^{186}_{\text{June,'94}}$ employs an ointment of 10 to 15 grains (0.65 to 1 gramme) of sulphate of quinia, 10 grains (0.65 gramme) of sulphate of iron, and 1 ounce (31 grammes) of lanolin.

P. Cazeneuve and E. Rollet $^{80}_{\text{Feb.15,'94}}$ recommend gallanol in the form of powder, or as an ointment with traumaticin, 3 to 30. Trousseau $^{996}_{\text{No.2,'94}}$ has obtained unexpected results in eczema of the eyelids with local applications of a solution, without alcohol, of corrosive sublimate, 0.05 to 0.25 gramme (⅞ to 4 grains) to 500 grammes (16 ounces) of water. Compresses soaked in this fluid are also employed. He has observed remarkably prompt results after the ordinary means had failed. Internally, quinine may be given; and, locally, the employment of a solution of carbolic acid, to allay the itching. Salves are contra-indicated, as they are not well borne and sometimes cause the affection to become aggravated. They may, however, be used in the terminal period, when desquamation of epithelium sets in, and then only with caution, first trying those least irritating, as pure vaselin or lard; then bismuth, oxide of zinc, ichthyol, yellow oxide of mercury, or oil of cade.

M. B. Hartzell $^{51}_{\text{Apr.,'94}}$ gives the following directions for the treatment of vesicular and squamous eczema: When inflammatory symptoms are slight and moisture absent, use the following paste: ℞ Acid. salicylic., 10 drachms (40 grammes); pulv. amyli, zinci oxidi, each 2 drachms (8 grammes); petrolat., ½ ounce (16 grammes). M. Sig.: To be applied twice a day. Where inflammation is more acute, with abundant oozing of serum, saturated solution of boric acid in water to be freely and often applied. Soap prohibited. Vaselin to be used for cleansing, when necessary.

Jumon $^{108}_{\text{Sept.,'94}}$ claims that most cutaneous affections in children under 5 years are eczematous. Etiologically, alimentation and dentition play an important part, while the skin is naturally

delicate and easily irritated. By way of prophylaxis, one should avoid all irritants; soaps should be neutral. Vaselin is of great use in cleansing and softening the skin. Frictions should be avoided in drying the child after a bath and wool clothing should not be put next the skin. If the eczema simulate impetigo he applies sublimate, 1½ grains (0.1 gramme), to the quart (litre) of water, and, when the inflammatory signs begin to abate, he prescribes ointments of the following composition: ℞ Sulphur (washed), 1 part; zinci oxidi, 4 parts; vaselin, 30 parts. Or, again: ℞ Acidi salicylici, 1 part; zinci oxidi, 40 parts; vaselin, 300 parts. When there is much seborrhœa, lotions of Sodii borat., 10 parts; aquæ camomil., 500 parts; followed by Zinci oleat., 5 parts; adipis, 50 parts; will be very efficient. Or, if the child is older, the latter formula may be replaced by Hydrarg. chlor. mit., 1 part; zinci oxidi, 4 parts; vaselin, 40 parts. It is well to avoid alcoholic applications and to protect the eczematous patches with bandages to keep the child from scratching the lesions.

In the treatment of eczema of infants Marfan [8 Mar. 26, '94; 15 July] says that the child should be fed as follows: For the first month it should have the breast regularly every two hours during the day and twice during the night; for the second and third months, seven times in the day and once in the night; from the fourth to the sixth month, six times a day, once in the night; and during the next three months six times a day. The diet of the nurse must be strictly regulated. For internal treatment he recommends the use of calomel in doses of ⅙ to ¼ grain (0.01 to 0.015 gramme), administered once a week or twice in ten days. Locally the affected surface must be kept rigidly clean and free from crusts and scales by the use of starch poultices and washing with a 3-per-cent. boric-acid lotion; and in cases of impetiginous eczema a very weak watery solution of corrosive sublimate, such as 1 in 10,000, ought to be used. In three or four days this treatment should be stopped, and an ointment consisting of 1 drachm (4 grammes) of oxide of zinc, 15 grains (1 gramme) of sulphur, and ½ ounce (16 grammes) each of lanolin and vaselin substituted. In place of the sulphur resorcin may be used, from 5 to 15 grains (0.31 to 1 gramme), according to the tolerance of the skin of the patient. Where there is dry eczema in scattered patches in youth-

ful dyspeptics, the digestive troubles must be carefully attended to. The most minute details on the sterilization of the milk must be given, the degree of dilution, on the quantity of the milk, and the number of times the child should be fed. If there be vomiting Marfan washes out the stomach and irrigates the large intestine with boiled water. When there is green, watery diarrhœa he prescribes paregoric elixir, salicylate of bismuth, or salol. In violent itching the child must be prevented from scratching, either by tying its hands or covering the affected part. If dentition bring on an acute attack, the irritation of the gums may be relieved by touching them with the finger dipped in a solution of cocaine and bromide of potassium. Carver $_{\text{Sept.16,'98}}^{59}$ thinks that every newborn child should be treated as liable to an attack of eczema. The fat or oil used to remove its smegma should be of the blandest quality and the soap should be perfectly neutral. Pears's soap is recommended, which is not by any means neutral.

In the seborrhœic eczema of infants Feulard $_{\text{Aug.10,'94}}^{212}$ begins by using lotions of saponated coal-tar,—about a teaspoonful in 1 pint (½ litre) of water,—after which the crusts are removed by starch poultices. Compresses of tarlatan soaked with a solution of resorcin in recently-boiled water—about 2 grains (0.13 gramme) to the ounce (31 grammes)—are then applied throughout the day, while at night an ointment of 16 grains (1 gramme) of balsam of Peru to 1 ounce (31 grammes) of vaselin is rubbed in and a powder of carbonate of bismuth and starch dusted over this.

Epithelioma.—White $_{\text{Nov.,Dec.,'94}}^{245}$ has recorded a case of multiple, benign, cystic epithelioma in a woman, the lesions being situated upon the face, from the size of a pea to an inch in diameter. Other lesions were scattered over the neck, shoulders, and forearms, those on the face only showing secondary transformation. Dujardin $_{\text{June 16,'94}}^{220}$ used pyoktanin in a case of epithelioma of the eyelid, in a man aged 71. It was covered with a crust, and had a hard, festooned, and slightly-raised margin. It was of about three months' duration and was gradually extending. It had caused very little pain. The treatment consisted in the local application of a 1 in 20 solution of blue pyoktanin on alternate days. This was continued for several weeks without result. Then, suddenly, on the day following an application of the solution, the epithelioma became painful and surrounded by an erysipelatous redness.

The local inflammation increased, and the ulceration rapidly extended until it became almost doubled in size. The pyoktanin was discontinued, and poultices and boric ointment applied. Gradually the inflammation subsided, and the ulcerated surface became freed from crusts and of a healthy rose color. It gradually diminished in extent until only a firm cicatrix remained.

Erysipelas.—Tschourilow, in making some experimental researches in the laboratory of Nencki, at the Imperial Institute of Experimental Medicine at St. Petersburg, [1101 Dec.,'93; 673 Feb.,'94] came to the conclusion that subcutaneous injections of ortho- and para- chlorphenol and orthobromphenol, in feeble solutions (1, 1½, or 2 per cent.), killed spores as resistant as anthrax more quickly than did a 5-per-cent. solution of carbolic acid. His results led him to use these drugs in the treatment of erysipelas, in the form of an ointment, 1 per cent., 2 per cent., and 3 per cent. of the preparation to 100 grammes (3½ ounces) of vaselin. Friction of the affected parts was kept up for one minute twice a day. These frictions never produced irritation, even in patients, with nephritis, presenting general œdema of the skin. During the first few applications the patients felt a slight lancinating pain in the parts, but this altogether disappeared. The only treatment of the erysipelatous process consisted exclusively in the local application of the drugs. There was no general treatment, and no antipyretic was given, although in 1 case the temperature reached 40.8° C. (105.4° F). The results were excellent. In 6 cases the erysipelas disappeared on the second day, in 8 on the third day, in 3 on the fourth day, in 2 on the sixth day, and in 4 on the seventh day. The longest treatment was for eight days,—in 2 patients with bullous erysipelas of the face and head, general weakness and delirium, and temperatures reaching 40.8° and 40.5° C. (105.4° and 104.8° F.). None of the 25 cases assumed the so-called phlegmonous character, as the author observed in other methods of treatment. He believes that the remedies would be still more efficacious if administered by subcutaneous injection, as it would come in contact more quickly with the pathogenic microbe. That the injected substance would involve no danger either to the organism or to the skin in the vicinity of the injection he has proven by injecting into himself, on the sides of the abdomen, two Pravaz syringefuls of a 1-per-cent. aqueous solution of parachlorphenol.

Zelewsky [673 Mar.,'94] has found ichthyol efficacious in every form of erysipelas, and in his opinion it is superior to other remedies. In some cases of migratory erysipelas affecting both sides of the patient's body, he painted one side with Trousseau's solution (acidi tannici, camphoræ, āā 2.0 grammes—31 grains; æther. sulph., 15.0 grammes—3¾ fluidrachms) and the other with ichthyol, the morbid process subsiding much more quickly under the latter treatment than under Trousseau's solution. He prescribed the drug as follows: Ammon. sulpho-ichthyol, spir. æther., āā 1 part; collodii elastici, 2 parts. Thomas [187 July,'93] states that success depends upon very thorough rubbing of a strong ointment of ichthyol with vaselin or lanolin into the red area and into the adjoining healthy skin, covering the parts with a sheet of lint or the ordinary surgical dressing. Hallopeau [80 Feb.15,'94] uses the following combination: ℞ Gutta-percha, chloroform, of each, 25 grammes (6½ drachms); ichthyol, 50 grammes (1½ ounces). This is applied not upon the diseased parts, but around these, that a barrier may be formed, so to speak, against the progress of the malady.

Arnozan [243 Nov.2,'94] recommends the following treatment: Quinine is administered in doses of 8 to 16 grains (0.52 to 1.04 grammes) in accordance with the temperature, 4-grain (0.26 gramme) pills being given three or four times daily, so that the patient is kept constantly under the influence of the drug. Over the affected surface is applied an ointment made up of: ℞ Bichloride of mercury, 1 grain (0.065 gramme); lanolin, vaselin, of each, ½ ounce (16 grammes). Of twenty-five cases thus treated there was frequently noted a prompt arrest of the eruption, or, in case this failed, marked alleviation of the symptoms. The temperature fell in three or four days, and the average duration of the attack was five to seven days.

Whalen [61 Apr.20,'94] has used guaiacol successfully in facial erysipelas, employing from 20 to 30 minims (1.3 to 2 grammes), diluted, if necessary, with alcohol, olive-oil, or any of the fixed oils. Tordeus, [357 July,'94] in the erysipelas of children, applies locally compresses saturated with: ℞ Spirit. camphor., 1000; hydrarg. chlor. cor., 0.05. Internally a solution of antifebrin and resorcin, in doses of as many centigrammes of antifebrin as the child is years old, and of resorcin twice as many centigrammes as the child is years old. The solution is given three or four times a day.

Dietz [116 Oct.,'93; 2 Nov.11] has tried the mechanical treatment of erysipelas advocated by Kroell. [116 No 2,'93] He surrounded the arm (which was the seat of the affection) with a narrow strip of adhesive plaster, at a distance of one-half centimetre from the reddened area. On the following day, after removal of the plaster, the œdema was seen to cease abruptly at its lower border, excepting on the inner surface of the arm, where, at the situation of the vessels, etc., the plaster had purposely not been applied so tightly, and where the erysipelas had crept up the breadth of two fingers toward the axilla. A fresh band was therefore fixed more tightly immediately above the point, supplemented on the following day by a second one immediately above the former, the possibility of some loosening being taken into consideration. Three days later the plaster was removed, the disease having presumably been kept in bounds thereby, and recovery having taken place. The author confidently recommends this procedure in similar suitable cases.

Salinger [80 Mar.,'94] tried pilocarpine, hypodermatically in twenty-eight cases, with very gratifying results. He concludes that the full physiological action must be produced; that is to say, that unless marked sweating, increased salivation, and increased diuresis are noticed, good results cannot be expected. He advises doses of $\frac{1}{6}$ grain (0.01 gramme) every four hours until such effects are produced. When called early and case is circumscribed, J. McFadden Gaston [19 Mar.24,'94] uses ℞ Carbolic acid, 1 fluidrachm (4 grammes); glycerin, 3 fluidrachms (12 grammes); distilled water, 4 fluidrachms (16 grammes); mixing and injecting hypodermatically one syringeful to each portion the size of the hand daily.

Erythema Elevatum Diutinum.—Crocker and Campbell record [697 Jan.,Feb.,'94] a peculiar and unusual condition of the skin of the knees, buttocks, and elbows, and finally of the hands, in a female of 6 years. The lesion in right index finger most nearly typical was raised one-eighth of an inch, convex, sharply defined, pale purplish red in color, with a few dilated vessels over it, somewhat whiter on pressure, but diminishing very little in size; firm to the touch, very tender, but not painful except when pressed upon. It did not itch or burn. The microscope showed a chronic inflammatory process affecting both plexuses of the corium, but attacking only the upper wall of the deep plexus. The fibrous tissue was more developed in the older lesions. Crocker quotes a similar

Erythema Induratum of the Scrofulous. (Hutchinson)

Archives of Surgery.

BURK & McFETRIDGE LO LITH PHILA

case, which was recorded by Bury, [2155 Feb.22,'90] in a girl of 12 years. It began first on the toes, then attacked the knees, then the elbows, and finally the hands. Crocker's case had been treated with liquor arsenicalis, at first in 2-minim (0.13 gramme) doses and afterward increased to 4 minims (0.26 gramme); tincture lupuli, and a lotion of liquor carbonis detergens. Afterward a piece of skin was removed, and it was a question whether the arsenical treatment or the operation was the means of cure. Bury's case had been treated with ammoniated-mercury ointment and small doses of arsenic internally, but without effect. This latter case was seen by Hutchinson three years later, when it was found unimproved, some of the lesions having become thicker and more nodular.

Erythema Induratum of the Scrofulous (Bazin's Disease).—Hutchinson [806 Oct.,'90] describes cases of this curious affection. The disease is a manifestation of scrofula occurring mostly in young women, in which multiple ulcers, the consequence of a subcutaneous and self-infective inflammation, occur on the legs, such ulcers being difficult of cure, prone to relapse, and presenting appearances very likely to be mistaken for syphilis. White [245 Nov.,Dec.,'94] mentions four cases, and states that the lesions are very similar to those of erythema nodosum, but that, instead of remaining as nodose tumors, they break down and form ulcerations. They also differ in the fact that there is a successive crop, and that the time of their appearance may be extended over a considerable period. After ulcers, which are very sluggish, have formed, the health of the individual may suffer greatly.

Erythema Multiforme.—E. Freund [814 Apr.25,'94] describes cases of erythema multiforme where, owing to faulty processes in the digestive tract, the production and absorption of toxins were possible. Examination of the urine and fæces disclosed a large excess of indol, skatol, indoxyl, and skatoxyl, as well as phenols and organic compounds of sulphuric acid,—bodies such as occur in putrefactive decomposition of albumin in the intestine. Besides these, an abundance of diamins was discovered. Disinfection by calomel was followed by very rapid cure.

In cases of "erythematous affections which remain fixed upon the skin for weeks, months, or even years, without alteration of type" J. F. Payne [245 Aug.,'94] finds that the disease may be successfully

combated by certain drugs, and that when the eruption betrays no tendency toward spontaneous resolution after the lapse of a considerable time, the indication for their use is a strong one. The agents which have given him the best results are quinine in large doses and sodium salicylate. The indications for each are not clear. Twenty to 30 grains (1.3 to 2 grammes) of quinine in 5-grain (0.32 gramme) doses should be given daily. Sodium salicylate does not always give the best results in rheumatic subjects. The quinine was most satisfactory, but if, after a fair trial, it do not cause improvement, the salicylates should be substituted. The local treatment has two ends in view: astringent as regards the blood-vessels and sedative as regards nerves. Lead lotion meets the first; coal-tar, carbolic acid, etc., the second. Ointments are objectionable on the ground of their causing retention of the heat of the skin.

Folliculitis.—Kaposi [45 B.26,H.1; 607 Aug.,'94] describes a case of *folliculitis necrotisans et exulcerans serpiginosa nasi.* He has had three cases under his care,—two males, one female. The disease occurs in middle age, and appears as an acute eruption on the apex of the nose. Necrosing nodules from a pin-head to a bean in size quickly develop, leaving exposed an uneven, pus-colored, granular surface. This necrosing process involves the whole of the fleshy part of the nose, destroying the skin, and in the course of a few weeks heals, leaving cicatricial pits. It does not spread to the skin over the nasal bones. The characteristic point is the formation and speedy necrosis of vascular nodules around the follicles of soft parts of the nose. Microscopically there is a total absence of any attempt at organization of the new tissue, abundant granulation, and numerous giant-cells. Lukasiewicz [45 H.2,'91] has recorded a somewhat similar case of folliculitis exulcerans attacking the nates and lower extremities of an anæmic girl, which only yielded to treatment with the thermo-cautery; and since then slight fresh eruptions, not so severe, have appeared in the neighborhood of the primary seat. The treatment adopted in the three cases was purely local, scraping, lunar caustic, and the thermo-cautery; the previous application of salicylic acid and mercurial plasters availed nothing. The more radical measures effected a permanent cure.

In the same paper Kaposi gives the history of two cases of another form, viz., acne telangiectodes. The first is that of a

male, aged 48 years, who had, four weeks previous to admission to the clinic, an eruption on the forehead, cheeks, and lower eyelids, consisting of rosy papules, some grouped, others scattered, varying from a small shot to a bean in size. Some were topped with a scale, others showed a bead of pus at the apex; the majority were smooth, and blanched on pressure with the finger. The patient was a metal-worker by trade, but this had no connection with the disease. Histologically there was vascular granulation tissue, giant- and epitheloid cells, but no micro-organisms, situated in the deeper layers of the corium around the hair-follicles and coil-glands. Treatment with medicated soaps and sulphur and resorcin pastes proved inefficacious. Scooping out effectually cured the eruption, leaving small scars.

Herpes Zoster.—Hartzell, [245 Sept.,'94] in a paper read before the American Dermatological Association on May 31, 1894, refers to protozoa-like bodies found in the vesicles of herpes zoster, stating that they are not found in the ordinary inflammations of the skin, but are peculiar to zoster, variola, vaccinia, and varicella. He gives the credit of their description to Pfeiffer, who believed that they were parasites of the order of protozoa which entered the skin and gave rise to the characteristic eruption of zoster. Hartzell examined these bodies from three cases, two of the idiopathic dorso-pectoral type and one of recurrent zoster of the sciatic nerve, and states that they consist of three distinct parts: (*a*) the cell-body proper, a broad ring of tolerably uniform width without any external limiting surrounding membrane; (*b*) a thick internal wall or capsule which in turn incloses (*c*) a large cavity in which there are contained from three or four to a dozen or more round or oval cells. He further believes that they are not protozoa, but altered portions of epithelium which it is only fair to suppose are present in other diseases held to be due to psorosperms. Cantrell [9 Apr.,'94] gives the history of a case of zoster from inception to termination and describes the varying conditions met with. The lesions were erythematous, papular, and vesicular, at first remote from the centre of the affected nerves (the brachial plexus), contrary to the generally accepted views. The writer describes zoster as appearing at first as an erythematous redness, scattered in macules of irregular size over the course of the affected nerve and remaining for an indefinite time, followed by the formation of papules upon

these erythematous bases, which, in turn, quickly or slowly change completely into vesicles. Billstein [119 Aug.15,'94] used salol in the treatment of herpes zoster, observing an immediate abortive effect.

Hydroa Vacciniforme—The Summer Eruption of Hutchinson.—Bowen [245 Mar.,'94] describes a case of hydroa vacciniforme,—the first mentioned in America. The lesions in the early attacks were confined to the face, but later the hands as well were affected. Those of the face left small pits closely resembling small-pox depressions, while numerous cicatricial points were visible upon the ears. After careful histological examination of both early and late lesions, the author arrives at the conclusion that the disease begins as an inflammation of the epidermis and upper portion of the corium in a circumscribed area, which quickly becomes a vesicle. Should the lesion proceed farther than this, necrosis is likely to follow. The vesicles may at times be very large,—either by extension or confluence,—subsequently drying and showing a closely-adherent crust, which, upon being thrown off, reveals a varioliform depression or pit.

Hyperidrosis.—Unna [697 Sept.,'94] has somewhat changed his views in regard to the function of the sweat-glands as expressed by him some years ago. At that time he held the radical opinion of Meissner, that only fat was formed in the sweat-coils, the watery portion of the sweat coming from the papillary layer of the skin. He now adopts the view of Henle, that, during ordinary secretion, the sweat coming from the glands is made up largely of specific secretory elements, but that, under the influence of appropriate stimuli, a watery fluid is formed which is very poor in specific elements.

Neebe [22 May 2,'94] treats hyperidrosis of the feet by means of crude hydrochloric acid. When the feet are very tender, especially in hot weather, treatment is preceded by an eight to ten days' application of compound-talc powder, which is sprinkled in the stockings. The application of the acid is best made in the evening. The crude hydrochloric acid is poured into a flat vessel of stone or glass or porcelain sufficiently large to receive the two feet. Since the soles of the feet and the skin between the toes are the seat of the trouble, sufficient hydrochloric acid is poured into the vessel to completely cover the soles. It should not be allowed to come in contact with the skin of the backs of the feet. The heels

are kept in the acid for five minutes; then the soles of the feet for ten minutes. After this the feet, especially the skin between the toes, are washed in soap or warm water. Soaking in the acid must be at once stopped as soon as pain is excited, and the painful spots must be treated with zinc ointment until healing is complete. The process of soaking may be repeated twice weekly, and continued for from five to eight weeks, in obstinate cases.

Ichthyosis Congenita.—Sherwell [245 Sept.,'94] records an interesting example of congenital ichthyosis in which the child weighed only two pounds at birth, and was living, at the time of his report, at the age of 5 months. The treatment consisted of inunctions of oily substances until the child was somewhat older and able to bear the use of washes of borate of soda.

Keloid.—Cantrell and Stout [119 Aug.4,'94] record an example of keloid occurring in two male members of the same colored family, and believe that family predisposition certainly must play a decided factor in the production of this complaint.

Leprosy.—J. N. Hyde [2139 '94] gives a *résumé* of the distribution of leprosy in North America. The credit of first collecting statistics as to the number and location of lepers in the entire country is due to the American Dermatological Association. Under the leadership of James C. White, of Boston, investigations were begun and a year later the first "Report of the Statistics of Cutaneous Diseases in America" was published. Credit must be given to the work done by C. Grönbold, of Minnesota; N. W. Blanc, of New Orleans; Allen, Morrow, and Piffard, of New York; and W. H. Giddings, of South Carolina.

Campana, [589 V.4,Nos.288,289; 2 Dec.9,'93] who has long experimented with the bacillus of leprosy, believes that he has succeeded in cultivating it. He describes the organism which he has cultivated as "a bacillus similar to the bacillus of leprosy," which developed in attempts made to cultivate an organism from tissue taken from a case of tubercular leprosy. The bacillus has a length of one-third to one-half of the diameter of a red corpuscle of the human blood; that is, it is from two to four micromillimetres, the breadth at the thickest parts being one-fifth to one-eighth of its length. It is usually straight, but in rare instances somewhat flexed. When stained the protoplasm is homogeneous, but sometimes interrupted by minute points clearer than the rest. Campana cultivated the

organism in agar-agar with grape-sugar, with the addition of 1-per-cent. peptone. It thrives most luxuriantly at a temperature of 37° to 37.5° C. (98.6° to 99.5° F.). Treated with fuchsin and nitric acid, it retains the red coloration until placed in the second stain, which then takes the place of the first.

Montgomery [9 Apr. 14, '94] reports the case of a young man who had, seven years before the first manifestations of his malady, resided in the Sandwich Islands. Two years before he came under observation a small red pimple had appeared over the left malar bone. When examined there was in this region a plaque of reddish-brown skin with steep borders as large as a fifty-cent piece. Over the anterior surface of the lower third of the right radius there was a red desquamating patch as large as a silver dollar. There was no atrophy nor any fibrillary twitching of the muscles. The ulnar nerves could be felt distinct and hard as they passed over the internal condyles. There was analgesia but no anæsthesia of the patches. The temperature-sense in the patches was diminished. Eyesight, smell, taste, and hearing were normal and the tendon reflexes were natural. A section was cut from the patch on the face, but, though carefully examined, no lepra bacilli could be found. This is not to be wondered at, even if the diagnosis of leprosy were correct, as it is often impossible to demonstrate them. The unusual part of the microscopical finding was the presence of giant-cell-like bodies. These were not exactly like the giant-cells of Langhans, as they were more circular and presented at the periphery usually a single row of round nuclei. Hansen thought that these structures were probably capillary blood-vessels the nuclei of which were undergoing proliferation. The author agrees with this opinion.

In a paper which was awarded the Alvarenga prize for 1892 by the College of Physicians of Philadelphia, Bibb [5 Nov., '94] concludes: 1. That leprosy is a specific disease due to the presence of the lepra bacillus. 2. That it is influenced by race, climate, soil, food, etc., only in so far as these tend to enervation on the one hand or to physical well-being on the other. 3. That experiments have not demonstrated it to be inoculable on man or beast. 4. That it is hereditary. 5. That it is contagious, infectious, and communicable under conditions not yet understood. 6. That it is both mitigable and curable. 7. That chaulmoogra-oil is a drug of

unquestionable value in the treatment. 8. That it may be completely eradicated from the list of human ills. Dyer [143 May,'94] describes leprosy throughout its entire course, and refers to the diagnosis and its treatment by chaulmoogra-oil, which he advised in doses beginning with 5 drops, hoang nan in doses of 3 grains (0.20 gramme) three times a day, combined with the use of tonics. He recommends the removal of lesions either by caustics or the cautery, and their absorption by suitable applications such as iodine, nitrate of silver, and the electro-cautery.

Lichen Planus.—Thibierge and Leredde [287 V.2,No.11] describe a case of this affection in a woman aged 48 years, the daughter of a negress, her father being a mulatto. The papules were black and hyperpigmented, the surrounding skin being of a bronze color, and the polygonal outline and the bright tops less marked than in white people. The eruption was present on the neck, chest, arms, and legs. On the neck the papules were all isolated and not hyperpigmented, but were more of a gray color, which was not the case in any other situation. A detailed account of the results of microscopical examination is given, which, in the main, accords with that generally described.

Welander, of Stockholm, [370 V.56,No.4] describes the case of an iron-worker, aged 24 years, who experienced a severe mental shock due to an accident in which he was nearly drowned. He became very nervous and lichen ruber planus, lichen simplex chronicus, and vitiligo developed together, one independent of the other, in a period of eighteen months. Welander was able to clearly diagnose the three separate diseases.

Lichen Scrofulosorum.—Of 43 cases seen by Lukasiewicz, 35 were males and 8 females. [45 B.36,H.1; 697 Oct.,'94] As a rule the eruption was confined to the trunk, and the efflorescences individually and relatively agreed with Hebra's description. In 2, eczema of the pubic and inguinal regions was present, and on the lower extremities there was also acne cachecticorum. In 21 cases the eruption was limited to the belly, lower half of chest, and back; in 11 it was also distributed over the extensor and flexor aspects of the upper and lower extremities. In 1 case, that of a female aged 21 years, the lower extremities alone were the site of a thick eruption of lichen scrofulosorum. Four weeks previously she had been confined; the disease appeared in the latter months of pregnancy, and

it disappeared on the internal administration of oxalate of iron. The duration of the disease previous to treatment varied from ten weeks to a year. Disappearance of the eruption was frequently accompanied by copious desquamation. A pigmented, atrophic condition of the skin marked the site of the larger patches of lichen efflorescences. As a rule, tonics and dieting alone effected a cure, even of severe cases, in from two to eight weeks; when combined, however, with local measures (oleum morrhuæ, zinci pasta, ung. acidi borici, ichthyol, baths) the duration of treatment was considerably shortened. In 2 cases a relapse occurred after discharge from the hospital,—in one a month after, in the other a year, in both owing to deficient nourishment. The age of the patients varied from 7 to 56 years; the majority of the cases were under 26 years of age. As regards the presence of tubercle, 7 suffered from tubercular lymphadenitis (neck and axillæ); 3 from scrofuloderma, of which 1 case had also caries of the tarsus; 3 patients had catarrhal conjunctivitis, 6 lupus vulgaris (face 2, extremities 4), 2 cold abscesses; 1 suffered from lymphadenoma of the glands of the neck. Out of the 43 cases 1 died three months after admission to the hospital; during this period the eruption nearly disappeared; a few scaling efflorescences still remained; and the autopsy revealed tuberculosis of pericardium, and of cervical, mediastinal, and bronchial glands. In 8 cases there was hereditary predisposition to tuberculosis. On the other hand, in 7 there was no history at all of phthisis, and their present condition, although admittedly deteriorated, was by no means debilitated, but rather the result of malnutrition. Lukasiewicz's view of the etiology of lichen scrofulosorum is that the disease is the result of malnutrition, be that due to tuberculosis (one of the most frequent causes of malnutrition), or to insufficient diet, or to some extra strain—*e.g.*, pregnancy—which the organism is liable to and not able to bear within the limits of health. He also draws attention to the fact that the presence of giant-cells in the infiltrate is itself an indication of malnutrition, karyokinesis having taken place, but the division of protoplasm has not followed, as it would have done had the cell been nourished properly.

Lichen Simplex Acutus, Vidal.—Of this rare skin disease, described by Brocq under the name of prurigo simplex acutus, Rasch, of Copenhagen, [373 No. 12, '94] describes a typical case occurring in a

woman aged 22 years, appearing about three weeks after vaccination. The eruption of the small, conical, red papules commenced on the forearms, spreading to the hands, leaving, however, the fingers free. On the trunk and knees a few papules were also present. Three weeks later the skin was entirely normal. Colcott Fox [607 Aug.,'94] observed an otherwise healthy lad of 14 years in whom there was some difficulty in diagnosing a thickly-disseminated miliary papular eruption, a folliculitis of acute production, but of little inflammatory intensity. The papules were pale, and in this respect contrasted with the red papules of miliaria and eczema. On the other hand, it did not appear to belong to the cases of acute wide-spread miliary lichen scrofulosum, in which grouping was, on rare occasions, very slight.

Lupus.—Crocker [245 Jan.,'94] regards lupus erythematosus as an imitator of erythema tuberculatum, and quotes three cases illustrating its polymorphism. In one of these it simulated psoriasis guttata of the breast in a female; in two others it very closely resembled lichen planus; in another it had been treated for syphilis, while another case resembled angioma serpiginosum. The tuberculous nature of disseminated lupus erythematosus, asserted by Besnier and others, is supported by a case which came under the observation of Audry, of Toulouse. [479 Aug.,'94] The patient was a man of 58 years who had had for an indefinite, though long, time various patches of lupus erythematosus situated on the face, lobe of the ear, leg, and thigh. The description accords with that of a severe type of the disease, and Audry expressly states that it was not lupus vulgaris. The man had bronchitis, but no bacilli were found in the sputum. Iodide of potassium was prescribed, and he died with intense anasarca, accompanied with the production of bullæ. In the integumentary lesions were found tubercular infiltrations, with giant-cells, but no bacilli. Jonathan Hutchinson [607 Oct.,'93] gives notes on a form of acne lupus which occurs on the shoulders in connection with lupus erythematosus of the scalp, and describes a case of lupus sebaceous [806 Apr.,'94] in a clergyman's wife with a strong family history of tuberculosis.

In the treatment of lupus some attention has been given to its treatment by thyroid extract. Byrom Bramwell [2 Apr.14,'94] tried it in two cases. In the first, a girl aged 16½ years, whose disease had persisted for nine years, covering the nose, left cheek, and upper

lip, and extending from each corner of the mouth to the chin, administration of the extract was continued, with a few intervals, from February 13th to July 28th. At the latter date the improvement was marked. In an intermission the disease retrograded, but improved again on the resumption of the thyroid treatment. After a year the patient was much improved, not cured. The second was a girl, aged 18 years, whose nose, mouth, and right eyelid were affected. Noticeable improvement was made within a month. Abraham [697, Aug., '94] records a case of apparent improvement.

Schütz [45, Feb. 1, '94; 2, Jan., '95] treats lupus vulgaris as follows: After the administration of chloroform all the friable tissue is scraped away with the sharp spoon; then the floor of the wound and the borders, to a distance of one centimetre, are scarified. When the bleeding has been stopped the wound is dabbed over several times with a cold saturated alcoholic solution of chloride of zinc, to which a little hydrochloric acid has been added. During the ensuing six hours sharp pain is felt, which may be mitigated by the application of iced compresses. Before twelve hours have passed local swelling comes on, with œdema, more or less pronounced, of the neighboring parts. Compresses of boric acid disperse this in thirty-six hours and cleanse the wound. For four days afterward a dressing of pyrogallic acid (1 in 4) in vaselin is applied three times a day. Then boric-acid compresses, frequently changed, are substituted for this dressing. After five days the dressing of pyrogallic acid in vaselin is again resorted to and continued for four days and followed by boric compresses again for three days; lastly, a final application of pyrogallic acid and vaselin is made for two to three days. Cicatrization is rapidly obtained by the use of iodoform in powder or of boracic acid in vaselin. The duration of treatment is from two and one-half to three months, and an excellent-looking scar is the result. Recurrence may take place at one or two points. If so, the nodules must be scraped away with the sharp spoon and chloride of zinc applied. The author claims that the results of this treatment are more satisfactory than those of any other plan known to him. The treatment is applicable to lupus of the skin. For that of mucous membranes in readily-accessible situations, such as the gums and the uvula, Schütz recommends applications of a watery solution (20 to 30 per cent.) of chloride of zinc.

Martens [586 Nos.13-14,'94] concludes, as the result of personal investigation, that thiosinamin will not cure lupus, but that it is sometimes valuable as an adjuvant to other treatment. Its internal administration is followed by the same results as hypodermatic injections. It is undoubtedly possessed of diuretic properties. W. Van Hoorn [28 June,'94] thinks that it is wise, in most cases, not to commence with the thiosinamin treatment, but to hold it in reserve until local treatment has failed.

Lang [245 Apr.,'94] presented to the Vienna Society of Dermatology a young man on whom he had operated for lupus of the face. The lupous tissue was excised through its whole extent, and the surface almost entirely covered by grafts taken from the thigh. A few days later the parts covered were completely healed, although the grafts were placed on a level some millimetres below the surrounding skin. There was no return in the case and, according to Lang, there need be none if the incision is carried deeply enough. An excellent review of the subject is presented by W. S. Gottheil. [451 Oct.,'94]

Nævi.—Reboul [360 May,Oct.,'93; 2 Oct.21] says that, as nævi are congenital in their origin, they may give rise to the formation of a variety of benign and malignant tumors. In quite a considerable number of cases they disappear spontaneously after birth, but in others they remain apparently stationary, and then they must be carefully watched so as to detect any changes which may take place in them. Whenever the least sign of extension, transformation, or malignant degeneration appears, it is necessary at once to adopt active measures, and to remove them freely. When they undergo malignant degeneration, especially of the melanotic variety, they must be regarded as infectious, and in the performance of operations for their removal every precaution must be taken which will tend to prevent a local infection, which may become the point of commencement of a generalization of the growth, and hence lead to a fatal termination.

Pityriasis Rubra Pilaris.—White [245 Nov.,Dec.,'94] records an instance of pityriasis rubra pilaris occurring in a female of 27 years, in whom the face and neck showed uniform, diffused hyperæmia, infiltration, and desquamation. Over the remaining affected portions of the body there were discrete, firm, horny, hemispherical or conical papules, which varied in size from the head of a small

pin to that of a large upholsterer's tack. In color these lesions were slightly redder than the general tint.

E. Bodin [31 No.68,'93; 2 Dec.30] says that the indications in the treatment of pityriasis versicolor are to destroy the fungus and to prevent recurrence. The former is easy, inasmuch as the fungus is confined to the epidermis. If the patches are not too numerous or too large, it is sufficient to paint them two or three times with tincture of iodine, afterward washing the parts with soap so as to remove the epidermis containing the fungus. When the disease is extensive, it can be cured in eight to ten days in the following manner: In the morning the parts should be washed with soft soap and hot water. In the evening the following ointment should be applied: ℞ Resorcini, acid. salicylic., āā 1.0; sulph. præcipit., 5.0; lanolini, vaselini, sebi, āā 25 parts. In such cases sulphur-baths are also of great service. Prevention of recurrence can be secured only by thorough disinfection of the clothes which are in direct contact with the skin; these should be washed with very hot water and soap, or, better still, they should be exposed to the action of steam.

Prurigo.—R. Hatschek, of Vienna, [45 p.981,'93; 697 Mar.,'94] reports the result of 11 cases treated after the method described by Murray [370 '89]; 7 of these belonged to prurigo agria and 4 to prurigo mitis. The proceeding consists of simply rubbing the affected area, beginning at the peripheral end of the extremities and rubbing toward the centre. The time required for one treatment, during the first few days, is from ten to fifteen minutes. As improvement takes place this may be reduced to from five to three minutes. In all cases this treatment was followed by prompt relief of the troublesome itching and a visible improvement in the infiltration of the skin In some cases there was a return of the small papules, which, however, disappeared promptly after the vigorous use of massage. Two to three weeks seemed to be sufficient to produce a complete disappearance of the disease; while an occasional use of massage seemed sufficient to prevent a return. In cases in which eczema formed a complication massage appeared to act as an aid in its cure.

Psoriasis.—M. K. Zartmann, of Copenhagen, [373 No.36,'93] observed, during a long period, a patient who shared his bed with another man many years affected with psoriasis. Three weeks later he

suffered from an acute eruption of psoriasis, which disappeared almost entirely with the use of warm baths. Hölscher [28 B.17,E.] describes four cases in which a coincidence between psoriasis and asthma occurred. Sometimes the asthmatic attack preceded the psoriasis, disappearing with the development of the skin eruption; sometimes it appeared with the outbreak of psoriasis and ceased as the eruption faded.

Byrom Bramwell [2 Oct.26,'92] was led to try thyroid extract in the treatment of psoriasis after observing the definite effects of the remedy on the nutrition of the skin in cases of myxœdema and sporadic cretinism. He regards the results as warranting further trial. John Gordon [2 Jan.27,'94] tried the agent in a case of what he calls syphilitic psoriasis, but which was probably a papulo-squamous syphilide, occurring over the whole surface of the body, including the palms and soles. After five weeks' treatment by mercury and arsenic there was considerable improvement, but this line was stopped and the patient placed on thyroid. In three weeks the disease had disappeared, leaving only the usual pigmentation, but, as the author takes occasion to remark, doubt remains as to whether the gland-extract exercises any controlling influence over the cutaneous manifestations of syphilis. Ménau [188 June 10,'94] records four cases of psoriasis treated by thyroid extract, in the form of pastilles of identical composition with those employed by English observers, giving two daily,—equivalent to one thyroid gland; one of the patients took thyroid gland daily. In none of the cases did any improvement result from the use of the medicament. The ingestion of a thyroid gland in one case produced a febrile condition, nausea, and diarrhœa, without any manifestation of acute dermatitis. Cantrell [80 Sept.,'94] used desiccated thyroids in the treatment of 3 cases, 1 of which was cured in about two months. The remaining 2 were benefited only to a slight extent. The dose ranged from 3 to 15 grains (0.2 to 1 gramme) three times a day.

Jonathan Hutchinson [806 Oct.,'92] lays down the following rules to guide in the treatment of psoriasis: "In all cases alcoholic stimulants should be forbidden. Those who persist in intemperance are incurable. An ointment containing chrysophanic acid, creasote, liquor carbonis, and ammonio-chloride of mercury, varying in proportion according to the delicacy of the skin, is by far the most

efficient means of treatment. It must be used very freely, without regard to the underclothing or bed-linen. The regular use of a hot bath softens the skin and prepares it to receive the ointment. The addition to the bath of liquor carbonis detergens or of the carbonate of soda, or both, in the proportion of a drachm to the gallon, very much increases its efficiency. Although arsenic exercises a specific influence over psoriasis and is in many cases the best internal remedy, there are yet many cases in which it is better to avoid it. This is generally true in most cases in which the patient has taken it often and for long periods. Tartarized antimony in small doses will be often found useful in cases not suitable for arsenic."

Gamberini and Mouari [245 May,'94] claim to have cured psoriasis in twenty days by frictions with a liniment composed of sodium ethylate, 20 grammes (5 drachms); olive-oil, 80 grammes (2½ ounces).

Bayet [219 Sept.,'93] finds that gallanol (anilide of gallic acid), first recommended by Cazeneuve and Rollet, [211 Apr.9,'93] has a real effect on psoriasis, that it does not stain linen, and can be applied to the head and face. Its action, however, is decidedly weaker than that of chrysarobin. It is a reducing agent more powerful than beta-naphthol. Gonnon [2071 '93] finds that it is most effective in cases of moderate severity, especially when the scalp, the face, or the neck is the seat of the disease. It is best used in the form of a pomade or mixed with traumaticin. In old, obstinate cases gallanol acts less rapidly than chrysarobin, but it is free from the drawbacks which attend the use of that drug.

Psorospermosis Follicularis Vegetans (*Darier's Disease*).—The essential feature of this disease consists in blackish, horny excrescences, occurring separately and also in masses; in the latter case a plateau of large size results. A considerable area of the body-surface may be involved. Darier and others believe that the affection is caused by psorosperms, which he divides into two main groups,—*corps ronds* and *grains*. Petersen's observations [50 Oct.16,'93; 2 Dec.9] lead him to reject this theory on the following grounds: 1. Transitional forms are to be found between the bodies in question and the cells of the epidermis. 2. They occur but seldom between the cells, and their presence in this position is explicable on purely mechanical grounds. 3. The thick, highly-

refractive membrane inclosing each body is due merely to the premature keratization of the margin of the epithelial cell of the rete mucosum, out of which the structure in question is developed. Its presence forms no argument for the parasitic nature of the latter. These statements are directly opposed to the three principal reasons adduced by Darier in support of his view that the bodies under consideration are parasitic. In addition, Petersen supports his contention by the following arguments: 4. Identical or similar bodies occur in other examples of keratosis, in which their origin from epidermal cells is even clearer. 5. They contain, in certain developmental stages, keratohyalin and eleidin,—substances not found, as far as he is aware, in psorosperms. 6. Culture and inoculation experiments with the bodies have failed. For these reasons Petersen concludes that the *corps ronds* and *grains* cannot be looked upon as parasites, but merely as degenerated forms of epidermal cells. J. Fabry $_{\text{Feb.,'94}}^{45}$ records a typical case of Darier's disease,—the fourth recorded in Germany.

Purpura.—A case of infectious purpura is recorded by Lebreton. $_{\text{Nov.8,'94;}}^{81}$ $_{\text{Oct.}}^{451}$ The patient was a girl, 18 years of age, a child's nurse, who, forty-eight hours after violent emotion, suffered from severe headache and backache, chills, fever, and repeated epistaxis. After twelve hours confluent purpuric spots appeared on the arms, hands, thighs, and the gluteal region. The eruption on the body was discrete. Subcutaneous injection of ether and caffeine and inhalations of oxygen were given to prevent the syncope, which caused grave apprehensions. The spleen was enlarged and the surface of the body was cold. After some days the alarming symptoms gradually subsided and the patient recovered. Cultures made from the blood and urine showed numerous colonies of the staphylococcus pyogenes albus. The seat of invasion of the microbe was unknown. No furuncle, impetigo, angina, nor other suppurating affection was found in the family. In the discussion Gridal mentioned the organisms that have been found in infectious purpura, and suggested that they may all be secondary to some primary lesion. Mathieu spoke of the difficulty of diagnosing infectious purpura from hæmorrhagic variola, but believes that in the absence of bacteriological investigation this case would be considered as of neuropathic origin.

I. M. Snow, of Buffalo, $_{\text{Aug.,'94}}^{51}$ reports a case of purpura hæmor-

rhagica complicating lobar pneumonia in a girl-baby. He describes the purpuric spots as small, livid blotches, appearing on the abdomen, above the umbilicus, and thence spreading rapidly, covering the whole anterior portion of the trunk in the course of two days. There was an erythematous discoloration of the back. At first the child suffered from chronic indigestion and bronchitis, and during the purpuric outbreak developed an acute attack of vomiting and diarrhœa. The temperature was 97° F. (36.1° C.). Death occurred in eleven days. The autopsy showed an enlarged and fatty liver and lobar pneumonia of the upper right lung, but no visceral hæmorrhages. The author is inclined to the view that purpura is an acute infection caused by the pneumococcus or by secondary infection.

Vierhuff, [21 Nov. '96] from a case seen by him, believes that purpura hæmorrhagica may lead to intussusception. Sansom [6 June 2, '96] has successfully treated the disease by sulphocarbolate of sodium in ½-drachm (2 grammes) doses every four hours for a protracted period.

Scleroderma.—At the January meeting of the Berlin Dermatological Society, Schutte [287 May, '96] showed a patient affected with scleroderma, who had been treated by prolonged salt-water baths and massage, with salicylic vaselin, at first 2 and eventually 10 per cent. The patient then had the full use of his limbs and was able to work. During the application of the salve the urine was found to contain salicylic acid, but no albumin. A woman similarly treated by Lassar a year before had remained well. After a faithful trial of arsenic without appreciable results, du Rocher, by the local use of the static form of electricity, obtained [245 Apr., '96] from a modified Leyden-jar apparatus, secured the complete disappearance of a plaque of scleroderma covering one-half the dorsal surface of the foot. The discharge is made at the point desired in the form of a shower of little sparks over a limited surface, thus preventing the production of pain or discomfort.

Tinea.—Since the publication of Sabouraud's work [2157 '96] there seems to be a pause in the constantly-increasing evolution of knowledge regarding the tinea which has been going on for some years. Moreover, the very basis of his work had been controlled and confirmed by various authors, both in France and elsewhere. Among important articles on the subject may be mentioned those

of Beclère [287 June, '94] and Wickham. [287 June, '94] The latter writer, in a thorough *résumé* of the subject, [697 Oct., '94] states that the ancient tinea tonsurans is differentiated into two separate classes, as distinct one from the other as tinea tonsurans is, for example, from favus. These two classes are: 1. Tinea of Gruby and Sabouraud, or common tinea; tinea with small spores, which is due to the *Microsporon audouini.* 2. Tricophytic tinea, or tinea with large spores, which is due to the divers forms of *Tricophyton megalosporon.* The former class exists only on the scalp and exclusively in children; it is rebellious to treatment and is essentially a human parasite except as regards the "common contagious herpes" of chickens. The small size of the spores, the absence of mycelium, and their circumpilar position are three distinctive characteristics of this form of tinea, while the development of the parasite in the hairs takes place from above downward. The second class includes two distinct types due to (*a*) *Tricophyton megalosporon endothrix* and (*b*) *Tricophyton megalosporon ectothrix.* (*a*) Tinea due to tricophyton megalosporon endothrix exists only on the scalp of children and rarely of adults; it determines in the neighborhood (neck, face) transitory lesions which do not constitute veritable herpes circinatus. Only two varieties of this tinea are known: (1) due to tricophyton with resistant mycelium, and (2) due to mycelium with fragile mycelium. The great size of the spores, the presence of the mycelial threads in bands, the resistance of the mycelium, and its intra-pilar situation constitute the distinctive characters of the first type, and the large size of the spores, the presence of mycelial threads in chaplets, the fragility of the mycelium, and their intra-pilar situation, the distinctive characters of the second.

Tinea due to tricophyton megalosporon ectothrix gives rise to tinea of the skin (herpes circinatus), tinea of the beard (sycosis), kerion celsi, agminate perifolliculitis, etc. It is an animal tinea —*i.e.*, the parasite lives on animals—and is communicated to man accidentally. This is not one single tinea, but a very large number of different varieties of tricophyton which occur specially on one animal or another. This group is far from being definitely elucidated. Twenty different sorts are suspected up to date; five or six are well defined, as, for instance, the tricophyton with white pyogenic cultures in the horse, the cat, the calf, and in birds.

These tricophytons give rise to pus in which there is no staphylococcus nor streptococcus, etc., but only the tricophyton, which can be obtained in the pure state by sowing the pus on agar. The commonest of these tineæ is that caused by the tricophyton with white cultivations of the horse; this it is which almost always produces tinea of the beard. The group has characters in common. When hairs are attacked they break off short, and become denuded of their aërial sheath, but surrounded by a very visible sheath in their radicular portion. The spores are more or less large; mycelium is very distinct; the situation is around the hair,—circumpilar; there are no intra-pilar parasites.

Leslie Roberts $_{\text{Sept.29,'94}}^{2}$ criticises the efforts of Sabouraud to decide the pleurality of species of the hair-parasites, pointing out that it is absurd to endeavor to distinguish species by differences in the mycelium, and that the appearance of cultivated vegetations can be altered by changes in temperature. He describes what he calls the physiological method of research. The fungus to be studied is cultivated in a sterilized, shallow, glass dish containing a 10-per-cent. solution of best English malt. When a fair-sized vegetation has formed on the surface the hair is introduced, and the dish replaced in the incubator.

The infusion of malt represents a piece of inanimate nature, supporting the fungus, after the manner of a saprophyte. The hair represents the man or animal which comes in contact with the saprophyte, and in due time the hair is invaded.

This, Roberts considers, points to a source of ringworm and other vegetable parasite disease hitherto scarcely suspected, viz., dead organic matter, and that the hair-attacking fungi belong essentially to the saprophytes, but to that class of saprophytes which may under certain conditions adopt the parasitic life; that, although the connecting link between the lowest parasitic position and the saprophytic habitat of these fungi is still missing, the very simple conditions under which germination and mycelium of formation may occur, and the fact that Roberts has observed tricophyton and the common saprophyte, blue mold, growing side by side, in open spring-water cultures, support the theory. He shows that the soil and the mode in which the fungus attacks its host have a considerable share in producing microscopical variations. According to Sabouraud, when tricophyton megalosporon of human

origin attacks scalp-hair, its vegetations are confined to the interior of the hair-shaft, the sheath of the shaft remaining intact. Roberts took a hair invaded by the fungus, and made from it a pure cultivation. He then laid a piece of healthy scalp-hair and beard-hair on the aërial surface. After a week both hairs were examined, and found to be thoroughly pervaded by the fungus and the sheath utterly corroded. This, he believes, teaches that, when the fungus ascends to its position in the hair from dead organic matter, it may vegetate outside the sheath, and that the formation of ectothrix or endothrix vegetations does not suffice to distinguish one kind of megalosporon from another. The ectothrix vegetation has been frequently found, when it is highly probable, if not certain, that the origin of the disease has been directly from one of the domesticated animals. The ectothrix vegetation may, therefore, be taken to suggest direct animal origin, but by no means to prove it. Sabouraud also endeavors to prove that distinct forms of disease are associated with the several varieties of hair-fungus, but Roberts considers that, although there is a tendency in like hair-fungi to produce like lesions, still there is no invariable rule, and that the symptoms will be found to vary with the character of the hair and the mode in which it is attacked.

Macfadyen $_{\text{Sept. 22, '94}}^{2}$ has investigated the tricophyton tonsurans with the object of determining whether it produces ferments, and, if so, what their nature is. His results, briefly summarized, are as follow: 1. The ringworm organism produces a proteolytic enzyme which liquefies gelatin very rapidly. 2. This enzyme is capable of acting even when greatly diluted, and is very stable, as its action can be demonstrated in cultures three months old. 3. This enzyme acts most rapidly and energetically at or near blood-heat. At blood-heat a complete liquefaction of 10 per cent. gelatin was produced in fifteen to seventeen hours. 4. Exposure to a temperature of 100° C. (212° F.) for two minutes destroys the ferment. 5. The proteolytic enzyme is also produced in simple beef-broth; acidity hinders and alkalinity favors its production. 6. The gelatin containing the active enzyme does not exert any inimical action upon the staphylococcus pyogenes aureus or the bacillus pyocyaneus. 7. The formation of a diastasic ferment by the ringworm organism is not demonstrated, but it grows well in solutions of grape-sugar and milk-sugar. 8. A slight growth was

obtained on cane-sugar soils, and evidence obtained of the presence of a feeble inverting ferment. 9. A milk-curdling ferment is not produced by the tricophyton. 10. The best soil for its growth was Sabouraud's beerwort-agar, consisting of beerwort with the addition of 1.5 per cent. of agar. 11. It may be that the proteolytic enzyme aids the organism in softening the tissues and overcoming their resistance to the penetration of the hyphæ. It would be interesting in this connection to test the action of the enzyme on keratin, and experiments are being at present carried out in this direction.

Biro, $^{520}_{\text{No.27,'93}}$; $^{673}_{\text{May,'94}}$ after numerous and very careful investigations and experiments (as, for instance, the cultivation of bacteria on various soils, the investigation of the development of the bacteria of favus and its inoculations in men), arrives at the following conclusions: 1. That the parasite of favus, cultivated on various artificial media, manifests itself differently. 2. That cultures, apparently differing at first, after a certain series of cultures on the same soil, begin to resemble each other in appearance. 3. That there is a certain dependence between the appearance of the bacterium of favus and the soil on which it is cultivated, and that the bacterium accommodates itself to the soil. 4. In view of these facts there is no certainty that former writers had not met with one and the same bacterium, and that no proofs exist that there is more than one variety of bacteria in favus.

P. T. Thomson, of the Policlinique Saint-Jean at Brussels, $^{219}_{\text{Jan.25,'94}}$; $^{697}_{\text{May}}$ stimulated by Feulard's observations, has investigated the records of the military services in Belgium, and finds that during the years 1888 to 1892 there were exempted from military service 3.03 per 1000 on account of teigne, which here probably may be taken as synonymous with favus. The proportion of exemptions varied enormously in the different provinces; for example, 4.20 per 1000 in West Flanders, 1.90 per 1000 in Luxembourg. The affection is met with very rarely in the east part of Belgium, and comparatively frequently in the north part bordering on Holland, and in the central part. With the exception of the arrondissements of Nivelles, Charleroi, and Liége, the great frequency of exemptions on account of leigne comes from the Flemish part of the country. The mountainous and at the same time less-peopled parts (Liége, Luxembourg, and Namur) seem to be free.

Tylosis Palmae et Plantae (Crocker)

British Journal of Dermatology

The affection is also less frequent along the sea-board. The arrondissements comprising the great centres (Brussels, Antwerp, Liége, and Ghent, and the coal-district of Charleroi) are those whence come the greater part of the cases. Thomson also finds that, notwithstanding these exemptions of recruits, favus is met with in the Belgian Army in the proportion of 0.15 per 1000 men in the service. Cantrell and Stout [245 Sept.,'94] report a case in an Italian boy of 10 years, the disease first beginning upon the scalp during the voyage to the United States, the body showing the same condition nineteen months later. Numerous portions of the trunk and extremities were covered with the characteristic yellow mortar-like crust.

Guladre [571 No.5,'94] gives the following directions for the treatment of the disease: Shave the head, wash for the first five days with green soap, and on the sixth day apply a compress soaked in thymol, 1 part; chloroform, 8 parts; olive-oil, 36 parts. Keep this in position with a bandage, applying a fresh compress three times daily. When the softened particles drop off, remove the hairs and rub with the mixture, replacing it in three or four weeks with iodine, 2 parts; glycerin, 1 part. Use daily for one week.

Tylosis.—Crocker [697 V.2,No.22] records two cases of tylosis of the palms and soles in which it was thought that the hyperidrosis aided in its production, and also that family predisposition, as thought by Hutchinson, seemed to have an influence. The second case referred to was witnessed through the fifth generation. Crocker advises that the parts be soaked with hot-water compresses and followed by the application of resorcin or of a salicylic-acid plaster (20 per cent.), believing that if this treatment is persevered in the result will be ultimately successful.

Ulcers.—E. Diver [22 May 30,'94] read a paper on the use of chlorine-gas in the treatment of chronic ulcers of the leg. The gas was formed by pouring about 2 drachms (8 grammes) of potassium chlorate and 1 drachm (4 grammes) or more of HCl into a pickle- or marmalade- jar the outside of which was covered by brown paper. After this a disc of white paper was introduced, and on top of the paper sufficient absorbent wool; a large cork was then fitted to the neck of the jar. The wool, yellowish-green on the surface, was first exposed to view, was placed over the ulcer, and quickly covered by gutta-percha tissue, and ordinary bandages

applied. No rest was enjoined. The gas was probably chiefly Cl with some peroxide of Cl in mixture. One patient had, on commencing treatment, a varicose ulcer on each leg, between the calf and the ankle. Both steadily improved under treatment, and the left was well within eight weeks, the dressing having been applied three times weekly. This leg had never been healed for twenty-five years, and at the time of commencing treatment the ulcer was over two inches long by nearly two inches broad. The healing of the second ulcer was impeded by an accident and by several other circumstances. Another patient had a large, deep, annular ulcer, which originated from a cat-bite some twenty years ago. Its boundaries were from a little above the ankle to near the middle of the calf. It was treated in exactly the same way, and soon its ashy surface showed granulations, which went on increasing until the level of the skin was reached after six weeks' treatment. It has since steadily improved. The author had observed that chlorine-gas increased in an extraordinary manner the germinating power of poor samples of barley, and this fact induced him to employ it as a local stimulant.

BOSTON MEDICAL LIBRARY ASSN. AUG 28 1895

Marquant $_{\text{Aug.24,'94}}^{3}$ reports good results from the use of franklinization in chronic ulcers of the leg. The method employed is as follows: The sore is first washed with an antiseptic solution and then covered with absorbent cotton. The patient is placed upon the insulated seat and connected with the negative pole of an electro-static machine. The electrode is then brought near enough to the sore to produce the electric *souffle*, while, at the same time, it is kept far enough away to prevent the passage of a spark. The effluvation is continued for ten minutes, and the sittings are given three times a week. After the treatment the ulcer is dressed with a layer of absorbent cotton. All cases where the ulcers depended on the varicose condition of the veins, uncomplicated by other troubles, improved rapidly; where other debilitating factors were present the cure was less rapid. In many of these latter cases, however, other means had been first tried and had failed.

Kirsch, $_{\text{Sept.,'93}}^{116}$; $_{\text{Nov.18}}^{2}$ in cases of varicose ulcer where absolute rest is impracticable, achieves good results by bandaging in the following manner: If the ulcer be deep it is filled with iodoform gauze to the level of the surrounding skin, the edges and borders are

dusted with dermatol, and the whole is covered with an absorbent compress. Over this is placed a sufficiently-large sponge with a flat under-surface, the sponge having been previously allowed to swell in warm water, and applied moist, but not too wet. When, however, the ulcer is flat, an hydropathic covering is applied to the surface direct. In either case the limb is then surrounded, from the toes to the knee, with a moderately-tight non-elastic binding, the sponge being included in the bandage. In the course of one or two days the sponge will be found to have imbedded itself in the ulcer, and, with continued treatment, the œdema will diminish and disappear, while the edges will be found soft and flattened and the ulcer in a granulating condition. At this period an ointment can be applied, but the sponge-compression should be persevered with, even after the ulcer appears to be healed. When the edges are abnormally hard and rigid the author has found massage very useful, the application being by means of a specially-constructed roller. Should the ulcer be too sensitive to allow of immediate compression the author envelops the limb to as high a limit as possible, again commencing, where possible, above the tender area. The œdema will thus gradually be pressed toward the ulcer and disappear, and, at the same time, successive bandages will allow of greater approximation to the ulcer until the whole of it can be included in the bandage as described. The author has convinced himself of the efficiency of this treatment in a large number of cases of varicose ulcers, the principal advantage being the ability of the patients to follow their ordinary avocations. His successful cases included ulcers which for years had resisted all treatment.

Urticaria.—The physiology of the urticarial lesion forms the opening consideration of a paper by Stephen Mackenzie.[697 No. 3, '94] The development of a wheal is a process determined by a reflex mechanism set in motion by two sets of stimuli. Here, as elsewhere, the mechanism must consist of afferent nerves, a centre and afferent nerves, the centre being located in the plexus of fine fibres ramified through the superficial layers of the corium. The stimuli which awaken the activity of this system are direct or indirect; they are external irritants applied directly to the surface of the skin,—*e.g.*, changes of temperature, nettles,—or they arise from the ingestion of certain substances endowed with toxic properties.

In the latter case some poisonous product of faulty digestion is absorbed into the blood and irritates, by its chemical action, the superficial plexus. The ultimate cause is then, in the writer's opinion, the same in both cases,—stimulation of this centre; and the fact of the general distribution of urticaria is, he thinks, an evidence of the correctness of the theory. He refers to the occurrence of urticarial wheals on the mucous membranes of the mouth, air-passages (its alternation with the phenomena of asthma), and stomach, as well as to the more unfamiliar causes, as the presence of hydatids. Urticaria has been produced by Debove $_{\text{v.1,p.24,'88}}^{6}$ by the injection of hydatid fluid under the skin, and the author gives a case in which an outbreak followed the rupture of a cyst in the abdomen. It may occur independently of any poison, following parturition or the passage of a uterine sound, or may be coincident with menstruation and pregnancy. Stewart Abram $_{\text{May 12,'94}}^{6}$ observed a rare case due to santonin given for thread-worms.

Dubreuilh $_{\text{Apr.,'94}}^{25}$ points out the resemblance between the "urticaria of infants" (Colcott Fox $^{697}_{\text{'90}}$) and "prurigo simplex acutus" of adults (Brocq $^{287}_{\text{'94}}$). In each the elementary lesion—the recent papule—is the same. The distribution of the lesion, the appearance of fresh crops during the night, and its greater frequency in summer are the same in each. The pathological anatomy of the lesion has been shown by Darier to be identical in both. Dubreuilh objects to the terms "urticaria" and "prurigo" as applied to this disease, and proposes to class the adult and infantile forms together under the old name of "strophulus."

Billstein $_{\text{Sept.15,'94}}^{9}$ records a case of urticaria in which glycosuria was a marked symptom. The patient had been healthy up to 2 years of age, when, after an attack of measles, he became delicate. At the age of 7 years he had an attack of urticaria which had become chronic, and it was found that glycosuria was a complication. Heat and cold seemed to be the exciting influences, the boy being able to digest all kinds of food without producing an attack. Scanga $_{\text{No.12,'96}}^{589}$ observed a case of urticaria in a nervous student, characterized by unusually-violent pruritus. The wheals appeared rapidly and disappeared as quickly. The skin was extraordinarily hyperæsthetic, and showed to an unusual degree the phenomena of dermographism. The writer believes that an irritable condition of the vasomotor nerves was present. The

patient was successfully treated by means of the galvanic current and the internal administration of strychnine.

Xanthoma.—H. Hallopeau [287 No. 8, '93; 245 May, '94] presents the following conclusions as to the nature of xanthomata and the proximate causes of their complications: 1. Xanthomata are benign neoplasms of embryonic origin,—*i.e.*, nævi, according to the newly formulated conception of these tumors. 2. They may be localized, as Koebner has shown, in a region occupied by a nævus. 3. They may form long bands following the course of nerves,—a characteristic disposition of nævi. 4. They are due, conformably to the views of Touton, to the persistence in the tissues and the proliferation of embryonic cells, capable of fat formation. 5. They may secondarily become the seat of exudation, hyperæmia, or hæmorrhage. 6. Tumors of the limbs, being very vascular, may be effaced to the point of becoming almost unrecognizable. 7. The icterus which accompanies xanthoma is due, according to Kaposi, to their extension to the biliary passages. 8. The glycosuria which in a number of cases has coincided with it, is due, from analogy, to another visceral localization of the lesions; the pancreas is the probable site. (The author regards the xanthoma as the primitive process.) 9. This visceral localization is especially observed when the xanthoma occupies the body in the form of punctate tuberosities. 10. The existence of macules in the neighborhood of tumors shows that they are susceptible of undergoing retrograde evolution; this fact and also the possibility of change of size according to the degree of repletion of the vascular system explains the intermittences of icterus and glycosuria with which the disease may be accompanied.

W. Dale James [2 Oct. 13, '94] describes a case of congenital xanthoma multiplex in a female child aged 3½ years. The plaques were situated on the right upper eyelid, right side of nose, over the mesial line of the upper lip, the lower end of the breast-bone, right subclavian region, at the back on the right side of the dorsal vertebræ, and on the left lumbar region. There were in addition five on the scalp. The mother declared that at birth they were plum color; but when first seen—when the child was 18 months old—they consisted of sharply-elevated masses of a pale-flesh color, having a few vessels running over the surface. No microscopical examination has been made. The mother stated that the

places grew during two years, but had not increased since. During the time the child was under the care of the author the plaques on the scalp varied in fullness from time to time, but have now undergone involution. They are not raised; they have the appearance of yellow, hairless scars, and the skin feels thin and atrophic. The plaques on the face are also less prominent, both as to elevation and color. In all respects the child is in good health.

Crocker [697 V.4,No.46] records an interesting case of xanthoma diabeticorum, the lesions of which were situated upon the buttocks, front of the arm, and on the elbows and knees. The case is clinically important as a guide to a possibly unsuspected glycosuria. The urine was found to contain about 18 grains (1.17 grammes) of sugar to the ounce (31 grammes).

MISCELLANEOUS.

The Blood in Skin Diseases.—Henocque [28 B.16,p.182] has devised an hæmatospectroscope for the estimation of the oxyhæmoglobin of the blood through the skin and mucous membrane. It consists of an ordinary spectroscope with a movable diaphragm in front of the slit and colored methodically-shaded glasses analyzing the normal oxyhæmoglobin bands of the skin, nails, etc. The oxyhæmoglobin, hyperæmia, vascularization, and intensity of the blood-stasis can be estimated by the thickness of the glass required.

Influence of Baths upon the Number of Microbes in the Skin.—G. Markow [586 No.12,'94] examined fifty-one hospital patients as to the proportion of micrococci to be found in the skin before and after bathing. The maximum of bacteria found upon the abdominal surface before bathing was 12,475 to the square centimetre; the minimum 12. On the back the maximum was 4836 and the minimum 15. On the inner surface of the thigh the maximum was 11,586, the minimum 10. The greatest number were observed in patients with rough, hairy, and sweaty skin, and in those who had used Roman baths for a long time without subsequent bathing in fresh water. He therefore urges that ablutions of fresh water be insisted upon after Roman baths.

OPHTHALMOLOGY.

By CHARLES A. OLIVER, A.M., M.D.,

ASSISTED BY

WILLIAM CAMPBELL POSEY, A.B., M.D.,

PHILADELPHIA.

SECTION I.

CONGENITAL ANOMALIES, EMBRYOLOGY, AND HISTOLOGICAL ANATOMY.

A CASE of *congenital anophthalmos* has been observed by Ramage, [2 Mar. 31, '94] in which the right eye was represented by a small stump of apparently fibrous tissue, which moved in harmony with the left eye. All the appendages of both eyes were normal. As the result of careful dissection of the head of a *Phasianus Colchicus* with no external ocular appendages, Gillet de Grandmont, of Paris, [274 Dec., '93] has discovered eyes possessing the rudiments of each of their constituent organs. There was no trace of an orbital cavity or of a conjunctival sac.

Becker, of Marburg, [254 Dec., '93] has made an histological examination in a case of *microcephalus* and *palpebral cyst.* The latter was the size of a pigeon's egg, and communicated directly with the globes by means of a fissure two to three millimetres wide. There were slight pathological changes in the cornea, lens, retina, and optic nerve. The lens was partially cataractous and far too large in proportion to the rest of the tissues. There was no trace of the zone of Zinn. The anterior chamber was very narrow and, like the vitreous, was absent in a number of the sections. The ciliary processes were very large and not radiated. The remains of the pupillary membrane were visible, whilst there was corectopia and want of development of the sphincter of the iris. The retina did not hold its natural relationship to the optic nerve, but was folded into many layers in an ectasic portion of the sclera, superior to the cornea. The fissure in the posterior wall of the globe lay directly below the optic nerve, and the retina was continued through it as a fibrous tissue rich in cells, with which the pigment-layer of the retina was associated, and which, in the form of cylindrical cells

with long processes, lined the walls of the cyst. The external wall of the cyst was continuous with the sclera, and consisted of fibrillary connective tissue with some connective-tissue cells. The author believed the internal layer of the cyst to be the retina, the condition having originated late in fœtal life, as all the ocular tissues had been developed save the zone of Zinn. Mitvalsky's theory would explain the cause of the deformity, the separation of the retina from the optic nerve being due to the fact that the lens had only caused a partial invagination of the distal layer of the primary optic vesicle, and that that particular part of the layer near the optic nerve was not acted upon, being left to grow in the encompassing mesoderm, and there gradually developing into a cyst.

Bernheimer, of Vienna, [251 Apr., '94] has studied histologically the eyes of a case of microcephalus, the details of which were given by Virchow. [2034 '93] With the exception of their small size, the eyes were well developed in the anterior segments. There was a lack of development in the iris and ciliary body of the left eye, which the author thinks was due to a slight colobomatous formation. In the right eye there were the remains of the pupillary membrane. The lenses in both were partially cataractous. There was a small prominence on the posterior pole of the left lens, entirely covered by capsule and connected with the lens by a slender pedicle. Not far from the insertion of this pedicle there was a distinct tear in the capsule, and through this the lenticular substance had protruded in the form of two large drops and a long, flat process, which was situated on the posterior portion of the lens. Between these there was a fold of retina which contained the vessels, pigment, and remains of the vascular capsule of the lens. The region of the optic nerve was partially occupied by a large space, the walls of which were lined with a gliomatous tissue. In the right eye the lens was perfectly formed, whilst its posterior surface was covered with changed retinal and capsular tissue. The retina was *in situ* anteriorly, but was detached posteriorly, and with the optic nerve contributed to the formation of the cavity in the nerve. The gliomatous degeneration was also visible in this eye.

Velhagen, of Göttingen, [204 Jan., '94] has made a microscopical examination of the eye of a pig in which, as shown in the accompanying illustration, the optic nerve was absent. With this exception the

external configuration of the eye was perfect. A partially-developed lens was *in situ* and the choroid was also present, though much altered; its capillary layer was but slightly developed, and but few larger arteries and veins were present. The iris and ciliary bodies were also present, the latter being unusually large. Of the retina, however, the pigment-layer was the only one perceptible, for not a trace of its nervous elements could be found. The ciliary processes were unusually large, and were provided with numerous folds. From these latter a tissue was developed which separated the anterior segment of the eye from that bordered by the pigment-layer, in which there were three

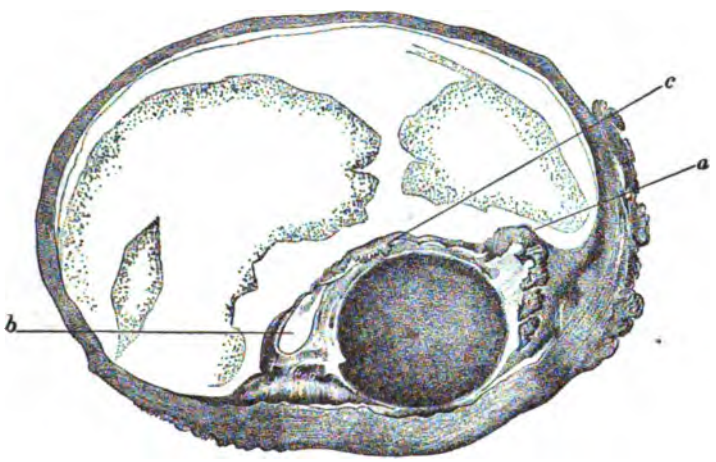

ANOMALY OF EYE IN A PIG. (VELHAGEN.)
Archiv für Ophthalmologie.

distinct types of newly-formed tissue. The first, which was developed out of the first fold in association with the ciliary processes, was composed of numerous spindle-cells, and was rich in blood-vessels and huge lymph-spaces lined with pigmented epithelium. The second consisted of a series of long tubes, especially developed at the posterior portion of the lens, whilst the third was composed of large cells provided with long processes that filled in the spaces left by the tubes. The author regards these tissues as embryonal connective tissue, the first a product of the proliferation of the ciliary processes, the canals being either overgrowths of the epithelial cells of the ciliary processes or of the pigment-layer. He explains the general condition as due to an atrophy of

the anterior wall of the secondary vesicle in direct connection with the new growth of the pigment-cells, and further points out that the newly-formed tissue in the anterior segment of the eye is not independent of the retinal change.

Swasey, of Worcester, 1018 Apr., '94 has seen an instance of *coloboma* of the iris, ciliary body, choroid, and optic-nerve sheath in the left eye of a woman 19 years old. From the microscopical study of a partial coloboma of the upper lid in a deformed fœtus of six to seven months, Hoppe, of Göttingen, 204 v. 39, No. 3 has concluded as follows:

COLOBOMA OF UPPER LID IN A DEFORMED FŒTUS. (HOPPE.)
Archiv für Ophthalmologie.

1. Coloboma of the lid may have more than one mode of origin. 2. In the majority of cases the condition is due to a compression exerted by the amnion upon the bulbus and its adnexa, generally associated with a consecutive growing together of the parts, resulting in a partial hindrance to the proper development of the lids. 3. Certain colobomata of the lower lid may result from a faulty position of the facial fissure. 4. Primary anomalies of the globe, as keratoconus, may cause coloboma of the lid. The accompanying illustration gives an excellent idea of the nature of the deformities and shows the amnion adherent to the head. As an addition to

an article previously reported by him upon a rare family history of coloboma of the iris, de Beck, of Cincinnati, [249 July,'94] states that he has observed two additional cases of this affection in the same family, thus completing the participation of three successive generations,—father, daughter, and grandson. Of unusual interest is the fact that, in a marriage of first-cousins, one of whom had a mother affected with the anomalous condition, none of the four children presented any unusual ocular condition, this generation escaping entirely. The succeeding offspring, however, were affected, the coloboma appearing in the eyes of a male member. In these families the law of descent varied so considerably that it was impossible to formulate any data from their study. A chart is appended which, owing to the fact that the defect showed itself in four generations, although not in line, the author states is unique.

Phillips, of Savannah, [207 Jan.,'94] has seen an instance of *persistent pupillary membrane* associated with atrophy of the choroid and optic nerve. W. J. Collins, of London, [6 p.1496,'94] cites three instances in adults of well-defined opaque plaques in or on the anterior lens-capsule, midway between the equator and the pole, about 1.5 by 0.5 millimetres in size, with a long axis in the median line. He believes that opacities of this kind should be regarded as mere fœtal vestiges, and not as pathological products. An instance of coloboma of the lens in a myopic eye has been observed by Theobald, of Baltimore, [764 Apr.,'94] in a mulatto girl. The notch was in the lower periphery of the lens of the left eye. There were several isolated areas of opacity in the anterior cortex of the lens. Marple, of New York, [2035 Jan.,'94] has observed an instance of double coloboma lentis associated with upward dislocation of the lenses. The patient was highly myopic, but did not present a similar defect in the ocular tissues. The colobomata embraced about a third of the lower half of the lens, and were almost symmetrical.

Carter, of New York, [814 Feb.15,'94] has seen an instance of *congenital symmetrical zonular opacity* around the fovea in a Hebrew infant 19 months of age. The child had grown progressively weaker from the third month, and at short intervals there had been tonic contractions of the muscles of the limbs. Both optic nerves were pallid, and the macular changes resembled those of embolism. An instance of zonular cataract with an associated anterior polar opacity and remains of a pupillary membrane is recorded by Purt-

scher, of Klagenfurt.[190 Feb.,'94] There was a well-developed zonular cataract in the left eye, limited to the temporal half of the lens. The line of separation between the opaque and the clear portion was irregular. No direct communication between the anterior polar opacity and the cataract could be observed. The same condition existed in the left eye, but was less marked. The author thinks that the asymmetry of the process of development in the internal and external halves of the globe is a proof of the dependence of the anomaly upon some fœtal mechanical cause affecting only one lateral part, and points out the importance of Hess's discoveries upon the embryo chick in explanation of similar conditions.

Pinkard, of Chicago,[139 Feb.,'94] has observed *congenital dislocation of the lenses* in two sisters. In both instances the displacement was downward. A case of persistent hyaloid artery and coloboma of the choroid has been reported by Stricker, of Cincinnati.[249 July,'94] The posterior capsule of the lens did not show any evidence of an adherent hyaloid or a posterior capsular cataract.

An instance of *atypical coloboma* in the fundus is recorded by Beckmann, of Kiew,[190 Mar.,'94] who, in a somewhat microphthalmic eye, found two circumscribed ectasia of the sclera, which bordered immediately upon the inner and lower periphery of the nerve-head, and in which the choroid was entirely absent. In the immediate neighborhood of the ectasic areas, as well as the optic disc, there were large heaps of pigment,—a proof of a probable intense inflammatory process in the deeper ocular layers. A high degree of degeneration of the vessel-walls also gave further evidence to a previous pathological process. The author states that these changes must have arisen during fœtal life, and that the pathological condition which hastened the deformity must have occurred shortly after the closure of the fœtal fissure. He regards the ectasia as the result of altered intra-ocular pressure associated with a chronic inflammation of the ocular coats, especially of the sclera. In the other eye there was a deep posterior staphyloma, and the skull showed evidence of asymmetrical growth. From a consideration of these facts, the author is inclined to view the anomaly as the result of a pathological change in the membranes of the brain during the third month of fœtal development. Notes of three cases of coloboma of the optic nerve are given by Mueller, of Hamburg.[353 June,'94] The first two instances occurred in a boy, 18

years old, who was mentally inferior, but did not exhibit any other anomalous conditions. In both fundi, in place of the papillæ, there was a circular disc about one-third larger than the normal. This area was surrounded by a shiny, white, sclerotic ring bordered by broken pigment-masses. The maculæ were difficult to see, and were of a yellowish color, surrounded by a ring of choroidal pigment open toward the disc. In the third instance, a man 53 years old, glaucoma simplex had manifested itself, complicating a coloboma of the nerve on the left side. From a review of the literature on the subject, the writer has grouped his own, as well as reported cases, as follows: 1. Coloboma in which the vessels appear upon the inferior border of the sheath of the nerve. 2. Coloboma where the vessels are seen to arise centrally or near the superior border. 3. Coloboma where the vessels are already separated, but are quite regularly grouped about the centre.

A series of congenital *anomalies of the fundus* have been observed by Mitvalsky, of Prague. [254 Feb.,'94] There were two instances of paramaculary choroidal coloboma with a tubular formation. In the first, in the superior temporal region, about two and one-third to three discs' diameter from the optic-nerve head, there was a peculiar glistening, white formation, covered with pigment-spots. The borders of this coloboma were sharply cut, and the rest of the fundus was apparently normal. This area consisted of two nests, between which there was a tubular formation which projected into the vitreous without showing any fibrous processes. The retinal vessels were distributed anomalously. In the second case there was a partial coloboma down and out. The papilla was incompletely covered by a grayish-white formation which extended up and out, hiding the superior temporal artery and vein, and finally ended in a coloboma of the choroid five to six discs' diameter distant from the disc. From this coloboma a tubular formation projected into the vitreous, on the end of which there was a tent-like, grayish, fibrous covering, which marked the upper half of the coloboma and proceeded toward the equator of the globe. In contradistinction to similar cases already reported, the tubular formations in both of these cases were inserted in the coloboma at an appreciable distance from the disc, whilst the choroidal defect in each instance was above the macula. The cases also depart from the characteristics of this condition described by Hirschberg, by their

irides not showing any color-difference, and by the absence in the first cases of any tent-like covering to the tube. Central scotoma was also wanting, there being only a peripheral contraction of the visual field. In the third case there was a defect of the choroid, with a tent-like fibrous covering of the fundus, associated with an anomaly of the optic nerve. In the situation of the disc, which was not visible, a club-shaped figure ran temporally. In addition there was an extended, white, mother-of-pearl-like, fibrous

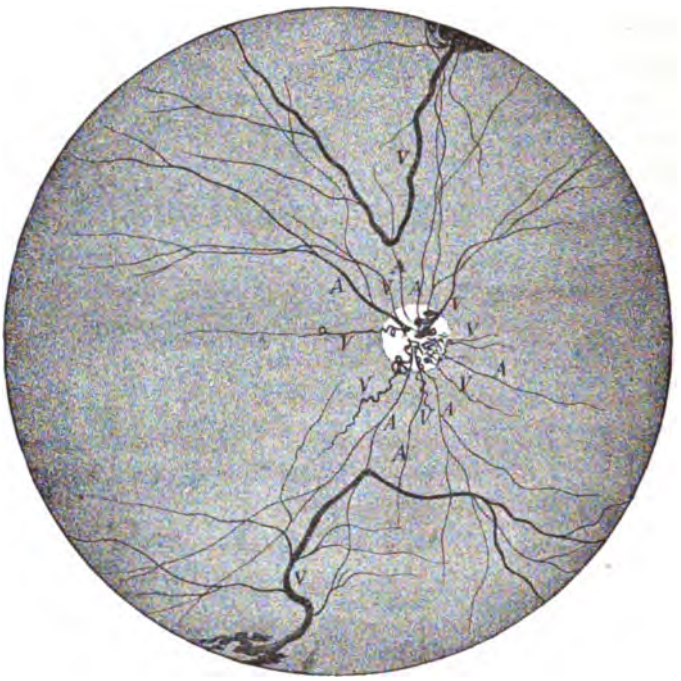

ANOMALY OF RETINAL VEINS. (AXENFELD.)
Klinische Monatsblätter für Augenheilkunde.

streak. The posterior pole of the eye was surrounded by an elliptical strip of black pigment. The author does not doubt that this condition is accounted for by the retina becoming mechanically detached from the choroid by the fibre-layer, from some pathological change in the fœtal connective tissue of the secondary optic vesicle. The fourth case represented a typical example of persistent hyaloid artery, with the clinical appearance of a posterior polar cataract.

Axenfeld, of Marburg, [353 Jan.,'94] describes an interesting *anomaly*

of the retinal veins. The greater part of the venous blood was carried out of the eye by a large superior and inferior cilio-retinal vein at the equator. These veins received numerous branches and became thicker as they reached the periphery, and finally were lost in a heap of chorio-retinal pigment in the neighborhood of the vorticosi veins. The central retinal vein was small and did not anastomose by any of its branches with the foregoing. There was a disseminated choroiditis which the author did not consider to be of moment in the production of the anomaly, as he thinks that the miliary aneurism and dilatation of the retinal vessels that were present point to some gradual obstruction to the circulation of the fœtal eye that was compensated for by the development of these large trunks.

Le Double, of Tours, [274 Apr.,'94] has studied the *variations in the human ocular muscles, lids, and brows*, finding the following varieties in the insertion of the levator palpebræ superioris: Anteriorly, instead of attaching itself only upon the border of the tarsal cartilage, this muscle may insert itself (1) upon the cartilage and the posterior surface of the conjunctiva at the level of the superior *cul-de-sac;* (2) upon the posterior surface of the superior *cul-de-sac;* (3) on the ciliary portion of the orbicularis; (4) into the cartilage upon the posterior surface of the *cul-de-sac* and the ciliary portion of the orbicularis. The author has seen the small oblique increased to the size of the great oblique in an old woman. He has never found the internal and the inferior recti muscles to arise from a common origin. In two instances he has noted an absence of the corrugator supercilii.

Green, of Birmingham, [204 B.40,H.1,'94] has carefully observed the *goblet cells of the conjunctiva*, and has found that these cells exist normally at all ages, and that their primary function is the secretion of mucus. His results are based upon the examination of thirty human eyes, of which two were of the fœtus, two of newly born, and two of somewhat older children.

Wallace, of Philadelphia, [112 Sept.,'94] claims to have recognized *nerve-fibres in the crystalline lens.* He states that sections demonstrate the existence of two white cords in the lens-capsule,—one near its outer surface, appearing to cease at the insertion of the suspensory ligament; the second near the inner surface, giving off fine-twisted strands, some of which reunite and proceed as lens-fibres. Fibres

starting from near the equator "assume a concentric arrangement around the nucleus, while those from near the anterior insertion of the suspensory ligament are at first directed inward; this results in a crowding of the fibres at one point; from here the last-mentioned fibres bend rather sharply outward and terminate in a cord, which runs just below the layer of epithelial cells parallel with this layer and gives off branches which run up between the cells and join the inner cord of capsules." The fibres surrounding the subcapsular cells have a figure-of-eight arrangement, suggesting that a movement of the fibres might cause a passage of the nucleus from one of these spaces to the next.

In a contribution to the *anatomy of the human retina*, with a special consideration of the terminal loops of the rods and cones, Norris and Wallace, of Philadelphia, [112 Mar.,'94] assert that the cones terminate in a looped extremity, which passes down over the body of the cone and, after some convolutions in the position of the so-called external limiting membrane, winds along among the elements of the outer nuclear layer. Mays, of Heidelberg, [204 B.20,H.3] thinks that he has proven the presence of iron in the brown pigment of the retina. Snellen, [2 Sept.15,'94] has made a microscopical study of the dots that were present in two cases of descemetitis. In one they were found to consist of a conglomeration of short bacilli; in the second they were seen to be made up of cells with the same form of bacilli between them. The author concludes that descemetitis is a disease *sui generis*, due to microbes growing in the anterior chamber and inducing irritation of the uveal tract by the toxins that they secrete.

Salzmann, of Vienna, [204 B.20,H.4] has made a microscopical examination of an eye containing *a broad conus* down and in from the disc, enucleated from a 9-year-old girl upon account of a tumor of the optic nerve. An ophthalmoscopical examination of the eye during life had not been feasible, owing to the presence of dense corneal opacities. From the pathological appearance, the papilla was seen to be elliptical in form, and the conus extended down and in from it. The microscope revealed the presence of both layers of the retina in the conus, the inner one being normal in appearance, whilst the outer had not attained its maximum degree of development. The external granular layer was reduced to a line, and in many places was replaced by atypical connective tissue. Numerous spaces

were present, and it was only around these that the three external layers came in contact. At the border of the disc both layers became blended. The transition of the pigment-epithelium was accomplished by the pigment-cells first losing their pigment, then splitting to form several layers, and finally taking on the appearance of the muscular layer. In order to explain the peculiar appearance of the external retinal layer, the author suggests that the retina formed a fold at the site of the conus, whose free end was continuous with the optic nerve, whilst its internal layer formed the normal connection with the fibrous layer. This condition, he thinks, may be regarded as a coloboma of the choroid, arising from a dislocation of the retinal fold, induced by the overgrowth of its inner layer. The external layers of the choroid were unchanged, whilst the absence of the capillary layer and the lamina vitrea was accounted for by the disturbance in development of the pigment-layer of the retina.

SECTION II.

PHYSIOLOGY.

Giese, of Göttingen, $\frac{254}{\text{Apr.,'94}}$ has measured *the temperature in the human conjunctival sac* by means of a mirror galvanometer. He found the average temperature of the conjunctiva to be 35.72° C. (96.2° F.), corresponding to that of 37.18° C. (99° F.) of the mouth. In cases of hyperæmia and swelling, the temperature was increased about half a degree. After cold compresses it sank to a corresponding degree and rose to an almost similar degree after warm compresses were maintained from ten to twenty minutes. In only exceptional cases did the reverse occur. In several instances where continued cold applications had been persisted in, the temperature remained low for a time, but finally it rose to a higher degree than before they were applied.

Knies, of Freiburg, $\frac{254}{\text{Feb.,'94}}$ has performed a series of experiments upon animals in order to discover *the avenues of exit of fluid from the eye* by means of pathological changes induced by injecting aseptic agents into the vitreous capable of exciting inflammation. He found that the fluid obtained egress through the fissures in the tissue, and not through any closed spaces (for the greater part through the angle of the chamber and the sclera into Tenon's

capsule, and also to a lesser degree into the subconjunctival tissue by way of the unchanged cornea). The posterior lymph-spaces in the optic nerve, especially in its connective-tissue work, showed evidences of inflammatory change. The author was also able to produce the prodromal symptoms of an attack of glaucoma by similar injections. He thinks that he has proved the falsity of the theory of the neurotic nature of glaucoma, and insists upon the pathological difference existing between glaucoma simplex and acuta, recognizing the former to be a form of atrophy of the optic nerve with excavation, and the latter as a result of anterior iridocyclitis. With a view to determining the diffusion of liquids through the membranes of the eye, Bellarminoff, of St. Petersburg, [204] has made a series of studies upon animals with injections of fluorescin. The fluid was dropped into the conjunctival sac, and, after a time sufficient for its absorption had elapsed, the fluid from the anterior chamber was drawn off by means of a fine syringe and the color of the humor was compared with that of the standing solution. Coloration of the aqueous humor occurred much more rapidly when the fluorescin was dropped into the eyes before enucleation than when the experiments were made upon eyes which had been excised. The diffusion occurred through the conjunctiva as well as the cornea, but was much greater through the latter. After the removal of the corneal epithelium the diffusion became much more marked, both in living and in dead eyes. When the action of the cervical sympathetic was abolished the diffusive power of the ocular membranes was much diminished, but an irritation of that nerve increased it markedly. Division of the trigeminus exerted a varied action: (*a*) immediately after its section the diffusion co-efficient was lessened; (*b*) one and one-half to two hours after the operation the co-efficient was increased; (*c*) twenty-four and more hours after the procedure, when corneal changes were present, the diffusion increased in a very marked degree. Irritation of the trigeminus diminished the power of diffusion to a slight extent. The increase of the diffusion produced by cocaine was attributed by the author to an irritation of the peripheral sympathetic and consequent diminution in the intra-ocular tension, in addition to paralysis of the peripheral endings of the trigeminus and changes in the corneal epithelium produced by the drug.

In regard to the physiology of the *orbicularis palpebrarum*,

Fevrier [171 Sept.,'93] concludes that the recti muscles exert upon this muscle a traction analogous to that exerted by the levator ani. The contraction and even the simple tonicity of the intra-orbital muscles constantly modify the direction of the orbicularis muscle by the mediation of the superior portion of the orbital aponeurosis. Sherrington, of London, [178 Aug.12,'94] has found that if the left third and fourth nerves be severed, leaving the external rectus muscle alone unparalyzed, and excitation of the cortex be induced, in the monkey, conjugate movements of both eyes toward the opposite side, with excursion of the eyeball limited to the median line, takes place. This reaction was obtainable from all points of the cortical substance, which, on excitation, gave conjugate lateral deviations of the eyes. Various experiments demonstrated that in many cases this action of arrest takes place subcortically, and that the cortex is not essential to the reaction. When the third nerve was severed intracranially the eyelid drooped permanently to the middle of the pupil, and volitional opening of the fellow-eye was unaccompanied by any movement in the lid of the opposite side; whereas, in blinking, the opening after momentary closure was equally rapid on both sides, demonstrating that there was no evidence of any cooperative contraction of the antagonistic muscles under volition any more than under experimental cortical excitation or during epilepsy.

Russel, of London, [178 Aug.12,'94] has conducted an elaborate series of experimental investigations on *eye-movements.* He has demonstrated the truth of Hughlings-Jackson's surmise that the reason why none but lateral movements of the eye have been obtained on cortical excitation might be that these movements are so much more powerfully represented in the cortex than any of the other ocular movements that they overpower the latter when the eye-area is stimulated. The possibility of the lateral movements taking place was excluded by cutting the lateral straight muscles before stimulating the cortex, when the following movements were evoked: 1. A direct downward movement of both globes. 2. A similar upward movement of both globes. 3. A movement of both globes downward and to the opposite side from the hemisphere stimulated. 4. A similar movement upward and to the opposite side from that stimulated. 5. A movement of convergence, both globes turning inward toward the middle line. 6. A

direct lateral movement toward the side of the hemisphere stimulated. 7. A movement upward and to the same side. The chief focus for the first-mentioned movements was located just above the horizontal fissure of the precentral sulcus. That of the second was slightly above and in front of the preceding area; the third just in front of the vertical part of the precentral sulcus; the fourth just below the horizontal fissure of the precentral sulcus; the fifth chiefly below and slightly above the hinder part of the horizontal sulcus designated **W** by Beevor and Horsley; the sixth and seventh were very inconstant. He also found that, when a portion of the eye-area of one cerebral hemisphere was excited, both eyes at first turned toward the lesion, but recovered their normal position after a variable time, dependent upon the severity of the lesion. If, however, the animal were anæsthetized, the eyeball returned again to the abnormal position, which was retained to some extent for a period of time varying from one to two hours after consciousness was restored. The phenomena seemed to the author to confirm Hughlings-Jackson's view that, after destruction of part of the cortical representation for eye-movements, certain nervous arrangements for some ocular movements are lost forever. Other experiments appeared to prove that one lateral half of the cerebellum controls the cortical cells of the opposite cerebral hemisphere, this and other facts making it more than probable that abnormal positions of the globes met with after ablation of parts of the cerebellum are due to the removal of some cerebellar influence directly exerted on the ocular muscles, rather than to any indirect effect of the cortex of the opposite cerebral hemisphere; and that this direct effect is of a paralytic rather than of an irritative character is put beyond question by the fact that, after the eye has returned to its normal position, it can be made to assume its abnormal position again under the influence of anæsthesia by ether. With regard to nystagmus, the result of ablation of parts of the cerebellum, two entirely different phenomena are concerned: the one, spontaneous and following an irritative phenomenon, possibly reflexly induced; the other, only invoked on voluntary movements of the globe, and in all probability a paralytic phenomenon, due to weakness of the muscles producing the movement of the eyes in any given direction, or to weakness of the antagonists of these muscles.

A study of the *mechanism of accommodation* has been made by Tscherning.[62 Dec.,'98] His experiments were performed with the ophthalmophakometer. During the act of accommodation the summit of the anterior surface of the lens remained in its place, whilst that of the posterior receded. The radius of the anterior surface of the crystalline, when accommodation was taking place, increased to a quite considerable degree toward the periphery. Almost spherical whilst at rest, during accommodation the surface affected a form approaching an hyperbole of revolution. The peripheral parts of the surface became flattened, whilst those of the central part became arched. In a word, the accommodation changes observed by him were as follow:. (1) the lens receded a little; (2) the curvature of the central parts of the surface increased, those of the peripheral portions diminished; (3) the central part of the crystalline increased in thickness. He believes that the ciliary muscle consists of two layers,—a more external one, which is inserted anteriorly into the sclerotic, and a more internal one, which has no fixed insertion, the fibres changing their direction anteriorly in order to become circular. Both layers are inserted posteriorly into the choroid. The mechanism of accommodation is accomplished by a traction exercised by the zonule upon the crystalline, which is effected as follows: The anterior extremities of the deeper layer recede, and in this way exercise a traction out and down upon the zonule. On the other hand, this traction tends to make the crystalline recede, whilst, on the other, it changes the form of its surfaces by rendering the central parts more convex. The posterior extremity of the entire muscle advances and stretches the choroid in such a way that it supports the vitreous and prevents it from receding. By fixing the crystalline, this last act favors the effect of the zonule traction upon the configuration of its surface.

Sattler, of Leipzig,[204 B.40,H.3,'94] takes exception to the statement raised by Schneller that the amplitude of accommodation increases with the convergence and lowering of the eyes. As he believes that this author's method of testing was faulty, he conducted his own experiment by an instrument constructed for the purpose under Hering's direction. The principal points upon which his observations were founded are: 1. When examining with parallel axes, the haploscopical fusion of two identical images presented to both eyes is the only absolute guarantee that convergence has been

entirely excluded. Whilst experimenting with this method of fusion, the eyes often seem to diverge. 2. The apparatus must be so constructed that the distance between the optical centres of the correcting lenses necessary in those cases and in testing is equal to the pupillary distance when examining with parallel axes; and, furthermore, the visual axes must be perpendicular to the lenses and the test-cards in the position of the axes. 3. The axis of the revolution of the apparatus about which the lenses and test-objects revolve whenever the frame leaves the horizontal must pass through the centres of rotation of both eyes, *i.e.*, coincide with their basal line. The author asserts that when internal accommodation is fully excluded no increase in refraction worth considering is brought about by converging or lowering the visual axes. He also states that the thickness of the sclera at the posterior pole is absolutely greater in relation to the length of the globe in children than in adults.

From a study of the *range of convergence* when the visual axes were raised and lowered, Schmidt, of Leipzig, [204 B.39,H.4] concludes that (1) the position of the area of fusion is at times the same when the visual axes are raised as when they are horizontal or lowered. Gradually, however, there is a greater power of divergence and a lesser power of convergence. 2. The position of the area of fusion is dependent upon the equilibrium of the eyes. In different conditions of accommodation the equilibrium in raising and lowering the axes lies internally for the greater part, and about equally distant from the divergence borders of the range of fusion; so that an increasing degree of insufficiency of convergence arises upon increased accommodative effort. (Dynamical external strabismus of von Graefe.) If such an insufficiency exist with the absence of accommodative effort, it becomes increased by the increase in accommodation. 3. By raising the visual axes the range of the area of fusion remains the same or becomes smaller at the cost of the power of convergence than when the visual axes are directed downward.

Hughlings-Jackson, of London, [6 Jan.6,'94] points out the necessity of observing the movements of the iris in a dim light in order to ascertain whether or not the *action of the cervical sympathetic upon the pupil* has been abolished.

Sachs, of Prague, [204 B.39,H.3] claims that the *play of the pupil*, in

individuals possessing *disturbances in the perception of color*, is different from that in normal color-perception. The deviation from the normal is the more capable of explanation by the consideration of the changes which the value of light-intensity undergoes in color-blind eyes. From the behavior of the pupil when subjected to tests, it is quite possible to determine the nature of the color-blindness.

In regard to the *field of observation in the direct method of ophthalmoscopical examination*, Guilloz [274] Feb.,Mar.,'94 concludes as follows: 1. The ophthalmoscopical field of observation is practically a little less than the value given it by its formulæ, but remains higher than that assigned to it by Helmholtz. 2. It increases proportionately to the sum of the pupillary sizes of both the observer and the observed, and inversely with the distance which separates the images of their pupils. The influence of the dimension of the pupil of the observer is, therefore, of the same order as that of the pupil of the observed. 3. In the ametropia of curvature the field of observation is larger in hypermetropia, all things being equal, than in emmetropia. It is greater in the latter condition than in myopia. It increases with the degree of hypermetropia and decreases with that of myopia. 4. In axial ametropia, designated by M, the crossing-point of the rays joins the superior part of the pupil of the observer with the inferior part of that of the observed, and reciprocally by calling Xh, X, Xm the fields of observation of eyes respectively hypermetropic, emmetropic, and myopic; then, if M is in advance of the anterior focus of the observed eye, $Xh > X > Xm$; if M coincide with F, then $Xh = X = Xm$; and, finally, if M is between the observed eye and its anterior focus F, $Xm > X > Xh$. 5. In regard to the extent of the field of observation, ophthalmoscopes employed in the direct method should be provided with large apertures in order that the field may be benefited by the entire size of the pupillary opening of the observer. It is well to employ an illumination of sufficient strength that its field may be at least equal to the field of observation.

Rée, of Copenhagen, [173] June,'94 has examined a number of individuals by making them draw the figures as they saw a point of light at different distances from their eyes, and has found that the acuity of the normal eye was about $1\frac{1}{2}$. An acuity equal to or less than 1

always indicates an irregularity in the refracting media, and the degree of these irregularities corresponds in general to the diminution in the visual acuity.

In testing the *light-sense of the periphery of the retina* for diagnostic purposes, Holden, of New York, [249 Jan.,'94] employs a card with a gray quadrant, 15 millimetres in size, having four-fifths the intensity of white on one side, while the other is provided with a 1-millimetre black point. These points should be seen at the same angle and serve as a control, the one upon the other. This card is used to detect slight changes in the intermediate and central zones, whilst errors in the periphery are discovered by a second card, which has a 3-millimetre black point on one side and a darker gray patch, two-thirds the intensity of white, on the other. The author gives notes of seven cases where this method was of value in ocular examination.

Nicati, of Marseilles, [171 June,'94] states that his *charts for oxyopimetry* are adapted for distance at 3.50 metres, and for reading at 35 centimetres; by means of another series of charts on photometry and photo-esthesiometry he readily takes account of the distribution of illumination in the different parts of a room; these may also be used in physiology to determine the exact visual acuity. By the typometry test the proportion between the eye and the form of the letter is said to be easily ascertained. The author states [274 May,'94] of these charts that the unit represents a measure of sensation (vs), which diminishes or increases arithmetically with an illumination which increases or diminishes geometrically. He thinks that the method will be of service in measuring the loss in visual acuity after accidents, and proposes, as a photometric unit, the light, which, being placed at the unit of distance, reflects upon the visual acuity a white surface. This he calls *the photo*, which he defines as being the minimum of illumination which, when placed one metre from the test object, gives to the normal monocular vision a limited visual angle equaling one minute.

In answer to the question, why are persons who have a high degree of functional narrowing of the field of vision not disturbed in their powers of observation, Groenouw, of Breslau, [204 B.40,H.2] states that the concentrically-narrowed field widens out for distances,—*i.e.*, the field of vision of an individual so afflicted is greater when going about in a room than during perimetric examination. Again,

the periphery of the visual field which appears defective when examined with a small white quadrant is not entirely insensitive to all impressions of light, and greater or better illuminated objects may still be seen.

In order to determine how much the form sense is influenced by hindering the perception of impressions of light, Guillery, of Boulogne, 254 Apr.,'94 has made use of small quadrants containing Snellen's figures. The required reduction in the visual acuity was accomplished by holding convex spherical glasses of varying strengths before the eye. It was found that the form sense was but slightly dependent upon a fixed law and a fixed intensity of perception.

In regard to the equality in *size of the retinal images in corrected axial ametropia and in emmetropia*, Lagrange, 171 Feb.,'94 of Bordeaux, points out that, when in ametropia the correcting-glass is placed at the anterior focus of the eye, a system of associated convex lenses is created, of which the common nodal point is placed anterior or posterior to the nodal point of the ametropic eye. This discrepancy in the position of the nodal point represents exactly the excess or deficiency in the length of the eye. He adds 171 Apr.,'94 that the study of lenses associated in certain conditions will make clear their action when applied to the eye.

In regard to the *theory of the perception of colors*, Dufour, of Lausanne, 178 June,'94 states that red is the color which appears the darkest, its brightness being more variable than that of other colors. With a solar spectrum the sensation of light commenced only feebly at bright red, near the line B; it increased and diminished chiefly at E and B, and to diminish immediately at pure green. From these facts he concludes that: 1. The theory of Hering is not sufficient to explain how subjects who are not capable of stimulation, except at the centre of perception of black and white, perceive the greatest clearness in the green of the spectrum. 2. The Young-Helmholtz theory explains the fact perfectly. Supposing the absence of two fundamental sensations in the observed cases, the conical sensation will be that of green. In reality, when the person observed sees green, he perceives the different shades of green. Wallace, of Philadelphia, 112 May,'94 believes that the retina contains a numerous series of cones varying in their length, so regulated as to vibrate with the varying lengths of the other waves. He would

account for color-blindness by supposing the absence of cones corresponding to a particular wave of the spectrum.

Griffith $_{\text{Sept.15,'94}}^{2}$ says that when the eye is at rest there is only a single row of pigmented columnar cells in the pars non-plicata of the ciliary body, and in the act of accommodation this cellular membrane is thrown into folds which are analogous to the involuted arrangement of the cells in the posterior surface of the iris, giving to it the appearance of glandular structure. He denies that the chorio-capillaris extends forward and lies subjacent to the ciliary epithelial of the processes, on the ground that he has found a cessation of this fenestrated membrane at the ora serrata in the injected eye of albino rabbits. He finds it difficult to attribute the power of secreting the aqueous humor to the ciliary glands described by Collins, and suggests that their function is the regeneration of the ocular pigment, as they exist in greatest number in dark-brown eyes, are scanty in blue eyes, and are absent in the eyes of albino rabbits.

A study of the primary, secondary, and tertiary *retinal pictures after momentary impressions of light* has been made by Borsch, of Utrecht, $_{\text{B.40,H.1,'94}}^{204}$ who concludes as follows: 1. The consecutive retinal pictures appear in the truest and simplest form after the shortest illumination possible of a localized part of the retina when every other impression of light has been excluded. 2. Contrast effects in the neighborhood of the retinal vessels also occur in illumination by electrical sparks. 3. The perception processes are the clearer when a neighboring contrast irritation occurs at the same time by local retinal irritation. 4. In its simplest form the perception image has three phases: the primary, which lasts longer than the illumination itself; the secondary, which has the complementary colors of the primary; and the tertiary. 5. The third phase of the retinal image is characterized by the diminution of sensibility of weak objective light, by which it otherwise would be extinguished. 6. The after-image of a long, equal illumination is composed of an accumulation of rapidly-following light-impressions.

In regard to the *perception of colors by different races*, Regnault $_{\text{Nov.4,'93}}^{31}$ concludes that: 1. The theory of Magnus, that each race perceives colors differently, has as yet no foundation. The different expressions employed in the denomination of colors are due to the

poverty of the language and the lack of attention which characterizes the savage. 2. The preferences of each nation should be taken into consideration. The northern races generally prefer sombre tints, whilst the races of the south admire brighter colors. Savages have a marked predilection for red. Preference for a color does not only appear in the clothing, etc., but also in the arts, and even in architecture.

Concerning the *production of secondary images*, Snellen, Sr., of Utrecht, [171] Oct., '93 concludes as follows: 1. An instantaneous illumination produces secondary images possessing three phases. 2. The first two phases are brightest, the shorter the time of illumination. 3. The third phase only appears when there has been a total absence of all external illumination, the objective light causing this secondary image to disappear. 4. During the fixation of the surface but feebly illuminated, images are perceived, successively bright and shaded. These changes indicate the existence of retinal fatigue, followed by immediate restoration. In answer to objections raised by Ole Bull, Hegg [171] Feb., '94 maintains the views embodied in a former article upon *perimetry* by means of colored pigments, and states, in conclusion, that he attributes a certain diagnostic value to his pigments in affections of the optic nerve.

Regarding the *visual function of the cuneus*, Bressaud, of Paris, [171] Nov., '93 has concluded as follows: 1. The optic radiations—*i.e.*, the sensory fibres—are the most limited of the entire mass of the oval centre. Their origin in the optic striated nuclei are sufficiently definite, but they do not necessarily terminate in the occipital region. They border upon the entire inferior portion of the lingual lobe from the posterior extremity of this convolution up to the hippocampus, anterior to the olivary bodies. A certain number also protrude into the fusiform lobe, and perhaps even into the third occipito-temporal convolution. 2. There are no fibres of projection of the cuneus, properly speaking, in the visual nuclei, or, if they do exist there, they are in so small a number that their destruction is not capable of causing hemianopsia. Lesions of the cuneus alone are incapable of producing hemianopsia by a rupture of the fibres of projection. If lesions of the cuneus produce this result, the mechanism of the hemianopsia is not the usual one,—that is to say, it does not correspond to a direct interruption in the cortico-thalamic fibres.

While visiting North Greenland with the Peary expedition, Cook [61 Jan.27,'94] observed that when the natives were presented with a picture they invariably inverted it in order to appreciate it. The author's explanation of the phenomenon is that "these natives, in the infancy of civilization, have not been educated as we have, by a long series of training and probably by heredity, to read pictures as they would natural objects, but instead they hold the picture upside down so that the image will be transmitted to their retinas in a reverse position, and hence the impression is transmitted to the brain in the most natural way." He further says that he has since noticed the same peculiarity of vision among the mountaineer Indians of Labrador, and more rarely in young persons in civilized countries.

Gates, of Washington, [889 Sept.12,'94] has conducted a series of experiments with a view of determining the possibilities of *developing* certain *functions of the brain by early training.* For this purpose he selected three puppies from the same litter. The first received no special attention, the second had the eyes covered from birth, and the third was subjected to a careful course of education of the sight, by which he ultimately was taught to discriminate fifteen different shades of color. At the end of a certain period all three animals were killed, and the autopsy showed, in the second dog, an entire lack of development of the visual areas of the brain, while in the third animal they were twenty-five times better developed than in the brain of an ordinary dog, as represented by No. 1. Microscopically, the brain-tissue was denser, more highly vascular, and contained a larger number of cells, more highly developed than in the ordinary dog.

Angelucci, of Palermo, [173 Aug.,'94] has found that *extirpation of the superior cervical ganglion* in newborn animals occasions an alopecia of the same side of the face and dystrophies of the cranial bones and of the teeth. The development of the cornea is arrested, the eye becomes atonic, the calibre of the choroidal vessels diminishes, and the tract atrophies. Removal of the Gasserian ganglion produces contraction of the ocular vessels, followed by neuroparalytic lesions of the cornea. In the aged the disc has a greenish-gray appearance, which is due to senile alteration in the crystalline. Chromat-æsthesia is also present, as well as a diminution in the visual acuity. This explains the abuse of white, the pre-

dilection for violet, and the confusion between violet and green which is seen in aged artists.

Proskauer [190/Apr.,'94] has succeeded in *viewing the fundus of his own eye*, by holding a concave mirror provided with a central aperture before the right eye in such a way that it makes an angle of forty-five degrees with the forehead, and then looking into a plane mirror placed opposite to the left eye. In this way the right eye is made to see the image of the left in the plane mirror. The flame for illumination is placed upon the left side so that the left eye receives no direct light from it.

Carter, of London, [6/Mar.17,'94] has had an *instrument for the quantitative determination of color-vision* constructed. The apparatus consists of a box in the interior of which test-objects are displayed under illumination of varying colors and intensity. The light is supplied by a lamp, the rays from which are admitted in parallel direction through a convex lens, behind which is placed a canvas with plates of colored glass. The objects are placed in a revolving disc at the back of the box, and the examiner and patient view them through separate tubes. The author believes that the instrument will prove of value in the study of amblyopia with central color-scotoma.

In conducting *examinations for color-blindness* in applicants for railway employment, Welsh, [1164/June 5,'94] in addition to the ordinary tests for this condition, makes use of a representation of the rear end of a caboose-car, with lanterns which are identical in shape with those that are used in train service. These are illuminated by electricity, the light of which may be flashed.

Thomson, of Philadelphia, [9/Aug.18,'94] has arranged a new *wool-test for the detection of color-blindness.* It consists of a large green and a large rose test-skein with forty small skeins, each marked with a bangle having a concealed number extending from one to forty. These are placed in a double box, and are so arranged as to keep the two series apart and permit each to be exposed upon a table in a confused mass. In applying the test, the large green skein is first employed and the patient is directed to select ten shades of the same color as the test-skein. If this be properly done, the bangles on the selected wools will all bear odd numbers. The rose test-skein is used in a similar manner.

Of 45,000 railroad employés examined by Ricchi, [173/Aug.,'94] 65.43

per cent. presented normal vision in both eyes. (Vision equalled $\frac{14}{10}$ in both eyes, the vision of one eye not being below $\frac{5}{10}$, myopia less than 5 dioptres, hypermetropia and astigmatism not greater than 2 dioptres. The visual field was not limited.) There were 6.27 per cent. myopes and 3.13 per cent. hypermetropes. The chromatic sense was normal in 97 per cent. As a total among 100 subjects, 13.57 per cent. presented anomalies of refraction and 2.20 per cent. defects in the chromatic sense. Not one case of limitation of the visual field was sufficient to require treatment, though several cases of scotoma for red and green were produced by alcohol.

SECTION III.

ERRORS OF REFRACTION AND ACCOMMODATION.

Southard, of San Francisco, $^{77}_{\text{Dec.,'93}}$ has made an *analysis of* 1300 *cases of refraction*, 8 per cent. being between 5 and 10 years of age, 16.61 per cent. between 10 and 15 years, and 22 per cent. between 15 and 20 years; 70 per cent. were females, the greatest difference in proportion of the sexes being between 10 and 25 years; 58 had a vision equalling $\frac{20}{20}$ previous to the correction of the existing ametropia; 78.18 per cent. were hypermetropic; 58 per cent. had simple hypermetropia; 21.82 per cent. had myopic refraction, of which 8 per cent. were simple myopia. In 70 per cent. of the hypermetropes the error was less than 1.5 dioptres. In an examination of the eyes of 1900 school-children of the public schools of San Francisco, Pishl, $^{61}_{\text{Sept.15,'94}}$ has found 69.52 per cent. emmetropic, 11.12 per cent. hypermetropic, and 7.21 per cent. myopic. There was also an increase in the percentage of myopia from 3.98 per cent. in the grammar school to 11.59 per cent. in the normal school. From the methods adopted in the examination, many hypermetropic and astigmatic eyes were included among the emmetropes.

From a *comparison of the eyes of white and colored pupils in the public schools* of Washington, Belt $^{1007}_{\text{Mar.,'94}}$ concludes that children often have defective eyes without being aware of it, and are loth to complain of their troubles, as shown from the fact that, although 40 per cent. had defects which caused more or less discomfort, only 15 per cent. complained of headache or of their

eyes becoming tired or painful upon use. These children, however, frequently give evidence of trouble by not advancing as rapidly in their studies as others of their age, and too frequently are thought to be stupid when, in fact, their eyes are at fault. This is well illustrated in the second grade, in which most of the pupils are 7 or 8 years of age; there were some, however, still in the second grade who were 10 and 11 years of age, 80 per cent. of whom had defective eyes, which were evidently the cause of their backwardness. He thinks that the increase of near-sightedness among Washington school-children is less than in most American cities, probably because their physical condition is better when they begin school. The few cases of abnormal eyes found among the colored pupils, as compared with the white, indicate the influence of the more advanced civilization in the causation of defective sight. Especially is this so of astigmatism, which was found in 25 per cent. of the white and in only 10 per cent. of the colored pupils. Heredity also has much to do with it. Myopes should not marry myopes, and parents with eye troubles should especially be careful to see that their children's eyes have proper attention in order that they may avoid the development of the same defects. Hypermetropic eyes are unhealthy ones, and tend to become myopic after passing through the stage of emmetropia, as would seem to be indicated by the fact that the decrease in hypermetropic eyes in the white school, which was 14 per cent., corresponds closely with the increase of myopia, which was 13 per cent., and, the greater the percentage of hypermetropia at the beginning, the more myopia at the close; *e.g.*, in the white school there was 31 per cent. of hypermetropia at the beginning and 23 per cent. of myopia at the close, while in the colored school there was only 16 per cent. of hypermetropia at the beginning and only 12 per cent. of myopia at the close. These facts being established, it follows that correction of the hypermetropia at an early age would probably prevent the development of many cases of myopia during school-life.

Among 1240 cases of *myopia*, Martin, of Bordeaux, $\frac{171}{July,'94}$ found 180 instances of the *monolateral form* of the disease. Corneal astigmatism is more common and exists in a higher degree in myopic than in non-myopic eyes, the frequency and degree of this astigmatism in myopes increasing with the degree of myopia. The monolateral type is not congenital in origin, traumatism and inflam-

mation of the cornea being doubtless the cause of the condition in subjects already predisposed to myopia. As a result of 800 examinations made in normal and high schools, Ball, of St. Louis, [364 Aug. 15, '94] found that, although the average age amongst the students of the former schools was much higher than in the latter, the percentage of myopia was greater in the latter than in the former. He explains this disproportion by the fact that the high-school children are almost without exception reared in the town, whilst the majority of the students of the normal schools are from the country.

Hess and Diedrich, of Leipzig, [254 June, '94] examined the eyes of 1875 public-school scholars, from 6 to 14 years of age, by means of retinoscopy under mydriasis. In nearly 1 per cent. of all cases of astigmatism the degree was against the rule. The normal astigmatism did not show any marked decrease from the sixth to the fourteenth year. Of one of the schools examined, 263 children were myopic; of these, 129 had a similar state of refraction in each eye. Of 142 myopic children, 50 per cent. were anisometropic; 55.1 per cent. had the highest degree in the right eye and 44.9 per cent. in the left. Bordier, of Bordeaux, [274 June, '94] presents several tables showing the apparent and the real acuity of the different forms of ametropia.

Risley, of Philadelphia, [249 July, '94] has prepared a series of tables from observations based upon the results obtained from an examination of 200,000 formulæ for spectacles and eye-glasses in Philadelphia. These cases were obtained partly from his own practice and partly from the books of several optical companies. The whole number of eyes for which distant glasses had been furnished by the optician was 187,018, of which 21.6 per cent. were for myopia. Of these, 39.5 per cent. were for simple myopia, whilst 60.5 per cent. were for myopic astigmatism. Among the private cases, however, where the refraction had been done under mydriasis, 22 per cent. were myopic; of these, 9.67 per cent. were instances of simple myopia, while 90.33 per cent. were astigmatic in varying degrees. In a very large number of patients there was mixed astigmatism on one side, whilst on the other there was either simple or compound myopic astigmatism, similar pathological symptoms being present in both eyes. The percentage of myopia was 3 per cent. higher among private cases than among

those selected from the books of the optical companies. The obvious inference is that the progress of the increasing refraction, both in percentage of cases and in the degree of the increase, was arrested by the treatment and glasses received. The value of modern ophthalmic methods is also shown most strikingly by this beneficial result, and the author adds that of late years he has been less frequently called upon to treat detachment of the retina and eyes impaired by macular hæmorrhage and atrophies.

Velhagen, of Göttingen [358 Mar.,'94] has found that when the parents are myopic their children frequently present the same form of ametropia, but that in the great majority of cases of myopia there is no family history of *myopia*. In only two cases out of fifty was there any blood relationship between the parents.

Wray [2 Dec.22,'93] suggests that in night-schools teaching should be conducted preferably by black-board and lantern, avoiding the use of accommodation in reading. Martin, of Bordeaux, [188 Nov.26,'93] believes that the two chief factors in the production of myopia among scholars are, first, the long use of the eye for near work, and, secondly, insufficient bodily exercise. Despagnet [173 Apr.,'94] has seen a case of myopia of 9 dioptres which he thinks was produced by a railway accident.

In the production of symptoms of *asthenopia*, Moriarty, of Omaha, [106 Feb.,'94] has found that defects in refraction are responsible for about 50 per cent. and muscular deficiencies for about 85 per cent. of the cases. Clarke [2 Sept.15,'94] considers *blepharitis* an expression of eye-strain in the strumous and in those who exhibit a tendency to eczema, just as the same ocular conditions will induce headaches and asthenopia in the nervous. Gould, of Philadelphia, [2 Sept.15,'94] again emphasizes the fact that it is the *low degrees of ametropia* that often give the greatest irritation to the general nervous system.

The significance of *subnormal accommodative power* is again referred to by Theobald, of Baltimore, [1018 July,'94] and several typical cases of this affection reported. He employs a vertical diplopia test, and orders the glass for near use, which gives an exophoria of from two to three degrees at thirteen inches.

Guilloz, of Nancy, [274 Nov.,'93] claims to have proved the existence of an *accommodative astigmatism* of the crystalline lens. In both of the observations made by him the patients were able to overcome cylindrical glasses of varying strength, but this could not be

accomplished after atropinization of the eye. Care was taken to eliminate the action of the lids during the experiment.

Rychner [217 Jan.,'94] has published a new *method of determining* the *refraction* by means of the indirect method. A convex lens of 10 dioptres is attached to a centimetre measure in such a way that the centre is 9.5 centimetres from one end of the measure. This extremity is held in contact with the lower orbital rim of the eye under examination. The indirect method of ophthalmic examination is then performed, and a small needle is placed upon the measure about the place where the image on the fundus is formed. The head of the observer is now moved from side to side to determine on which side of the needle the aërial image falls. The observer tries to cover one of the small retinal vessels by one of the crossed threads of the net. Mydriasis is necessary for the application of the method. The chief advantage claimed for it is that it is of service even in cases where the media are very hazy.

In regard to *retinoscopy*, Bardelli, of Vienna, [274 Jan.,'94] concludes as follows: (*a*) All the phenomena of retinoscopy take place upon the retina of the eyes under observation, and hold to the variation of the relations between the field of observation (the pupillary field of the observed eye) and the illuminated field of the same eye. The pupil of the observer does not play any rôle in these phenomena. (*b*) The field of observation depends upon the amplitude and the form of the pupil of the eye under examination, or, more precisely, it is constituted by the image of the pupil under observation upon the retina of the observer. (*c*) The field of illumination is constituted by the projection of the pupil of the observed eye upon the retina of the same eye, and moves upon the screen represented by the retina in the same direction as the movements of the plane mirror. (*d*) When the fields of illumination and of observation have their centres upon the same axes and the visual line of the observer, they recover perfectly. When the field of illumination is displaced, that of observation remaining fixed, a portion of the latter is occupied by the shadow. (*e*) When the punctum remotum of the observed eye is in advance of the eye of the observer, the luminous rays cross one another before they arrive at this latter and the shadow moves in an opposite direction in relation with the direction of the field of illumination of the observed eye. When the punctum remotum falls behind

the eye of the observer, the rays are received without their being crossed, the shadow moving in the same direction as the displacement of the field of illumination. The variations in the curvature which limits the shadow and the rapidity of its movement depend upon the different enlargements which may be presented by the transparent media of the observed eye in different ametropias. (*f*) The intensity of the illumination and the shadow in the pupillary field of observation depends upon the circle of diffusion in the image of the flame upon the retina of the patient, and also upon the condition of parallelism, convergence, or divergence of the rays which leave the eye under observation. (*g*) The movements of the shadow are neutral points when the punctum remotum of the observed eye coincide with the principal anterior focus of the eye of the observer. In the performance of *retinoscopy for* the *determination of conical cornea*, Mackay, of Edinburgh, $^{76}_{\text{Nov.,'93}}$ has observed that, owing to the fact that the pupil is usually dilated in this class of cases, two distinct glows are obtained,—a peripheral one which is clear, and a central one which is dull. Between these there is an intermediate ring of variable breadth and intensity. The author has studied the movements of the shadows in the central area, by first shutting off other disturbing rays by means of a stenopaic slit, and then, while tilting the mirror, approaching to about one-half millimetre or nearer to the patient's eye. This distance, however, is increased as soon as an approximate correction is obtained with concave glasses. Wray, of Croydon, $^{2}_{\text{Sept.15,'94}}$ has seen several cases in which, although the retinoscopic examination indicated the existence of more than 1.5 dioptres in the myopic meridian and 2 dioptres in the hypermetropic, examination with distant type showed no improvement over that obtained by correcting the hypermetropic meridian.

Truhart-Fellin, of Wenden, $^{21}_{\text{Mar.4,'94}}$ points out the value of *skiascopy* to the general practitioner as an easy and sure way of determining the refraction. He prefers the plane mirror, and stations himself at one metre distance from the patient.

Of the objective tests used in the *detection of astigmatism*, Prince, of Springfield, $^{1018}_{\text{Jan.,'94}}$ prefers retinoscopy and says that the ophthalmometer of Javal is only of use in conjunction with other means in making a diagnosis in doubtful cases.

From the study of the *astigmatism* resulting from wounds of

the cornea, Bates, of New York, $^{248}_{\text{Jan.,'94}}$ has formulated the following propositions: 1. A corneal incision lengthens the radius of curvature of that corneal meridian which is at right angles to the line of the incision, and does not flatten any other meridian. The astigmatism produced is a regular astigmatism, and is corrected by a convex cylinder at an axis parallel to the line of the incision. 2. The immediate result is greater than the ultimate result. 3. The astigmatism produced is permanent after a length of time,—at least a month after the cornea has healed. There may be at first 3 dioptres of astigmatism produced. At the end of a month there may be 2 dioptres. At the end of three months the astigmatism may still be 2 dioptres, and this amount will be permanent. 4. The amount of astigmatism produced is greater the nearer the incision is to the centre of the cornea. As much as 9 dioptres can be produced. 5. Mixed astigmatism occurs (*a*) temporarily; (*b*) with incarceration of the iris. He reports two cases of astigmatism where corneal section improved vision, although the ophthalmometer did not reveal any diminution in its amount.

Roosa, of New York, $^{1}_{\text{May 2,'94}}$ is convinced that the use of a mydriatic to determine the glass to be worn is entirely unnecessary if the ophthalmometer be employed. Lautenbauch, of Philadelphia, $^{1007}_{\text{Dec.,'93}}$ has examined 1400 eyes with Javal's ophthalmometer, and found that the instrument showed the axis of the astigmatism in 88 per cent. and its amount in 45 per cent. of the cases. It revealed the knowledge of diseased conditions of the eyeball, where the corneal nutrition was interfered with, or the intra-ocular tension modified; while, in connection with other methods, it permitted of a calculation of the lenticular refraction and astigmatism, as well as the depth of the eyeball. In order to determine the refraction of liquids, Moauro, of Naples, $^{173}_{\text{Aug.,'94}}$ has utilized the Javal ophthalmometer, to which he has added a small concave mirror. The measurements obtained were identical to those furnished by the prismatic method. Hudson, of New York, $^{1}_{\text{Aug.7,'94}}$ has found the ophthalmometer to be a very unreliable instrument, especially in the estimation of low degrees of astigmatism. In 144 cases in which he employed it, the results were incorrect and misleading in 99 instances.

An instance in which the corneal astigmatism was probably overcome by a corresponding axial change in curvature upon the

part of the crystalline lens has been cited by Chibret, of Clermont-Ferrand. [274 May, '94] The case was that of a presbyope, who was able to correct his myopic astigmatism only when the right eye, which was emmetropic, was used in conjunction with the other. By excluding the action of the irides, one is forced to admit that the ciliary muscle was the agent in the accomplishment of this act.

Thompson, of Kansas City, [786 Aug., '94] believes that a definite *tonicity of the ciliary muscle* is normal and should be taken into consideration in determining the refractive condition of the eye. He would not, as a rule, consider an hypermetropia of $\frac{2}{8}$ dioptre an abnormal condition in children, and has never seen a convergent squint in a child successfully treated by the correction of an hypermetropia.

Bowles, of New York, [59 May 19, '94] observed, within the space of a year and a half, the total *disappearance of a myopic astigmatism* of 2.5 dioptres in the right eye and a change from a myopic astigmatism of 2.5 dioptres to a simple hypermetropia of 5 dioptres in the left eye of a man aged 30 years. Chibret, of Clermont-Ferrand, [173 June, '94] has observed a case of astigmatism against the rule, where the refractive power of the cornea and the astigmatism had simultaneously increased, the former $1\frac{1}{2}$ dioptres and the latter 1 dioptre. From a comparison of a number of cases of astigmatism with and against the rule, the increase of 1 dioptre of an astigmatism of the latter class was found to be accompanied by an increase in the refractive power of the cornea of 1.40 dioptres; in astigmatism with the rule, the refractive power of the cornea was not increased. From these observations he concluds that: Astigmatism against the rule is caused by a deformity of the anterior pole of the eye produced by the corneal centre yielding to the intra-ocular tension, while the meridian, possessing the highest refracting power, has a tendency to deviate from the vertical into an horizontal position. Astigmatism against the rule is an acquired vice of refraction, whilst that with the rule is due to a congenital conformation.

In a case of *myopia* of 2 dioptres, J. Hutchinson, [806 Oct., '93] of London, observed an extensive zone of choroidal atrophy surrounding the discs. The patient was an illiterate man of 72 years of age. Caspar, of Muelheim, [254 Dec., '93] has seen three cases of ectasia of the posterior pole in myopic eyes of high degree similar to those

reported by Weiss. These appeared as half-moon-shaped depressions in the ocular tissue to the nasal side of the disc, with their concavity directed toward it. In one instance a smaller accessory one was found external to the larger. The author attributes the condition to a failure in development.

Masselon, of Paris, $^{171}_{\text{July,'94}}$ draws attention to *ectasia of the sclera* in myopia, on the nasal side of the disc, independent of the staphylomatous distension at the posterior pole of the eye. This is of interest as bearing upon the causation of myopia, being a condition of the sclerotic characterized by a lack of resistance in that envelope. He states that he is the first to have drawn attention to this, which is quite frequent in high degrees of myopia.

Lange, of Braunschweig, $^{353}_{\text{Mar.,'94}}$ has seen a well-marked accumulation of pigment on the outer border of a conus in a myopic boy 12 years old. After several weeks' instillation of atropia to overcome a slight spasm of the accommodation, the pigment disappeared, partly from paralysis of accommodation and consequent relaxation of the choroid, and partly from the action of atropia in producing a change in the circulation of the vessels.

Batten, of London, $^{76}_{\text{Apr.,'94}}$ draws attention to the importance of studying localized *posterior staphyloma* with distortion of the retinal vessels in myopic eyes. He has found that the distortion of the vessels indicates the position of the staphyloma, and that staphylomata of the macula itself do not produce so much disturbance in vision as those in its immediate neighborhood, which produce a great amount of dragging upon the retina.

Vacher, of Orleans, $^{173}_{\text{May,'94}}$ gives the notes of 13 cases of myopia in which transparent crystalline lenses were removed as a prophylactic measure in the progressive forms of the disease, and in retinal detachment. The author thinks that the operation should be performed only in cases where the myopia is over 14 dioptres, and only then when the annoyance of the subjective symptoms makes any remedial measure justifiable. He has never had an accident follow the procedure. Pflueger, of Berne, $^{173}_{\text{Aug.,'94}}$ states that it is his practice to needle but one eye in high myopia. From his statistics, comprising 20 women and 10 men, he concludes that the age of individuals does not seem to have any influence upon absorption. When the myopia is between 17 and 22 dioptres the increase of vision is inferior to that obtained in lower degrees. This

depends upon the fact that the lack in the refraction which follows the discission is superior in high myopia to that in lower degrees. Being persuaded that a low degree of hypermetropia is preferable to a myopic state, he fixes the inferior limit at 10 dioptres for children and 12 dioptres for adults. In all of his cases vision improved, sometimes doubled, or even tripled; and, once acquired, it remained.

With a view of obtaining a consensus of opinion as to the value of prescribing less than 0.50-dioptre cylinders, or less than 0.75-dioptre spherical lenses, Starkey, of Chicago, [61 Sept.8,'94] solicited answers from ophthalmic surgeons in the United States as to their practice and experience. Of seventy-five who replied, all but two were in the habit of using such lenses in cases of asthenopic or reflex symptoms associated with low refractive errors, claiming to have derived marked benefit from their employment. Hotz, of Chicago, [61 Mar.18,'94] has analyzed the results obtained in 50 cases of ametropia in which cylinders of 0.50 dioptre or less were prescribed. In 30 instances good results were obtained, in 1 there was a negative result, and in 19 the results are unknown.

A possible explanation of the relief afforded by the correction of low degrees of ametropia, offered by Strickler, of St. Paul, [776 July,'94] is that the error is sufficient to produce ciliary spasm in accommodation, while it does not have the same effect in distant vision. Coleman, of Chicago, [1007 Dec.,'93] orders full correction in ametropia, and thinks that, if this rule be adopted, but 2 per cent. of the cases would require treatment directed toward the muscles. Lydston, of Chicago, [61 Feb.24,'94] advises the application of a glass in time to militate against the establishment of pronounced nervous impressions known to be the sequelæ of uncorrected eye-strain consequent upon uncorrected refractive error, whether such error requires a cylinder of high or low degree for its correction.

For the prevention of myopia among school-children, Martin, of Bordeaux, [188 Dec.8,'93] recommends properly-regulated physical exercise as a part of the course of instruction.

Bates, of New York, [59 Jan.27,'94] states that, as a general rule, the treatment of axial myopia without glasses will improve the vision to that previously obtained with glasses. He uses atropia, with local bathing with hot water, and leeches to the temple. Dark glasses are worn to protect the eyes from light. Astringents

are applied to the conjunctiva. He has also found that many cases of myopia are improved by the employment of the pressure-bandage. Black, of Denver, $^{1171}_{\text{Apr.,'94}}$ considers a cycloplegic necessary in estimating errors of refraction only in patients under 40 years of age, and for this purpose employs tablets of homatropine. Payne, of New York, $^{814}_{\text{June 15,'94}}$ has found that the proportion of instances in which the astigmatism is corrected by cylinders with the axes at 90 degrees increases progressively with age, while a corresponding increase occurs in the number of cases in which the axes of the cylinder are at 180 degrees. He explains this by supposing that the superior and inferior, straight and oblique muscles, acting in accommodation, increase the curve of the cornea in the vertical meridian, and that the decreasing power of the ciliary muscle consequent upon age diminishes this action.

In regard to the modification in the size of retinal images produced by correcting lenses in the different anomalies of refraction, Bordier, of Bordeaux, $^{274}_{\text{May,'94}}$ has found that the images are of the same size if the ametropia be axial as those formed on the retina of emmetropes. This is only true when the correcting glass is in the anterior focal plane of the eye. In ametropia of curvature, however, the images are only the same size when the lens touches the cornea. This latter fact should be borne in mind in testing anomalies of this class. In cases of ametropia produced by a change in the refractive power of the ocular media, the lens never produces an image upon the myopic eye which is equal to that upon the eye of the emmetrope. The same is true in hypermetropia.

SECTION IV.

DISEASES OF THE ORBIT.

James, of Kilkenny, $^{2}_{\text{Dec.2,'93}}$ has removed *a metallic cane-head*, measuring one inch and three-quarters in length and weighing three-quarters of an ounce, from the antrum. The foreign body, after rupturing the globe, had glanced off and fractured the floor of the orbit and penetrated into the antrum, where it remained concealed by the tissues until eight days after the eye had been enucleated, the secretions of the antrum having driven it for a

short distance into the orbital cavity. The shape and size of the foreign body are here shown.

A case of *gunshot wound* of the left eye with loss of vision of the right eye is reported by Boyle, of New York. [776 Jan.,'94] The autopsy revealed the fact that the ball had penetrated the left eye and had buried itself in the brain after fracturing the body of the sphenoid bone. A clot which pressed upon the third, fourth, sixth, and optic nerves, and gave rise to the visual disturbances and the accompanying muscular deviations, was found at the base of the brain.

Scheidemann, of Berlin, [190 Dec.,'93] has observed six cases of attempted suicide by revolver-shots which had perforated the temporal region. From a study of these and other reported instances he has grouped the ocular symptoms arising from this condition as follows: 1. Tearing of the optic nerve, with instantaneous blindness. 2. Internal hæmorrhage and rupture of the internal layers when the coats of the eye are involved. In this latter class of cases, vision may be disturbed to a greater or less degree. 3. Paralysis of ocular muscles, isolated or in combination with the first two groups. The globe, as a rule, is uninjured, being anterior to the track of the ball, and its round contour and tendinous coats causing the shot to glide off from it.

FOREIGN BODY IN ORBIT AND ANTRUM. (JAMES.)
British Medical Journal.

Walker, of Liverpool, [6 Jan.27,'94] makes a plea for *early ligature in* cases of *pulsating exophthalmus.* He cites an instance of this affection in a woman 42 years old. The condition first appeared two weeks after a fall, and soon increased to an enormous extent. The common carotid artery was subsequently ligated, with cessation of the ocular symptoms. Power, of London, [173 Apr.,'94] has seen good results follow ligature of the common carotid artery in a young man who had developed exophthalmus as the result of a pistol-shot wound of the orbit. Compression failed to relieve the symptoms. Ligature of the artery was finally necessitated by a violent hæmorrhage from the left nares.

Friedenwald and Crawford, of Baltimore, [249 Jan.,'94] report two cases of exophthalmus due to orbital hæmorrhage. In the first instance

the orbit had been penetrated by a small foreign body. The subsequent protrusion of the globe is attributed to the pressure of the extravasated blood upon the optic nerve and the retinal vessels. The second case was thought to be an instance of spontaneous hæmorrhage into the orbit, from the suddenness of the onset, the comparative freedom from pain, and the absence of any inflammatory signs of throbbing or of *bruit.*

Pignatri, of Naples, 78 May, '94 describes two cases of exophthalmus of quite different origin. The first case was that of a boy, 4 years old, in whom the proptosis was produced by a fragment of wood driven into the orbit by a fall. The ocular movements were limited in all directions except below. The cornea was slightly occluded, and the retina and optic nerve were sufficiently inflamed to reduce the vision to $\frac{1}{10}$. Two weeks after the removal of the fragments of wood the exophthalmus disappeared and all inflammatory symptoms ceased. The second case was that of a man, 36 years old, in whom symptoms were due to a large polyp in the frontal sinus. Leplat, of Liége, 293 Feb., '94 observed marked *tenonitis* following exposure to the weather. Under proper treatment the case recovered.

Morison, of Newcastle-on-Tyne, 6 Jan. 6, '94 believes that the presence of a roughly fan-shaped subconjunctival hæmorrhage on the outer aspect of the eyeball is diagnostic of a fracture through the orbital plate, corresponding to the eye affected. He cites three instances in support of this assertion.

A case of chalky deposit and bone-formation in one of the ocular muscles following traumatism of the orbit has been seen by Brügger, of Manheim. 254 Apr., '94 Evidences of an inflammatory origin were present, and the case furnished an excellent opportunity of observing the correlation between hyaline and amyloid degeneration. The development of bone had no direct connection with the two latter forms of degeneration, but was regarded as an interstitial myositis arising in the perimysium of the muscular fibres. Vignes, 178 Apr., '94 has treated a patient in whom the movements of the globe were restricted in all directions, and diplopia produced from a blow upon the eye, causing hæmorrhagic compression of the ocular muscles.

Fage, of Amiens, 171 Nov., '93 cites an instance of *orbital cellulitis and palpebral abscess from a decayed tooth.* Fromaget, 70 Feb. 11, '94 of Bordeaux, describes a case of iritis consecutive to *empyema of the*

antrum of Highmore. The ocular inflammation, which had resisted all local treatment, subsided at once after the evacuation of pus from the antrum. A case of *suppurative disease in* the *maxillary antrum*, complicated with abscess of the lower limb, and attended with septicæmia, in a child 7 years old, is reported by Würdemann, of Milwaukee. [1018 July,'94]

May, of New York, [1018 July,'94] cites an instance of intense *orbital cellulitis* following tenotomy for squint. The operation was performed under strict antiseptic precautions, and the only complication was a rather profuse hæmorrhage from the wound. The cellulitis developed the day after the operation and gave rise to optic neuritis. The final outcome of the case was, however, good. The author thinks that the eye became infected by cold compresses applied by the family.

Axenfeld, of Marburg, [204 B.43] believes that the greater frequency of metastatic purulent ophthalmo-phlegmonous disease of the orbit is due to the distribution of the finer capillaries in the eye, and that prognosis is much more serious when both eyes are affected. Gallemaerts, of Brussels, [868 Nov.4,'93] details an instance of phlegmonous disease of both orbits, following measles, in a child 2 years old. Notwithstanding that the orbital tissues were freely incised, giving egress to a quantity of pus, the purulent material invaded the brain, causing death.

Drake-Brockman [2 Sept.30,'93] gives the notes of three cases of *double proptosis* due to pathological conditions in connection with the sphenoid and ethmoid bones. The first case occurred in a male Hindoo aged 35 years. The tumor presented itself at the oral cavity, obstructed the nasal chamber, and extended into the pharynx, subsequently involving the orbits and nasal, superior maxillary, and frontal bones. Both corneæ were ultimately destroyed. Post-mortem examination showed a sarcoma springing from the sphenoid bone and extending into the adjacent cavities. The second case was seen in a European officer, aged 41 years, serving in India. The progress of the disease was rapid and was accompanied by symptoms of a varied character, pointing to the involvement of several of the cranial nerves. Accumulations of pus appeared at various localities, the most extensive occurring beneath the trapezius muscle and in the right subclavian triangle. Autopsy showed the seat of the disease to be in the sphenoid bone, from whence pus

had traversed the various foramina at the base of the skull. The third instance occurred in a male Hindoo 30 years of age. Exophthalmus presented itself early, and the eyeballs were rapidly destroyed. The patient, who was a syphilitic, died, apparently from cerebral involvement. The disease appeared to have originated in the ethmoid bone, and there was extensive implication of the brain-membranes.

A case of *suppurative phlebitis of the right ophthalmic vein*, extending to the sinus, and from there to the left ophthalmic vein, producing consecutive phlegmonous inflammation of both orbits, has been seen by Moissy, of Lille, $^{220}_{\text{Nov.17,'93}}$ in a man aged 62 years. The case terminated fatally. The author attributes the disease to the entrance of a virulent agent into some slight, transient wound, which had cicatrized without its being observed.

From a consideration of the subject of *tumors of the orbit*, produced by inflammation of the frontal sinus, Martin, of Bordeaux $^{171}_{\text{Sept.,'94}}$ concludes as follows: The diagnosis of empyema of the sinus is rendered easy by intra-nasal catheterization. Disturbances in visual acuity are only seen when orbital tumors exist, and are usually due to a compression of the optic nerve by a tumor at its entrance into the orbit. Where the disease is of a purulent nature, antiseptic washes are best, as they do not produce cicatrices.

An instance of dermoid cyst of the fronto-orbital region is reported by de Lapersonne, of Lille. $^{274}_{\text{Nov.,'93}}$ The patient was 18 years old, and the tumor first appeared three years previously as a small projection below the left eyebrow, gradually increasing in size until the eyeball was much displaced. Two centimetres above the brow, at the point of union of the external third of the brow with its middle third, a small, round, bony depression could be plainly felt. After partial extirpation a large perforation in the orbital vault, with irregular edges, was discovered, extending as far as the summit of the orbit. It had a diameter of one-half centimetre, and was situated fifty-five millimetres from the median line and twenty-five millimetres above the brow. The author is inclined to think that the cyst was at first implanted in a depression of the anterior table of the frontal bone. At a more advanced period in its evolution it separated the two bony plates, pushing the posterior table back more than the anterior. Finally, it

reached the vault of the orbit, which it perforated, communicating by a small orifice with the frontal sinus.

French, of St. Louis, [364 Dec. 1, '93] has seen a *cyst of the orbit* follow a blow upon the eye of an 18-year-old female. The eye was proptosed. An operation for the drainage of the cyst revealed the presence of necrosis of the frontal bone. Roberts, of Louisville, [224 May, '94] gives the notes of a large cystic growth of the orbit in a man 61 years of age. The patient stated that the tumor had appeared two months after a blow on the head and eye, and had extended from above the eye to the temple, dislocating the eye inferiorly.

An encapsulated *tumor of the orbit*, in a child 4 years old, has been seen by Kalt. [274 July, '94] The growth was the size of a pea, and was situated anteriorly to the large ligament of the lid. The principal lobe contained a central venous orifice one-half millimetre in diameter. Between this vessel and the periphery of the globe there were numerous moderately-sized vessels, which subdivided into small capillaries grouped around the vessels of the second order. The growth presented many points of difference from ordinary angioma of the orbit, and is regarded by the author as an hypertrophy of the venous system analogous to the hypertrophy of the glandular tissue in adenoma. Elliot, of Secunderabad, [6 Nov. 25, '93] has performed evisceration of the right orbit for a fibrosarcoma in a middle-aged woman. The affection dated from an injury over the affected eye.

Bourgeois, of Reims, [171 Oct., '93] has observed a case of secondary invasion of *myxoma of the optic nerve* by a sarcoma of the orbit. The patient had become blind fifteen years before, as a result of optic atrophy secondary to the myxoma. The exophthalmus and pain, which demanded enucleation of the eye and extirpation of the growth, had only been present two months before the operation. The patient was 69 years old.

Braunschweig, of Halle, [353 Feb., '94] gives the microscopical details of two cases of *melanotic sarcoma of the orbit*, exceedingly vascular in type, previously reported by him. The non-recurrence of the growth had caused Berlin to doubt their malignant nature. Goldzieher, of Budapest, [190 Mar., '94] reports a case of freely-mobile *fibroma of the orbit* in a 17-year-old patient. The growth had originated in the orbit, but appeared later as a bosselated tumor of the subconjunctival tissue of the upper lid. The conjunctiva covering

the neoplasm contained enlarged blood-vessels, but was free from any suspicion of a granular process. After removal of the growth the microscope revealed its fibromatous nature. Tiffany, of Kansas City, [1007 Apr.,'94] believes that recurrence of malignant growths may be prevented by the employment of large grafts of skin upon the denuded area left after the extirpation of the neoplasm. He takes the precaution of building up the health of the patient before the grafting. The grafts should always be one-fifth to one-third larger than the site of the wound, and only the true skin, free from fatty subcutaneous tissue, should be taken. A pedicle is of no advantage. In order to prevent contraction of the flap when used to repair a socket, Gifford, of Omaha, [249 Jan.,'94] after dividing all cicatricial bands, packs the cavity with gauze for several days prior to the laying on of the flaps.

Noyes, of New York, [2035 '94] diminished the *deformity from necrosis of the orbit*, by which an eyeball was dislocated downward and outward nearly one-half inch below its proper level. In order to diminish the prolapse of the eyeball, parallel incisions were made to the inferior orbital rim from a point beyond the outer margin of the orbit to the side of the nose, following the line of a deep furrow. The upper one was situated one-half inch below the edge of the lower lid, whilst the lower inclosed the scarred tissue in the groove. The edges of these incisions were undermined. The mass of the cicatricial tissue was then buried, and the gap closed by a flap taken from the skin of the cheek at the external angle of the wound.

DISEASES OF THE LACHRYMAL APPARATUS.

Goldzieher, of Budapest, [78 Jan.,'94] has found that the lachrymal gland is supplied by the facial nerve, and that one-sided weeping is due to a paralysis of that nerve, the fifth nerve having nothing to do with the innervation of the gland, the eye being ordinarily moistened by a conjunctival secretion. The gland is only brought into activity in the act of weeping or in forced lachrymal secretion. Tepliachine, of Kasan, Russia, [274 July,'94] from experimental research, states that the cervical sympathetic nerve is the secretory nerve of the lachrymal gland and controls lachrymation.

Bach, of Wurzburg, [204 B.40,H.3] has found, experimentally, that an *infection of the conjunctival sac by bacteria* from the nose is im-

possible by way of the lachrymal canal. The tears have a germicidal action, although the element possessing this property could not be detected. The aqueous humor does not possess similar qualities. The vitreous offered a favorable ground for the development of the staphylococcus pyogenes aureus, as did also the mucous secretion of the conjunctiva. An increased secretion, however, did not seem to have any influence. Mechanical cleansing with neutral, non-irritating fluids was found to be a greater preventive against the development of germs than washing with antiseptics, the method of disinfection first described by himself and Stroscheim being the best.

In regard to the etiology of *kerato-conjunctivitis*, Couëtoux, of Nantes, [171 Oct.,'98] has found that the disease, in 137 cases observed by him, commenced at the time of life when affections of the rhino-pharynx are most marked, *i.e.*, before puberty. Of 30 cases observed in private practice, 25 exhibited marked rhino-pharyngeal symptoms. Mazet, of Bordeaux, [70 Dec.2,'98] has made a bacteriological examination of a *phlegmonous lachrymal tumor*, and concludes that it was associated with the evolution of a streptococcus virulent in the rabbit, the extreme virulence of the streptococcus being probably due to its association with a non-pathogenic bacillus.

Wood, of Chicago, [249 Jan.,'94] has observed an instance of congenital, bilateral, and *symmetrical fistulæ of the lachrymal sac*, in a man 35 years old. The openings occurred on the inferior edges of each sac, and were about five millimetres from the caruncles. Dianoux, of Nantes, [171 Aug.,'94] reports three cases of tumor of the lachrymal gland. In the first case the floor of the orbit had been markedly perforated in three places. In spite of a large perforation in the ethmoid, the dura mater and the mucous membrane of the nose had escaped injury. The only operative procedure indicated in the second stage of the disease is the horseshoe incision, made sufficiently far from the orbital rim to avoid injury of the frontal nerves. Antonelli, of Naples, [173 Aug.,'94] cites an instance of acute dacryo-adenitis of the inferior accessory lobules, in a man 25 years of age. The disease presented itself as a small tumor under the bulbar conjunctiva, one centimetre up and out from the corneal limbus. An exploratory incision was followed by the exit of a drop of pus mixed with epithelial *débris*. Healing followed in a few days.

Huth, of Iserlohn, [190 Apr.,'94] has removed a mass of *actinomycoses* from the lower canaliculus of a healthy man 44 years of age. The growth had obstructed the canal and had produced some slight inflammatory symptoms. An instance of actinomycosis of the lower canaliculus in a supposedly healthy 62-year-old woman was seen by Schroeder, of St. Petersburg. [353 Apr.,'94] The growth appeared as a swelling in the region of the canaliculus, and produced catarrh of the conjunctiva with slight stillicidium. After a thorough removal of the mass with the curette, the conjunctivitis disappeared and recovery ensued.

Marbourg, of Pueblo, [1099 Aug.,'94] has found that *dacryocystitis* occurs with equal frequency in specific and non-specific rhinitis. Dunn, of Richmond, [1007 Mar.,'94] cites an instance where simultaneous syphilitic inflammation of the mucous membranes of both lachrymal ducts produced strictures in their calibre which resisted all treatment. There had been no other manifestation of syphilis, and the nature of the disease was not detected until several years later, when ulceration of the soft palate and nasal cavities ensued. The same author [249 July,'94] gives some additional notes of a case of complete *destruction of both lachrymal ducts*, in a mulatto woman, the *result of syphilitic necrosis*. There was no lachrymation.

In the treatment of *stricture* of the lachrymal canal, Plettinck, [173 June,'94] employs sounds, which he allows to remain *in situ* six, eight, or even ten days. He uses three different classes of instruments, the first twenty-five millimetres, the second thirty-one centimetres, and the third thirty-eight millimetres in length. These are properly graded, a larger one replacing a smaller as soon as the former has worked loose. Six or eight sittings will complete the cure. Lagrange, of Bordeaux, [173 June,'94] has found electrolysis to be efficacious in a number of cases of stricture of the lachrymal canal, although it does not entirely fulfill the claims made for it. In certain instances, where too great a strength was employed, tough strictures were produced. When the current used was weaker than 4 milliampères, the canal was soon placed in an excellent condition to permit the passage of large probes. Fox, of Philadelphia, [760 Dec.9,'93] employs large probes, followed immediately by the insertion of a silver stylet into the duct. Guaita, of Siena, [30 V.22,No.1 6] has had excellent results from the rapid surgical treatment of dacryocystitis as proposed by Despagnet and Terson. He does

not incise the canaliculi, but simply dilates them with a conical sound. Coggin, of Salem, Mass., [99 Nov.9,'93] prefers frequent emptying of the sac by pressure and the use of an eye-lotion to probing.

Pschel, of Turin, [190 Aug.,'94] has constructed a galvano-cautery sound for employment in disease of the lachrymal apparatus. The instrument is straight and consists of two threads of platinum separated by an insulating layer. These two threads come together in a point, and are so arranged that only a small portion of the sound is brought to a heat, thus permitting of the restricted application of the cautery. He claims to have had remarkable success following this plan of treatment.

In a case of complete bony obstruction of the nasal duct, Caldwell, of New York, [1 Oct.1,'93] has operated successfully by first removing the anterior tip of the inferior turbinated bone up to the opening of the nasal duct and then extirpating the nasal wall of the nasal duct, together with the new formation, until the tip of a probe previously passed into the lachrymal sac was reached.

DISEASES OF THE EXTRA-OCULAR MUSCLES.

Hobby, of Iowa City, [61 Sept.8,'94] protests against the tendency to consider everything connected with the visual organs as governed by inflexible mathematical formulæ. The co-ordinate movements of the muscles of the eyes to perform a given task are the result of the same kind of practice and the same kind of training that, pursued for a long time, gives to the fingers and hands of the type-setter or musician their distinctive skill; in fact, the same kind of training and experience that the babe must go through with before standing on its feet and walking.

Grady, of Nashville, [120 July,'94] is convinced that so-called *muscular asthenopia*, or *heterophoria*, is not a condition of the muscles *per se*, and that "there is not enough evidence that the inherent viciousness is in the muscles themselves to warrant the violence that has been done them in the last decade." With the rare exception of irregular tendon attachment, all cases of asthenopia originating in the ocular apparatus have their beginning in the ciliary muscle. Clinically, there are two types of asthenopia: the hypersthenic, in which there is clonic spasm of the internal recti accompanied by esophoria and subnormal convergence power, and the asthenic, in which there is relaxation of the interni and

subnormal convergence, associated with exophoria. In both types there exists excessive stimulation of the interni through the ciliary muscle, which, as a rule, is produced by ametropia. He advocates treatment by innervation stimulation, and says that, while occasionally complete tenotomy may be necessary, partial or graduated tenotomies have no place in practice.

From a careful study of the dynamic power of the internal and external rectus muscles in 100 cases, Valk, of New York, [59 July 21, '94] concludes that in more than 50 per cent. of asthenopic cases the power of the externi exceeds that of the interni, in comparison with the usual proportions that should exist between these muscles; in other words, insufficiency of the interni is much more frequent than is stated in the text-books. Personally, he has found only 3 cases of insufficiency of the externi. He places very little reliance on any test for insufficiency of the muscular power, when the visual impressions of one eye are reduced by any means, and depends only upon the old test of the actual power of each individual muscle to turn the visual axis of the eyeball, coincident with a ray of light, deviated by a prism, from a candle placed at twenty feet from the person examined. In 48 cases the vertical diplopia test did not agree, and was exactly opposite to that of the prism test in 19 cases. In cases where the proportions of the muscles are as one to one, he exercises the weak muscles for a reasonable time, or as long as their power will increase, but has found this exercise useful only in weakness of the interni. Prisms, combined with the glasses, with the base over the weak muscles, may afford relief, and he has not found any of his cases develop a latent insufficiency from their use. In some cases they afford complete relief for a time; but there may be a return of the muscular weakness, the improved power obtained by exercise or prisms not being constant. The error of refraction, either simple or with astigmatism, should in all cases be corrected by suitable glasses, and these should be worn for a month at least before an attempt is made to correct any muscular insufficiency. In diplopia a complete and careful tenotomy should be performed with as slight a laceration of the tissues as possible. In well-marked insufficiency when the results of several trials with the prisms are the same, a partial tenotomy may be performed with the full confidence of a good result. In order to determine what part astigmatism plays

in the production of convergent strabismus, Chevallereau, of Paris, [173] examined the eyes of 200 cases presenting this deviation. The squinting eye in 59.6 per cent. exhibited more than ½ dioptre of astigmatism. In 46 cases the amount of the astigmatism was the same in both eyes, but in the majority of instances it was greater in the converging eye, whilst in 6 cases the fixing organ showed the greatest degree of corneal irregularity. Of the 119 eyes that were astigmatic the curvature was one hundred times with the rule and but nineteen times against it.

Hale, of Nashville, [1018] states that want of converging power is the chief cause of *muscular asthenopia.* He does not agree with those who have found insufficiency of the external recti to be a much more frequent cause, and also feels that if they will assume that disturbance of innervation is at the bottom of most of these cases, and work them out from that stand-point, they will find that many cases which they have supposed to be dependent upon weakness of the externi will fall very naturally under the reverse head. The notes of a series of cases are added in which the application of this principle was most successful.

Maddox, of Edinburgh, [76] draws attention to the physiology of latent torsion of the eye and the methods employed by him in testing it. It is important to bear in mind that in near vision apparent insufficiency of the obliques is just as physiological as latent deficiency of convergence, and in distant vision slight deviations are not unphysiological. Wahlfors, of Helsingfors, [254] asserts that strabismus depends upon a congenital muscular anomaly associated with other factors, one of the principal being innervation. The state of ocular equilibrium is not always one in which the visual axes are parallel, and the eyes may occupy a convergent or a divergent position.

Believing that *heterophoria is produced by a faulty innervation of the centres controlling ocular movements*, Gould, of Philadelphia, [1018] proposes to effect a normalization of innervation and co-ordination in exophoria by requiring the patient to overcome an excessive amount of prismatic power, bases out, whilst the object is carried from the near to the distant point. This procedure should be persisted in several times daily until no diplopia is produced by the first adjustment of the prism. In esophoria the exact reverse of the plan should be tried. It is wise to begin

with periods of a few minutes each in duration (reading moderately-fine print, varied with exercises in bringing appropriately-sized test-letters from beyond the point of fusion to a position within the point of fusion). There should be six to twelve exercises a day. Duane, of New York, asserts that this method has been known to the profession for many years, and that he has had but poor results from it, although he has employed it very frequently. In his practice, exercise of the convergence is of service only in those cases of exophoria in which the patient is unable to disassociate his convergence and accommodation.

A careful study of all cases of asthenopia has led C. H. Thomas, of Philadelphia, [104] to the following conclusions: "Muscular asthenopia may present symptoms of all grades of importance, from the slightest to the most serious. The muscular conditions in every case should, as a matter of routine, be as carefully investigated as are the media, eye-ground, refraction, and amplitude of accommodation. As in refractive, so in muscular, asthenopia, the gravity of the symptoms bears no constant relation to the amount of the physical defect. It is impossible to predict, with any considerable degree of definiteness, the result of correction of either refractive or muscular error. As much and very much the same kind of relief is to be expected from the correction of the muscular anomalies as from the correction of errors of refraction and accommodation, as might be expected from the similarity in the symptoms which these conditions respectively cause. During the earlier years of my study of these cases, I gave considerable attention to the graver neuroses—especially epilepsy—in connection with muscular anomalies, continuing the observation of a series of epileptic cases throughout a period of about five years. The results obtained in this series were altogether negative, not one recovering. With expectations of cure of epilepsy greatly abated, I, nevertheless, consider it proper to remove eye-strain of muscular origin in this affection, as I would in any other condition; and for the additional sufficient reason that sound conservatism in the management of epilepsy calls for the removal of all possible sources of peripheral irritation." He re-affirms his faith in graduated tenotomies, and attributes their effectiveness to the elasticity of the margin of the tendons.

In a discussion of the truth of Savage's statement regarding

the *harmonious symmetrical action of the oblique muscles*, Wilson, of Detroit 249 Jan.,'94 advances the following conclusions: 1. Compensatory rotation of the eyeballs in astigmatism will be necessary in order to secure binocular single-vision whenever the predominant diffusion-lines of any object upon the retina of one eye and the normal or diffusion-line image in the other eye do not fall upon corresponding retinal points. 2. This lack of retinal correspondence, or rotation of the image, is a function of (*a*) the amount and character of the astigmatism; (*b*) the nature of the ametropia (probably); (*c*) the nature of the object viewed; (*d*) the action of the ciliary muscle.

Hansell, of Philadelphia, 61 June 9,'94 maintains that *hypertropia* is always found to complicate *esotropia*, that this deviation is always transferred with the esotropia in concomitant or alternating strabismus, and that there is permanent upward deviation of the inward-turned eye in constant squint. The hypertropia disappears under correction of the error of refraction and tenotomy of the interni, and vertical equilibrium can be obtained only by operating on the vertical muscles.

According to Price, Nashville, 61 Sept. 8,'94 the causes of *cyclophoria* are: oblique astigmatism, fatigue of the superior oblique muscles from continued near work, increased action imposed upon the oblique muscles by faulty insertion of the straight muscles, and faulty attachment of the oblique muscles themselves. As a *memory-help* to the proper axes in which the cylinder should be placed in order to exercise weak oblique muscles, Steele, of Chattanooga, 1007 Mar.,'94 states that each cylinder should be rotated in the direction which will place its axis in a general way parallel with the middle line for the eye, the deviation of which is shown upon Savage's chart.

In *testing for heterophoria*, Woods, of Baltimore, 1007 Feb.,'94 believes a comparison of the distant and near equilibrium to be very important. Of 100 cases examined by him, the distance equilibrium was: orthophoria, 39; esophoria, 29; exophoria, 28; hypophoria, 3; hyperexophoria, 1. Insufficiency of convergence was noticed in 23 of the 39 cases with distance orthophoria, 26 of the 29 with esophoria, all of the 28 with exophoria, and 4 with vertical deviations. Of these 81 cases of comparative divergence at thirteen inches, 54 were hypermetropes and 21 myopes. It is a safe rule

to correct enough hypermetropia to produce at thirteen inches a comparative divergence of 2 or 3 degrees, and, in myopia of 3 or 4 dioptres, if the correcting distance-glass be employed at thireen inches, there will nearly always be deficient comparative divergence of 2 to 5 degrees, which will disappear when the strength of the concave glass is reduced. From this second fact he concludes that esophoria contra-indicates the use of strong concave glasses for near work, because of a necessarily-increased ciliary and a consequent internal rectus activity.

Having well considered the facial expressions in cases of heterophoria, Stevens, of New York, 1007 Feb.,'94 notes the ocular movements and records the results of the phorometer. These tests are performed without correcting lenses, as the author thinks that the latter lead to error, and that their absence has no influence upon the muscular condition. He considers the use of prisms to be very limited, gymnastic exercise to be but tentative, and claims that actual adjustment of the muscular condition is best accomplished by the performance of graduated tenotomies and by tendon contractions. He makes it a rule never to correct an overcorrection by a new tenotomy, but to shorten the tendon or the muscle when such a condition arises. In the *management of symptomatic heterophoria*, Barnes, of New York, 1 Apr.22,'94 urges the adoption of the following plan: (1) correct any refractive error; (2) wait; (3) experiment with prisms; (4) perform tenotomy. He advises surgical interference if, after a period of at least six months, decided relief is not afforded by the correction of the error of refraction, and especially if prisms in addition are of benefit. Stewart, of Cincinnati 776 July,'94 has employed prism-exercise with marked benefit in two cases of headache with weak internal rectus muscles. Jackson, of Philadelphia, 451 Feb.,'94 most properly pleads for the conservative employment of operative measures in the treatment of strabismus.

From his own rather limited experience and the writings of safe men, Bernstein 776 July,'94 believes that heterophorias are present in a large proportion of cases which seek aid for asthenopia. In by far the greatest majority attention to ametropia will be all that is necessary to give perfect comfort, and it is for which counsel is sought; the patient cares very little whether he has an exophoria, esophoria, or hypophoria, so long as it does not annoy him.

Hall, of Galveston, 2013 May 2,'94 gives the notes of several cases of

insufficiency of the ocular muscles, in which treatment directed toward the condition was followed by a subsidence of troublesome symptoms. Morton, of Minneapolis, 1007 Mar.,'94 reports four cases suffering with severe asthenopia, relieved by rhythmic exercise, after the failure of other plans of treatment. Scales, of Pine Bluff, Ark., 1007 Apr.,'94 has cured a vertical nystagmus of one eye by shortening the superior rectus muscle. Hansell, of Philadelphia, 9 Mar.2,'94 reports two cases of functional nervous disease successfully treated by tenotomy of the superior and inferior rectus muscles. The first instance was that of a girl, aged 16 years, who, for two years previously, had suffered from attacks of epileptiform convulsions of increasing frequency. There were also marked facial spasms. In the second case, that of a girl of 19 years of age, there was a history of headache, vertigo, fainting attacks, and asthenopia.

Heath, of Indianapolis, 1018 Apr.,'94 pleads for conservatism in the treatment of muscular insufficiency, and says: "I hope not to be misunderstood as claiming that operative treatment in muscular insufficiencies is never advisable, but that it should be resorted to only in persistent cases, not hopelessly neurotic, with diagnosis reasonably certain, and after the more conservative measures have been tried and found wanting." Savage, of Nashville, 86 Dec.,'94 has seen relief from habitual constipation with permanent urticaria of fifteen years' duration follow the correction of an ametropia and the institution of ocular exercise for a weakness of the oblique muscles.

In uncomplicated cases of *convergent strabismus*,—*i.e.*, where the false and true images are on one horizontal plane,—Hansell, of Philadelphia, 1018 Jan.,'94 divides each internal rectus partially or entirely by severing the tendons only, and, if convergence still persist, by advancement of one or both external tendons. The treatment of complicated convergent squint—*i.e.*, where there is upward or downward deviation from the visual lines—includes improvement of vision by a careful and full correction of all optical defects and the exercise of amblyopic eyes. He operates as soon as the patient is able to give accurate information of the relative positions of the double images. The proper equilibrium through operation is gained by (*a*) restoration of vertical equilibrium by tenotomy of the superior rectus of the upward and, if necessary, the inferior of the downward deviating eye; (*b*) restoration of horizontal equi-

librium by tenotomy of both internal muscles and, if necessary, advancement of one or both externi.

In regard to *vision before and after the operation of strabismus*, Schmidt-Rimpler, of Göttingen, 173 Aug.,'94 states that the theory that the projection of the false image is normal in strabismus when it is produced by means of a colored glass is fallacious. When the non-deviating eye fixes a candle, if the finger is interposed between it and the flame, the flame disappears. If the deviating eye possess the same qualities of impressionability as the macula of the non-deviating eye, the patient would see the flame. It is therefore necessary to prescribe stereoscopic exercises after operation, in order to improve the vision of the squinting eye.

Stevens, of New York, 2 Sept.15,'94 contends that few cases of *heterophoria* operated upon by the usual methods acquire *binocular vision*, and that failures may be practically eliminated by careful attention not to the gross and most conspicuous phenomena of strabismus (the lateral deviation), but to the essential and important relations of the tensions in vertical as well as in horizontal directions. In a squinting eye which had previously been amblyopic, seen by Johnson, of Patterson, N. Y., 347 Jan.,'94 vision improved from $\frac{20}{70}$ to $\frac{20}{20}$ in four days' time, from necessitated use of the eye; the good eye having been injured to such an extent that it could not be utilized. At the end of fifteen days the patient could read Jr. 1 at ten inches. The patient had previously undergone a tenotomy which had partially corrected the strabismus, but it had no effect upon the vision of the eye. The author considers this case to be another evidence of the existence of amblyopia exanopsia, and that it clearly indicates that the amblyopic eye does not enter into the visual act, even though it may be successfully operated upon; and that, although it does not resume its functions while the fellow-eye is still selected for use, it has the ability to and does return to its normal condition immediately after the loss or destruction of the fixing eye.

Lydston, of Chicago, 60 Dec.22,'93 believes that there is a true *amblyopia exanopsia*, and states that, if a cortical lesion be assumed to account for the defect in vision in a squinting eye, the other eye would also be affected, owing to the decussation of the optic-nerve fibres. In advocating the restriction of the term *amblyopia* to the imperfect vision found in eyes that have been deprived of perfect

retinal images at the point of fixation for some length of time, Hobby, of Iowa City, [1007 Mar.,'94] concludes that this condition is rarely found excepting in eyes that have been deprived of perfect retinal images for a considerable time, probably for years. Where the eye is deprived of the formation of distinct retinal images from birth for several years, amblyopia always results. The more imperfect the retinal image during childhood, the higher the grade of amblyopia. In another paper [347 Feb.,'94] he states that the best vision in strabismus is obtained not by early operation, but by enforced use of both eyes. By beginning this treatment at 5 years of age, and even later, he has repeatedly secured binocular fixation and vision without operation.

Hirschberg, of Berlin, [190 July,'94] points out that in convergent squint each eye avoids the external position. The cause of this is that the vertical arc of rotation is displaced toward the nasal side in both eyes. Motais [173 June,'94] proposes a new method in performing simple *muscular advancement.* Two double-needled sutures are employed. The first needle is passed through the tendon two millimetres from its point of insertion. One of the needles of the second suture is then passed through the tendon in a similar manner, two millimetres posterior to the former. The tendon is then cut at its point of insertion, the two superior needles being carried under the conjunctiva, which they traverse at the level of the vertical meridian. This manœuvre is repeated for the two inferior sutures, which are so tied as to include the conjunctiva. They are removed at the end of the eighth day. The procedure is indicated: 1. In non-progressive paralytic strabismus of five to fifteen degrees, when other local and general methods of treatment have failed. 2. In the strabismus of very young infants, where tenotomy frequently results in an overcorrection, particularly in nervous subjects. 3. After more or less unsuccessful results from a previous tenotomy, when the deviation does not exceed twelve degrees, and when the squint has resisted all other optical and orthoptical methods. 4. In complicated strabismus, where the superior squint is not corrected after the operation upon internal strabismus. 5. In muscular insufficiency, except in that of myopia.

Landolt, of Paris, [2 Sept.15,'94] suggests the following rules to facilitate the *diagnosis of paralysis of the ocular muscles:* "1. The

affected eye is that in the direction of the image of which the diplopia increases. 2. The paralyzed muscle is the one which should have given to the eye the position and the direction of the false image. 3. The direction of the head corresponds in every way to the physiological action of the paralyzed muscle."

Zimmerman, of Milwaukee, 1018 Apr., '94 reports a case of *traumatic paresis* of the left inferior rectus, combined with traumatic insufficiency of the left external rectus, following a blow upon the eye. Dresel, of San Francisco, 77 Dec., '93 observed paralysis of all the external ocular muscles supplied by the third nerve, together with paresis of the fourth and sixth nerves of the right eye, in a man 41 years of age, as the result of a blow on the back of the head. There were no other ocular symptoms. The author considers the lesion to have been a hæmorrhage involving the nuclei of the affected nerves. Landman, of Toledo, 1018 Jan., '94 cites two cases of *monocular polyopia* the results of trauma. In both instances there was strabismus internus, both eyes being affected in one case, with monocular diplopia in each. In the second instance there was monocular polyopia in the squinting eye. The difficulty was in the visual centres, and was due to a hæmorrhage and clot, which became organized and finally absorbed. The centre was subdivided by this act, and received two or more impressions from one image. He is led to believe that monocular diplopia may be the result of a lesion separating the visual centre within itself,—the peripheral impression being one and the central two or more.

Duane, of New York, 249 Jan., '94 has seen six cases of *isolated paresis of the superior rectus muscle*, and four others in which the paresis of this muscle was associated respectively with esophoria, insufficiency of the externi, paresis of the internal rectus of the other eye, and a congenital divergent squint. He also quotes some half-dozen other cases in which the muscular conditions were more complex, but in which various circumstances pointed to the part played by the affection of the superior rectus in the production of the attendant symptoms. These cases occurred, for the greater part, in subjects under 30 years of age, who were obliged by their occupation to look long and steadily at near objects, and who, as a rule, presented but slight symptoms, vertical and lateral diplopia being the most constant. In the majority of instances the paresis is of congenital origin, and probably due to lack of

development. Advancement of the paralyzed muscle is indicated, but relief to the symptoms is often gained by reducing the amount of the accompanying exophoria by the use of prismatic exercise. The notes of fifteen cases are appended in full. Jocqs, of Paris, [171] Jan.,'94 reports a case of paralysis of the sixth cranial nerve following a traumatism of the base of the brain. The patient was 9 years old. There was no hæmorrhage in the nose or ear, but the child expectorated a quantity of mucus tinged with blood, which the author thought came from the Eustachian tube. The force of the fall was back of the left ear. A diplopia which was caused by a paralysis of the right sixth nerve pointed to a fracture of the right petrous portion of the temporal bone.

Jack, of Boston, [99] Dec.21,'93 cites an instance of *recurrent paralysis of the oculo-motor nerve* in a 26-year-old woman. The attacks began when the patient was 16 years of age and had recurred repeatedly as often as five or six in a year. At no time could any connection be traced to disturbed menstruation. The patient did not exhibit any evidence of constitutional disease. For the first few years there had been no paralysis between the attacks, but during the last four or five years dilatation of the pupil, paralysis of the accommodation, and a degree of diplopia produced by looking upward had been permanent.

Raia, of Providence, [9] Feb.2,'94 gives notes of three cases of *partial paralysis of the ocular muscles.* The interesting features were that in two of the cases the ocular affection was on the opposite side to the head injury; in the third case, while the compression was apparently exerted upon the brain, the permanent injury was limited to a branch of the oculo-motor nerve; in all three instances the paralysis came on some days after the accident. Sachs, of Vienna, [217] June,'94 has successfully treated a case of isolated paralysis of the left inferior oblique by tenotomy of the right superior rectus. The patient had been struck in the orbital region by the horn of a stag. The author accounts for the crossed diplopia that was present by the existence of an insufficiency in the interni muscles, the enophthalmus present being produced by depression in the floor of the orbit. Speville, of Paris, [118] Mar.4,'94 reports an instance of complete paralysis of the third nerve in a child 4 years of age. In the absence of any other symptoms, the author thinks that the paralysis was due to an infectious process of an undetermined nature which

had involved the entire nerve. The case terminated successfully under inunctions of mercury.

Couëtoux, of Nantes, [171 Aug.,'94] states that the cause of many ocular affections among printers is due to oscillations in the source of illumination, and not to its intensity. Although electricity is the better illuminating agent, there is no reason why gas should not be employed if the disadvantages of the latter be avoided in some especial manner.

To save time and annoyance in testing for heterophoria, Gould, of Philadelphia, [1018 Jan.,'94] has introduced a mechanism by which a double row of different-strength prisms can be readily brought before the eyes. Jackson, of Philadelphia, has devised a triple, rotary, variable prism, employing for this purpose two rotary prisms



BAXTOR'S PHOROMOTERIC SLIDE.

Archives of Ophthalmology.

of 7.5 centrads each and a fixed prism of 15 centrads. An effect may be produced by this combination from zero to 30 degrees centrads, by arranging the prisms in such a way that the components increase with the sines of the angle which neutralize each other, and the components diminish with the co-sine of the angle which is available for use. A *phoromoteric slide* has been devised by Baxtor, of Bangor, [249 Jan.,'94] which adapts itself readily to the detection of anomalies in the extra-ocular muscle. It consists of two large rotary prisms the apex of one of which is placed vertically and the other horizontally. By means of this contrivance the necessity of constantly shifting the position of the prism is abolished. The accompanying sketch represents a *centring instrument* devised by Bumstead, of Decatur, Ill. With the eyes at the rest, *E*, two cross-wires on the frame, *F*, are made to intersect at the

figure *H*, placed three metres away, with each eye separately. By means of this contrivance the centres of the glasses are readily ascertained. Landolt, of Paris, $\frac{274}{\text{Dec.,'98}}$ has invented an instrument to which he has given the name of *ophthalmotrope*, by means of which the direction of the ocular movements may be studied and demonstrated. It consists of a schematic skeleton eye, represented by a cornea with horizontal and vertical meridians that are suspended by the extremities of the axes of rotation of its muscles in two fixed rings, of which one is vertical and the other is horizontal. Not only the direction but also the degree in each of the three movements of vertical and lateral rotation, as well as rotation around the antero-posterior axis, are plainly shown. Upon

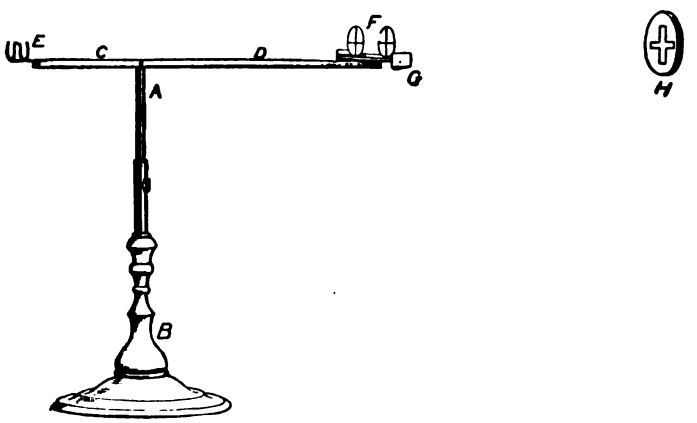

CENTRING INSTRUMENT. (BUMSTEAD.)

the posterior surface of the schematic cornea the vertical meridian is painted in red. This red line, when viewed from behind, shows the position of the false image when paralysis of any of the muscles is present. He has also made an ordinary rubber ball with a representation of a cornea with vertical and horizontal meridians painted upon it. The anterior extremity of the axis of the two oblique muscles is marked at a point on the horizontal meridian thirty-nine degrees from the anterior pole, whilst at sixty-three degrees on the opposite side the axes of the superior and inferior rectus muscles are designated. In order to show the action of any of the muscles—as, for example, the superior oblique—a compass is taken and one arm fixed at the anterior extremity of the axis of the muscle, whilst the other is made to describe a circle by passing

through the summit of the cornea, the position of which, after a movement to any degree, may be ascertained by tracing a line forming at the centre an angle of the same degree as that to which it has moved, with the horizontal axes below if for the superior oblique, above if for the inferior oblique.

DISEASES OF THE LIDS.

Panas, of Paris, [274 Oct.,'93] has found that *cultures taken from the edges of the eyelids* in ten healthy subjects with normal eyes produced colonies of staphylococcus albus or aureus in every case; these, inoculated into the cornea of rabbits, produced abscess of the cornea and in one case suppuration of the eye. The same experiments performed after the lids had been washed with a watery solution of biniodide of mercury gave the same results after some delay. Painting the lids with biniodide in oil reduced the number of cultures. The best results were obtained by prolonged application of the biniodide. All cataract patients, the night before operation, had their lids carefully washed with a solution of bicarbonate of soda to remove the fat; the conjunctival sac was next washed with a solution of the biniodide. Biniodide of mercury in oil, 4 parts in 1000, was then carefully brushed upon the edge of the lids. The eye was kept excluded until the time of the operation. The results of the method have been excellent, and no case of infection has taken place. Sous, of Bordeaux, [188 Oct.8,'93] reports a series of cases of *foreign body in the lids*, and reviews the literature of the subject. Hansell, of Philadelphia, [119 June 16,'94] has observed inflammation of the skin and infiltration of the subcutaneous connective tissue in a young woman, from the instillation of a solution of duboisia sulphate into the eyes.

Rolland, of Toulouse, [173 Jan.,'94] cites an instance of primary *chancre* of the lower lid followed, in two months, by an erythematous rash. The patient was a man 50 years old. Vignes, of Bordeaux, [73 Feb.24,'94] reports a case of syphilitic chancre of the lid in a patient affected with mucous patch of the genitals and anus.

Ayres, of Cincinnati, [347 Dec.23,'93] has obtained excellent results in the *treatment of blepharitis*, especially where ulceration existed, by applying dioxide of hydrogen daily to the affected parts. Ayres, of Cincinnati, [347 Feb.,'94] has found hydrogen dioxide of value in the treatment of blepharitis marginale. After the eye has been

cocainized the drug is applied to the lid upon a cotton tampon. The treatment should be persisted in daily. Essad, of Constantinople, [173 Apr.,'94] has for the past two years successfully employed the treatment recommended by Despagnet (ANNUAL, 1893) in all forms of blepharitis.

Fukala, of Pilsen, [190 Oct.,'93] agrees with Fuchs in the belief that *chalazia* are the result of a closure of the opening of the Meibomian glands with consecutive irritation and inflammation of the walls of the gland itself and the neighboring structures. He has never found any trace of micro-organisms in these formations. Chalazia developing after the use of atropia are due to the chemical action of the drug on the openings of the gland, and may be called *collyria chalazia.* Deyl, of Prague, [57 Apr.2,'94] believes that the specific bacillus of chalazion is a pseudodiphtheritic bacillus of Lœffler, and that a scrofulous diathesis is an attending factor in its production. Manfredi, of Pisa, [173 Aug.,'94] as a result of numerous observations, is convinced that chalazion is not a tubercular formation, but that the giant-cells are simply the product of degeneration.

In order to escape the hæmorrhage which obscures the site of operation in *canthoplasty*, Czermak, of Innsbruck, [353 Mar.,'94] passes a long-armed artery-forceps over the skin of the canthus. Sutures are then buried on each side of the forceps. The instrument is now withdrawn and the tissues are quickly cut through. In cases where the conjunctiva is scanty and canthoplasty is indicated, Gifford, of Omaha, [249 Jan.,'94] employs two small Thiersch flaps to cover the cut surfaces produced by the incision.

Noyes, of New York, [2035 '94] has overcome the deformity of *epicanthus* associated with a deep depression over the root of the nose by a canthoplasty followed by a plastic operation which removes the crescentic folds and elevates the bridge of the nose. After the performance of the first procedure, two parallel and vertical incisions, one centimetre apart, are made at each side of the median line over the nose. From the middle of each of these incisions a rectangular flap is cut toward the inner canthi. After the lateral flaps are freely loosened and the central bridge of skin over the nose dissected up, the former is passed under the latter and the stitches are introduced through the three superimposed layers.

Germaix, of Algiers, [173 July,'94] gives the following steps of an *oper-*

ation devised by him *for* the cure of *distichiasis:* 1. Dissection of the anterior layer containing the bulbs of the cilia until the bulbs appear. 2. Cauterization of these latter. 3. Continuation of the dissection until the tarsus is exposed to the height of six or seven millimetres. 4. Ablation of a muscular cutaneous flap taken from the lid, bringing the suspensory ligament into view. 5. Sutures passed in the suspensory ligament and made to embrace the ciliary body by loops. 6. Tying of the sutures to the superior edge of the ciliary border, which is then to be co-aptated with the superior part of the lid, but without sutures.

Stephenson, of London, $^{2}_{\text{Dec.22,'93}}$ has observed congenital trichiasis of the lower lids in brothers. In the younger subject both eyes were affected and in the elder the right eye only.

A new *operation for trichiasis and distichiasis* is described by Watson, of London. $^{2}_{\text{July 14,'94}}$ A bridge is formed by incisions parallel to one another and the margin of the lid, including within it all of the faulty eyelashes; a "button-hole" lying horizontally above the margin of the lid is thus formed. Into this "button-hole," a button marked out in the skin immediately above it by a semilunar incision is turned in and sutured into place; the band of skin thus formed soon becomes partly mucoid in character at the margin of the lid, removing the lashes from the cornea and giving them an horizontal direction. Fernandez, of Havana, $^{274}_{\text{Feb.,'94}}$ operates for the same conditions by advancing the upper lid. He incises the external commissure by detaching the superior lid to the extent of one centimetre, places under it a short flap dissected up from the temple, and sutures the commissure, one centimetre of flap remaining under the lid. He reports six cases thus successfully treated.

In operating for *entropium*, Thomalla $^{190}_{\text{Oct.,'93}}$ excises two millimetres of skin from the outer margin of the lid and inserts two sutures, but does not tie them. In operations on the lower lid he passes one end under the skin and the needle through the margin of the lid at the upper lip of the wound, fastening the under end of the suture to the cheek by means of collodion. In a case of spastic senile entropium, which had relapsed after the performance of a Hotz operation combined with the removal of a piece of skin, Bettman, of Chicago, effected a cure by performing canthotomy.

Noyes, of New York, $^{2035}_{\text{'94}}$ has obtained excellent results in a

case of ectropium of both eyelids following a burn, by transplanting a flap upon the lids large enough to cover them both. This flap was obtained from the arm, according to Wolfe's method. Fukala, of Pilsen, [171 Jan.,'94] has had good results from the operation proposed by him some years ago, for the cure of senile ectropium and that form of the disease consecutive to blepharitis. In cases of extensive ectropium, Gifford, of Omaha, [249 Jan.,'94] has obtained satisfactory results by first adjusting a Wolfe flap, and adding a Thiersch graft to it after the usual necrosis of the superior layers had taken place.

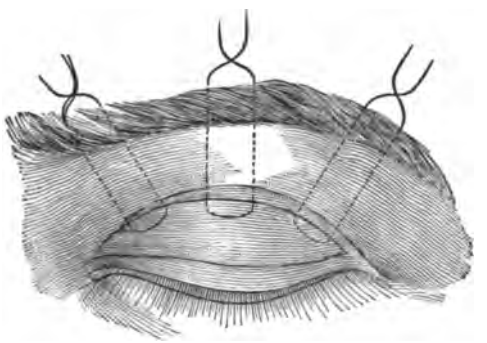

FIG. 1.



FIG. 2. FIG. 3. FIG. 4.

OPERATION FOR PTOSIS. (HESS.)
Archiv für Augenheilkunde.

Parker, of Charleston, [43 Jan.,'94] operates for ectropium of the lower lid by excising a broad area of conjunctiva from the entire length of the *cul-de-sac*, and attaching the conjunctiva to the ciliary border of the lid to the bulbar conjunctiva just below the cornea. After several weeks the *cul-de-sac* re-forms.

A case of *blepharophimosis* consecutive to trachoma has been successfully operated upon by Noyes, of New York, [2035 '94] by the introduction of flaps of skin into the outer angles of the lids after the method previously described by him.

The above illustrations represent a new operative procedure,

successfully employed in ten instances by Hess, of Leipzig, [254 Dec.,'93] for the relief of *ptosis*. After the eyebrow has been shaved a curvilinear incision is made through the skin and subcutaneous tissues (Fig. 2, *a*, *a*) in its whole length, and following its curve so that the scar may be hidden by the subsequent growth of hair. The skin and the subcutaneous tissue of the lower flap are now dissected up nearly as far as the ciliary margin, as shown in Fig. 2. Three double-needled sutures are passed from without inward through the skin only, and are brought out in the space made by the previous dissection. After the stitches have been pulled upon, causing the skin in the upper lid to become folded upon itself, the needles are passed deeply under the upper border of the incision in the brow and brought out a few millimetres above, where they are tied over small rows of plaster. The stitches are removed after eight to ten days. Figs. 3 and 4 represent a diagrammatic section of the lid before and after the tightening of the sutures.

To obviate some of the disadvantages of Panas's operation, Pergers, of Maeseyck, Belgium, [353 Jan.,'94] has proposed certain modifications of the above procedure. A curved incision is made three millimetres above one canthus to the other, just below the orbital border, and the skin dissected up. The skin under the eyebrow is undermined in its entire length by a double-pointed knife. A double needle-thread is passed through the summit of the flaps, and is carried up under the brow to a point above it. Traction is made on the suture so as to bring the flap into position. Similar sutures are placed at the extremity of the flap. A second incision is made directly above the ciliary border and parallel to it, and its lower lip is sewed to the upper lip of the first incision by a number of sutures, which are made to include the tarsus.

Derby, of New York, [2035 Jan.,'94] has removed a growth resembling an epithelioma from the region of the inner canthus. Microscopical examination, however, proved it to be a *cylindroma*. The patient, a man aged 65 years, had had a growth removed from the site of the tumor thirty years previously. A microscopical examination of this growth had not been made. The cylindroma was provided with a partial epithelial covering, which showed a tendency to undergo colloid degeneration. The greater part of the tissue, however, was composed of irregular cylindrical and club-shaped hyaline masses, anastomosing freely. The walls of the

arteries had undergone hyaline change, whilst those of the veins were almost reduced to a layer of endothelium. Noyes, of New York, [2035/94] gives the notes of a case of *epithelioma* of the lower lid, in a female 63 years old, which recurred after the removal of a primary growth and required enucleation of the globe and partial exenteration of the orbit. A third growth appeared somewhat later, and microscopical examination proved it to be a fibroid sarcoma.

Sourdille, of Paris, [274/Mar.,'94] has studied a case of *primary epithelioma of the Meibomian glands* occurring in a man 59 years old. When first seen the growth was mistaken for a chalazion and increased rapidly in size after a curetting operation had been done for its removal. A microscopical study of the disposition and form of the cells, their reaction, great vitality, as shown by the number of nuclei, the presence of mucous globules forming the centre of veritable epithelial lobules, and the union of the neighboring acini with absorption and almost complete disappearance of their fibrous capsule, clearly established the primary intra-glandular epitheliomatous nature of the growth. From a diagnostic stand-point, the advanced age of the patient, the hard consistency of the tumor, the lancinating pains which accompanied its development, its rapid evolution, its tendency to adhere to the neighboring skin and to early perforate the conjunctiva, the presence of grayish granules, hard and bleeding easily, and the engorgement of the preauricular glands, all would favor epithelioma. However, the microscope alone can with certainty decide the diagnosis. Zimmerman, of Philadelphia, [76/June,'94] reports a case of primary *melanotic sarcoma of the eyelid* occurring in a man 50 years old. The growth had appeared eleven months previous to its extirpation. From the microscopical examination the author thinks that the tumor originated in the Meibomian glands.

DISEASES OF THE CONJUNCTIVA.

In order to ascertain the *ability of the conjunctiva to absorb virus*, Comte, of Toulouse, [14/Nov.1,'93] performed a series of experiments. He was unable to inoculate an animal with hydrophobia unless the poison was in contact for at least one hour; the virus of glanders was absorbed at the end of thirty minutes, while that of cholera was taken up very rapidly. In every instance the absorption was

the more certain the longer the virus was in contact with the conjunctiva.

From one hundred and thirty experiments to determine the *antiseptic power of different chemical agents when instilled into the conjunctival sac*, Franke, of Hamburg, [204 B.M.J.] has been led to conclude that: 1. Conjunctivæ which appear perfectly normal may contain micro-organisms of a pathogenic nature. This is particularly true of the ciliary border of the lid. 2. On this account it is necessary to thoroughly disinfect the conjunctival sac before every operative procedure. 3. All three antiseptic remedies made use of are about equal in their advantages and disadvantages. 4. Perfect asepsis is impossible, and in only 24 per cent. of the cases was there a diminution in the quantity of the micro-organisms. 5. The effect of the solution is probably confined to those germs which are situated in the superficial layers of the epithelium. On this account, a remedy capable of dissolving mucus should be applied to the conjunctiva before washing with the antiseptic is commenced. Irrigation with neutral remedies, such as sodium chloride, during the operation is useless. 6. Pathogenic germs which are not killed by the antiseptic are just as harmful as those micrococci which have not been subjected to irrigation. The author gives a list of the various cocci and bacilli found by him in conjunctival sacs.

Baltus [220 Jan. 20, '94] gives the notes of a case of *spontaneous subconjunctival chemosis.* The patient was a female, 23 years old, and had presented symptoms of indigestion, congestion of the face, and severe cephalalgia. The author is inclined to attribute the condition to an active vascular dilatation acting upon the eye through the medium of gastric excitation. Berry, of Edinburgh, [76 Mar., '94] has seen a definite and rare form of *bullous conjunctivitis* signalized by the presence of irregularly-stellate cicatrices upon the tarsal surface of each upper eyelid. The patient was a female 47 years old, and had had a herpetic dermatitis of the face and shoulders, with swelling of the eyelids, a year previously. At that time she could feel "little bladders" lying under the skin of the lids. Albrand, of Berlin, [353 July, '94] reports a case of *pemphigus of the conjunctiva* in a 17-year-old female. The patient was in poor condition, and had had attacks of the disease since the age of 8 years. In spite of a local sedative treatment, the objective symp-

toms increased. The conjunctiva atrophied, and the cornea, which was softened, perforated in several places and presented a staphylomatous appearance. Sachsalber, of Gratz, [204/'94] has made a microscopical study of a section of conjunctiva affected with this disease. The most striking change was in the thickness of the epithelial layer, which sent down more or less long epithelial processes into the subconjunctival tissues. In many places a thread of subconjunctival tissue filled with blood-vessels could be followed into the horny portions of the epithelium, which was not separated from the subconjunctival tissue by any limiting membrane, but formed a thick layer of small cylindrical cells. The subepithelial connective tissue was very vascular, and was remarkable upon account of its lack of adenoid characteristics and marked development of its fibrillary elements.

Hirschberg, of Berlin, [190/Feb.,'94] points out that *ophthalmia neonatorum* was not unknown to the ancients, and quotes a passage from Aëtius to substantiate this view. Hilgartner, of Texas, [143/Aug.,'94] urges the necessity for proper legislation to insure the immediate treatment of ophthalmia in the newborn. Stephenson, of London, [22/May 30,'94] considers proven the proposition that the contagion of ophthalmia is often spread by imperfect washing arrangements, and that the disease is apt to occur among any congregation of people. He believes it possible to guard against the former condition by erecting such apparatus for washing and bathing as to render the use of water by more than one individual an impossibility. Gorecki, of Paris, [173/June,'94] states that ophthalmia neonatorum is not epidemic, and that the physician should not be required to declare it as such. Friedenwald, of Baltimore, [81/July,'94] has observed a haziness of the corneæ and pus in the eyes of a baby one hour after birth. The bag of waters had remained intact until three or four hours before birth. There were chancroids and venereal warts on the genitals of the mother. It was supposed that the gonococci had penetrated the membrane, a supposition not shared by the writer. Alleman, of Brooklyn, [157/Nov.,'94] urges the instillation of 1-per-cent. solution of nitrate of silver into the eyes of all newborn babes. In the treatment of ophthalmia neonatorum, Grady, of Nashville, [86/Dec.,'93] recommends that the palpebral conjunctiva be washed with a 1-per-cent. solution of nitrate of silver, the drug being allowed to remain in contact with the membrane for twelve seconds before

being washed off. Grandclement, of Lyons, [211 Jan.28,'94] thinks that in all cases of blennorrhagic conjunctivitis the gonococcus should be sought for; for if strong solutions of silver be employed in purulent conjunctivitis which is not gonorrhœal, the liability of the cornea to suppuration is increased.

Wallace, of Philadelphia, [112 Jan.,'94] has made a microscopical examination of a section of conjunctiva taken from a case of purulent ophthalmia. He found masses of leucocytes around the bases of the papillæ, the lateral walls of which were thickened by proliferated epithelium. The cells had been wedged apart by the leucocytes in places, giving egress to these latter by the formation of long channels. The author states that ulceration of the cornea is produced by the corpuscles invading that membrane, entering the eye through the canal of Schlemm. He has found that unless silver nitrate is applied to the conjunctiva in the form of the mitigated stick its employment is futile. Trousseau, of Paris, [173 May,'94] has made a bacteriological examination of the contents of the conjunctival sac after it had been subjected to several diverse measures of antiseptic lavage. He has found the streptococcus seven times after the employment of distilled water, three times after cyanide, and once after sublimate. The staphylococcus aureus persisted once in spite of the cyanide, the albus six times; the streptococcus was seen three times in an isolated form when distilled water had been employed, after the cyanide once. In spite of two washings with cyanide and two with sublimate the streptococcus and staphylococcus albus were associated four times.

In the treatment of the milder forms of conjunctivitis, de Schweinitz, of Philadelphia, [347 Jan.,'94] sprays the membrane with a solution of boric acid and salt, the good effects of this plan being probably due to the fact that the liquid thus applied penetrates the deeper tissues and correspondingly increases the extent of the contact and prolongs the action of the drug. In a refractory case of phlyctenular conjunctivitis in a girl 15 years of age, Maberly, of Pechan, [2 Nov.4,'94] obtained rapid improvement by having the eyes bathed with hot milk and water. Hot foot-baths, diaphoretics, and purgatives were also employed. De Schweinitz, of Philadelphia, [119 Apr.7,'94] considers frequent washing of the eyelids and surrounding skin with warm water and Castile soap the most efficacious home-treatment for catarrhal conjunctivitis. In the treat-

ment of fifteen cases of purulent ophthalmia, Campbell, of Detroit, [816 Dec.,'98] obtained good results by the mild and antiseptic method (silver, 5 grains—0.32 gramme; corrosive sublimate, 1 to 5000). Scott, of Cleveland, [61 Sept.15,'94] claims to have had uniformly successful results in the treatment of this disorder, when seen before involvement of the cornea, by the employment of a solution containing sulphate of hydrastine, 5 grains (0.32 gramme); boric acid, 5 grains (0.32 gramme); biborate of soda, 5 grains (0.32 gramme); deodorized tincture of opium, ½ fluidrachm (2 grammes); distilled water, 1 fluidounce (31 grammes); from four to six times daily, together with frequent cleansing of the *cul-de-sac*, application of ice compresses, and the use of 1-per-cent. solution of nitrate of silver. Abadie, of Paris, [173 June,'94] deprecates the abandonment of silver nitrate. He applies the drug to the conjunctiva as soon as the superficial eschar of the previous application has disappeared.

Reich [249 Jan.,'94] claims to have had satisfactory results from the external use of quinine partially dissolved by muriatic acid.

Burchardt, of Berlin, [190 Nov.,'98] proposes a new method of treatment which has for its principle the removal of the cause of the inflammation from the conjunctival sac and the subsequent treatment of the disease. He abstains from the use of cold compresses and the application of strong solutions of silver nitrate, washing out the gonococci by a particular mode of manipulation of the lids whilst a stream of silver-nitrate solution is passed between them. If there is much pus, it is first removed by washing the eye with a 5-per-cent. solution of chlorine-water. All collyria are used lukewarm. The patient is made to lie on his back, the surgeon moving the under lid rapidly up and down and the upper lid slowly from side to side, while an assistant permits the solution to flow in from the inner canthus. This manipulation lasts from one-half minute to a minute, and should be performed not less than four times a day, compresses of chlorine-water being maintained during the intervals. The author claims to have cured cases of ophthalmia neonatorum of five and six days' standing in four days' time, in spite of the fact that in one instance deposits of a diphtheritic type were found in the conjunctiva.

Woods, of Baltimore, [1018 Apr.,'94] believes that silver nitrate is responsible for many of the corneal opacities following purulent conjunctivitis, and that the clinical condition demanding the non-use or

discontinuance of silver is: conjunctival purulency, unaccompanied by the swelling or tension of the lids characteristic of infiltration, and without papillary swelling of the conjunctiva, or much of it, on the upper lid, and the deep-red color seen in the conjunctiva in severe cases. Woodston, of Birmingham, Ala., [647 June,'94] considers the operation of paracentesis of the anterior chamber, in threatened perforation of the cornea in purulent ophthalmia, as harmful, because it aids the passage of bacteria into the interior of the eyeball.

Two cases of *abscess of the subconjunctival tissue* and of the lids, occurring during the course of a purulent conjunctivitis, have been seen by Berger, of Paris. [274 June,'94] The author believes that abscesses of this character are analogous to those which complicate purulent urethritis. In the first instance the patient thought that he had contracted the disease from a public opera-glass. Rohmer, of Nancy, [173 June,'94] cites an instance of intense conjunctivitis due to animal infection. A bacteriological examination revealed the presence of streptococci of no unusual characteristics.

Sourdille, of Paris, [274 Apr.,'94] concludes that there is no essential point of difference between *croupous and interstitial conjunctivitis*, that both are the result of the same process, but in the one case the lightness of the infection or the resistance of the tissue produces the superficial variety. From a clinical stand-point, however, it is well to maintain a distinction between the two forms, on account of the difference in the treatment. Guibert [274 Oct.,'93] cites an instance of *chronic pseudomembranous conjunctivitis* in which the bacteriological examination revealed the presence of staphylococci and streptococci. The case was that of a child, 7 years of age, who had had a membranous inflammation of the left eye since the age of 3 months. The numerous relapses, the long duration, and the final loss of the left eye gave evidence of the gravity of diphtheritic conjunctivitis and emphasized the fact that the disease is not so benign as is usually supposed.

Bourgeois and Gaube, of Reims, [173 Jan.,'94] have observed an instance of *pseudomembranous conjunctivitis* in which the inflammation was so intense that evisceration of the globe was necessary. Bacteriological examination failed to reveal the presence of any bacillus other than the streptococcus. Valude, of Paris, [171 Feb.,'94] describes an hyperacute form of pseudomembranous conjunctivitis. The cases observed by him thus far have been in the newborn. In

the course of a catarrhal conjunctivitis without any premonitory symptoms the conjunctiva and cornea were covered by a dense, yellowish-gray membrane, the lids being enormously thickened and hardened. The membrane was detached with difficulty, and left a bleeding surface. The cornea was prone to perforation. This condition persisted for about a fortnight, when the membrane became detached in fragments and the mucous membrane appeared bleeding and eroded. Catarrh ensued, disappearing according as the cornea had been affected. This local condition was accompanied by a slight general febrile one. The author regards this form of conjunctivitis to be one of transition between the pseudomembranous and the diphtheritic varieties. The association of the staphylococcus and the bacillus of Lœffler gives rise to pseudomembranous conjunctivitis, whilst the union of this latter bacillus with the streptococcus occasions the graver forms of inflammation. He divides the disease into four clinical heads: 1. *Croupous conjunctivitis*, the pseudomembrane being nothing more than an epiphenomenon in the catarrhal process of the conjunctiva. This should be designated as *simple or catarrhal pseudomembranous conjunctivitis.* 2. *Chronic pseudomembranous conjunctivitis.* But a few instances of this disease have been reported. Its characteristic signs are: a thick, gray, false membrane, covering the underlying conjunctiva to a greater or less extent; the false membrane may exist for months, and after it disappears leaves the mucous membrane uninjured; the cornea may be slightly altered, but generally escapes. 3. *Hyperacute pseudomembranous conjunctivitis.* 4. *Interstitial pseudomembranous conjunctivitis* (the diphtheritic form of Graefe). Silver and other cauterizing agents should be avoided in all forms of the disease. The bichloride of mercury should also not be employed, and cold applications and scarification are most harmful. Warm irrigation is the essential basis of his treatment. A pint (½ litre) of a solution of extract of opium is to be used every hour, and asepsis of the conjunctival sac obtained by the introduction of iodoform ointment twice a day. When the discharge becomes profuse, terpinol should replace the iodoform.

In the six cases of pseudomembranous conjunctivitis recorded by Sourdille, of Paris,[274 Jan.,'94] which comprise the two clinical varieties of this affection that have already been described,—*i.e.*, superficial

croupous conjunctivitis and true diphtheritic conjunctivitis,—the bacillus of Lœffler was found. The latter variety of inflammation has a bacillary origin, and should always be treated with great care and energy. Lœffler's bacillus was never found isolated, but always associated with the staphylococcus or the streptococcus,—at times with both, or with other cocci, including the diplococcus. The most benign cases were those where the bacillus of Lœffler was associated solely with the staphylococcus, the disease occurring clinically under the croupous type. The association of microbes plays an important part in the intensity of ocular inflammations, the gravity of the infection in the diphtheritic variety depending at least upon two factors,—polymicrobic association and the virulence proper of the bacillus. The affection is particularly one of the palpebral conjunctiva, and the attendant ulceration of the cornea is due to the secondary infection of that membrane by the streptococcus, this latter complication being favored by the alteration in the general system of the diphtheritic subject occasioned by the slight but real vascular disturbance of the conjunctivitis and by the epithelial alterations of the cornea from the irritation of the conjunctiva as well as the action of the indurated lids. In the treatment of this affection the author has abandoned the use of silver nitrate, and has found lemon-juice to be of real service. A concentrated solution of carbolic acid appears to have a somewhat specific action against diphtheria, and he prefers it to any other antiseptic, in the strength of 2 grammes (31 grains) of the drug to 20 grammes (5 fluidrachms) of glycerin. In case of corneal complication the ulcer is treated as one of an ordinary infectious variety. The author has never had a single perforation follow this plan.

In the treatment of *fibrinous conjunctivitis*, Van Der Berg, of Brussels, [17] Feb. 25, '94 believes that cauterization with silver should never be, and scarification but rarely, used. In some few cases ice compresses are of advantage; more usually, however, antiseptic solutions are indicated.

In regard to the *relationship* existing *between trachoma and purulent ophthalmia* as they occur in Egypt, Demetriades, of Alexandria, [171] Jan., '94 states that there is no doubt that the gonococcus is not the cause of the purulent ophthalmia in that country. The microbe, by its pyogenic action upon the conjunctiva, paves the way for the microbes of trachoma whenever it is associated with

that pathogenic agent, as yet unknown. The trachoma in Egypt is exactly similar in evolution and character to the European form of the disorder.

Hopgood $^{2}_{\text{Mar.2,'94}}$ expresses the opinion that *contagious ophthalmia* in English high-class schools is the same as seen in pauper schools and work-houses. Epidemic follicular ophthalmia is due to one cause, and if neglected will end in trachoma. Follicular conjunctivitis may run into granular lids. Slight enlargement of the follicles is a personal peculiarity, and not an evidence of disease. Numerous cases of enlargement of the follicles exist with no symptoms of previous inflammation, no inconvenience to the patient, and no secretion. Catarrhal ophthalmia runs through families, and is attended by patchy congestion of the ocular conjunctiva. Catarrhal ophthalmia is contagious, but is easily cured and runs a shorter course, and, when follicles are enlarged, they are secondary.

To facilitate the differential diagnosis between the acute forms of purulent, catarrhal, and granular conjunctivitis, Juler, of London, $^{2}_{\text{Sept.15,'94}}$ advises an immediate microscopical examination of the conjunctival discharge. He has found the gonococcus of Neisser present in twenty-four instances. In connection with Griffith, he has studied the discharge in catarrhal conjunctivitis, and has frequently found an organism similar to that described by Weeks and Kartulis. He believes that in chronic conjunctivitis the excessive formations of granulations in the *cul-de-sac* point to trachoma, but that their actual formation in the palpebral portions of the conjunctival membrane is proof positive of that affection. For performing expression, Stafford, of New York, $^{645}_{\text{Nov.,'93}}$ prefers roller forceps, the cylinders of which are made smooth to prevent laceration of the conjunctiva.

Truc $^{171}_{\text{May,'94}}$ studied the general characteristics and contagiousness of *trachoma* in the vicinity of Montpellier, France. Among 10,000 public patients he found the disease in 10 per cent. of his cases, whilst in his private practice the disease occurred in but $\frac{1}{10}$ per cent. It affected those suffering from malnutrition of different kinds. The proportion of subjects who escape the affections in families suffering with the disease was 48 per cent. for Montpellier, 60 per cent. for Cette, and 63 per cent. in the neighboring villages, this difference in the percentage being due to the better

moral and sanitary conditions of Cette. In spite of their intimate association, the disease did not show any undue disposition to spread from husband to wife, or from parents to children, and *vice versâ*, but, for precautionary measures, he isolates all acute and subacute cases suffering with purulent or muco-purulent discharge. Vigier, of Algiers, [171] July,'94 has examined the eyes of 16 Algerian families, 61 persons in all, 30 of whom were affected with the disease. Of 10 cases of contagion, the disease was communicated in 5 instances from the children to the parents; in 4 it was communicated from parents to children. Contact, frequent and very prolonged, seemed to be necessary for conveying the affection.

Omeltschenko, of Kieff, [190] Apr.,'94 in studying the pathology of the disorder, hardened sections in Fleming's solution, and finally imbedded them in photoxylin. He found that the granulations differed in their histological structures from lymph-follicles, as they consisted for the greater part of polygonal cells of an epithelial type, without any trace of frame-work. In the immediate neighborhood of the epithelial layer of the conjunctiva and of the deeper epithelial growths there was a diffuse infiltration of leucocytes,—the sign of a reactive inflammation. In addition to the extraordinary richness in the number of vessels possessed by the growth, there existed a degeneration of the endothelial lining and a sclerosis of their walls. Trachoma is, therefore, in his opinion, a precise pathological process *sui generis*, the essential feature of which consists in an alteration of the epithelium of the conjunctiva, more especially of the cells constituting Henle's glands. Truc, of Montpellier, [173] Apr.,'94 distinguishes three varieties,—mucoid, fungoid, and sclerotic. The lymphatic system plays an important rôle in its production, and a strong relationship exists between it and phlyctenular conjunctivitis.

Tiffany, of Kansas City, [568] Dec.,'93 states that in his experience the majority of trachomatous patients are hyperopic or astigmatic. Tobacco, especially if chewed, is also a factor, and patients having chronic granular conjunctivitis, or trachoma, cannot be cured so long as they continue its use.

Widmark, of Stockholm, [353] July,'94 asserts that in certain parts of Finland trachoma was not less frequent in the last century than at present, while in Sweden the disease has been much less common during the past decade.

A microscopical study of sections of the conjunctiva removed from lids affected with the disease after different operative procedures had been employed has been made by Pergeus, $^{353}_{\text{May,'94}}$ who has shown that operative procedure never destroys the follicles, but only hastens the natural course of the process by emptying them. Le Mond, of Denver, $^{1099}_{\text{Apr.,'94}}$ believes that in 90 per cent. of the cases the real cause of the affection is an uncorrected error of refraction.

In the treatment of trachoma Venneman $^{173}_{\text{May,'94}}$ performs a superficial curetting of the conjunctiva, followed by cauterization with a solution of silver 1 to 500. Lydston, of Chicago, $^{61}_{\text{Sept.29,'94}}$ believes that all harsh surgical measures should be eschewed during the early and transitional stages, and reserved for the correction of the sequelæ. He re-asserts the value of insufflations of papoid and boric acid, both upon the thickened conjunctiva and upon the supervening pannus. Tiffany, of Kansas City, $^{61}_{\text{Feb.24,'94}}$ finds subsequent treatment of the conjunctiva necessary, extending over a period of weeks or months, even after the most thorough use of the forceps. Scott, of Cairo, $^{2}_{\text{Sept.15,'94}}$ has found cyanide of potassium the most potent agent in the treatment of the disease, a 4-per-cent. solution being applied once a day to the conjunctiva and a $\frac{1}{4}$-per-cent. solution instilled two or three times daily. A cure is effected much more rapidly in warm weather, irrespective of humidity, than in cold weather. Willits, of Pittsburgh, $^{9}_{\text{Nov.4,'93}}$ thinks expression the quickest and most effective mode of treatment, especially in the form known as summer granulations. He does not favor the method in the papillary type and in the cicatricial stage of all forms. Montgomery, of Chicago, $^{451}_{\text{Dec.,'93}}$ strongly advocates "expression" in chronic follicular trachoma, and claims to obtain better results by using the thumb-nails than by employing any special forceps. Taylor, of Sherman, $^{73}_{\text{Nov.,'93}}$ has found that mechanical treatment, with or without scarification and impregnation of the lids with corrosive sublimate, does not cure all cases, but benefits and cures the great majority and always abridges the recovery. In rare instances it converts a simple trachoma temporarily into an inflammatory trachoma, but injures no case permanently. Tanner, of Lincoln, $^{106}_{\text{Mar.,'94}}$ believes that canthoplasty should be performed in all cases of long standing, and treatment continued until perfect cure is established. Although refractive and muscular errors cannot be considered as the predis-

posing causes of the condition, his experience has shown that such errors do exist in all cases which have been examined after a cure has been effected, and that in reported correction of these errors no relapses have been said to have taken place.

Gifford, of Omaha, [59 Aug.25,'94] has seen suppression of tear-secretion with resulting xerophthalmia and ulceration of the cornea follow surgical treatment. Trachomatous pannus in particular subsides with great rapidity under such measures, but a non-vascular ulceration, whether superficial or deep, should be considered as positive contra-indication to any extensive surgical interference. Schoenberg, of Kars, [353 Mar.,'94] believes that ectropium complicating trachoma is caused not by the shrinking of the tissue, but by the blepharospasm attending pannus. In order to overcome this deformity he has made use of the following procedure: Three double-armed needles are passed through the conjunctiva, over the middle of the convex portion of the tarsus, under the skin and muscle, to the superior border of the cartilage and the free edge of the lid, where they are brought out directly over the cilia. The sutures are placed above, three millimetres apart. Flarer's procedure is then adopted and the sutures are tightened.

In a case of catarrh of the conjunctiva without well-marked follicles, Kalt [173 June,'94] has found an eruption of follicles upon the mucous membrane of the lachrymal sac, which was enlarged. This condition is not an unusual one, but has escaped notice on account of the difficulty of histological study of this region. Fayrer, of Solon, [239 Oct.16,'93] has observed a *venereal ulcer* of the palpebral conjunctiva in a man with a soft chancre upon the penis. Hodges [293 Mar.,'94] cites an instance of syphilitic chancre of the bulbar conjunctiva in a woman who had contracted the sore from a kiss. Herter, of Frankford, [353 June,'94] has seen two syphilitic patches in the conjunctiva of the same eye, one being situated upon the bulbar conjunctiva directly over the superior border of the cornea, and the second upon the lower outer portion of the limbus conjunctiva. Under appropriate treatment the case made a good recovery.

Schapringer, of New York, [814 Feb.15,'94] removed a flat, reddish growth, two by three millimetres in size, from the limbus of the conjunctiva. Histologically the growth was made up of vascular, thickened, conjunctival epithelium. A case of *angioma* of the conjunctiva which showed evidence of spontaneous cure was

seen by Kroschinski, of Greifswald, [417] in a 7-year-old boy. It was the size of a pea and red in color, and grew from the outer angle of the conjunctival sac, to which it was attached by a pedicle three millimetres long. After extirpation the growth was found to consist of numerous vascular spaces bound together by loose connective tissue. The pedicle was covered with epithelial cells similar to the tumor. Its vessels were almost obliterated. The author advances the supposition that primarily the tumor was wart-like, but that, later in its development, the repeated torsion and pulling to which it was subjected gave rise to the formation of a pedicle, which became gradually thinner, and, by a constriction of its blood-supply, produced a spontaneous cessation in the growth of the tumor. He has observed two other similar cases of conjunctival tumors; but, microscopically, one was found to be a pediculated *teleangiatomic fibrosarcoma*, whilst the other was a true angioma. The author points out that if conjunctival growths be pediculated they are more apt to be benign.

A *papilloma of the conjunctiva* is described by Wagenmann, of Jena, [204] in which the diagnosis was only made from the pathological examination, as the tumor had a smooth surface and resembled a bean-like, pedicled growth. The richness of the tumor in goblet-cells in all its parts was particularly noticeable. Schultze, of Frankfurt-on-Ofen, [353] observed two instances of *melanotic sarcoma* of the conjunctiva, both of which originated in the tissue of the corneal limbus. The first case was remarkable for the fact that the individual affected was but 14 years of age, that the growth was of slow development, and that it occurred in both eyes. The tumors were removed. Six months after the operation there had been no tendency to recur. The microscope showed the growth to be a large round-celled sarcoma. The second case was in a woman 61 years old. After a third recurrence of the growth, exenteration of the orbit was performed. The tumor proved to be of the spindle-celled variety. The author points out the liability of conjunctival sarcoma to recur, but states that sarcoma of the corneo-scleral margin appears to be limited, as in neither instance observed by him was the interior of the eye invaded by the disease.

A *lymphosarcoma* of the semilunar fold was seen by Piccoli, of Naples, [173] in a man, 27 years old, otherwise healthy. The

tumor, which had appeared five months before, was elliptical in its vertical axis, quite soft, two centimetres long, and prevented the complete closure of the lids. Rapid healing followed its removal. An histological examination revealed a lymphadenoid tissue, with small foci of hyaline degeneration of the reticulum under the blood-vessels.

An instance of amyloid degeneration of the conjunctiva is cited by Kruch and Fumagalli. [171 July,'94] The disease occurred in an anæmic woman of 25 years, and took the form of an hypertrophy of the lower lid, appearing as an ellipse with its long axis placed horizontally. The tumor was excised, and section of it treated with iodine gave the reaction characteristic of amyloid change. Microscopically, the epithelium was found to be but little altered, while the subepithelial layers exhibited a rich cellular proliferation. The vessels were enveloped in amyloid masses and the adventitia of their walls had degenerated. The staphylococcus pyogenes albus was present, as well as a bacillus which the author regarded as a pathogenic microbe. He concludes that amyloid degeneration of the conjunctiva in man may be independent of the divers processes which precede it in the conjunctiva itself, and may exist as a simple local process without any connection with the general system of the individual. A partial excision of the degenerated tissue may bring about a cure. The elements of the subconjunctival connective tissue contribute, for the greater part, to the production of the amyloid substance. The vessels do not represent the point of departure of the degeneration. Scimemi, of Messina, [173 Aug.,'94] has been able to demonstrate, upon one preparation, the gradual transformation of the coloration of the hyaline substance into the coloration of an amyloid material, and *vice versâ*. He has seen the amyloid coloration change into the hyaline in a tumor of the semilunar fold.

In operating for *pterygium*, Bettman, of Chicago, [61 Mar.31,'94] pursues a plan similar to that of Galezowski, the object being to bring a mucous surface in contact with a raw one. The apex of the growth having been dissected from the cornea, a double-armed suture is passed through the apex from the outside, and is then carried through the base just far enough so that when the flap is turned upon itself the roll will correspond to the corneal margin. The ends of the suture are then firmly tied, thus bringing the

under surface of the pterygium in contact throughout almost its entire extent. In operating for the same affection, Hobbs, of Atlanta, [61 Sept.15,'94] makes an instantaneous application of a fine-pointed cautery-blade at white heat horizontally to the neck of the growth, and re-applies it until the tissues are completely severed. As a precautionary measure it is best, where possible, to have the pterygium raised from the sclera while using the cautery.

Galezowski, of Paris, [178 Feb.,'94] has successfully operated upon three cases of pterygium by a new procedure to which he has given the name of *double conjunctival authoplasty*. After the pterygium has been ablated, the denuded area is covered by two flaps cut from the conjunctiva. These flaps are quadrangular in form with their bases near the cornea, whilst their linear extremities are brought together. Parker, of Charleston, [43 Jan.,'94] gives notes of a successful case of transplantation of the conjunctiva of the rabbit to the human eye for symblepharon associated with stricture of the lachrymal passages.

DISEASES OF THE CORNEA AND SCLEROTIC.

In a case where immediate efforts failed to dislodge a *foreign body* deeply imbedded in the cornea, Theobald, of Baltimore, [11 June,'94] succeeded in readily accomplishing its removal after a lapse of several days, when necrosis had occurred around it. Hasbrouck, of Providence, [776 Apr.,'94] reports four cases of penetrating *wounds* of the cornea, in all of which vision was greatly benefited and relief obtained from reflex symptoms by the wearing of a proper correction.

From an extended experience, Thompson, of Kansas City, [72 Oct.,'93] is led to think that "there is in hay-dust a *materies morbi* which can excite acute inflammation of the conjunctiva and superficial layers of the cornea in chronic diseases of the eyes; and not infrequently that poison can cause an outbreak of acute blennorrhœa in eyes which were previously healthy." Gruber, of Vienna, [204 B.11,H.2] has studied the effects of the deposit of rust in the cornea by placing particles of iron in the corners of cuts. Five minutes were sufficient to make the iron reaction appreciable, metallic iron being chemically irritant, whilst iron oxide was not. The ring of rust found about the foreign body consisted of hydrated oxide of iron, and was chemically innocuous. The corneal epithelium

showed itself to resist extraordinarily the invasion of the oxide of iron.

Nuel, of Liége,[274] Mar., '94 has made a careful anatomical study of sections of the cornea excised from a case of *superficial punctate keratitis.* Clinically, he has found the opacities more often in the periphery of the membrane, frequently there being numerous small, whitish, slightly-elevated points of infiltration about the cornea, whilst in one case the conjunctiva of the lower lid was spotted with small granulations similar to those seen in follicular conjunctivitis. He has also found the disease to be more frequent in winter. Microscopically, the *substantia propria* of the cornea appeared clear. The opacities were composed of a cluster of cones crossing one another in all directions, chiefly, however, parallel with the corneal lamellæ. These filaments, when isolated, were seen to have a spiral form, the smaller ones appearing in the interlamellar spaces. In the punctate opacity itself the filaments were so densely packed that it was impossible to distinguish any cells; but when stained a granular body resembling altered cellular tissue became manifest. The author concludes that the formation of the filaments takes place in the fixed corneal corpuscles. The filaments were found immediately under Bowman's membrane in all the sections, and there were evidences of a serous œdema in all the lamellæ. At first sight the epithelium appeared to be normal between the opacities, but closer examination showed it to be more or less altered. Migratory cells were nowhere visible. The author regards the filaments as hyaline, the change originating in the fixed corneal cells, the filaments growing from these and insinuating themselves between the lamellæ and the corneal fibrillæ. This form of corneal inflammation is an especial variety, differing from the other diseases of that membrane in that it produces a considerable œdema of the anterior corneal layers. This œdema spreads more or less through the cornea and insinuates itself between the deeper epithelial cells, which become changed, the contact between them being broken, and œdematous fluid accumulating in the form of intercellular lacunæ. The œdema is inflammatory in nature. The fixed corpuscles, being bathed in the liquid, become altered and precipitate a hyaline substance. The disease, therefore, is especially characterized by a lymph-stasis of the corneal conjunctiva, and may be

regarded as a kind of lymphangitis of the tissue of the cornea, extending as far as the limbus. The most favorable structures for the hyaline change are the nerve-canals terminating under Bowman's layer. The author attributes the disease to "catching cold," and does not believe that it is of microbic origin. The same author[274 Oct.,'98] has observed frequent polymorphic changes in corneal epithelium, and states that the formation of corneal filaments appears to be one of the special varieties of these changes, to which he has given the name of mucoid and hyaline degeneration without necessarily indicating that such is the nature of the pathological condition. The most marked change was observed in a case of absolute glaucoma, in which the cornea had been roughened and insensible for some months. The surface cells were much flattened and absent in places, whilst the succeeding three or four layers of cells were normal. Underneath these latter they were elongated and flattened and highly refracting, while in the next layer they were of normal size, but, the protoplasm having lost its fibrillary character, were somewhat disassociated. They then gradually increased in size, and the deepest of them were like large, clear vesicles, containing drops of a transparent, homogeneous, liquid substance. A granular crescent surrounded the vesicle formed by the protoplasm. The deepest layer consisted of large, polynuclear, protoplasmic cells. This pathological condition gives a dull appearance to the cornea when viewed clinically. The condition is produced by a hyaline degeneration of the cells, which occur in nests.

The same author also makes[274 Oct.,'98] a further contribution to the study of *filamentary keratitis*, pointing out that the excrescences seen in cases of wounded or ulcerated corneæ are even more polymorphous than those of the idiopathic type. In the former class of cases the filament is provided in its entirety with small, more or less fusiform cells, which are elongated in the direction of the fibrillæ toward which they are directed. These cells have the characteristics of migratory elements and are epithelial in character, many of them possessing the structure of those of typical filamentary keratitis. The author has modified his opinion upon the transformation of the pedicle of the elongated filaments, as he has discovered that, although having the same origin, the envelope of the pedicle is entirely different in its central cable.

The action of toxins upon the lachrymal secretion and their rôle in the *pathogenesis of keratomalacia* in infectious fevers have been studied by Berger, of Paris. [78, May, '94] He has found an unusual dryness of the conjunctiva in cases of typhoid fever, coming on about the second week and disappearing toward the end of the fever. An abnormal absence of humidity of the eye during convalescence, he thinks, is due to a paresis of the secretory nerves of the lachrymal glands and of all the other glands that secrete the lachrymal fluid; this paresis is due in turn to the action of toxins, the production of the fever. Keratomalacia, in the course of different infectious diseases, is dependent upon alteration in the epithelial cells of the cornea, secondary to this dryness. Chloride of sodium in the strength of 4 to 1000 and the application of a bandage are the best means of combating this lesion.

Of 25 cases of *hypopyon keratitis*, Guaita, of Sienna, [173, June, '94] found the diplococcus in 23 cases, either alone or associated with a staphylococcus. In 4 cases the micrococcus occurred in phlegmonous disease of the eye. Bassa, of Geneva, [173, June, '94] believes that, in the majority of instances of this affection, the infectious agent is the diplococcus of Fränkel. In nearly all of his cases the germ was found in the mouth, giving rise to the suspicion of disease in that cavity.

From the microscopical study of the eyes of a boy, 15 years old, suffering from *parenchymatous keratitis*, Hippel, of Heidelberg, [204, B.20, H.2] concludes that in the retrogressive stage, which is characterized by marked vascularization, the cloudiness of the cornea depends upon infiltration with cellular elements and a change in the fibrillary basal tissue, the nature of which is not understood. The clinical picture of parenchymatous keratitis with iritis corresponds anatomically with the disease of all the ocular tissues. It cannot be determined absolutely whether the keratitis in given cases is secondary or whether it is the primary lesion. It is, in all probability, produced by a tubercular infection of the eye, in which case it occurs as a so-called attenuated form of tuberculosis capable of absorption and cure.

Heunicke, of Jena, [353, Apr., '94] has made a microscopical study of several cases of *interstitial keratitis* in bears. The examination showed that the disease originated in the anterior portions of the eye. As it was epidemic among the younger animals, the cause was prob-

ably some disturbance in their general nutrition. Microscopically, there was a thick infiltration of the cells, which lessened at the centre of the membrane. Near the limbus there were fine hæmorrhages. The endothelium was normal. Beyond, in the sclera, there were numerous, fine, round-celled infiltrations. A case of relapsing, non-specific, interstitial keratitis has been observed by Emerson, of New York. [814 Feb.15,'94]

Dujardin, of Bordeaux, [220 Oct.15,'93] has seen a case of instantaneous blindness in a child 11 years old, also affected with *strumous keratitis.* The ophthalmoscope revealed a large extravasation into the choroid in the macular region. Under the continued administration of calomel, vision gradually improved. The author suggests a tubercular origin in this case.

Kamocki, of Warsaw, [204 B.30,H.4] has observed an unusual form of disease of the cornea, occurring in a 42-year-old woman. The disorder was characterized by the appearance of numerous chalky-white opacities under the epithelium of the cornea, and forming a polygon with its convexity directed toward the periphery of that membrane. A zone of fine blood-vessels surrounded the corneal limbus, but there was no ciliary congestion, and the conjunctiva was normal. Both eyes were affected. The subjective symptoms appeared in the form of "attacks" occurring at weekly intervals, and were accompanied by headaches, acute pain, and a burning sensation in the eyes. At the height of the "attack" the eyes became red, sensitive to light, and watery, and the characteristic specks appeared upon the cornea. A microscopical examination of several sections of the affected corneal tissue revealed a peculiar form of fatty degeneration of that layer. The epithelium was normal, but Bowman's membrane was split up into many parts by the pathological process. Numerous nests of cells exhibiting fatty-degeneration change were scattered through the superficial layers, and the neighboring lymph-spaces were enormously distended and filled with large bubble-like cells. The affected area suggested that of recent corneal scar-tissue, but the author was unable to find any traces of cicatrization, either in the stages of quiescence or of irritation. He reports another instance of a somewhat similar disorder in a woman 31 years old. In this case the cornea was partially covered by pannus, and in the centre of that membrane were three limited, superficial, saturated, dull-whitish plaques,

myrtle-leaf in form. On account of the method used in preparing the section, the demonstration of fatty change was rendered impossible, but the author believes the pathology of this case to be identical with that of the preceding. In a case of keratitis seen by Churchman, of Charleston, W. Va., 481 June, '94 the ulceration involved the whole cornea. An examination of the exudate showed it to consist of filaments of the *Aspergillus fumigatus.*

A careful histological study of a rare case of *corneal herpes* has been made by Giannettasio, of Sienna. 274 Jan., '94 Bane, of Denver, 61 Nov. 4, '93 is of the opinion that keratitis dendritica and herpes corneæ are distinct diseases, excited by different causes and requiring different treatment.

From a clinical study of a case of *keratoconus*, and a pathological examination of this condition artificially produced in rabbits, Elschnig, of Gratz, 358 Feb., '94 draws some valuable conclusions in regard to the mechanism of this disorder. In the case observed by him the left eye presented a well-marked opacity at the summit of the cone; in the right eye this opacity was at first absent, and developed under his observation. From its peculiar stripe and fold-like appearance he was led to suppose that the condition might be produced by some interference with the inner layers of the cornea. He accordingly incised the layer of Descemet in a rabbit's eye and saw the characteristic opacity of keratoconus develop a few hours afterward; while in another eye in which the endothelial cells were alone removed the opacity was not marked. He therefore concludes that a lesion in the layer of Descemet is the essential factor in the production of this condition, which is dependent upon some unknown pathological change in the endothelial cells. To support this view he draws attention to the analogy existing between this condition and the production of aneurism by the giving way of the elastic coat of the artery. In treatment the best results are to be obtained by cauterization. In the case reported by him the vision in the left eye was improved by counting fingers at three metres to $\frac{6}{18}$ by this method, whilst in the right eye the visual acuity was raised from $\frac{6}{36}$ with — S. 5.5 D. to $\frac{6}{30}$ with — S. 5 D. He lays stress upon the importance of uniting the cauterized summit of the cone to the corneal limbus by a narrow bridge of scar-tissue at a point where the resulting opacity will least interfere with vision. Campbell, of St. Louis, 776 July, '94 has

successfully employed the galvano-cautery in the treatment of a case of phlyctenular disease of the cornea and conjunctiva which had proved intractable to other methods.

Having noticed that a zone of vascularization around the cornea followed the subconjunctival injection of sublimate solution, Terson, of Toulouse, [171] May, '94 has been led to try this method of treatment in diseases in which this region was unduly injected, and claims to have thus cured a case of episcleritis in a rheumatic subject in whom the disease was unaccompanied by any involvement of the more deeply situated ocular tissues. The injections are contra-indicated when such a complication exists. Fromaget [171] Oct., '96 points out that in the treatment of *corneal ulcers* curetting and antiseptic dressings are indicated in (1) persistent phlyctenular or traumatic ulcers accompanied by intense reactionary phenomena and a tendency to infection, without a disposition to heal; (2) asthenic ulcers; (3) limited infectious ulcers. They are useless and contra-indicated in (1) recent and superficial ulcers with no tendency to infection; (2) ulcers of granular keratitis and infectious ulcers with infiltration of the cornea. Paracentesis should be associated with grattage when there is increase in tension and the depth of the anterior chamber, danger of perforation, and a stubborn hypopyon. In cases of corneal ulcers where the infiltration is not too extensive and deep, Goldzieher, of Budapest, [190] Mar., '94 has successfully employed an ointment composed of natrium, sozoiodol, and vaselin. When atropine or pilocarpine is indicated either may be added. Kugel, of Sofia, [204] B.40,H.2 claims to have seen excellent results follow cauterization of the scleral conjunctiva in many cases of chronic parenchymatous and ulcerative keratitis of an asthenic nature. It is also of value in chronic inflammation of the sclerotic. He employs the mitigated stick of nitrate of silver for this purpose.

In the treatment of *infectious ulcers of the cornea*, Galtier, of Nimes, [171] Mar., '94 has had excellent results, in six or eight cases of this affection, by the employment of the method suggested by de Wecker, viz., curetting, antiseptic irrigation, and occlusion. He considers the occlusion to be the essential part of the treatment, and to be maintained for several days. He has even found this method of value where there is a complication of blennorrhœa of the lachrymal sac. Carpenter, of Stanford, Ky., [112] Nov., '98 has seen rapid

improvement in a case of kerato-iritis follow the cauterization of an hypertrophied turbinate on the same side as the affected eye. In the treatment of *hypopyon keratitis*, McDermott, of Cincinnati, advocates the use of a boric-acid wash, a solution of peroxide of hydrogen (¼), atropine, and a protective bandage. If these measures fail to arrest the disease, he advises a Saemisch operation in preference to the galvano-cautery.

For purposes of treatment, Lang, of Middlesex, divides infected or hypopyon ulcers into four stages: 1. Prehypopyon. 2. Large superficial ulcer, with hypopyon. 3. Increase in hypopyon, with impending perforation of the cornea. 4. Rupture of the floor of the ulcer, with contact or a prolapse of the iris. In the first two stages the ulcer is to be thoroughly scraped and the galvano-cautery applied to the entire infected part, as demonstrated by fluorescin. Atropine salve is then introduced into the eye and a bandage applied. In the third stage the same method is adopted, and the thinnest part of the floor is perforated so as to allow the escape of the hypopyon. Should the fourth stage have been reached, no attempt should be made to remove the prolapse; but if after healing there is any increased tension, an immediate iridectomy should be performed. Bocchi, of Pavia, [173] June, '94 claims that subconjunctival injections of corrosive sublimate are followed by good results in severe ulcers of the cornea. They are, however, less efficacious in the treatment of cases of parenchymatous keratitis, plastic iritis, and primary and secondary traumatic iridocyclitis.

In the treatment of *epithelioma* of the corneo-scleral junction, Fage, of Amiens, [171] Oct., '93 believes that the greatest care is to be exercised in the extirpation of the growth, on account of its tendency to recurrence. Amputation of the anterior segment of the globe should only be performed when the deeper layers of the cornea are affected. When the growth has involved the anterior chamber and iris, enucleation is indicated. Martini, of Rome, [173] Aug., '94 has cured a case of epithelioma of the corneal limbus by injections of sublimate. The case was that of a man, 70 years old, in whom the neoplasm had invaded three millimetres of the cornea by a slow growth. Extirpation of the tumor was followed in two months by recurrence. An examination at this time proved the existence of true epithelioma. Enucleation being refused, subconjunctival

injections of sublimate were made both in and around the tumor, which disappeared, leaving a superficial ulceration that healed in two weeks' time.

Vincentis, of Rome, [173] Apr., '94 has had successful results in four instances of *transplantation of the cornea of rabbits* upon the human eye. Van Milligen, of Constantinople, [173] June, '94 states that *keratoplasty* is without result in *adherent leucoma* with opacities in the lens, and he therefore trephines the cornea as far as the layers immediately over the lens, and applies a contact glass of Sulzer. He claims to have had excellent and lasting results. Bourgeois, of Reims, [173] Mar., '94 has saved an eye from enucleation and preserved one-eighth visual acuity by transplanting a conjunctival flap upon a corneal *fistula*, which had resulted from an extensive lime burn. The flap was obtained from the conjunctiva of the injured eye directly above the wound. The pedicle was allowed to remain undisturbed until the eighth day.

Kostenitsch, of Vienna, [254] Dec., '93 in a microscopical study of an eye affected by *scleritis*, has found that the principal changes consisted in an inflammation and infiltration of the tunics of the organ. This infiltration was particularly well marked in the periphery of the cornea, in the sclerotic, and in the conjunctiva of the inferior nasal and superior nasal sectors. The anterior portion of the sclera in this position was richest in cells. Upon the external surface there were only isolated leucocytes, seen generally in association with the vessels. In the inferior temporal portion all of the scleral and conjunctival layers were affected. The parts of the iris and ciliary body corresponding to the most intense area of scleral involvement were infiltrated by leucocytes. There were also secondary changes which pointed to a previous iridocyclitis and secondary glaucoma which had necessitated the removal of the eye. Demicheri, of Paris, [171] June, '94 reports two cases of gummatous episcleritis, and states that this affection is entirely limited, that it exhibits but a slight degree of reaction, and that there is no outlying ciliary congestion.

Lagrange, of Bordeaux, [274] Dec., '93 has studied three cases of *epibulbar epithelial tumors*. In the first instance extirpation of the growth sufficed to bring about a cure, whilst in the other two enucleation was demanded. The author raises the question of the presence of coccidia in certain of the cells of the tumors, but reserves his opinion in the matter. He points out the danger resulting from

the penetration of the conjunctival epithelium, the cells gaining ready access to the eye through the spaces of Fontana. When the epibulbar tumor is situated at a distance, excision is effectual when followed by cauterization. On the other hand, when the limbus is the seat of the growth, enucleation should be performed if the surgeon has convinced himself of the invasion of the globe by means of a careful digital examination of the base of the growth.

Coggin, of Salem, Mass., [249 Jan.,'94] has removed a *papilloma of the sclero-corneal margin* from a man 60 years old. The growth recurred three times. Buller and Adami, of Montreal, [282 Feb.,'94] describe a *congenital polypoid growth* removed from a child 3 months old. It was attached to the sclera by means of a thick expansion extending slightly into the cornea. Its microscopical structure showed that it corresponded rather with the tissues of the outer surface of the eyelid than with the conjunctiva, but that it was of too simple a nature to be classed as a true dermoid.

DISEASES OF THE IRIS AND CILIARY BODY.

Stephenson, of Hanwell, [22 Oct.25,'93] believes congenital *ectropion of the uvea* to be not uncommon, and divides it clinically into three classes: (1) nipple-like projections from the pupillary margin, (2) pigmented particles lying free in the anterior chamber, and (3) cysts formed by the degeneration of such particles. He regards the condition as "a reversion in type to the anatomical structure of vertebrates lower in the scale of creation."

Howe, of Buffalo, [1154 Aug.,'94] has observed three cases of ectropion uveæ, all occurring in myopic eyes. In two of the instances the condition was congenital and underwent but slight change while under observation. The third was seen in a case of progressive myopia, the growth being first noticed when the patient was 24 years old, the pigment masses being then numerous, and both globular and pedunculated in form. In the course of nine years some of them became sessile, while others underwent absorption. The author considers the two forms as illustrated in the above cases to be simply different stages of the same process, and suggests that the term *papilloma iridis* be given to the condition. The frequency of the co-existence of myopia suggests a relationship between the two, due, possibly, to the distension of the choroid in the elongated eyeball.

Antonelli, of Naples, [30] v.22,Nos.2–5 has studied the *corneal reflexes* in several cases of bilateral *corectopia* by means of Javal's ophthalmometer, and has found that, in spite of a marked degree of eccentricity of the pupil, a part of that aperture always enters upon the corneal zone, which is more or less central and is always included during the usual ophthalmometric examination.

Oliver, of Philadelphia, [112] May,'94 gives the clinical history of a case of successful *extraction of* a piece of *steel from an iris* in which purulent inflammation had been established. There was prompt subsidence of the inflammatory reaction and restoration of full vision. Foltz, of Akron, [192] Dec.,'93 cites a case of *recurrent iritis* occurring in a young woman who was subject to attacks of subacute rheumatism. The ocular symptoms yielded to salicylic acid. Guetin [164] Jan.,'94 does not believe that it is as yet definitely determined whether an iritis can be due to toxins.

Gayet, of Lyons, [211] Mar.4,'94 reports a case of iritis, in a man 46 years old, resisting all treatment, but finally disappearing after an attack of facial erysipelas. Robertson [105] Sept.15,'93 urges the importance of early and frequent instillation of atropine in iritis. Hansell, of Philadelphia, [119] Jan.,'94 has employed discs containing $\frac{1}{1000}$ grain (0.000065 gramme) of eserine in the late stages of iritis, where there have been attacks of blindness due to a blocking up of the angle of the anterior chamber by masses of plastic material thrown out by the iris.

Bansier, of Avignon, [171] Sept.,'94 has employed the *continued current in* eight cases of *old iritis* complicated by synechiæ, currents weaker than 5 milliampères giving the most favorable results. The positive pole is placed behind the ear, whilst the negative one is applied upon the closed eye. Atropia is instilled at each *séance*, which should be about twenty-five minutes in length. The amelioration in vision produced by this plan of treatment is obtained (1) by bringing about partial or complete absorption of the exudates which block up the pupil; (2) by clearing up the vitreous. They increase the efficacy of iridectomy by diminishing the adhesions, while they are of service after the operation by rapidly calming any post-operative inflammation.

Oliver, of Philadelphia, [112] Oct.,'94 has made some additional studies upon the *clinical value of repeated careful correction of manifest refractive error in plastic iritis.* Ignoring any cases where there

were objective evidences of corneal opacity, lenticular haze, or even the faintest visible disturbances in the aqueous or vitreous humors; excluding all instances where there were any perceptible tags of adhesion between the iris and the lens; and, limiting the work to those eyes where the pupils were seemingly dilated *ad maximum*, a number of experimental studies were instituted to determine, if possible, the cause of the ametropic increase. A forward displacement of the lens was shown not to occur, objectively, in two ways. In studying the plane of the iris by ordinary inspection through a corneal loupe upon a brilliantly-illuminated area, it was found that in nearly every instance the anterior plane of the iris was either vertically placed or was dragged backward. Estimation of the relative positions and sizes of the catoptric images, especially of the two lenticular reflexes, showed, either by roughly testing by a candle-flame or, more scientifically, by recourse to an ophthalmometer of Helmholtz, that, whilst the anterior capsular reflex moved forward and became smaller, the posterior one moved slightly backward. Neither the index of refraction nor the actual amount of either the aqueous or the vitreous humor is increased during the inflammatory process. This was shown, first, by careful and repeated study of the objective appearances of successive layers of these two media, by both oblique illumination and the ophthalmoscope. No thickening, no visible sign of increase of density of the fluids, as by planes of increased reflection, and even no distortion of any of the gradually-deepening meridional reflexes could be conscientiously asserted. Moreover, it was shown by reference to the fact that, in nearly every case which was studied, the distance between the anterior and the posterior lenticular reflexes was unduly increased. To make certain that the temporary increase of the index of refraction in the type of cases under special consideration was dependent upon either spastic tonicity of the fibres of the ciliary muscle or congestion with rigidity of the ciliary bodies, a number of control tests, with both mydriatic and myotic agents, were made in such a manner as to set aside any confusion or disturbing influence that might be supposed to have arisen from the first two categories of cases. This was done by first obtaining the exact corrective lens necessary to bring a subnormal vision to normal, care being taken to choose intelligent patients with but slight refractive error. This done, three instillations of two drops

each of strong solutions of either atropine, cocaine and atropine, or eserine were made at three-minute intervals, and the ametropia was immediately re-examined, when, in every case in which the inflammatory process had not absolutely subsided, the use of the cycloplegic reduced the apparent amount of the refractive error (ordinarily $\frac{1}{4}$ to $\frac{3}{4}$ dioptre), whilst the myotic, in every instance tried, increased the apparent amount of the ametropia. To recontrol these tests, all of the eyes, whilst in a condition of surcharged dosage, as it were, were re-submitted to a few of the most important of the objective tests, when, in every instance where the mydriatic was used, the lenticular reflexes were shown to be more greatly approximated, whilst in those cases where the myotic was employed the lenticular reflexes became farther separated. The conclusion, therefore, is that, in every instance of this third variety, not only is so-called "spastic accommodation" proven, but the supposition of the forward displacement of the lens is, in a great measure, disproven, and both real and relative increases of aqueous and vitreous humor are confuted.

Carpenter, of Philadelphia, $^{119}_{\text{May 15,'94}}$ has seen an instance of decrease of myopic refraction in a case of plastic iritis. Alt, of St. Louis, $^{347}_{\text{Oct.,'93}}$ describes a form of iritis which he calls *croupous*, and which is usually ushered in by severe pain and the attendant inflammatory symptoms, and is characterized by the formation of a grayish-yellow, semitransparent membrane in the anterior chamber, hæmorrhages into which are also frequently seen. In the uncomplicated cases the membrane clears away without leaving a trace. Microscopically this is similar to that observed in other croupous affections. From the fact that in a number of instances the author has found clusters of cocci arranged after the manner of the staphylococcus pyogenes aureus, it would seem probable that the condition is produced by some specific form of infection. The notes of three cases of the disease are added. Teillais $^{173}_{\text{May,'94}}$ concludes that hæmorrhagic iritis may be considered generally as a benign complication possessing no individuality.

McCrindle, of Middlesborough, $^{6}_{\text{Jan.20,'94}}$ has seen an instance of *iridodialysis* followed by recovery. The union of the tear seemed to take place through the medium of a blood-clot that had formed on the iris. The detached portion of the iris had a thinner appearance, and seemed to have a more open texture than the

rest of the membrane, being somewhat frayed out at the pupillary border. The damaged portion of the iris did not contract to light-stimulus.

Armaignac, of Bordeaux, $_{Mar.11,'94}^{188}$ reports an obscure case of *tumor in the anterior chamber* complicated by iritis and hypopyon. There was a history of a perforation of the eye twenty years previously. The tumor had been under observation for thirteen years and had caused great annoyance. A bacteriological examination of its contents was negative. The author inclines to the view that the growth was an implantation cyst which had undergone ulceration. Baquias, of Livorino, $_{v.22,Nos.2-5}^{30}$ relates an instance of gumma of the periphery of the iris occurring in the secondary stage of the disease. Schneider, of Milwaukee, $_{Nov.4,'93}^{61}$ removed a tumor of the iris in a 16-year-old girl by iridectomy. The growth, which was reddish-yellow in color and measured nine by five millimetres, had its origin from the pectinate ligament of the left eye and occupied the lower inner quadrant of the iris. Microscopical examination showed it to be a papilloma originating in the subepithelial connective tissue of the iris. Rosenweg, of Vienna, $_{June,'94}^{217}$ reports a case of congenital serous cyst of the iris occurring in a child 3 months old. The growth appeared as a round, pearly-gray vesicle, situated on the iris, its anterior wall being transparent and permitting a thickened iris to be seen beneath it. The cornea was unchanged. The mass was removed by an iridectomy, and its walls were seen histologically to be composed of iris-tissue surrounded by a loose connective material. The anterior wall consisted chiefly of epithelium entirely free of pigment. The author points out the analogy in the formation of the tumor with that of a dermoid cyst, and regards the condition as due to invagination and constriction of the retinal layer of the iris, followed by a later cystoid formation the result of the constriction.

A case of sarcoma of the iris in a girl 14 years of age is recorded by Williamson, of Newcastle-on-Tyne. $_{v.2,p.1204,'93}^{2}$ The growth was of a bright-yellow color and occupied the lower outer quadrant of the iris of the left eye. When highly magnified the surface was seen to be covered with little vascular tufts. An attempt at removal through a corneal incision failing, the eye was enucleated four days later. Microscopical examination showed the tumor to consist entirely of spindle-cells, with imperfectly-developed blood-

vessels, these cells being traced along a vessel into the ciliary body. Sections through the deep part of the corneal incision showed several nests of epithelial cells adherent to the cut surface of the cornea. The author believes that the cells were carried to this position by the knife, and, finding a congenial soil, developed. He sees no reason why cancer-cells should not behave in the same manner when similarly placed, and questions whether an operation for carcinoma may not, for this reason, prove useless as a curative measure.

In regard to the subject of tubercular iritis, Vignes, of Paris, [178 Apr., '94] concludes as follows: 1. It is important, from a clinical point of view, to differentiate a tubercular variety of iritis. 2. This form of inflammation is premonitory of the tubercular nodular eruption, which it may precede by several weeks. 3. It is characterized by its subacute mode of invasion; its evolution is slow and torpid, being marked by faint reactional signs, although in addition there may be dense synechiæ more or less completely obstructing the pupil. 4. The absence of pathognomonic symptoms renders the diagnosis difficult. 5. The tendency to spontaneous cure of miliary tuberculosis of the iris depends upon the individual resistance, and especially upon the resistance of the iris. The incapsulation of tubercle of the iris and the rapid obliteration of the surrounding capillaries favor its isolation and the protection of the sound tissue. It is not the attenuation of the bacillus nor of the toxins which brings about resolution, but the character of the tissue which receives the poison. The notes of three cases of tubercle of the iris are given by Sanford. [2 May 12, '94] In the first instance the ocular affection was coincident with recent similar pulmonary troubles, while in the second it occurred in the course of a renewal of tubercular activity in an old cavity. The third case, one of primary tuberculosis of the iris with involvement of the ciliary region, the suspensory ligament, and apparently of the lens, was seen in a child 5 years of age. Excision of the globe was followed by marked improvement in the health of the patient. An instance of the primary form was seen by Velhagen, of Göttingen, [353 Apr., '94] in a boy, 8 years old, otherwise apparently healthy. The disease manifested itself clinically as a yellowish prominence on the external half of the iris, and embraced the angle of the chamber in that position. There were marks of descemetitis and more inflam-

matory symptoms than are usual in that disease. After enucleation the growth was seen to be tubercular, and, while the inner half of the iris was free from the tumor, the entire area of the space of Fontana was infiltrated with cells, leading the author to the opinion that the disease originated in this position. A delicate tissue composed of tubercular matter had originated in the ciliary body and the anterior part of the retina, and entirely surrounded the lens.

In the performance of *iridectomy* Reche, of Breslau, [254 Oct., '98] points out that the segment of iris should be removed from the temporal and not from the nasal side. It makes no difference what part of the lens is utilized for the production of the image when light falls upon it, spherical aberration occurring in the peripheral parts of the lens, causing rays which pass through the periphery of a convex lens to be more strongly refracted than those which pass through the centre. If, therefore, a small aperture be made near the periphery of the iris in the inner quadrant, the image will be formed on the temporal side of the macula, and, in order to cause it to fall on the macula, the eye will have to be turned inward. Upon account of the great amount of convergence and attendant fatigue, and also of the large field to be gained by a temporal iridectomy, the author advocates making the pupil in this position.

Denti, of Milan, [173 June, '94] has made a clinical and anatomical contribution to the study of *tuberculosis of the uveal tract*, and gives the notes of three cases of tubercular iridocyclitis. In the first the caseous mass filled more than half of the anterior chamber. Surgical interference being refused, three months later the conditions regressed and spontaneous healing ensued with total posterior synechiæ and pupillary exudate. In the other two instances the intensity of the ciliary pain and the imminence of perforation rendered enucleation inevitable.

Mitvalsky, of Prague, [254 Feb., '94] has had an opportunity of studying, both clinically and pathologically, a case of *tumor of the ciliary body* in a man 66 years old. When first seen it appeared in the periphery of the iris as a grayish prominence. Oblique illumination revealed the presence of a blackish tumor, the size of a pea, immediately posterior to the lens. Corresponding to the situation of the growth in the upper nasal segment of the eye, there was a slight cloudiness of the lens. A few weeks later the neoplasm

pathological change. Swasey, of Worcester, [1018 Apr.,'94] has observed a case of double *congenital cataract*, which appeared as a black spot on the posterior post of the lens, converging toward which there were fine, needle-like opacities. Peters, of Bonn, [204 v.40,No.3] insists upon his theory of the relationships between zonular and total cataract. He thinks that he has disproved several of the hypotheses advanced by Schirmer to account for the production of the former variety. Schirmer [204 v.39,No.4] answers the objections of Peters, and emphasizes his former hypothesis that the constitutional basis of zonular cataract is the presence of an oval zone of closely-grouped globules, and of a similar condition of the nucleus, but with fewer globules associated into heaps in the latter.

Jackson, of Philadelphia, [736 Dec.,'93] considers that senile change does not produce cataract, but predisposes to it; that the efficient determining causes are both ocular and general, and that the general causes are not particular diseases, but the conditions arising in the course of disease. Hocquard [274 Apr.,'94] has studied the effects of pressure upon the crystalline lens in eyes which have undergone pathological changes, finding that the lens is very prone to adapt itself to mechanical influences. If the effect upon it has been momentary it resumes its original form, but if the pressure or traction last for some time the deformity persists.

Jennings, of St. Louis, [82 Mar.14,'94] records two cases of lamellar cataract, in both of which a visual acuity was obtained by glasses not to have been expected from the density of the opacity. From a study of these cases he concludes (1) that we cannot estimate the visual acuity from the density of the opacity; (2) that we should therefore not operate until the child is old enough to read, and until we have corrected any error of refraction; (3) that by so waiting we need not fear amblyopia exanopia; (4) that if we can secure working vision it is unwise to remove the lens. Reche, of Breslau, [190 v.17,p.368,'93] has studied three cases of incipient cataract with the magnifying-glass. In each instance the opacity began in the posterior part of the lens. The first case, which occurred in a boy 10 years old, was remarkable upon account of the large number of narrow stripes that ran through it, and which became cloudy from the periphery toward the centre.

Mueller, of Vienna, [33 June,'94] reports two instances of *posterior lenticonus*,—one in a lad 18 years old, a weakness in the right

eye being first noticed seven years ago. Examination of the organ with a plane mirror revealed a large disc with unevenly-defined margins in the middle of the illuminated pupil. Upon turning the mirror the disc was seen to contain a red sector with its apex at the centre of the pupil and with its base corresponding to the side of the dark disc. The corneal reflexes were normal. The anterior lens-reflex seemed to increase very rapidly in size and to grow disproportionately long when moved from the centre to the periphery of the lens, whilst the posterior lens-reflex showed constancy in size and regularity in movement. Under mydriasis the retinoscope showed that there was hypermetropia at the centre and myopia at the periphery of the dark disc. The direct method proved the centre to be emmetropic. Owing to the parallactic displacements of this abnormal central part of the lens relatively to the pupillary margin and to the corneal reflexes, the author thinks it probable that the phenomena were produced by the nuclear portions of the lens, possibly by the posterior, but by no means by the anterior lens-surface. The second case was that of a girl 10 years old. In the left eye, up and out from the posterior pole of the lens, there was a gray opacity, in the form of a T, composed of irregular striæ. Surrounding this there was an almost circular area which appeared brighter than the periphery when the pupil was uniformly illuminated. In this case the plane mirror produced shadows in the same direction in the periphery and in the opposite in the area just mentioned. The author divides such cases into two groups: (1) where the opacity is either at the posterior pole or excentric and is not confined to the more highly refracting area; (2) where there are no lenticular opacities. In this latter class of cases there is an abnormal curvature in the lens-nucleus rather than a change of curvature of the surface of the lens itself. In the first group, however, there is an abnormal curvature of the posterior surface of the lens. All are congenital, and presuppose an abnormal development of the lens-structure. He thinks that the term "lenticonus" should be discarded, and suggests as a substitute the term "*lens of double focus.*"

In the determination of the question as to when a cataract is ready for operative treatment, Jackson, of Philadelphia, $\frac{234}{\text{Nov.,'98}}$ concludes as follows: "1. In considering the question of operation on senile cataract we must recognize visual maturity and surgical

maturity as distinct conditions. 2. It is sometimes best to have surgical maturity before proceeding to the extraction of cataract. 3. Surgical maturity may be obtained, however, by preliminary operation whenever it is desirable. 4. The time for extraction will then be determined rather by the visual maturity,—not, generally, of the cataract to be extracted, but of the cataract in the eye that retains the better vision. 5. If necessary for visual and personal reasons, it is proper to extract a cataract surgically immature. 6. In young people where some visual power remains, the value of the power of accommodation must be considered in determining the question of operation. 7. If the removal of the lens is deemed advisable in young persons, it should be done as early as possible. 8. In all cases the condition of the patient's general health should be carefully considered and given the greatest weight in determining the time for a cataract operation."

De Schweinitz, of Philadelphia, $^{61}_{\text{Jan.27,'94}}$ considers a preliminary ripening operation generally unnecessary. He has never had unfortunate results follow such a procedure. Jackson, of Philadelphia, $^{61}_{\text{Jan.27,'94}}$ is of the opinion that it is better to perform a ripening operation where there is still considerable clear and soft cortical substance, but does not hesitate to extract an immature lens with a large, hard nucleus in patients over 60 years of age. Risley, of Philadelphia, $^{61}_{\text{Jan.27,'94}}$ favors the combination of an iridectomy with ripening operations, as these forms of cataract are usually complicated and an iridectomy is of real therapeutic value, and, moreover, affords free exit for the soft cortical. Hansell, of Philadelphia, $^{61}_{\text{Jan.27,'94}}$ would operate upon the eye first affected when the patient is deprived of useful vision in the second eye.

King, of Washington, $^{776}_{\text{Oct.,'93}}$ has found the employment of the *electric current* of great value *in cases of incipient cataract*, corneal maculæ, and the various forms of heterophoria. He gives the notes of a case of the first affection where vision was improved from $\frac{5}{20}$ to $\frac{5}{12}$ by this treatment. In a case of incipient cataract Egbert $^{107}_{\text{May 15,'94}}$ claims to have obtained marked improvement in vision by the following method: The eye is thoroughly cleansed with a solution of boric acid, and 1 or 2 drops of a 4-grain (0.26 gramme) solution of eserine is instilled. A small particle of vaselin is introduced into the *cul-de-sac*, and the eyeball is manipulated through the closed lids for a period of fifteen minutes. The eye

is again thoroughly washed with the boric-acid solution, and 2 drops of succus cineraria maritima are instilled. The treatment is repeated daily for two weeks, and later every second or third day.

Unless there be contra-indications, it is the practice of Bolard [173 Aug., '94] to operate for cataract in children at the end of the first year of life. In soft cataracts, after a careful discission, the lenticular matter is evacuated by means of an instrument constructed for the purpose by Redard. From a consideration of the subject of cataracts in children, he concludes as follows: 1. Cataracts are frequently seen in the young. The soft form is the more frequently encountered among children, but the zonular variety is the most frequent congenital form. 2. It is of the greatest importance, when a cataract is diagnosed, to obtain full information in regard to the nature, the extent, and the situation of the lesion, and not to interfere until the most favorable conditions have been obtained. 3. In congenital cataract it is necessary to interfere early, in order to avoid the disadvantages of a bad ocular education (myopia, strabismus, nystagmus). 4. In very young infants complete chloroformization is necessary. A simple bandage is all the dressing required, the child being then confided to its mother or some other familiar person. When the child is older, the same dressing is employed as in adults. 5. In zonular cataracts an artificial pupil is usually obtained. If complete extraction is necessary, the corneal incision should be large enough to permit the ready passage of a nucleus, which is often quite large. 6. Superior keratocystotomy is the operation of choice in the extraction of soft cataracts in young subjects. If the incision made in the capsule by the point of the knife is not adequate, there is always sufficient time to enlarge it with a cystotome. 7. In general, in young subjects operated upon soon after the appearance of the cataract, the optical results are infinitely superior to those obtained in subjects affected for a long time with lenticular opacities. The visual acuity should be observed at frequent intervals after the operation.

De Schweinitz, of Philadelphia, [80 Nov. 15, '93] gives the following as safe and proper procedures before and during cataract extractions: (*a*) Sterilization of the hands of the operator and assistants, and of the skin in the region of operation. (*b*) Disinfection of all instruments with non-cutting edges, or with edges not readily injured,

by boiling in a 2-per-cent. solution of carbonate of sodium, followed by a bath of absolute alcohol, in which they should remain for at least twenty minutes before the operation, when they should be removed and their blades freed from the alcohol, which is irritating, by dipping them for a moment in a vessel containing boiling water. Sterilization of the cataract-knife by dipping in boiling water, followed by immersion in alcohol, or by the method of Stroschein. (*c*) Preparation of the ciliary margins by frequent washing with soap and water, followed by a thorough rubbing with sterile salt solution, or, if preferred, a mild antiseptic fluid, and immediately before the operation a thorough flushing out of the conjunctival *cul-de-sac* with a boric-acid solution applied with some force, or a sterile physiological salt solution. (*d*) Removal of blood, etc., during the operation with bits of gauze sterilized in steam, under no circumstances bringing bichloride of mercury or other irritating germicide in strong solution in contact with the wound. (*e*) Sterilization of alkaloidal solutions by boiling, followed by the addition of a chemical substance, such as a 4-per-cent. solution of boric acid or a 1 to 10,000 solution of bichloride of mercury, care being taken, in the case of cocaine, after each application to the eye, to keep the lids closed, and thus prevent drying and wrinkling of the corneal epithelium. (*f*) Careful inspection and cleansing of the margins of the lids, conjunctiva, and lachrymal points, and the naso-pharynx. If there be the least suspicion, the use of a preparatory bandage, no operation to be undertaken until this may be applied for twenty-four hours without evidence that undue secretion is created. (*g*) Due precaution at each subsequent dressing to exercise the same care with hands, dressings, and collyria as at the primary operation.

Fage, of Amiens, [173] June, '94 instills 3 or 4 drops of atropia into the eye previous to the simple extraction of cataract, believing that this facilitates the operation and also aids in obtaining a clear pupil, while it diminishes the liability to prolapse of the iris. The instillation is especially indicated in soft cataracts where the delivery of the soft cortical matter is rendered much easier by reason of the large pupil. Haltenhoff, of Geneva, [173] May, '94 gives the indications for the performance of the different operative procedures in traumatic cataract. In simple cases operation should be postponed until the danger of glaucomatous complications has passed. The

aspiration process is indicated in young subjects. He avoids discission, as it unduly prolongs the duration of the case.

Hodges, of Galveston, [2013 May, '93] has successfully removed a lens from the anterior chamber of an eye, congenital *dislocation* posteriorly having occurred, with spontaneous luxation into the anterior chamber. Its removal was necessitated by a severe scleritis produced by pressure. Noyes, of New York, [2035 '94] has seen two instances of traumatic dislocation of the lens into the vitreous, occurring in individuals both of whom had met with a similar accident in the opposite eye some years previously. Dabney, of Louisville, [224 Sept., '94] has successfully removed a spontaneously-dislocated calcareous lens from the anterior chamber of a man 30 years of age. The eye had always been practically blind. Two cases of dislocated lenses were operated upon by MacLachlan, of Ann Arbor. [776 Apr., '94] The first instance made a good recovery, but in the second the irritation which had been produced by the lens persisted after its removal, necessitating enucleation.

Fage, of Amiens, [274 Oct., '93] believes that a secondary operation for the removal of *traumatic cataracts* complicated by glaucomatous phenomena and a clearing of the pupil is perfectly justifiable. For this purpose he employs a stout pair of capsular forceps, with which he removes as large a piece of the capsule as possible, then extracts the lenticular mass with a metal curette, and washes out the anterior chamber with boric acid or cyanide of mercury. In order to avoid the hæmorrhage which often follows iridectomy, he thinks that this procedure had best be performed in advance. In similar cases, the same author [173 June, '94] claims that secondary cleansing of the pupil is the most useful and reliable operative procedure.

Meighan, of Glasgow, [213 Mar., '94] has extracted the crystalline lens in two cases of high *myopia*. Both were operated upon by discission, with subsequent removal of the softened lens-substance. In one instance separation of the retina occurred three months after the operation, and since that time vision gradually failed. In the second instance considerable improvement in vision resulted. The author records a third case, operated upon by another surgeon, in which the result was very satisfactory. He states that he would hesitate to advise the operation in a good myopic eye, even though of high degree, provided that a fair amount of vision could be obtained with glasses. Fukala, of Pilsen, [254 June, '94] draws attention to the

fact that he performed discission upon cases of high myopia two years earlier than Vacher, the history of several cases being brought forward to prove the assertion. Bourgeois, of Reims, [577 Mar., '94] has had successful results follow the extraction of a transparent lens from myopic eyes of high degree in several cases.

In a case of *prolapse of the iris* into a wound in the periphery of the cornea, Smith, of Chattanooga, [61 Mar. 19, '94] has succeeded in permanently reducing the protruding membrane, keeping it in position by the employment of eserine. Valk, of New York, [1 Oct. 20, '93] has employed his "iris retractor" successfully in twenty-nine cases of simple extraction. In order to produce contraction of the pupil following simple extraction, Smith, of Detroit, [249 Jan., '94] administers an hypodermatic injection of ¼ grain (0.016 gramme) of morphia, followed by two other similar doses at eight-hour intervals. He says that if the drug be given in this form it does not produce vomiting. After the toilet of the lens he is also accustomed to instill 1 drop of a 1-grain (0.065 gramme) solution of eserine into the conjunctival sac. In order to prevent prolapse of the iris, Van Milligen, of Constantinople, [178 June, '94] applies a Sulzer contact glass, taking the precaution to get rid of all air-bubbles. The glass is removed at the end of the fifth day. In a case of prolapse of the iris seen within a few hours of the accident, Ryan, [285 Feb. 15, '94] advises a replacement of the membrane and the introduction of sutures into any existing wound in the sclerotic; if twelve to twenty-four hours have elapsed, an attempt should be made to disengage the iris. J. J. Chisholm, of Baltimore, [1018 Jan., '94] makes use of simple extraction, although he states that, on the whole, iridectomy will insure speedier convalescence. When the latter procedure is adopted he employs a permanent dressing of isinglass-plaster, which is not disturbed for five days. After simple extraction, however, the eye is observed daily for fear of prolapse of the iris. A Liebreich bandage, which includes only the operated eye, is removed at the end of the fifth day. The operation is performed in the operating-chamber, and the patient is permitted to walk to the ward after the operation, no restraint being placed upon his future movements. The author has had prolapse of the iris to occur in about 8 per cent. of his simple extractions. In operating upon soft cataracts in children no bandage is employed, but the precaution is taken to secure the hands of the patient by a wrist-band.

In order to avoid the optical hindrance of secondary cataract, Birnbacher, of Gratz, [190 Mar., '94] excises a section of the capsule immediately after the performance of the iridectomy. For this purpose he has devised a knife, which is introduced through the incision and the capsule incised in the area of the coloboma.

Fox, of Philadelphia, [61 v.22,p.887,'94] practices *posterior capsulotomy* at the time of the extraction, using a gold-enameled steel hook, with which he tears and lacerates the capsule from below the lower pupillary margin up to the corneal incision. Fifteen per cent. of the cases required a subsequent capsulotomy. His experience is fast leading him to adopt the use of a keratome to make the corneal incision and a de Wecker scissors to cut the capsule.

Noyes, of New York, [2035 '94] removed an hypermature cataract by delivering the nucleus after the procedure usually employed in the extraction of dislocated lenses. After the fluid contents of the capsule had been allowed to escape, the nucleus, which had fallen back into the vitreous, was pressed out of the eye by making firm pressure on the globe by means of two spatulæ. At the end of forty-eight hours a diffuse keratitis developed, which the author is inclined to attribute to the use of a 4-per-cent. solution of boric acid. In view of this fact, he thinks that that drug should never be employed for irrigating purposes in a solution stronger than 1 per cent., whilst he prefers for this procedure a $\frac{7}{10}$-per-cent. solution of chloride of sodium, blood-warm and sterilized.

Weeks, of New York, [59 Apr.21,'94] has successfully removed the crystalline lenses from a pair of eyes presenting evidences of past severe specific inflammation. In both there was thinning of the cornea and scleræ, atrophy of the irides, and a mummified condition of the lenses. In the left eye there was total posterior synechia with occlusion of the pupil by a pseudomembrane. French, of San Francisco, [776 July,'94] reports the successful extraction of a lens from an eye with chronic catarrhal inflammation and increased tension. During the operation a large quantity of fluid vitreous was lost.

Murrell, of St. Louis, [663 Feb.,'94] has found corrosive sublimate to be too irritating for use in cataract extraction, and prefers a solution of boric acid. He also favors confining the patients after operation as little as possible.

J. J. Chisholm, of Baltimore, [2 Sept.15,'94] re-asserts that "tying up

both eyes after cataract extractions, keeping patients in bed and in the dark, is useless, needless, and annoying."

Jackson, of Philadelphia, [1018 Jan.,'94] has treated a case in which destruction of the eye by *hæmorrhage* followed the extraction of a cataractous lens, which had been dislocated downward, and which was safely removed by simple extraction without the use of a wire loop or of fixation of the lens. A few minutes after the operation the patient complained of severe pain in the temple and back of the head. An examination revealed a copious hæmorrhage from the corneal wound, which was at once controlled by placing the patient in an upright position. There was a deep glaucomatous excavation in the other eye, but at no time were any hæmorrhages observed in the fundus. De Schweinitz, of Philadelphia, [1018 Jan.,'94] reports a similar case occurring in a female, 65 years old, who exhibited evidence of arterial sclerosis. A preliminary iridectomy had been successfully performed. Notwithstanding that a quantity of vitreous escaped at the completion of the corneal section, necessitating the removal of the lens by a scoop, the eye regained its normal tension and became unusually filled out. Ten minutes after a light antiseptic dressing had been applied the patient complained of a sickening pain in the back of the head and of nausea. The dressings were removed, and the palpebral fissure was found to be distended with a large blood-clot. This was removed and a firm antiseptic dressing applied. The head of the patient was elevated and hypodermatics of morphia administered until the pain was relieved. Under this treatment the hæmorrhage was controlled, and, although the eye became blind, panophthalmitis did not supervene, the ball becoming somewhat shrunken. Terson, of Paris, [274 Feb.,'94] points out that the chief factor in the causation of ocular hæmorrhage after extraction is an increase in the blood-tension. He has made a microscopical examination of an eye which was lost as a result of such an accident, and found that the choroidal and retinal vessels had very much thickened walls, and that there had been a classical total retrochoroidal hæmorrhage. The hæmorrhage seemed to have originated at the entrance of the posterior ciliary vessels in the posterior and external region of the choroid, and did not occur until three days after the extraction. The author thinks that the arterial sclerosis was not sufficient in itself to account for it, but considers that there

must have been a permanent increase in the arterial tension, which had risen at the moment of the hæmorrhage. The patient died shortly afterward from syncope, which was easily explained by the post-mortem examination of the heart and arteries. The former was hypertrophied, particularly in the left ventricle, whilst the arteries were everywhere much thickened. The author points out that the drug best adapted to produce a calmative and regulative action upon the heart-movements is veratrum viride, and that it is easily tolerated in the strength of 10 to 20 drops of the tincture twice daily. He also favors the performance of a preliminary iridectomy when hæmorrhage is to be feared, as it permits of the more rapid final extraction of the cataract and prevents the possibility of an increased prolapse in an already doubtful situation.

Risley, of Philadelphia, [1018 Jan.,'94] cites an instance of destructive hæmorrhage during extraction of a cataract. The patient was a female 82 years of age. The liquefied state of the cortical substance, the presence of cholesterine crystals in the lens, the sagging downward of the lenticular mass, the tremulous irides, and finally the very fluid vitreous, all gave indications of degenerative processes which had occurred in the eye before opacity of the lens took place. In this case the prolapse of vitreous followed immediately on the section, and a hæmorrhage appeared instantly after the delivery of the lens.

Jackson, of Philadelphia, [76 Dec.,'93] has found that the *astigmatism of the cornea* following section of that membrane appears in the course of two or three days or sometimes in a few hours, and quickly reaches its maximum, from which time it steadily declines. It is present in all cases, whilst in the large majority of instances it diminishes to less than 3 dioptres before it becomes fixed. It is due to a protrusion of the cornea and sclerotic at the seat of operation, produced by the diminished resistance of the ocular tissues at this point. Dolganof, of St. Petersburg, [254 June,'94] has studied the formation and development of corneal astigmatism consecutive to cataract extraction by means of the Javal ophthalmometer. Special attention was paid to the change in the refraction of the principal corneal meridian. The first observations were taken nine to fifteen days after the operation, the second after three or four weeks, and the third after five or six weeks, when a final record was made of the residual stationary astigmatism. From the

results obtained he found that the degree of the astigmatism lessens very gradually, the figures of the first measurement showing that the corneal refraction of the meridian perpendicular to the incision always decreases between 1 and 6 dioptres, and *vice versâ;* that there was always an increase in the corneal refraction of the meridian parallel to the incision (0.25 dioptre to 6.5 dioptres); and that finally the second measurement showed an increase in the refraction of the vertical meridian, only in exceptional cases remaining unchanged in the horizontal meridian. The two most prominent factors in the production of the astigmatism appear to be the effect exerted upon the lips of the wound by the traction of the extra-ocular muscles and the contraction of the scar-tissue itself, together with the action of the intra-ocular tension.

In regard to the acquired change in the ocular refraction, Schoen, of Leipzig, $^{254}_{\text{Oct.,'93}}$ points out that the decrease in the refraction seen in aphakic myopic eyes is greater than in aphakic eyes which have been emmetropic. Higgens, of London, $^{6}_{\text{Nov.11,'93}}$ gives the results obtained in 52 cases of extraction without iridectomy and 58 extractions associated with the removal of a piece of the iris. In the first series the results were successful in 46, partially successful in 4, and unsuccessful in 1; result not recorded in 1. In the second 40 were successful, 11 were partially successful, 2 were failures, and 5 were not recorded. The author believes that these results are worthless as a basis of comparison between the two methods, for the reason that "the whole of the non-iridectomy operations were picked cases." In selecting cases for simple extraction he is influenced (1) by the patients, choosing those who are moderately well nourished, in fairly sound health, and of tranquil disposition; (2) by the eye, accepting those where the cataract is fairly mature, the pupils circular and the irides movable, the anterior chamber good, and the cornea of a fair size.

Fage, of Amiens, $^{230}_{\text{Feb.,'94}}$ gives the statistics of 70 cases of cataract extraction, 48 of which were performed by the *simple method.* Among these, loss of vitreous occurred twice, prolapse of the iris seven times, and iritis once; in the 22 cases in which iridectomy was performed, the vitreous prolapsed twice. One case had iritis, and suppuration ensued in another patient with diabetes. In regard to the performance of discission, the author states that, in order to avoid irritation of the eye by excessive traumatism, it is

necessary to wait until several weeks after the primary operation; to take the same antiseptic precaution as at the time of the primary operation; to avoid bringing the needle in contact with the vitreous body, by reason of its being a most favorable soil for the development of germs; to make as little traction as possible upon the iris and the ciliary body with the needle, so as to prevent iridocyclitis.

Of a tabulated report of 73 cataract extractions [2035 Jan., '94] performed in the New York Eye and Ear Infirmary from October, 1892, to October, 1893, Case 70 is of extreme interest from the fact that, after an ordinary extraction with good projection, mild iritis occurred, which was relieved by atropia and hot boric acid. The pupillary space was partially filled with soft lenticular matter. Twenty days before extraction atropia was instilled, producing glaucoma, for the relief of which a broad iridectomy had been done four days later, eserine being used for a time. A free capsulotomy was finally performed, giving as a resultant corrected vision of $\frac{20}{80}$.

Higgens, of London, [6 Aug. 11, '94] gives the results obtained in his last series of 465 cases of extraction: 75.2 per cent. were successful, 9.4 per cent. were partially successful, 7 per cent. were failures, and the results of 7.9 per cent. were not recorded. Nineteen cases in which the patients were 80 or more years of age showed entire success in all but two instances, and in one of these the success was partial, while in the other, which was a failure, the fellow-eye was lost through sympathetic inflammation. Gruening, of New York, [814 Feb. 15, '94] has performed fifty consecutive simple extractions without the occurrence of prolapse of the iris. He makes the section larger than for the combined operation, and considers it absolutely necessary that it should be made entirely in the sclero-corneal margin. Thorough cocainization before and after the operation with a 10-per-cent. solution will confine the iris within the eye.

Noyes [2085 '94] reports an instance of partial *spontaneous disappearance of an opacity* of the lens. The opacity was the effect of a powder-burn, and, when first seen, presented a general conformity to the natural subdivisions of the lens, and resembled "a bunch of plumes" fastened by their stems, at the posterior pole of the lens. Three weeks later the opacity, which had become uniform over the posterior surface, assumed a molecular appearance, being

perforated by numerous holes. One year after the accident the opacity was much less, and resembled a "bundle of curled hair at the posterior pole of the lens."

A case of apparently spontaneous absorption of the crystalline lens, in a man 65 years of age, has been seen by Schneideman, of Philadelphia. [234 May,'94] The case is of interest because of the complete absorption of the lens in so aged a person, and because the process occurred without the supervention of glaucoma.

DISEASES OF THE CHOROID.

Rindfleisch, of Weimar, [353 Mar.,'94] has seen an instance of *coloboma* of the choroid situated above the disc. Near the periphery there was a localized choroiditis, which, in conjunction with the position of the coloboma, gave rise to the assumption that the ectasia was a result of fœtal inflammation. Buckle, of New York, [51 Nov.,'93] gives notes of a case of *choroiditis disseminata* in a child, 10 years of age, who was the subject of hereditary syphilis.

Trousseau, of Paris, [171 Mar.,'94] reports an *iridochoroiditis*, in a man 66 years of age, due to an abscess which had developed itself in one of the testicles. The disease first appeared as an hypopyon keratitis which yielded readily to treatment, but re-appeared shortly afterward as a periorbital lymphangitis. Pansier, of Avignon, [171 Apr.,'94] has employed the continued current in a series of cases of acute iridochoroiditis, finding its sedative effect constant. Pain was always relieved after several applications of the battery. The usual treatment of the disease by drugs was continued in each instance. Veillon and Morax, of Paris, [171 May,'94] have observed a case of *suppurative choroiditis*, due to streptococci, occurring spontaneously during the course of a general septicæmia occasioned by a suppurative arthritis of the knee-joint. The examination of pus from the eye and from the cavity of the joint showed the presence of the streptococci in both fluids. The mode of entrance of the organism was not ascertainable, though the authors admit, however, that the disease was of sanguineous origin. It is of interest to note the localization of the disease in the synovial cavity of the sac as well as in the choroid,—a coincidence which has been remarked in several instances of metastatic puerperal choroiditis. They are persuaded that surgical interference (arthrectomy) and the enucleation of the affected eye, by permitting the egress of pus

and by destroying the purulent foci, are the chief indications in the treatment of this class of subjects.

Several specimens of unusual forms of intra-ocular *neoplasms* have been seen by Treacher Collins, of London. [2 Dec.22,'93] The first was one of melanotic sarcoma of the ciliary body in a woman 63 years old. The whole uveal tract was congenitally deeply pigmented, and the sclerotic presented patches of pigment. In the second case there was a primary growth of the ciliary body of glandular type. The anterior portion of the tumor was deeply pigmented, whilst the posterior portion was devoid of pigment. The peripheral parts of the growth were less degenerated, and here the cells were epithelial in type, and in their arrangement suggested glandular structure. A study of this and four previously-recorded cases has led the author to the conclusion that in all of them the growth had its origin in the glands of the ciliary body. The third and fourth cases were brother and sister. In the man, sight began to fail at 20 years; in the girl it was first impaired at about 10 years of age. In each instance it progressed to complete blindness of both eyes in one year's time. All of the eyes were enucleated, but in the brother's case only after a period of thirteen years, when pain first occurred. Examination of one of the brother's eyes showed the retina to be detached, except at one point. The retinal veins were enormously enlarged and their walls were thickened. In the sister's eyes the interior structure of the globe could not be differentiated, being apparently replaced and the cornea invaded by a new growth composed of a net-work of thin-walled capillaries. The interior of both eyes contained large cavities and plates of bone which had formed on the inner surface of the choroid. Two cases of *sarcoma of the choroid* are reported by Mitvalsky, of Prague, [254 May,'94] to both of which the name of *flat sarcoma* was considered applicable by reason of their manner of spreading. He believes this to be a true, though rare, variety of sarcoma, characterized by its tendency to invade the whole uvea and by the liability to the formation of episcleral nodules. Friedenberg, of New York, [2035 Jan.,'94] has had an opportunity of making a microscopical study of a specimen of sarcoma of the choroid, in a very early stage of its development, in a woman of 30 years. Clinically the growth was remarkable upon account of a system of vessels which ran over it, and appeared as blood-bands of equal width throughout their course. The microscope showed

the tumor to be entirely within the choroid, the lamina vitrea being intact, and the lamina fusca appearing as a distinct layer between the growth and the sclera. The growth, a leucosarcoma of the spindle-celled variety, obviously had its origin in the layer of larger vessels, these being surrounded by numerous cells, for the greater part arranged regularly about the lumen. In addition to the vessels there were vascular spaces in which the blood had tunneled itself between the fascicles of the tumor. The amount of the pigment did not appear to be in excess of that in a corresponding area of the choroid, and the changes in its form and distribution were regarded as due to the mechanical influence of the tumor-cells. The pigment-layer of the retina was unchanged.

Fromaget, of Bordeaux, [171 Apr.,'94] cites an instance of intra-ocular hæmorrhage occurring in a case of sarcoma of the choroid after the instillation of atropine. The patient was 56 years of age, and the mydriatic was employed for the purpose of obtaining a more detailed view of the fundus than was possible with an undilated pupil. After enucleation histological examination showed the growth to be a leucosarcoma developed from the pigment-layers of the choroid, and resembling a sponge in its appearance, being filled with "veritable bloody lakes." Basso, of Genoa, [274 Jan.,'94] has made a careful study of mixed sarcoma of the choroid. Levi [7 Nov.27,'93] has observed a case of metastasis of a melanotic sarcoma having its primary seat in the eye, and occurring three years after the first ocular symptoms.

DISEASES OF THE VITREOUS.

Wolff, of Gladbach, [204 B.40,H.2] has studied the effects of iodine injections into the vitreous of dogs. In ten cases in which from three to seven drops of the tincture were injected by means of Pravaz's syringe, more or less extensive detachment of the retina occurred, there being a connective-tissue formation at the point of injection, while the sclerotic in the immediate neighborhood was affected. In two cases there were circumscribed opacities of the posterior layers of the lens. Iridochoroiditis occurred once. The author does not attribute the changes to the iodine, but to the obliteration of the arterial supply. From the absence of marked inflammatory appearance he believes that iodine may be injected into the eye if not too strong solutions are carefully employed, and

BURK & McFETRIDGE CO LITH PHILA

Congenital Malformation of Eye-Ground (Wintersteiner)

Archiv für Augenheilkunde.

none of the fluid permitted to come in contact with the vitreous, as this is always followed by a shrinking and consecutive retinal detachment.

By the employment of the electro-magnet the removal of *iron chips from the vitreous*, attempted in 18 cases by Heurzeler, [217] was accomplished in $72\frac{2}{10}$ per cent. In 50 per cent. more or less vision was preserved, and in $11\frac{1}{10}$ per cent. the form of the globe was conserved. In 38 per cent. enucleation was rendered necessary. The author concludes that by means of this instrument not only iron chippings can be removed from the anterior part of the vitreous, but even from the retina, provided they are not encapsulated. In order that the chip may leave the eye through its point of entrance, it is necessary to turn the globe in the direction of this point. Operative interference should be inaugurated as soon as possible after the entrance of foreign bodies, as their presence tends to excite disease of the macula.

The accompanying chromo-lithograph is a representation of a peculiar ophthalmoscopical appearance observed by Wintersteiner, of Vienna. [254] The patient, a boy 13 years old, exhibited a slight degree of epicanthus, with opacities on both corneæ, the result of an earlier inflammation. As shown in the illustration, there was a globe-shaped opacity in the anterior portion of the vitreous of the right eye, apparently consisting of connective tissue. From this mass vascular connective-tissue processes ran to the periphery and the papilla. The optic-nerve head was white. The entrance of the vessels was covered and the vascular supply abnormal. The retina was covered by yellowish-white stripes. In addition to this there was a slight pigmentation of the fundus in the form of bands and spots. The author believes that this condition is a congenital anomaly, and explains it by a lack in development of the vitreous, owing to a failure in the proper disappearance of the vessels of that tissue, on account of which the retina was not closely approximated to the choroid, but lay in folds. The processes observed ophthalmoscopically represent their remains. The stripes were produced either by a union of the approximated surfaces of the retinal folds by a transudation into the fissures caused by the folds, or by an insufficient nourishment of the retinal folds later on when the choroid was developed.

Woodruff, of Chicago, [1018] has observed a case in which a dead

cysticercus appeared in the upper and outer portion of the vitreous as a bluish-white, translucent, tent-like projection. A small central, but motionless, body could be seen within the cyst-wall. Cheatham, of Louisville, $^{1018}_{\text{Apr.,'94}}$ has seen a similar case in an Irish woman 42 years old. The eye in which the parasite was found had been blind for twenty-seven years and had never been the seat of inflammation. The ophthalmoscope revealed a pedunculated cyst near the macula. Blood-vessels ran over the sac, which was opaque, bluish-gray in color, and motionless, and down and out from which extended a transparent, reddish cyst. Upon the upper part of this two spots, resembling air-bubbles, were seen. These were regarded by the author as the parasite's suckers. The cyst had a distinct rhythmical movement. Higet $^{2}_{\text{June 9,'94}}$ has observed an instance of this disease in a man 26 years of age, the entozoön being dead and shriveled and projecting into the vitreous from above. The head had pierced the retina and lay in the posterior chamber against the lens, and the body of the cyst was covered by detached retina. Vision equaled $\frac{1}{10}$.

DISEASES OF THE RETINA.

A case of rare and fatal disease of infancy, with symmetrical changes in the yellow spot, has been seen by Carter, of New York, $^{249}_{\text{Jan.,'94}}$ in a Hebrew child 19 months of age. The patient was healthy until 3 months old, when it began to fail. The sketch on next page gives an idea of the appearance of the fundus. In the maculæ of both eyes there was a cherry-red spot sharply defined, surrounded by a grayish-white halo. Both discs became atrophic. No autopsy was obtainable.

Mackay, of Edinburgh, $^{76}_{\text{Mar.,'94}}$ has reviewed the literature upon *blinding of the retina by direct sunlight*, and records seven new cases of "*eclipse blindness.*" The author believes that the persistence or re-appearance, on closure of the eye, of a sun-image which does not rapidly undergo alterations in color may perhaps be taken (save in the color-blind) as the mark of a retinal stimulation slightly surpassing the physiological limit, and that after-images are a more hopeful sign than positive scotoma, as presupposing the existence of a group of end-organs still capable of activity. In most of his cases an interval of two or more hours elapsed before the more positive permanent scotoma appeared. The function of

adaptation to intense light is doubtless largely subserved by the protoplasmic movements of the processes of the retinal epithelial cells and of the cones, the protection offered the percipient elements by this apparatus, however, being limited, as the mechanism is not instantaneous in action, the maximum protrusion of the pigment requiring several minutes for full development. Vision, in the author's cases, equalled one-third, one-half, or two-thirds of normal. It is important to measure the scotoma in order to properly

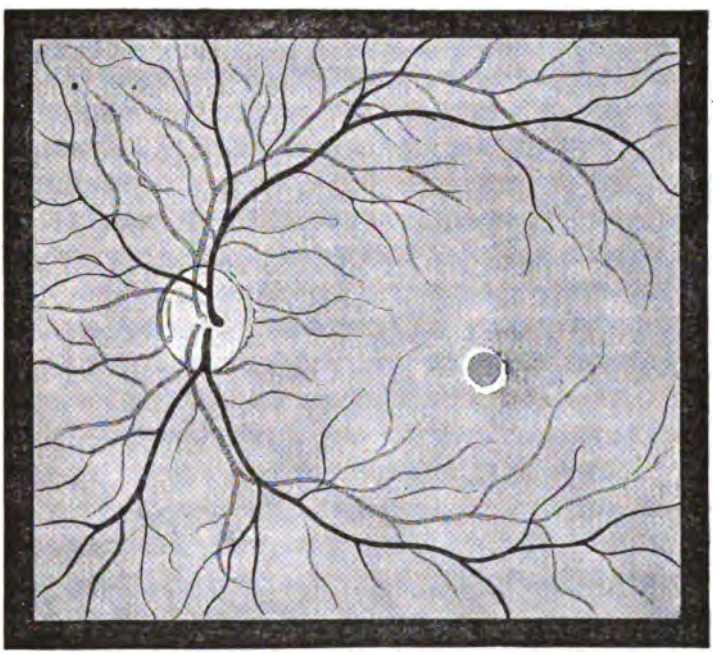

SYMMETRICAL MACULAR CHANGE IN INFANCY. (CARTER.)
Archives of Ophthalmology.

estimate the defect quantitatively. He concludes that the visual defect may occur as an absolute scotoma at one part, while it is but partial throughout the remainder. The rotary movements of the after-images seen in some cases he attributes to an actual quivering of some of the cones which have lost their proper support as the result of the injury. In his own cases the scotoma varied from three to twenty millimetres in diameter. Extensive ophthalmoscopical changes are not the rule. If the case be seen within the first week, and if the lesion be limited to the fovea and

be but slight, only a little flattening and loss of light-reflex is likely to be found. If the injury be more severe, a little spot of pale-orange tint may be seen within or near the fovea, presumably due to minute chorio-retinal extravasation. The surrounding fundus usually exhibits a pigmentary darkening. During the second week there is a tendency toward increase of pigmentation from proliferation of the retinal pigment-cells; this may replace or obscure the signs of exudation. In from three weeks to one month the fundus may appear quite normal. Only one of his cases complained of spontaneous metamorphopsia, and this in a modified form. Macropsia occurred as a sequel to the accident in four of his patients. The prognosis of a decided improvement in vision and a cessation of discomfort is, on the whole, favorable, while complete recovery is exceptional. The prognosis is influenced by (1) the time which has elapsed since the accident; (2) the degree of impairment of visual acuteness for test-type and for colors; (3) the extent of the scotoma, and especially of the absolute area contained within it; (4) the gravity of the ophthalmoscopical changes; (5) the presence or absence of oscillating movements; (6) metamorphopsia; (7) the local and general healthiness of the subject; (8) the refraction of the eyes; (9) the natural pigmentation of the fundus. He asserts that an uncorrected ametropia and a fundus which is rich in pigment may confer some protection. Supposing the eye to have been previously healthy and possessed of normal vision (an assumption largely justified by experience), the author roughly divides all cases into four classes, with reference to their probable prognosis, thus:—

Class I. A patient with $V=\frac{1}{8}$ or better in the first week (and the earlier the better) has a good chance of practical recovery in one month. Class II. A patient with $V=\frac{1}{8}$ in the second week has a fair chance of practical recovery in three or four months. One with less defect at this period will have a better chance (he may come under Class I); it will depend on the intensity of the retinal defect. Class III. A patient with $V=\frac{1}{8}$ in the third week will probably recover slowly in five or six months, but the chances are rather against his complete restoration. Class IV. A patient with V which is poorer than $\frac{1}{8}$ at any time, though he may make rapid progress in the first month, seems to have a bad chance of recovering $V=\frac{6}{6}$. By "practical recovery" he means cessation of obtrusive defect.

In order to avoid the condition a glass so dark that no object illuminated by diffuse daylight is visible through it should be used whilst viewing the sun. Time should also be given for the gradual adaptation of the retina. In the treatment of the affection coquilles (No. 2 London smoke) with side-pieces should be worn constantly, and near work should be dispensed with for the first month. If inflammatory symptoms threaten, however, diaphoretics and confinement to a darkened room should be tried. The use of hypodermatic injections of strychnine or galvanism is regarded as of little value.

Two cases of *electrical flashing* followed by severe retinal irritation and intense eye-pain are recorded by Brose, of Evansville, Ind.[219] After the stage of acute irritation the patient entirely recovered.

Beaumont, of Bath,[2] has noted a remarkable *intolerance of the retina* to red-colored objects in a highly-neurotic army-officer. The field of vision was somewhat contracted for white and greatly so for red and green, the field for green being smaller in the eye in which the retinal hyperæsthesia was the more pronounced. The author terms the condition *erythrophoria*.

An instance of *subhyaloid hæmorrhage*, occurring in a woman 28 years old, is reported by Dimmer.[217] The two points of interest in the case are: 1. The unusual situation and form of the hæmorrhage, which surrounded the papilla except below, and extended toward the macular region, giving rise to the impression that it came from the superior temporal or one of the macular vessels. 2. The peculiar bending of several of the retinal veins over the edge of the hæmorrhage.

Bull, of New York,[1] gives a detailed report of thirty-eight cases of *detached retina*, from a study of which he concludes as follows: "1. The science and practice of ophthalmology have as yet discovered no better means for dealing with detachment of the retina than the old methods which have been advised and carried out for so many years,—viz., rest on the back in bed, atropine, a bandage, and the internal administration of some drug which may induce absorption of the subretinal fluid. 2. The continued use of pilocarpine, either hypodermatically or by the mouth, may cause great prostration, even in cases in which it is apparently well borne; and the desired effect may sometimes be produced by small

doses of bicarbonate of sodium and iodide of potassium largely diluted with water. 3. In all recent cases puncture of the sclera subconjunctivally may do good temporarily by letting out the subretinal fluid and allowing the retina to collapse, thus producing some improvement in the vision; but the apparent improvement is generally transient, and when membranous bands exist in the vitreous no improvement can be expected from simple puncture. 4. Division of fixed membranous opacities in the vitreous causes but little reaction, and may do positive good even without division of the detached retina, as it reduces the danger of extension of the detachment. It is positively contra-indicated in cases where the vitreous opacity is vascularized, as it would certainly induce free hæmorrhage into the vitreous. It should never be done in an irritated or an inflamed eye. 5. Division of the detached retina, which allows the subretinal fluid to escape into the vitreous, may always be done in a quiet eye, and produces little or no reaction. If membranous bands are present in the vitreous, these should also be divided at the same time. 6. In most cases all these operative procedures produce but temporary improvement, and in many cases no effect whatever is gained by them. 7. There seems no good reason for any further indorsement of the method advocated by Schöler, but every reason for rejecting it from the domain of ophthalmic surgery."

In a case of double retinal detachment occurring in a myopic eye, Wolfe, of Melbourne, $^{2}_{\text{Apr.21,'94}}$ has successfully operated upon one eye by withdrawing the subretinal effusion. Two months after the operation vision equalled $\frac{3}{20}$, and the form-field showed contraction only to the temporal side. There was also considerable improvement in the vision of the unoperated eye. Gillet de Grandmont, of Paris, $^{274}_{\text{June,'94}}$ has successfully employed electrolysis, after the method recommended by Abadie, in a case of large detachment of the retina. Armaignac, of Bordeaux, $^{173}_{\text{May,'94}}$ reports an instance of spontaneous cure of this affection in a 9-year-old boy who had been struck in the eye with a chip of iron. As a result of the injury there was a large irregular wound in the ciliary body, with prolapse of the vitreous into it. A pressure-bandage was applied and a simple lotion ordered. Two months after the injury the retina, which had become detached as the result of very extensive hæmorrhage, had subsided, and there was

nothing left to mark the detachment save a large pigmented area.

A case of *hæmorrhagic retinitis* with hæmorrhages into the vitreous, in a woman 38 years of age, is related by Inouye, [200 Oct.29,'93] of Tokyo, in which, after absorption of the blood in the vitreous, newly-formed blood-vessels sprang from the external border of the laminæ cribrosa and jutted into the vitreous for a distance of one millimetre, disappearing after absorption of the retinal hæmorrhages.

Bach, of Würtzburg, [254 Dec.,'93] made a microscopical examination of the eyes of a female, 49 years old, affected with *syphilitic retinitis*, and found that the larger retinal arteries were the seat of a partial and annular inflammation of the adventitia as well as the intima, while in those of smaller calibre and in the capillaries the intima was found to be more often affected,—a condition which, in many instances, led to their closure. The veins were but slightly involved. The rest of the ocular tissues were unaffected. The author therefore concludes that it is possible to have a primary disease of the retina which is dependent upon the retinal blood-vessel system, and not secondary upon a choroiditis. From personal experience and study, Randolph, of Baltimore, [764 June,July,'94] concludes that: "1. Visual disturbances occurring in the first six months of pregnancy, and especially when associated with violent headaches, frequently mean *albuminuric retinitis;* and if this condition is found, in order to save sight, pregnancy should be at once terminated. 2. Visual disturbances showing themselves in the last seven weeks of pregnancy, while indicating the same retinal lesion, are of less grave import in so far as sight is concerned, and, unless very pronounced and associated with wide-spread ophthalmoscopical changes, should not in themselves call for the induction of premature labor, for literature shows that in such cases the sight is completely restored after labor. This is especially true when the retinitis shows itself in the last two weeks of pregnancy. 3. The occurrence of renal retinitis in one pregnancy does not mean that the woman will be likewise affected in a subsequent pregnancy, and, even though headaches be present and albumin found in the urine, so long as the fundi are free from the usual signs of an existing albuminuric retinitis, the question of sight should not properly be considered." He has had the opportunity of making an histological

study of the retina in a case in which the ophthalmoscope showed, throughout the retina, large white plaques which were confluent in the macular region, presenting a solid white background. The microscopical changes were: 1. Great œdema of the entire retina. 2. Hyperplasia of the neuroglia, especially marked in the nerve-fibre layer. 3. Hyaline masses with the formation of spaces throughout the retina, most pronounced in the external molecular layer. 4. More pronounced changes in the region of the disc, this being especially true of the nodules, which likewise extended almost to the ora serrata. Fatty degeneration of Müller's fibres was not detected, but the author believes that this may have been due to the method employed in hardening (Müller's fluid) and to post-mortem change.

Fuchs, of Vienna, [204] gives the name of *retinitis circinata* to a group of cases presenting characteristics enough in common to warrant their being described as a separate form of disease. Among 70,000 patients in the past seven years, he has only seen eleven cases of the disease. One other he had previously noted. Of this number ten were women of an average age of 60 years. In seven instances the disease was confined to one eye. As a rule, vision was much impaired and was the cause of all the cases seeking medical advice. The disease runs a chronic course, and may lead to permanent thickening of the retina or the changes may wholly disappear. Ophthalmoscopically there are two distinct types, the disease either appearing as a gray or grayish-yellow opacity in the macula, or as a belt of small white spots or larger white areas about it. The accompanying plate illustrates these different types. In the early stage the macular patch is small and limited, while later it may attain or even surpass the size of the disc, its edges becoming confluent with the surrounding retina, which is usually more or less hazy in this position. The belt of opacity is usually separated from the macula by a clear area, and is more often incomplete, being divided into an upper and a lower portion by breaks at the sides. It is elliptical in form, and may or may not include the papilla in its circumference. It is made up of numerous milk-white spots free from pigment, of a smaller diameter than the larger retinal vessels, which always pass over them. These spots may be either isolated or confluent. Vitreous opacities and detachment of the retina were observed in several

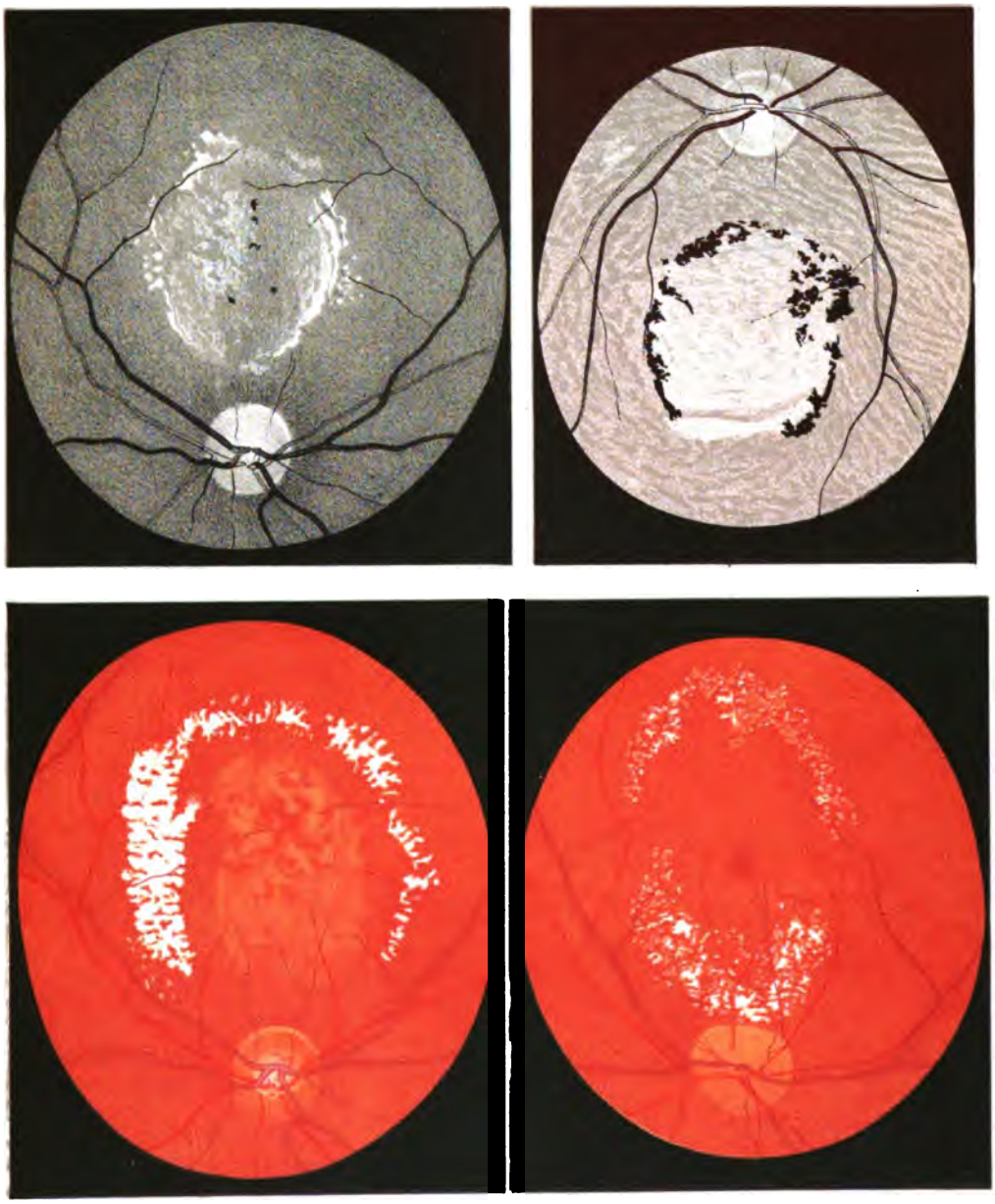

BURK & McFETRIDGE CO. LITH PHILA

Retinitis Circinata (Fuchs.)

Archiv. für Ophthalmologie

instances, whilst small hæmorrhages and, in the latter stages, pigment-spots were sometimes seen in the macular patch. The author believes that the spots are due to an exudation of albuminous fluid into the granular layer of the retina, the arrangement of the patches corresponding to the course taken by the retinal fibres above and below the maculæ from the upper and lower margins of the disc. Of the etiology nothing is known. The disease may be diagnosed from guttate choroiditis by the yellowish color of the dots in this latter affection, and from retinitis punctata albescens by the fact that this latter disease is usually seen in young persons of the same family, the dots being scattered throughout the entire fundus. De Wecker, of Paris, [274 Jan.,'94] does not believe that this form of retinitis is other than the fatty changes previously described by himself and Masselon, which occur in eyes that have been the seat of a retinal apoplexy. He has seen the disease in about the same proportion of cases as Fuchs (15 in 140,000), and has noted that the white areas of degeneration propagated themselves in a centrifugal direction about the macula, whilst between this latter and the affected area there was always a zone that had escaped pathological change. In the majority of cases the retinal vessels did not exhibit any structural change, although, in some instances, they were unduly tortuous. In the aged, however, the vessel-walls were thickened and showed evidences of perivasculitis. The fact that the author once observed a case in which there was the typical picture of retinitis circinata in one eye, while in the other were found changes peculiar to diabetes, has strengthened him in his view of the apoplectiform nature of the former condition. He has never seen the degeneration-areas disappear, nor has he observed them surrounded by a circle of pigment. He considers the disease to be one of slow progression, and cites an instance which he has had under observation for the past twenty years.

A peculiar case of *varicose dilatation of the retinal veins* has been seen by Westhoff, of Amsterdam. [190 June,'94] In the left eye there was a large retinal detachment with very tortuous veins, but in the right the ophthalmoscope revealed a large lateral coloboma to the nasal side with veins enormously dilated, following the usual course of those in the retina. A widely-extended vein, with curious dilatations, ran directly across the colobomatous area to the papilla. Examination of the heart showed it to be normal. Uhthoff [173 Apr.,'94] has

reported two cases of *embolism of the central artery of the retina.* In the first instance, a man 37 years old had complained of trouble in the vision of the left eye three years before death. The visual field remained unaffected only in its most central part. The ophthalmoscope revealed an obliteration of the arteries due to an optic atrophy. With the exception of too small arterioles, all the other vessels were obliterated. Pathological examination revealed the presence of an embolus in the central artery of the retina, which was situated in the optic nerve and was probably of endocarditic origin. The second case was that of a woman, 27 years old, who had a cardiac affection and presented a thrombus of the left carotid artery reaching up to the point of origin of the ophthalmic artery. The ophthalmoscopical finding was that of an embolus of the ophthalmic artery. Death followed three days after the appearance of the ocular symptoms. In a case of embolism of the central artery of the retina, seen by Barkan, of San Francisco, [147 Feb.,'94] massage produced a marked improvement in the retinal circulation and in vision.

Brailey, of London, [2 Dec.22,'93] gives the notes of a case of *failure of central vision* in an otherwise healthy man aged 57 years. In the left eye, which was first affected, there was absolute loss of central vision for form and color after two years, but, excentrically, form-vision was reduced to $\frac{1}{12}$ dioptre and color to $\frac{1}{8}$ dioptre of standard. The ophthalmoscope showed degenerative sequelæ of the retinal pigment-epithelium, and of the chorio-capillaris. The left eye exhibited similar, but less advanced, changes; there was a central scotoma, and excentric vision was reduced to $\frac{1}{8}$ dioptre for form and $\frac{1}{8}$ dioptre for color. Jack, of Boston, [99 Mar.29,'94] reports a case of *thrombosis of the central artery* of the retina of the left eye in a woman 43 years of age. Fourteen months previously, following confinement, the patient had been attacked with a right monoplegia, probably of cerebral origin, and for a period of six weeks previous to the appearance of the ocular affection had had attacks of sudden blindness in the affected eye, occurring at irregular periods and lasting from ten minutes to one hour. The attacks were ushered in with severe pain in the eye, and with chemosis of the conjunctiva. The ophthalmoscopical appearance was typical of embolism with an unusual amount of œdema. Marlow, of Syracuse, [1 Feb.17,'94] describes a case of *retinitis pigmentosa* with extreme

contraction of the visual field, but without night-blindness, in a woman 20 years of age. Central vision was almost normal.

Becker, of Heidelberg, $\frac{204}{\text{B.39,H.3}}$ has studied three cases of *glioma of the retina*, which give support to the views held by Gama Pinto as to the nature of that disease. The first instance occurred in a child 10 weeks old, the characteristic reflex being noticed but a few days before the eye was enucleated. A similar growth was found in the other eye. In the second instance a tubercular growth was suggested by the diffuse cloudiness of the vitreous in one of the eyes, induced by a slow cyclitis from a glioma in an early stage. A glioma in the other eye had been noticed directly after birth. A spontaneous hæmorrhage into the anterior chamber obscured the nature of the third case for a long time. Microscopically, all of the tumors presented a marked alveolar arrangement, broad layers of cells being arranged concentrically around the vessels, each lobe thus formed being separated from the others by areas of necrosed cells. As the general form of these growths bore a definite relation to the distribution of blood-vessels within their substance, the author considers them as angiosarcomatous in character. Mitra, of Ranchee, $\frac{1055}{\text{Mar.16,'94}}$ has performed enucleation for glioma of the retina in a child 5 years of age. For three months the patient remained free from any complaint, when symptoms of paralysis of the left extremities appeared, followed by coma and death. Rucker, of Eufaula, $\frac{73}{\text{Nov.,'93}}$ has enucleated the left eye of a girl 2 years of age for the same disease. There was a return of the growth in six weeks, followed shortly by death, probably from exhaustion.

Moulton, of Fort Smith, $\frac{506}{\text{Aug.15,'94}}$ performed enucleation, on account of a similar growth, in a child 5 years of age. The tumor occupied one-third of the cavity of the globe, and consisted of small, round, granular, nucleated cells in a fine, scant, fibrous matrix which spread out between the choroid and the retina. Intimately connected with the fibre-layer of the latter membrane there was a circular plate of tissue three-fourths inch in diameter and one or two millimetres in thickness. The tissue was quite dense, and was histologically similar to the retinal growth. The matrix, however, was still more dense. Webster, of New York, $\frac{51}{\text{Jan.,'94}}$ describes a case of recurrence of a glioma in a 2-year-old child, notwithstanding that the eye had been enucleated shortly after the disease appeared. A microscopical examination of the globe showed that

the optic nerve was intact, but that the sclera was sparsely infiltrated in places, and its blood-vessels congested.

Buller, of Montreal,[252 Dec.,'98] has observed a case of *white sarcoma of the retina*, in an eye enucleated for subacute glaucoma, occurring two years subsequent to sudden loss of sight. The patient was a woman of 49 years of age. A case of *gliosarcoma of the retina* with recurrence and colossal metastasis is reported by Van Duyse.[274 Feb.,'94] The tumor appeared in the left eye in a child 6 years old. The right eye was blind from ophthalmia neonatorum. When first seen the ophthalmoscope revealed a yellowish-white tumor in the fundus. A second observation, made one year later,

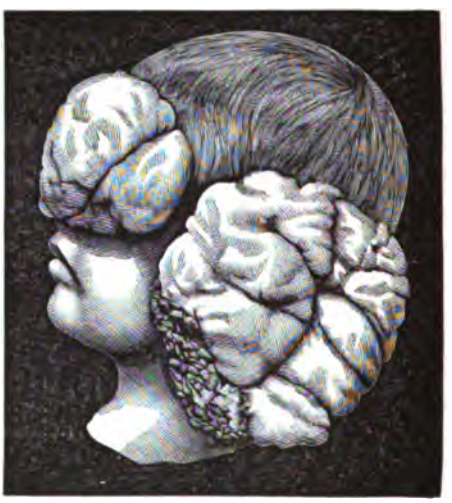

RECURRENT METASTATIC GLIOSARCOMA OF ORBIT. (VAN DUYSE.)
Archives d'Ophtalmologie.

showed no signs of the growth, but there were large plaques of choroidal atrophy and other evidences of intense disturbance to the deeper ocular tissues. The eye becoming blind, the patient came under observation at the end of another year, when enucleation was performed, although the diagnosis of glioma could not yet be made. Six weeks after enucleation the growth had recurred. Exenteration was performed, but the tumor appeared again, the picture presented by the accompanying sketches being obtained shortly after. The author explains the apparent disappearance of the tumor by an absorption of the growth sufficient to escape ophthalmoscopical detection. A comprehensive report of the

macroscopical and microscopical appearances of the growth is appended.

The same author [274 Jan., '94] has made a microscopical study of a case of *glio-angiosarcoma of the retina*, finding the tissue to present a yellowish-brown coloration situated between a series of cellular tubes, and a yellowish coloration of these tubes. The lamina vitrea had everywhere opposed the peripheral extension of the glioma. The most striking feature in connection with the retina was its richness in vessels and the isolated distribution of its elements. The primary tumor was represented for the most part by cells that had undergone a nuclear degeneration, the necrotic tissue forming a striking contrast with the vessels of an acinous configuration which traversed the regressive gliomatous masses. The disassociation of fragments of the gliomatous tissue and a study of the sections showed the existence of five types of vessels. The author explains the identity of the tissue between the tubes and that composing them by a supposed relative independence between the two structures, both representing different phases in the development of the same tissue.

DISEASES OF THE OPTIC NERVE.

Johnson, of London, [2 Sept. 15, '94] has found that in no case where workmen engaged in a glass factory have been exposed for several years to the furnace-light did their eyes escape without some permanent loss of vision resulting from a gradual atrophy of the optic nerves; whereas those having the same environments, but not exposed to the light of the furnace, escaped more or less completely. He states that the best protective measure consists in covering the upper three-fourths of the side-openings in the furnace with sheets of annealed, spectrum, blue glass, leaving room beneath for the workmen to introduce and manipulate the molten glass.

Hermann, of Coblentz, [190 v. 17, p. 366, '94] cites an instance of *choked disc following the extraction of a tooth*, visible ophthalmoscopical signs being left by the inflammation of the nerve, notwithstanding that treatment was promptly inaugurated. The swelling of the disc was first seen a few hours after the tooth was removed, and was attended with great visual disturbance. Both irides reacted promptly to light. There was a partial paralysis of the abducens

on the right side. The urine was normal, and the general condition of the patient (a 15-year-old boy) was seemingly excellent. The ocular symptoms were probably due to a hæmorrhage at the base of the brain, affecting the chiasm and the right abducens nerve.

Carpenter, of Philadelphia, 451 Nov.,'93 records two instances of *hyaline formations in the optic nerve*, both in elderly women. In neither instance was there any evidence of a similar change in the choroid. Rossenmeyer, of Frankford, 254 Dec.,'93 reports a case of *atrophy of the optic nerve* caused *by sympathetic inflammation.* The exciting eye had been enucleated upon account of iridocyclitis, the result of a perforation by an iron chip. The enucleated globe was examined by Sattler and no microbes were discovered. Symptoms in the sympathizing eye first appeared four weeks after the removal of the offending organ.

In a case of white atrophy of the optic nerves, in a child of 13 years of age, Magalt, of Nice, 173 May,'94 succeeded in improving vision from light-perception to the ability to read ordinary print, by means of hypodermatic injections of strychnine, continued for a number of months. Risley, of Philadelphia, 451 Mar.,'94 gives notes of an interesting case of optic atrophy, in a woman 28 years of age, in which vision increased, in five months' time, from $\frac{5}{200}$ in the right eye and $\frac{3}{200}$ in the left to $\frac{6}{6}$ and $\frac{6}{7\frac{1}{2}}$, respectively, without a corresponding improvement in the appearance of the optic nerves. The patient resided in a high altitude when the affection began. An examination made at that time showed decided enlargement of the inferior branch of the central vein in the left eye, followed in a short time by shrinking of that vessel and total disappearance of the "arteries of the disc." When first seen by the author, two months later, the right optic disc was gray-green in its outer half, and the left was greenish white throughout. The retinal vessels were about normal in size in both eyes. The field for form in each eye presented no abnormality. In the right eye the red field was fleeting, whilst in the left eye it was lost except for a small area in the nasal half. Improvement followed a sojourn at the sea-shore and administration, during the same period, of the "four chlorides," with iodide of potassium.

Gillet de Grandmont, of Paris, 171 Jan.,'94 has observed a case in which *optic neuritis, infectious in origin*, was propagated from one eye to

the other by means of the meninges, which were, in all probability, the seat of a serious inflammation. The patient, a child 4 years old, was shot by a revolver in the right eye and the deeper-lying tissues. The right eye shrunk and the left one became blind as a consequence of optic atrophy. Subconjunctival injections of sublimate were administered, and vision improved somewhat, until trephining was necessitated by symptoms that pointed to an abscess in the left motor region. The hemiplegia which had existed disappeared after the operation. One month later the child could count fingers at five metres' distance.

Braunschweig, of Halle, [204 B.39,H.4] has made a valuable contribution to the study of *primary tumors of the optic nerve*, reporting four cases, together with a new operative procedure. In all of the cases there was exophthalmus and the tumor could be outlined by the finger. In two instances the growth was removed in the usual way with conservation of the globe, while in the others it was extirpated by an osteoplastic operation. In the first case there had been no recurrence after five and a half years, and in the other three a cure was obtained. In one instance death ensued some time after the operation, doubtless from a brain-tumor. From a grouping of these and other reported cases the author draws the following deductions: The left nerve is the one usually affected; 29 cases have been recorded as occurring in the first ten years of life and 29 in the second, 9 cases between the twentieth and thirtieth years, 4 between forty and fifty, and 60 after the fortieth year. Heredity seems to have no influence, while trauma originates the condition in a number of instances. The middle of the nerve between both ends of its orbital portion is found to be the seat of choice for the development of the tumors. This is doubtless accounted for by the entrance of the retinal vessels in that position. Exophthalmus is the most constant symptom, the direction being usually that of the axis of the orbit. The globe is generally proptosed down and out. Strabismus is the first sign of the development of the growth. In regard to the time of the beginning of the exophthalmus the author has differentiated four types: (1) where blindness precedes the exophthalmus; (2) where vision begins to fail at the same time with or immediately after the appearance of the exophthalmus, and the failure continues until total or partial blindness results,

as in the majority of cases; (3) where vision begins to fail a long time after the appearance of the exophthalmus; (4) where vision is but little or not in the least affected. This last class consists only of certain endothelial tumors the diagnosis of which was in doubt. Though there are no characteristic ophthalmoscopical appearances by which to diagnose this disease, nevertheless the regular early appearance of inflammation and swelling of the optic-nerve head is most striking, and can, when other symptoms fail, suggest the nature of the disease. In regard to the behavior of the iris, there is no reaction to light-stimulus when complete amaurosis exists, although it usually reacts to consensual stimulation, which is due to the late conservation of the ciliary ganglion. The diagnosis depends upon (1) the long absence of inflammation and the painless course, (2) too early blindness or rapid diminution of the visual acuity, (3) the relatively unrestricted movement of the globe, and (4) a palpable tumor inside of the ocular muscles binding the globe and optic foramen together. The essential point in the operation described by the author is the excision of a segment of bone out of the external wall of the orbit, in order to gain free access to the contents of that space,—a procedure suggested by Krönlein. The operation is quite simple and may be rapidly performed, and healing follows without difficulty or disfigurement. Upon account of the facility with which the growth may spread to the brain, progress should always be guarded. Pathologically, tumors of the optic nerve may be divided into the smaller group, endothelial in nature, and the larger, which comprises myxoma, myxosarcoma, neuroglio-sarcoma, fibrosarcoma, and fascicular sarcoma.

From the clinical study of a case of tumor of the optic nerve, occurring in a girl 17 years old, Adamük, of Kasan, $\frac{254}{\text{Oct.,'98}}$ concludes that the periphery of the retina is not wholly dependent upon the blood-vessels of that membrane for its supply, but that the choroidal circulation also aids in the nutrition. In this case the tumor was excised and the globe conserved, the growth being so extensive, however, that it required so free a division of the bulbar attachments that not a single posterior ciliary artery escaped being cut. Notwithstanding this fact, after subsidence of a corneal opacity, which the author thinks was due to the circulatory disturbance, the fundus was seen to still present a red reflex, while the lumen

of the retinal vessels was narrowed. For months after the operation the vessels were still narrow and the papilla was much atrophied. Two months subsequent to the operation the iris had begun to atrophy and finally took on the appearance of a grayish membrane. The lens and the vitreous retained their transparency. The same author [254 Feb.,'94] reports two additional cases with a fatal ending. The first occurred in a man, 35 years old, who was blind and presented no other symptoms except headache. A cylindrically-shaped tumor projected nine centimetres from the right orbit. Upon its summit were the flattened remains of the globe. The relatives of the patient stated that the right eye had been blind ever since he was 4 years old, but that the left eye, in which the ophthalmoscope revealed the existence of an atrophied disc, had only been blind since his eighteenth year. In this eye the optic nerve had presented a peculiar excavation, which the author attributes to traction made upon it by the pressure of the growth. Extirpation of the tumor revealed its cyst-like nature, and also showed that the cranial cavity had been invaded. The optic foramen was much increased in size. The patient died of meningitis eleven hours after the operation. The chiasm was found to be almost obliterated by the growth and was drawn over toward the retinal side. The sella turcica was involved in the process and the pituitary body was semi-atrophic. Histologically the growth proved to be a myxosarcoma. The second case occurred in a patient 28 years old. The diagnosis of an hæmatoma of the orbit had been made, and the growth had been punctured upon several occasions, septic fluid being injected into it in the hope of absorption. After the death of the patient from apoplexy, section showed that the superior and posterior parts of the orbit were the seat of a new growth which had invaded the brain. Microscopically it proved to be a cavernous sarcoma. As in the preceding case, notwithstanding the extensive amount of damage done to the brain-structures, there had been no preceding paralytic symptoms.

Darier, of Paris, [173 Apr.,'94] reports a case of *exophthalmus with œdema of the lids and conjunctiva*, in which the first symptom appeared eight years previously, vision being unaffected for a long time. The diagnosis of a tumor of the optic nerve was based upon a weakness of the internal rectus muscle and upon a progressive degree of ptosis and proptosis. Lagrange, of Bordeaux, [70 Jan.,'94]

extirpated a growth from the orbit of a child 5 years of age. It proved to be a myxosarcoma of the sheath of the optic nerve, and from microscopical examination seemed not to have interfered with the functions of the optic nerve. Salzmann, of Vienna, [204] has had an opportunity of studying, clinically and pathologically, three cases of a similar nature in patients aged, respectively, 5, 9, and 46 years. In the first two instances the tumor was extirpated and the globe was conserved. The microscopical appearance in all three cases were so similar that the author grouped them under one description. He found two varieties of spindle cells with long processes, showing evidences of hyaline change. In addition to these, numerous round cells were associated with the blood-vessels, around which were grouped blood-corpuscles and pigment-particles, showing the hæmatogenic origin of the pigment of the optic nerve. The walls of the vessels were thickened as the result of hyaloid degeneration, this change being most marked in the oldest portion of the growths. The normal tissue from which the tumor had sprung was not simply pushed aside, but was incorporated into it. The intervaginal space was affected in each instance, but the nerve-fibres had escaped. A narrow strip of normal nerve-tissue separated the neoplasm from the globe in each case, the tumor reaching posteriorly to the optic foramen. The author thinks that the growths arose from the posterior portion of the orbital portion of the nerve, and that they grew anteriorly, either by true tissue overgrowth, proliferation and enlargements of the cells, or by an increase in the intercellular fluids. He is also inclined to think that after the tumor has reached a certain growth its tendency to spread posteriorly ceases.

Weiss and Brugger [254] have studied the *relationship between deformity of the skull* (*Thurmschädel*) *and disease of the optic nerves*, and reported the case of a boy, 14 years old, in whom there was a marked degree of exophthalmus. The eyes were slightly hypermetropic. The optic nerves were partially atrophied and a granular change in the macular region was considered as suggestive of an early neuroretinitis. The head of the patient was small and very high, and a well-marked spinous process corresponded to the site of the anterior fontanelle, while the orbits were much shallower than normal, as shown at *K* in Fig. 1. The authors measured a number of similarly-deformed skulls, and

Fig. 1.

Fig. 2.

Inner and Outer Aspects of Steeple Skull. (Weiss and Brugger.)

Archiv für Augenheilkunde.

BURK & McFETRIDGE CO. LITH PHILA

found that their sagittal diameter was the one that was usually diminished in size, whilst the breadth of the skull differed but little from the normal. The height of the orbit was found to be always larger than its breadth, whilst its aperture presented the form of a more or less perpendicular oval. The optic foramina were not encroached upon in any of the specimens, but in every case there was a marked lengthening and anterior distribution of the dorsum sellæ (Fig. 2). This anomaly may have exerted pressure upon the chiasm in early youth, and thus have given rise to the affection of the nerves. It is of interest to note that in no instance was there any evidence of such a disease.

A careful study of a case of *retrobulbar neuritis* in a 19-year-old lad has been made by Sachs, of Innsbruck. [254 Oct.,'98] Pathological examination of the nerve was rendered possible by death from phthisis. The patient used tobacco. Clinically the case presented the usual ophthalmoscopical findings of amblyopia ex abusa, and there was a circummacular scotoma in each eye. The author gives the name of "nuclear region" (*Kern Stelle*) to the fibres in the nerve, which physiologically manifest themselves in the field when diseased as an oval scotoma between the fixation-point and the blind spot. In the right nerve, at least, he believes the origin of the disease to have been clearly an inflammation of the posterior central vein of the retina. Reissert, of Strassburg, [254 Dec.,'98] cites an instance of a case of retrobulbar neuritis with sudden complete binocular blindness, in which vision was re-established. The patient was a healthy man, 22 years old, who became totally blind in twenty-four hours without apparent cause. The ophthalmic findings suggested a retrobulbar inflammation of the nerves. There were no cerebral symptoms, and, in the absence of any other cause to account for the condition, the author suggests that a great excitement to which the patient had been subjected by the death of a near relative might have originated the disease. When visual acuity began to return the field was found to be normal peripherally, whilst there was a relative scotoma for white and a positive one for color at the fixation-point. After a time, however, the field for white became normal, but a pure central relative scotoma for colors remained.

Moll, of Berlin, [190 Sept.,'98] cites an instance of a young man, of good family and personal history, who suffered from retrobulbar

neuritis of a recurrent type. All toxic agents could be excluded. The left eye was alone affected, and three recurrences had taken place. The author attributes the condition to a localized periostitis of the optic foramen. Two cases of hereditary optic-nerve atrophy have been observed by Kœnig, of Paris. [173 June,'94] The first, a young man 22 years old, had suddenly developed the symptoms one year before, these being preceded by marked cephalalgia. The brother of his maternal grandmother had suddenly become blind at 30 years of age. An uncle and first cousin on his mother's side were also blind. In the second instance the grandmother of the patient had had five girls and five boys, three of the latter developing optic atrophy between 20 and 25 years of age. One of the daughters had a son who became completely blind. The author is inclined to accept the explanation offered by Berger for the genesis of this affection.

Swartzbach, of Sydney, [557 Jan.,'94] reports an instance of retrobulbar neuritis, the cause of which he attributes to an effusion into the nerve by violent retching accompanying an attack of seasickness.

Oliver, of Philadelphia, [2036 '94] in a short note on the so-called hereditary optic-nerve atrophy, states that the disease, "which manifests itself as faulty transmission, teaches us conversely that a peculiar physical condition which has been obtained from frequently-repeated physiological acts during the life-existence of some antecedent containing animal form may be transmitted to the offspring (more particularly by consanguineous ties of the parents), and thus render the new organism more capable of evolving certain definite acts that are the physiological representatives of heredity of physical structure; the partial answer, at least, for so-termed hereditary genius."

A case of *toxic amblyopia*, apparently due to the use of tobacco and alcohol, in which vision diminished from normal acuteness to counting fingers at two feet, within a period of twelve hours, has been seen by d'Oench, of New York, [59 July 14,'94] in a man 40 years of age. There was distinct sector-shape atrophy of the temporal side of the optic nerve, with central color-scotoma. Rapid improvement of vision followed the withdrawal of the toxic agents and the hypodermatic use of strychnine.

In a case of *quinine amaurosis* observed by Claiborne, of New York, [59 Aug.18,'94] there was only sufficient improvement in vision at the

end of three years to enable the patient to see slightly by reflected light. Vision was still further reduced when direct or strong light was employed. From a study of the subject the author concludes that (1) quinine in toxic doses may produce blindness; (2) the toxic dose is distinctly indeterminate; (3) the duration of the amaurosis varies greatly; (4) the field of vision remains contracted; (5) the central vision usually returns to normal; (6) there is color-blindness at first, color-perception being ultimately restored in the central field; (7) the ophthalmoscopical picture is that of white atrophy; (8) experiments on dogs show that there is atrophy of the entire optic tract; (9) the same experiments show that the cells of the cuneus are probably not affected; (10) treatment is of no avail.

Perles, of Berlin, 190 Oct.,'98 reports six cases of *choked disc consecutive to intra-cranial growths*, doubtless gummatous in nature, in all of which, in spite of considerable change in the nerves, the vision and field of vision were almost normal. After a prolonged course of mixed treatment the swelling in the optic-nerve heads disappeared; the appearance of the discs became normal and continued so for years afterward. When, however, treatment is delayed until the regressive change of choked disc has set in, and the vision and field have materially suffered, the ophthalmoscope always reveals the traces of a previous inflammation by the discoloration of the disc and the streaks along the vessel-walls. An optic neuritis, infectious or chemical in nature, is always accompanied by a disturbance in the function of the nerve and a visible change in the fundus.

WOUNDS, INJURIES, AND FOREIGN BODIES.

Snell, of Sheffield, 2 Sept.15,'94 does not consider that the frequency of cataract in glass-blowers is due to the heat and sweating to which the workers are exposed, as the same conditions in iron-workers do not seem to induce the disease. Electrical welders suffer from excruciating eye-pain, with swelling of the lids and lachrymation, and those employed in burnishing silver suffer from hyperæsthesia of the retina. Of one hundred and fifty or more fragments of steel removed from the eye with the electro-magnet, not one patient was a female.

Pinckard, of Chicago, 1018 July,'94 reports a case of *lacerated wound of*

an *eye* caused *by* a *spectacle-lens* being broken by an umbrella. The patient recovered, with a vision of $\frac{20}{20}$. T. G. Morton, of Philadelphia, [19 Mar.10,'94] gives notes of a case of pistol-ball wound of the brain, dividing the left optic nerve in the optic foramen. Shortly after the accident the pupil of the left eye was moderately contracted, but two hours later it was widely and fixedly dilated. An examination of the eyes, five days after this, showed the temporal half of the nerve to be leaden white and devoid of capillarity. Contraction of the vessels, more especially the arteries, throughout the fundus, and a small hæmorrhage below the disc were also visible. There was a subconjunctival hæmorrhage to the temporal side of the cornea. Post-mortem examination revealed the fact that the optic nerve had been completely severed by the ball.

Dehn, of Rostock, [204 B.40,H.2] cites an instance of *luxation of the eye* in a girl, 15 years old, who, while in a maniacal frenzy, had literally "gouged her eyes out" with her finger-nails. The left eye was completely eviscerated, and the right contained several large holes in the sclera where the fingers had perforated the globe. All the muscles were torn away from their attachments. The numerous small hæmorrhages and the signs of reactive inflammation of the ends of the muscle-fragments gave evidence of repeated attempts at avulsion. The hæmorrhages in the sheath of the optic nerve, found microscopically, were produced either by the direct pressure of the finger-nails or by the traction exerted upon them.

Leviste, of Dreux, [171 Sept.] describes a case in which a *cilium* remained *in* the *anterior chamber* for twelve years. At the end of that time the removal of the foreign body became necessary by reason of lancinating pains. Rivers, of Denver, [249 Jan.,'94] cites an instance of *injury to* the *eyes from* a heavy charge of *electricity*, the cornea and the conjunctival tissue being escharred. The patient, however, obtained a visual acuity of $\frac{20}{30}$ in the right eye and $\frac{20}{20}$ in the left after the subsidence of the inflammation. The disturbance in vision, which persisted after all the acute external symptoms had subsided, was, he thinks, due to the effect upon the retina of the excessively bright light to which it had been exposed, and not to the current itself. Wintersteiner, of Vienna, [204 B.40,H.2] has made an interesting contribution to the pathological study of *traumatic aniridia and iridodialysis.* In two cases observed by him

there had been a rupture of the sclera, prolapse of the uveà, aniridia and aphakia, with hæmorrhages into the vitreous. In the first instance the prolapse was formed by the iris, in the second by the ciliary body. The author accounts for the condition in the latter case by the supposition that, at the same time with the rupture in the sclera, a total annular detachment of the iris had occurred, this entire membrane being swept out of the eye. The detachment and the prolapse of the ciliary body then followed, being independent of the iridodialysis through the action of the dislocated lens. In neither case was there any trace of lenticular matter. From the study of a third case, the author is of opinion that iridodialysis occurred before the scleral perforation was completed. Here, also, as in the two preceding cases, the iris was completely detached from its insertion. The notes of several other cases are given in which the iris-prolapse was so small that it was entirely hidden by the conjunctiva, although a pigmentation in the neighborhood of the limbus directed attention to the nature of the condition. In one case the border of both dialyses was formed by an iris-prolapse. The author attributes the hæmorrhage in these cases to the wound in the ciliary body and to rupture of the greater arterial circle of the iris. In 1000 cases of injuries to the eye, Ottinger, of Manheim, $^{353}_{\text{Mar.,'94}}$ found that the right eye was affected 398 times and the left 602 times, the latter being the more usually affected by accidents received while at work, from the fact that most men are right-handed and the left side of the body is thus the more exposed.

Hattenhoff, of Geneva, $^{173}_{\text{June,'94}}$ reports a case of double isolated *paralysis of accommodation consecutive to a thoracic wound* produced by a hat-pin. The ciliary paralysis developed itself without involvement of the pupils about three weeks after the accident, and lasted six months. The author thinks that this condition was produced by an atrophic lesion of the bulbar centres of accommodation, due to infection, of which the attendant fever and the accompanying erythema were the indices.

From a series of experiments to determine the *influence of wounds upon the histology of the retina*, Tepljaschin, $^{254}_{\text{May,'94}}$ of Kasan, found that every wound of the retina, whether attended by disturbance in the sclera or choroid, must be regarded as a severe ocular injury. The parts of the retina disturbed mechan-

ically were not alone found to be changed, but there was always an accompanying atrophy of the nerve-elements in the neighborhood of the wound.

Carter, of London, $\frac{1077}{\text{Sept.12,'94}}$ is of the opinion that so long as an injured eye remains aseptic some hope may be entertained for its recovery, but that whenever the inflammation assumes a septic character Mules's operation or enucleation should be performed without unnecessary delay. Whenever sympathetic ophthalmia has developed, mercury by inunctions, together with quinine internally, until its physiological effects appear, should be indicated.

Duffing, of Dossenheim, $\frac{204}{\text{B.40,H.3}}$ gives the results of an examination of an eye which had been doubly perforated by a fret-saw. The saw had entered the eye through the corneo-scleral junction down and out, and, after perforating the vitreous, had bored its way out upon the internal border of the superior rectus muscle. Four weeks afterward marked inflammatory symptoms, as shown by cloudy media, elevation of tension, together with a small tumor upon and in the point of exit of the wound, evidenced themselves. Enucleation was performed. At the point of entrance of the instrument there was a small intercalary staphyloma, while at the point of exit there was a scleral staphyloma three millimetres high. The ocular walls in the region of the wound were much thickened and the fibres of the newly-formed tissue ran parallel to those of the sclera.

Taylor, of Wilkesbarre, $\frac{61}{\text{Sept.15,'94}}$ pleads for more *conservative treatment in wounds of the eyeball*, and cites several cases of serious injury where non-operative treatment attained excellent results. In an article on extraction of steel from the eye with the electromagnet, Hubbell, of Buffalo, $\frac{227}{\text{Apr.,'94}}$ emphasizes the utility of the *electro-magnet in ophthalmic surgery* and recommends its early employment. He advocates a more general adoption of the sclerotic incision as the safest method of reaching steel when it lies at any point, supposed or known, in the vitreous humor or the inner coats of the eye, even to a disregard of the original wound.

Hotz, of Chicago, $\frac{19}{\text{Apr.14,'94}}$ reports two cases of success and one of failure in the *extraction of metallic foreign bodies from the vitreous*, and asserts that the operation should not be performed in any case where the injury to the eye is so serious that disfiguration or atrophy of the globe is sure to result.

The accompanying illustration represents a powerful *magnet* devised by Haab, of Zurich. [217 Jan.,'94] It consists of a sixty-centimetre-long, cylindrical-shaped cell of soft iron, provided at both ends with blunt corners, the outer one of which is capable of being removed for purposes of disinfection. Two coils of copper wire encircle the cell. The electrical current is furnished by an ordinary dynamo. The instrument is capable of bearing a current of 20 to 30 ampères. The patient is seated in front of the instrument and his elbows are rested on the shelf provided for that purpose upon the stout wooden support of the magnet. The author thinks that much better results can be obtained from the use of this instrument than from smaller ones of the same class, and claims, by its employment, to have brought all iron chips over $\frac{2}{200}$ gramme in weight, which had been imbedded in the deeper tissues of the eye, into the anterior or the posterior chamber. Deutschman, of Hamburg, [217 Jan.,'94] substantiates this statement of Haab's, by citing a case of a foreign body in the anterior chamber where an attempt at its removal by the Hirschberg magnet caused it to recede into the vitreous. The chip was finally recovered, however, by the employment of a large magnet of high power, and the eye regained useful vision.

MAGNET. (HAAB.)
Beiträge zur Augenheilkunde.

Fernatola, of Messina, [173 Apr.,'94] believes that enucleation is too frequently practiced after gunshot wound of the eye. He has treated 22 such cases without finding a pathogenic microbe in any of them: 14 of the eyes became phthisical, 5 suppurated, and only 1 remained in its normal condition. If rigorous antisepsis be employed in this class of cases, post-traumatic cataract is but little to be feared. Jackson, of Philadelphia, [112 Oct.,'93] has enucleated an eye from which he had some weeks previously removed a piece of iron by means of the magnet, enucleation being rendered necessary upon account of sympathetic irritation in the other eye. Two interesting cases of sympathetic ophthalmia are cited by Thompson, of Kansas City, [1007 Apr.,'94] the first being remarkable from the fact that the inflammation did not develop until fourteen months after enucleation of the exciting eye, and the second from the fact that there was a most extraordinary decrease of the intra-ocular tension.

Noyes, of New York, [2035 '94] has observed a case in which a foreign body had been imbedded in the eye sixteen years without producing any symptoms. It finally became inflamed and painful, probably from the liberation of a quantity of lenticular calcareous matter by an attempted operation on the lens. Weeks, of New York, [2035 '94] reports a case of *sympathetic ophthalmia* occurring forty-two years after the loss of the exciting eye, the detection of a recent extensive inflammation of the coats of the exciting organ showing it to be the cause of the disorder in the sympathizing one. After enucleation of the exciting eye, the fellow recovered with useful vision. It is of interest to note that the exciting cause of the inflammation must have come from within, as the eye was lost not as a result of the traumatism, but from a perforating ulcer following measles. From clinical observations and from experiments made upon animals, Bocchi, of Pavia, [173 Apr.,'94] concludes that the *inflammatory process in sympathetic eyes* is probably due to a chemical irritation of the changed intra-ocular liquids upon the ciliary nerves. Enucleation is the only operation that will effect a cure, and, as he has seen the disease follow two instances of adherent leucoma, he advises this plan of treatment. Ziem, [171 Sept.,'94] of Dantzig, states that in every case of *sympathetic irritation* it is necessary to examine the nasal and neighboring cavities and to institute methodical treatment in order to shorten the duration of a traumatic iridocyclitis and lessen the danger of sympathetic irritation.

GLAUCOMA.

Nicati, of Marseilles, [78] Apr., '94 concludes that the tensor muscle is the principal motor and producer of tension, and that it contracts reflexly in order to follow the oscillation of the tension of the blood, and accidentally, also, to follow other causes—aqueous secretion and external pressure—capable of acting in the same way. The centre of this reflex is situated in the anterior of the eye. Since it acts even after enucleation, it should be attributed to the nervous ganglion-cells scattered throughout the thick portions of the muscles. He thinks that there is a form of glaucoma occasioned by the non-exit of the aqueous humor which is associated with tearing pains of the tensor muscle, and another form that is due to paralysis of the tensor and rupture of the vessels from removal of the check for the maintenance of ocular tension. The first is curable by a simple operation, but the latter is incurable. He employs a tenometer for the purpose of testing ocular tension, and has constructed a formula by which its work can be registered.

Galezowski, of Paris, [173] Aug., '94 believes that *glaucoma* may be regarded as *a lymphangitis of the eye*, and curable by repeated sclerotomies, which he performs with a small lance-shaped knife. The principal cause of the disease lies in a total or partial obliteration of the canal of Schlemm, the changes seen elsewhere being consecutive. Beccaria, of Turin, [30] V.22, Nos.2-6 to show the *mechanical nature of secondary glaucoma*, cites an instance of traumatic luxation of the lens into the anterior chamber. When the head was bowed forward and the lens made to rest upon the ciliary body, the glaucomatous state supervened, while if the patient turned upon his back the lens slipped back into position and the glaucomatous symptoms subsided at once.

Bitzos, [171] Aug., '94 believes that the *initial lesion of glaucoma simplex* consists in a papillitis, interfering with the passage of the lymph from the eye and producing an increase in the intra-ocular tension, and the consequent changes in the anterior segment of the globe. This form of the disease is only an attenuated variety of the inflammatory type, the initial papillitis having an almost characteristic appearance, resembling the form of neuritis seen in retinitis pigmentosa,—*i.e.*, yellowish red in color, slightly œdematous, the disc becoming finally grayish yellow. The retinal arteries are narrowed and the veins are somewhat dilated. Usually a peripapillary zone

of choroiditis is present. The stage of congestion does not begin until about two months after the commencement of the optic-nerve trouble. The lesions in the nerve consist microscopically of a cellular infiltration of all the connective tissue of the papillary portion and that occupied by the nerve-fibres. This infiltration gives way later to sclerosis and to an hypertrophy of the connective tissue of the lamina cribrosa of the optic nerve and of the walls of the vessels, the calibre of the vessels becoming entirely or partially obliterated. Richey, of Washington, [1018 July,'94] thinks that the glaucomatous halo may "depend upon irritation of the retina and optic nerve," and that it is not caused by simple hyperæmia, but by precipitated urates; or that it may be due to the presence, in the aqueous or vitreous humor, of urates in the shape of rhombic prisms or amorphous granules (with or without spines), with power to cause diffraction of light. The prisms formed by sodic chloride plus urea at least have this faculty.

Terson, of Paris, [274 June,'94] has studied the *effect of dislocation of the lens upon the production of glaucoma.* His conclusions are drawn from the pathological study of two cases, in both of which there was a marked increase in tension. In the first instance the angle of the anterior chamber was perfectly free, while in the second it was somewhat involved, although its upper part was also patulous. The subluxation of the crystalline of the first case was regarded as causing the lesion in the ocular membranes in the posterior segment of the eye. In the second instance, however, the luxation appeared to have been a result of the glaucoma. The author believes that a glaucoma which is produced by dislocation of the lens need not necessarily depend upon a blocking up of the angle of the anterior chamber, as hypertonia may exist without this latter condition being present, the blocking being rather the result of repeated glaucomatous attacks, which originate from the disturbance in the intra-ocular vascular pressure, caused by a sclerosis of the retinal vessels.

A case of *buphthalmus* with conservation of $\frac{2}{3}$ visual acuity, occurring in a 13-year-old boy, is reported by Warlomont, of Bruges. [173 June,'94] One eye was emmetropic and the other possessed a slight amount of myopic astigmatism. The corneal curvatures were normal. The author considers the pathology of this disease to be practically the same as that of simple glaucoma, the tissues,

however, being more yielding in youth, and the ocular membranes being, therefore, able to accommodate themselves to the new condition of lymphatic circulation.

Smith, of Birmingham [76 July,'94] cites an instance of *hereditary glaucoma* in which the affected eye was smaller than normal, while the lens was unduly large, producing a blocking of the filtration angle. He believes that this disproportion is the cause of the hereditary glaucoma. From observations based upon the study of 282 cases of glaucoma, Neuburger, of Berlin, [190 Jan.,'94] finds that the disease is more frequent at the age of 40 years than between the ages of 10 and 30 years, the tendency increasing from 30 years, especially after the fortieth year is passed. Women are more disposed than men, the ratio being 100 to 175.

In an instance of glaucoma with large hæmorrhages and peculiar changes in the retina, seen by Hesch, of Basel, [254 Apr.,'94] notwithstanding that the retina was filled with hæmorrhages, it was but little altered, and there was no evidence of atheroma of its vessels. There was, however, a peculiar localized atrophy of the optic nerve.

Berberich, of Seckenheim, [204 B.40,H.2] gives the report of an *anatomical examination* of two cases *of secondary glaucoma produced experimentally* in the eyes of rabbits. In one case a sterilized deposit and in the other a portion of alcoholic extract of the streptococcus aureus was introduced into the anterior chamber. In the first case a fibropurulent kerato-iritis developed, which led to secondary glaucoma with pathological excavation and stretching of the tunics at the corneal limbus. In both eyes the angles of the anterior chamber became obliterated. The author regards the presence of several points of degeneration in Descemet's membrane, associated with the formation of hyaline substance, as proof of an ulceration in the inner layers of the cornea. In the second case there was a formation of colloid bodies, and the corneal epithelium showed degenerative changes that are common to glaucoma. The periphery of the iris was atrophied by traction, while the central portion was scarcely changed. The lens was intact, but in the choroid and retina there were slight changes attributed to pressure. In both eyes there were pressure changes at the sclerocorneal junction. The author suggests that the absorption of the material in the anterior chamber by the angle of the chamber

probably gave rise to a scleritis, which lessened the resisting power of the tissue. Viquier, of Bordeaux, [188 Nov.5,'98] has enucleated an eye upon account of hæmorrhagic glaucoma, finding the disc excavated, but no aneurismal dilatations in the retinal vessels. The fundus was filled with hæmorrhages, a large group of them occupying the macular region.

Oliver, of Philadelphia, [451 Sept.,'94] has made clinical and microscopical study of two cases of *glaucoma associated with intra-ocular hæmorrhages.* The first case was seen in a well-cared-for, but dissipated, man of 62 years of age. Embolic and thrombotic processes were evidenced in an eye which for some time had been affected with hæmorrhagic retinitis with increased tension. A broad iridectomy was successfully performed, vision returning to normal and pain being lessened. This improved condition lasted for six weeks, when, fresh hæmorrhages occurring, associated with intense pain, the eye was enucleated. Physical examination showed both peripheral and cardiac vascular disease. Microscopical examination of the globe showed all the evidences of old perivasculitis and retinal disintegration, mostly limited to the inner layers, the posterior pole, and the optic-nerve entrance. Sequelæ of both old and new hæmorrhagic extravasations were found in the larger cavities and thrust in between the more compact tissues. The ciliary bodies, folds, and muscles were markedly enlarged, and the remnants of loose, fresh blood-clots in and around the vessels could be seen. The angle of the anterior chamber seemed to be opened, though choked with pigment *débris* and pigment corpuscles. The second case occurred in a healthy man of 40 years of age. The left eye was blind, as the result of hæmorrhagic glaucoma. In the right eye the tension was markedly increased and vision was reduced to light-perception in an area of twenty degrees around fixation, except below, where it extended to fifty-five degrees. An iridectomy was made, central vision increasing to $\frac{2}{50}$, and a large central field for red and white being obtained. In the course of eight months there was a gradual return of the glaucomatous symptoms, vision falling to light-perception. A second iridectomy was performed, followed in a few months' time by extraction of the crystalline lens, which had become opaque. Since the last operation vision has increased to $\frac{3}{50}$, and the field for form and color embraces the fixation-point.

RIGHT EYE

Burk & McFetridge Co Lith Phila.

Glaucoma with Intra-Ocular Hæmorrhages (Oliver)

International Medical Magazine.

LEFT EYE.

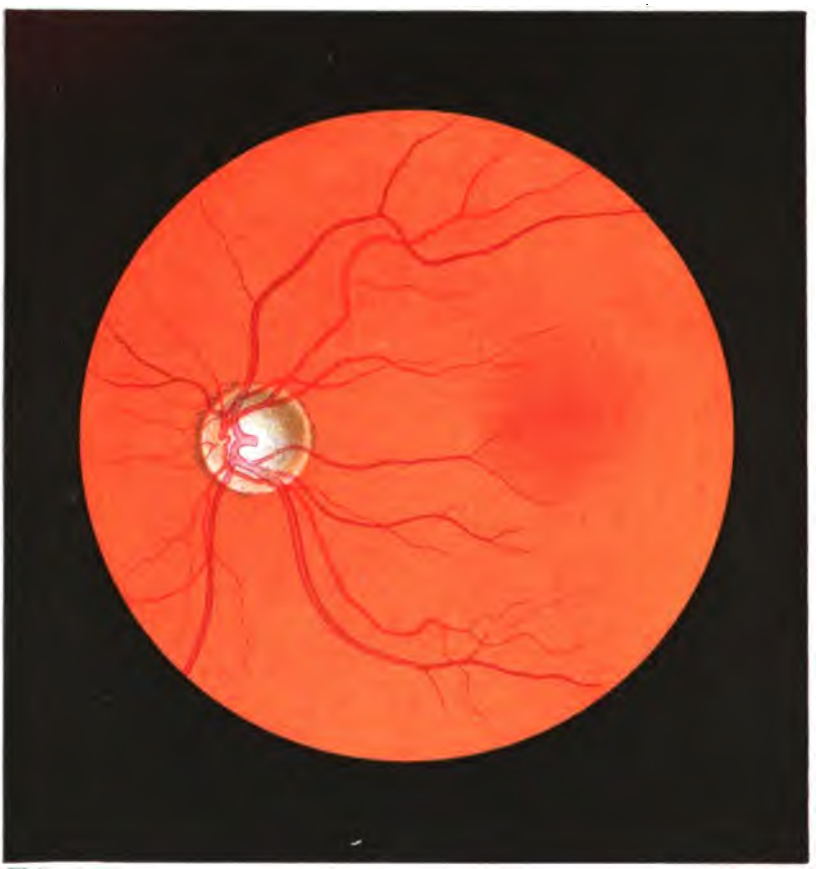

BURK & McFETRIDGE CO LITH PHILA

Glaucoma with Intra-Ocular Hæmorrhages (Oliver)

International Medical Magazine.

The ophthalmoscope showed a deep, almost complete glaucomatous cupping of the disc and marks of old blood-extravasation in the deeper-lying tissues. The accompanying chromo-lithographs show the ophthalmoscopical appearances in the first case very well. From a consideration of these cases, the author concludes that in some extremely rare cases secondary to slight recurrent attacks of intra-ocular hæmorrhage, especially in young and comparatively sthenic subjects in whom the vascular system is not greatly involved, the organ may be kept for much longer periods of time than ordinary in a condition of usefulness by appropriate hygienic and general therapeutic measures, care being taken to slowly perform operative procedures whenever there is urgent necessity to relieve increased intra-ocular tension.

Terson, of Paris, [173 June,'94] has made a microscopical examination of two eyes the subject of glaucoma, secondary to luxation of the crystalline lens. In both the angle of the anterior chamber was free, while in the first there was a deep excavation in the optic-nerve head. The author thinks that these cases show that an absolute glaucoma, with excavation of the disc, may exist for a long time without an accompanying obliteration of the canal of Schlemm, and that luxation of the lens does not apparently give rise to hypertonia, at least in every case, by blocking up the angle of the chamber, but by producing lesions posterior to the iris in the ciliary body, more especially in the retina and the vitreous.

Hesch, of Basel, [254 Apr.,'94] reports an instance of excavation of the optic-nerve head in an aphakic eye in which a chronic glaucomatous condition had arisen, producing pain upon the slightest exertion. To relieve this neurotomy of the optic and ciliary nerves was performed, when atrophy of the optic nerve supervened, and with the increase in tension the retinal-nerve fibres became compressed in the head of the disc, giving rise to the excavation which was thus produced by the action of both agents,—*i.e.*, glaucomatous pressure and optic atrophy.

Nicati, of Marseilles, [78 Jan.,'94] proposes an operation which he calls a *new sclero-iritomy*. The knife is plunged into the eye at the union of the cornea and sclerotic, parallel to the iris, and brought out at a point diametrically opposite. The blade is then turned one-fourth of a revolution to bring it in contact with the iris, and an incision made perpendicularly to the first, involving the sclera

and the iris, the blade being then withdrawn. In the treatment of glaucoma the author concludes that equatorial sclerotomy should be preferred when it is necessary to produce rapid re-establishment of the anterior chamber and the resolution of an œdema of the vitreous which persists in spite of the successful operation for glaucoma. Sclero-iritic puncture or the primary sclero-iritomy just described should be adopted as a preventive operation, and one which will cure cicatricial staphyloma of the cornea or cicatricial glaucoma. Iridectomy itself should be reserved for glaucoma with pupillary occlusion. Sclero-iritomy should be the operation of choice in spontaneous glaucoma. From a study of three instances of hæmorrhagic glaucoma, together with the literature of the subject, Risley, of Philadelphia, [112 Nov.,'94] states that in the future he would "first of all perform sclerotomy or paracentesis of the vitreous chamber, and, having thus relieved the tension of the globe and possibly secured a deeper anterior chamber, perform either a free sclerotomy or, if the iris was moderately healthy, a broad iridectomy."

From a state of total amaurosis induced by a glaucomatous attack, Kuvel, of Sofia, [204 B.40,H.2] caused vision to improve to counting fingers at ten centimetres with the right eye, and at one metre with the left eye, by the performance of a double iridectomy. Logetschnikow, of Moscow, [353 Mar.,'94] claims priority to Knies in the treatment of glaucoma by iridectomy with conservation of the pupillary border of the iris. De Wecker, of Paris, [171 May,'94] draws attention to the service rendered to ophthalmology by Quaglino's introduction of the operation of sclerotomy in the treatment of cases of glaucoma.

SECTION V.

MEDICAL OPHTHALMOLOGY.

As showing the connections between ocular affections and disease of the *nose* and *ear*, Rohrer, of Zurich, [171 Mar.,'94] states that he has found microbes to be three times more numerous in purulent rhinitis than in the simple form of the disease. Guibert, [173 July,'94] of Paris, claims to have cured fifty diverse cases of corneal and conjunctival disease by the removal of adenoid growths from the *pharynx*. Campbell, of St. Louis, [776 July,'94] gives notes of several cases

illustrating the fact that heterophoria is frequently the result of reflex nasal irritation. When this is the case, no form of operation upon the eye-muscles will do anything but harm, and relief will only be obtained when the cause is recognized and removed.

Hubbell, of Buffalo, [170 Sept.,'94] denies that *nasal and naso-pharyngeal diseases* are *causative factors* in the production of *phlyctenular affections of the eyeball*, believing that the constitutional conditions and a scrofulous diathesis simply afford common ground for various bacterial invasions. Consequently, success in treatment can be obtained by giving particular attention to each expression of the disease present, together with such general measures as tend to strengthen tissue-resistance and favor regeneration. Schloss, of Stockton, [77 Jan.,'94] claims to have cured a case of asthenopia which had resisted ocular treatment by the removal of nasal obstructions.

Schapringer, of New York, [347 Oct.,'93] reports the case of a child, 9 months old, who exhibited paralytic symptoms of the ocular branches of the sympathetic nerve, apparently consecutive to a retropharyngeal abscess. The symptoms observed were ptosis and myosis. There was no enophthalmus. The frequent association of *impetigo contagiosum* with phlyctenular disease of the eye leads Carpenter, of London, [51 June,'94] to suggest the possibility of the ocular affection being produced by pus-inoculation. As ocular defects originate reflex symptoms in remote organs, Young, of Burlington, Iowa, [106 Mar.,'94] sees no reason why the converse of this should not be true, and that asthenopia may result from lesions in parts that are remote from the eye.

Andogsky, of St. Petersburg, [353 v.22,p.363,'94] reports two cases of *chronic spasm of the orbicularis muscle produced by* the presence of *tape-worms* in the alimentary canal. Boice, of Toledo, [776 July,'94] records a series of cases of eye affections apparently of reflex origin. In two they were seemingly dependent upon nasal disease, in one upon dental caries, and in another upon rectal and uterine disturbance. Parsons, of Laramie, Wyoming, [1018 Apr.,'94] had under his care a man with a phlyctenular ulcer which had resisted all treatment, but which improved rapidly after the dilatation of a *narrowed meatus urinarius*. Bore [173 Aug.,'94] states that ocular hystero-traumatisms are more frequent than is usually supposed, and that they belong to the severe forms of *hysteria*. They are observed to follow railroad accidents, and consist in erythropsia, hemi-erythropsia, spasmodic

astigmatism, monocular diplopia, spasmodic strabismus, nystagmus, mydriasis, etc. They often constitute a form of mono-symptomatic hysteria, and may appear as initial symptoms in persons who have never presented any neuropathic phenomena. This should be borne in mind before attempting any operative procedure. An instance of monocular *paralysis of the superior oblique muscle following diphtheria*, in a 12-year-old child, is reported by Kraus, of Magdeburg. [190 Feb.,'94] The ciliary muscle was not affected, and the diplopia disappeared under general hygienic treatment. Friedenwald, of Baltimore, [9 Oct.21,'93] has observed paralysis of both external rectus muscles in a child, 5½ years old, who three weeks previously had had a slight attack of diphtheria.

In a case seen by Thompson, of Cardiff, [2 Sept.15,'94] *keratomalacia* was associated with jaundice in a 2-month-old child. At the height of the affection there was swelling of the lids, marked icterus of the conjunctivæ, and complete greenish-brown opaqueness of each cornea, the central portions of which were paler than the peripheral, being separated from one another by a wavy, sunken line of demarkation. Both corneæ sloughed within forty-eight hours. The child died ten days later.

A case of sudden and complete *blindness*, appearing *during* the course of an attack of *malarial fever*, is reported by Despagnet, of Paris, [173 July,'94] in a woman 23 years of age. When examined ophthalmoscopically some time after the attack, the optic discs were seen to be very pale, the retinal veins were somewhat full, the arteries were filiform and accompanied by small white stripes. The vessels were much reduced in size at the periphery. There was no trace of hæmorrhage or of exudation. Examination of the urine was negative. Satisfactory improvement in vision followed the administration of potassium iodide, thus leading the author to emphasize the importance of active treatment in this class of cases, notwithstanding their apparent hopelessness.

Gayet, of Lyons, [171 June,'94] reports two cases of *ocular manifestations* occurring *in* the course of a *cardiac affection*. The first case was that of a man, 30 years old, who developed panophthalmitis and aural abscess as the result of an infectious endocarditis. The second was also one of endocarditis, which was, however, rheumatic in character. The author thinks that toxins were carried to the eyes by the lymphatics.

Garrison, of Dixon, [77 July,'94] reports the occurrence of *exophthalmus with tachycardia* in a twin child 3 months old. Rapid improvement followed the administration of arseniate of strychnia and the removal of the patient to higher and dryer climates.

Pollock, of St. Louis, [364 Dec.15,'93] has seen a case of *proptosis* in a man whose skull presented a large *depression in the occipital bone*, slightly to the left of the median line. The patient claimed that the condition was congenital. The tension of the eye was considerably increased, but the sight was unimpaired. Rapid improvement followed the use of bichloride of mercury and the local application of hot water.

Barrett and Webster, of Victoria, [265 May 20,'94] give the notes of three cases of *ophthalmoplegia.* In the first instance there was paralysis of the external rectus muscle and of all the muscles supplied by the third nerve with the exception of the internal rectus in the left eye. Both eyes were myopic and the vitreous contained floating opacities. The history of the woman's pregnancies gave evidence of constitutional syphilis. The authors believe the lesion to have been a specific affection of the nerves at the entrance to the orbit. The second case was seen in a man, 30 years of age, who had contracted syphilis seventeen years previously. There was bilateral ophthalmoplegia interna with incomplete paralysis of the oculo-motor nerve. Both optic nerves were partially atrophic. Despite the use of large doses of potassium iodide, the affection steadily progressed. The third case was one of progressive paresis of the ocular muscles with almost complete optic atrophy, occurring in the course of tabes.

Uhthoff, of Marburg, [204 B.30,H.2] contributes the results of his clinical observations in syphilis of the central nervous system. The sensory and motor nerves of the eyes were found to be frequently affected. Of 100 cases there were 34 instances of paralysis of the oculo-motor, 16 of the abducens, 5 of the trochlearis, and 14 of the trigeminus. The palsies occurred, as a rule, in the later stages. Of the oculo-motor palsies, the double-sided lesion was especially common, and depended upon a basal process. In two instances there was disease of the tract, with homonymous hemianopsia. In only 1 case in 250 did hemianopsia depend upon the softening of the hemisphere, this occurring when the oculo-motor root was alone affected, and without any functional disturbances. Disease

of the chiasm and the consequent hemianopsia, associated with double-sided oculo-motor paralysis and extensive change at the base, appeared twice. The tracts were affected in nearly half of the cases, the rest of the motor nerves, as well as the olfactory, being also at times involved. Isolated double-sided oculo-motor paralysis was rare, and depended upon a gummatous degeneration of the roots. Monocular oculo-motor affections without crossed hemiplegia were mostly basal in origin, and in two-thirds of the cases this form of paralysis was associated with paralysis of other cranial nerves. When crossed hemiplegia existed the lesion was found either in the region of exit of the motor nerve or in the peduncle or pons. Isolated ophthalmoplegia interna was rare, and depended upon a nuclear or fascicular palsy. Periodically-recurring paralysis of the oculo-motor nerve seemed to depend upon a disease of the cortex. Double-sided abducens paralysis was produced by a basal affection, and occurred twice as often as the monocular form, this latter type being due to disease of the pons. Among 250 cases the trochlearis was affected eleven times, being nine times monocular and twice binocular. The oculo-motor was always affected at the same time, and other nerves were frequently involved. A basal lesion occurred in each instance. Trigeminal paralysis was always monocular and depended upon a basal lesion. Keratitis neuroparalytica showed itself very rarely. Nystagmus and nystagmic twitchings of the eye-muscles were observed only four times in 250 cases, and conjugate deviations of the eyes once in 100 cases. Reflex pupillary inactivity to light, generally with conserved reaction to convergence, was observed in about 14 per cent. of the cases; hemianopic pupillary inaction only once, and monocular, hippus-like contraction upon pupils which were almost inactive to light but once. The visual conducting apparatus was comparatively very seldom affected, disease of that system being generally associated with a post-neuritic atrophy, and more seldom hemianopsia.

Disease of the eyes was absent in but 15 per cent. of all collected cases affected with syphilis. In the hereditary type of the disease the central nervous system was implicated in the same manner as in acquired syphilis, although the globe itself seemed to be more often affected in the former. Tabes combined with syphilis of the brain appeared but four times among 100 cases.

Du Gourlay, of Dinard, [171 Feb., '94] cites seven instances where the presence of cerebral symptoms enabled him to diagnose tertiary syphilis as the etiological factor in a group of different ocular affections. He points out that an examination of the tibiæ, the naso-pharyngeal space, and especially of the functions of the brain, should be made in doubtful cases. A simple meningeal irritation, as evidenced by nocturnal headache, is of great diagnostic value. If the ocular lesions are asymmetrical, and are not associated with cerebral lesions, they may be regarded as secondary.

Bach, of Würtzburg, [254 Dec., '93] states that *tubercular infection of the eye* is not uncommon, and that all parts of the eye can be affected by it, the uveal tract being most frequently attacked. Ocular disease may be the only and the earliest manifestation of tubercular affection. The disease may occur upon the lids in three different types, isolated and diffuse and in the form of chalazia; it may appear as an ulcer on the conjunctiva or may simulate the clinical picture of trachoma. The author describes a case in which there were a number of miliary tubercles upon the tarsal conjunctiva and fornix of the upper lid and a sickle-shaped ulcer in the cornea near its limbus. The corneal affection is usually secondary to an involvement of the pectinate ligament by the tubercular process, although the corneal limbus may be primarily the seat of tubercle. The typical parenchymatous keratitis, however, can only occur when the tubercles are found in nearly all parts of the pectinate ligament. The uveal tract is most prone to be affected, and in this form of iritis the growths are usually situated upon the ciliary border. There are but few posterior synechiæ, while opacities upon Descemet's membrane are usually very numerous. In the experience of the past seven years he has found tubercular infiltration of this membrane to be quite as common as syphilitic. The ciliary body is generally in a state of chronic inflammation, often associated with hæmorrhages into the vitreous. In the choroid the disease may take the form of either the acute or chronic type, whilst in the retina the process is usually found in the nervous layer. Small, yellowish-white tubercular prominences may occur on the optic-nerve head. Tuberculosis of the optic nerve occurs most frequently as part of a tubercular meningitis in an acute and a chronic form. Blennorrhœa of the lachrymal sac may be produced either by tubercular ulceration of the canaliculi

or by a tubercular disease of the bony walls of the canal, with secondary disease of the mucous membrane.

Simon, of Berlin, [190 May,'94] reports three cases of *retinitis albuminurica* in which violet-blindness appeared as a marked symptom. In all three cases there was pronounced evidence of neuro-retinitis. The disturbance in color occurred at the fixation-point, and was characterized by the fact that blue was taken for green. The author believes that the source of the phenomena resides in a disturbance of the retina in the macular region, and not in the nerve itself. As the visual disturbance was but temporary, the substance for blue was either only damaged or destroyed, and easily replaced by a special production of the cones. Mauthner, of Vienna, [152 Dec.,'93] believes that a *diminution in* the *amplitude of accommodation* seen *in* five *diabetic subjects* is dependent upon a general muscular weakness affecting more particularly the internal rectus muscles. Germaix, of Algiers, [171 Oct.,'93] has observed an instance of pseudoretinitis pigmentosa, consecutive to a septic choroid retinitis induced by *varioloid*, in a patient 4 years old. Vision was at first much impaired, but improved progressively under tonic treatment. The discs were pale, the retinal vessels narrow, and the characteristic pigment-bodies present. There was slight hemeralopia, and the visual fields were much contracted, being represented by two narrow, inferiorly-placed sectors.

Herrnheiser, of Prague, [353 May,'94] has examined microscopically an eye taken from a lad who had died of *septicæmia*. Before death the ophthalmoscope revealed areas of exudation and hæmorrhage similar to those seen in pernicious anæmia. The choroid was filled with clumps of bacteria, these organisms being not nearly so numerous in the retina and having no more apparent connection with the exudated areas than had been observed clinically. Neither was there any apparent change in the blood-vessel walls that could account for the presence of the hæmorrhages. The author states, therefore, that bacteria occur accidentally in microscopical sections of the retina and choroid from individuals who have died from septicæmia, and that in such cases he has found changes in the retina in 32.6 per cent. A considerable number of patients who have marked retinal changes as a result of septicæmia recover perfectly, the hæmorrhages occurring very soon after the commencement of the disease.

In regard to the relationship existing between *siderotic* and *hæmatogenic pigmentation*, von Hippel, Jr., of Heidelberg, [2087 v.22,p.30,'93] has concluded as follows: 1. The iron reaction with ferrocyanide of potassium and an impure form of hydrochloric acid is obtained without exception even upon old sections. 2. The Berlin-blue reaction gives the same results as Quincke's with ammonia sulphide. 3. There is a true siderosis bulbi, which may originate either directly from foreign bodies or from the blood. 4. The hæmatogenic siderosis is entirely independent of hæmatogenic pigment. The hæmosiderin is a form of pigment whose color is independent of iron. 5. The siderosis appears especially in the epithelium of the ciliary processes,—the pars ciliaris, the retinæ, and the capsule of the lens. 6. The xenogenic siderosis originates from a precipitation of the carbolic acid of the tissues of the iron. 7. The greenish hue is not diagnostic of a foreign body of the globe. 8. The characteristic cross of brown spots under the lens-capsule is produced by a deposition of iron in the localized heaps of proliferated capsule epithelium. 9. Extensive degeneration of the retina follows the introduction of an iron chip into the vitreous. 10. The same changes have been observed in the human retina. 11. The introduction of blood into the vitreous simulates the changes which occur after the instillation of the foreign body. 12. When blood is injected into the vitreous after previous puncture of the anterior chamber, a bursting of the anterior capsule of the lens may occur.

Pignatari, of Naples, [78 Jan.,'94] reports sixteen cases of *dacryoadenitis consecutive to influenza*, twelve being subacute and four chronic. All the patients were between 35 and 50 years of age. This complication of influenza is rare, and usually benign.

Elschnig, of Gratz, [204 B.30,H.4] has had an opportunity in two instances of studying, both clinically and pathologically, the influence of *occlusion of the ophthalmic and carotid arteries* on the eye. In the first instance, although the ophthalmoscope revealed but a slight paleness of the optic disc, the post-mortem examination showed chronic endo-aortitis, thrombosis, and obliteration of the left common and internal carotid arteries beyond the origin of the ophthalmic artery. There was also incomplete obstruction of the latter; encephalomalacia, hypertrophy, and dilatation of the left ventricle. A polypoid plug of connective tissue, of probable em-

bolic origin, had obstructed the ophthalmic artery in the middle of the optic canal. The branches of the ophthalmic artery were partially sclerosed, but exhibited a normal calibre. There was a chronic perineuritis of both optic nerves, most marked at the seat of arterial obstruction. In the second case there was a complete thrombosis of the left internal carotid and the commencement of the left ophthalmic artery. Organization of the clot had occurred, and the circulation had been partially re-established by canalization. The arteries of the eyes were normal. The author concludes that thrombosis of the ophthalmic artery has no direct influence upon the ocular circulation. A series of injection experiments upon the dead body showed that under normal conditions the orbital vessels are not exclusively supplied by the ophthalmic artery, but also by the external carotid and its branches.

Gasparrini, of Siena, [30 v.22,Nos.2-5] inoculated pure cultures of the *diplococcus of Fraenkel* into the conjunctival sac, the cornea, the anterior chamber, the iris, and the vitreous of rabbits, and found that the cultures obtained their maximum degree of virulence in two days, and that all pathogenic action was lost in five days. In 25 cases of hypopyon keratitis he detected the diplococcus in the *débris* of the ulcer and in the secretion of the dacryocystitis which caused the condition. In 13 cases the diplococcus occurred alone. In 8 the staphylococcus was found. In 3 advanced cases no diplococci were noticed, and the inoculations made from these cases were not virulent.

A case of stubborn, recurrent, *herpetic disease of the conjunctiva and cornea, in conjunction with menstrual disturbance of the menopause*, is cited by Stuelp, of Hanover. [204 B.40,H.2] The disease took the form of a small loss of corneal tissue with fatty, uneven edges, and resembled a phlyctenule in appearance. Its summit had undergone ulceration. The eruption differed from that which is characteristic of herpetic disease by its disposition and appearance. Thompson, of London, [2 May 19,'94] reports a case of *chemosis and amenorrhœa, with symptoms of brain disease*, in an unmarried woman of 23 years of age. For a period of nine months the patient suffered from headache, dizziness, vomiting, drowsiness, anorexia, and constipation. For a short time there was diplopia. Typical choked discs appeared in each eye, and a hæmorrhage could be seen near the disc in the left eye. At the end of two and a half years, under

the use of iron and arsenic, all the symptoms disappeared and the optic nerves became normal in appearance. Derby, of New York,[2035 '94] reports four cases of affections of the eye, apparently dependent upon uterine derangement. In two instances the disease took the form of a retrobulbar neuritis. In the other two the ophthalmoscope revealed a neuro-retinitis with retinal extravasation and hæmorrhage.

An instance of temporary blindness during the period of *lactation* is reported by Heinzel, of Vienna.[217 Jan., '94] Failure of vision occurred seven weeks after the confinement of a 25-year-old primipara. The ophthalmoscope revealed a double optic neuritis of a low grade of intensity. Five days after the acme of the disease, notwithstanding that there was only light-perception in the left eye and none at all in the right, vision in the right eye equalled counting fingers at fifty centimetres and in the left at twenty centimetres. The visual fields were contracted, especially below. There was no central scotoma. Two months later vision equalled $\frac{5}{6}$ partially in both eyes, but the patient complained of seeing objects as blue. This symptom, together with the ophthalmoscopical findings, pointed to a slight degree of post-neuritic atrophy of the optic nerves, probably due to poisonous substances which had arisen from the tissue change during lactation, and which had set up a retrobulbar inflammation of the nerves. Puech, of Bordeaux,[70 Jan. 14, '94] cites an instance of suppurative choroiditis, occurring in a woman 40 years old, the result of *puerperal fever* following a miscarriage.

Lombard [197 Mar. 30, '94] notes an example of temporary blindness consecutive to *lead poisoning*. The blindness came on suddenly, and was complete for several days. The author thinks that this condition was produced by a modification of the blood induced by the poison.

Callan, of New York,[2035 '94] reports a case of sudden monocular blindness, without ophthalmoscopical changes, which lasted two months. It occurred in a woman 52 years old. There was a detachment of the retina in the right eye, which could not be accounted for by any local or general disturbance. The urine was normal. The first symptom of blindness in the left eye was the perception of phosphénes and a veiled appearance of all objects. Owing to the nervous condition of the patient the field of vision could not be obtained. Shortly after the eye became totally

blind. Two weeks before the death of the patient, which occurred some months later, the face assumed a fixed, anxious expression, and the co-existence of a degree of proptosis with a quickened pulse suggested Basedow's disease. Autopsy revealed an old pachymeningitis on both sides. The sheaths of both optic nerves were clotted with sago-like drops, owing to a probable constriction of the trunks in front of the chiasm. The left nerve was twice the diameter of the right, which was shrunken in its sheath and smaller than normal. Several round-celled gliomata were found: one beneath the angular gyrus and cuneus; one in the white matter beneath the cortex, interrupting the radiation of Gratiolet, which looked like broken-down tubercular material; one in the superior parietal lobe; and one, the largest, attached to the cerebellum.

Silcock, of London, 1077 Aug. 8, '94 records two instances of *herpes ophthalmicus associated with paralysis of the ocular muscles.* The first case occurred in a man aged 58 years, the third and fourth, sixth, and first division of the fifth nerves being involved. In the second case (a man of 79 years of age) there was complete ophthalmoplegia externa, proptosis, and a glaucomatous condition of the eye, with hypæmia. The first case was benefited by iodide of potassium. Green, of Pueblo, Col., 1018 July, '94 cites an instance of paralysis of accommodation resulting from diphtheria, in a girl 15 years old. Careful inquiry failed to elicit more than that she had suffered from a severe sore throat six weeks previous to the appearance of the ocular condition.

Two cases of *congenital external ophthalmoplegia* are reported by Gazepy, of Athens. 274 May, '94 The patients were brother and sister. Their parents were healthy, and the father had a brother and sister who were not diseased, but whose children presented the same lesion as the patients in question. The author is of the opinion that the condition was atavistic, being inherited from the paternal grandfather.

An interesting case of *multiple ocular paralyses* was observed by Eales, of Birmingham, 32 Aug., '94 in a woman aged 20 years. The affection began with paralysis of the right sixth. Two months later blindness and deafness, associated with paralysis of the facial nerves on the same side, occurred. Later the optic nerve showed incipient primary atrophy. The paralyses were gradually recov-

ered from. About one year from the primary attack the left sixth and seventh nerves became paralyzed. Both attacks were ushered in by persistent headache confined to the affected side. As the disease improved under iodide of potassium, the author suspected the cause to be a gummatous formation. Eliasberg, of Solonica, [190 May,'94] reports a case of *ptosis with monocular paralysis of the right oculomotorius*, occurring in a child 5 months old, symptoms coming on gradually and being intermittent in character. The ptosis developed after fever. The author regards the case as of nuclear origin. Parenteau [173 June,'94] reports two cases of *intermittent muscular paralysis*, in neither of which was migraine a prominent symptom. The first was that of a female, 24 years old, in whom the first attack appeared several months before puberty. The second occurred in a 16-year-old boy. The attacks in both cases were preceded by general malaise and vomiting, without true hemicrania. Darquier, of Paris, [171 Oct.,'93] has observed an instance of recurrent paralysis of the third nerve, consecutive to attacks of migraine, in a woman 65 years old, of a nervous temperament, although presenting no signs of hysteria. The paralysis was always preceded by a localized hemicrania, accompanied by attacks of violent vomiting and diarrhœa. The attacks lasted several days. For several years the paralytic seizures were limited to the left side. The same phenomena then appeared upon the right side. Ptosis was complete, and in repose the eye deviated externally. Abduction was almost abolished. Looking downward was accomplished more readily. Adduction was intact. Diplopia existed in the left half of the visual field. The fields were not contracted, and the visual acuity was the same in both eyes. The paralysis disappeared after several months. The author lays particular stress upon the pain which precedes these attacks, and points out that the autopsies that have been made thus far have invariably revealed a pathological condition of the third nerve, whilst the nuclear centres have been unaffected. Three instances of paralysis of the ocular sympathetic-nerve fibres are described by Gradle, of Chicago. [1018 July,'94] Characteristic symptoms were present in all three cases. There were no other nervous lesions nor any secondary changes.

From the observation of four cases of *exophthalmic goitre*, Berger, of Paris, [274 Feb.,'94] concludes that the increased lachrymation which occurs in that condition is not entirely the result of the exoph-

thalmus and the consequent insufficient weeping, but that it may occur several years before any other symptom of the disease, and may persist for years after the disappearance of the exophthalmus. On the other hand, the dryness of the conjunctiva may show itself when the protrusion of the globe is diminishing. The increase in dryness during the progressive stage, he thinks, is due to the more rapid evaporation of the tears from exposure of a greater part of the globe to the air. The increase in lachrymation is dependent upon an hypersecretion in the lachrymal glands, and the dryness to a diminution in the secretion.

Sulzer, of Geneva, [171] has had an opportunity of observing two cases of *Gerlier's disease* (paralytic vertigo). In the first instance there was slight ptosis; the temporal halves of the discs were pale and the nasal red and swollen, the latter being more marked on the right side, on which there was also a corresponding greater diminution in the visual acuity. The second case presented practically the same clinical picture. The visual fields in both instances had similar limitations, there being symmetrical narrowings in the superior halves, complicated in one eye by a loss of a quadrant in the inferior half. The symptoms are best explained by the existence of a cortical lesion in the visual centre of the occipital lobe. The ophthalmoscopical findings are attributed to a descending neuritis. The notes of two additional cases are appended in which the ocular symptoms were similar to the foregoing.

As a distinguishing point in the differential diagnosis of *congenital nystagmus* and that form observed in cases of disseminated sclerosis, Bard [211] points out that in the former class of cases the nystagmus diminishes upon fixation, whilst the ocular movements increase, especially when the extreme movements of the globes in any direction are attained.

Henschen, of Upsal, [173] has found, at the autopsy of individuals who presented the hemianopic pupillary inaction sign during life, that there are nearly always small hæmorrhages into the optic tracts, the geniculate bodies, or the chiasm.

Dunn, of Richmond, [347] reports a case of *exophoria* of four degrees at five metres occurring in a female 47 years old. Numerous reflex symptoms which had been supposed to have originated in some trouble in the lower spinal region—probably in the uterine plexus—were attributed to the ocular affection. According to

Gillespie, [430] in a case of asthenopia with retinal hyperæsthesia occurring in a woman, there is usually a decided spinal irritation in the lower cervical or upper dorsal region, Taylor, [2] of Norwich, has observed a case of probable *disease of the lenticular ganglion* in an hysterical married woman aged 49 years. The symptoms were manifested on the right side by proptosis, ocular pain, increased tension, and indistinct vision. When seen by the author, one month later, the symptoms had subsided. The left pupil was larger than its fellow, and the iris was immobile to light and convergence; but the pupil became larger under the effect of homatropine, cocaine, and faradization of the neck. The patient suffered from neuralgic pains in the eye and on the left side of the nose. There was a paralytic affection of the right arm which was probably due to peripheral neuritis. The history pointed to an orbital cellulitis in which the inflammation involved the lenticular ganglion.

Wolffberg, of Breslau, [353] has found that in *neurasthenia* there is greater tendency of the eye to roll up when the lids are closed than happens normally. This is probably a manifestation of muscular weakness, as certain dimensions of the orbital diameter and the prominence of the corneal summit render the act of closing the lids more difficult.

An interesting case of *optic neuritis*, occurring *in an anæmic girl* aged 13 years, has been seen by Nason. [32] For a period of five months there were recurrent attacks of vomiting, intense pain in the head and spine, tinnitus, numbness and paræsthesia of the finger-tips, and occasional momentary attacks of blindness. Under the use of iron the symptoms subsided. One year later, however, there was a return of all the phenomena, which again yielded to the same remedy.

Ayres, of Cincinnati, [347] reports five cases representing different phases of *hysterical amblyopia*. In the first instance there was concentric contraction of the visual field, and in the second a well-marked central scotoma. In two other cases there was a sudden disappearance of the amblyopia while the patient was undergoing a refraction-test. In the fifth case the disease took the form of photophobia, which was cured by mental effect. From the study of twenty-five cases of hysteria, J. K. Mitchell and de Schweinitz, of Philadelphia, [242] conclude as follows:—

"1. Achromatopsia, or loss of color-sense, as described in our previous paper, Nov., '89 is not present in the American cases (certainly not as it has been described by Galezowski and other French observers).

"2. Reversal in the normal sequence of the colors, so that red is the largest field, is usually present when there is anæsthesia; but that disturbance of the color-sense and anæsthesia do not necessarily belong to each other is proven by the fact that we have examined at least two cases of universal anæsthesia with no alteration of the visual fields, and a third case in which, although there was most marked contraction, reversal was not demonstrated.

"3. The green field is, relatively at least, more and more often contracted than the others.

"4. In the difficult distinction between certain types of neurasthenic and hysterical patients the presence of disturbance in the color-sense is of diagnostic import; it is less apt to be present in the former than in the latter, and yet its absence is of little meaning, as we have not found it in many typical cases of hysteria, and have found it in others which are properly classified in the neurasthenic category.

"5. It is possible that in the rare cases of hysterical one-sided or general hyperæsthesia it will be found that colors are more accurately appreciated than is normal and that the color-fields are correspondingly enlarged, although we can make this only as a suggestion, having received a hint of it in one case, but not having found it in others.

"6. The violence of the hysterical manifestations bears no relation to the disturbance of color-sense, the most marked change being found in patients the least affected nervously, and, practically, normal visual fields, where the general symptoms of hysteria, anæsthesia excepted, are of the highest grade.

"7. Some of the following changes, so far as the field of vision is concerned, are likely to be present in cases of hysteria: (*a*) Simple contraction of the color-fields, with unaffected form-fields. (*b*) Contraction of both form- and color- fields, the green field being relatively more contracted than the others. (*c*) Partial or complete reversal of the normal sequence in which the colors are appreciated, most commonly that variety in which the red field is greatest in extent. Under these circumstances the color-fields may be normal

in extent, sometimes even wider than is normal, or there may be an associated contraction of all the color-fields. (*d*) Unusual obscurations of portions of the visual field,—for example, in the form of an hemianopsia, or greater contraction of the fields on one side than on the other, the greater contraction usually being found on the same side with the anæsthesia."

To explain the *monolateral amblyopia* which at times occurs *in hysteria*, Knies, of Freiburg, [171] Jan.,'94 advances the following hypothesis: The suppression of the function of an entire hemisphere produces a crossed paralysis of the cephalic branches of the great sympathetic. Each centrifugal cerebral impulse is accompanied by a vasomotor impulse to the same organ. This suppression produces a vascular dilatation that may exercise a mechanical influence upon the nerves, especially where they pass through narrow foramina. Crossed amblyopia is caused by such a compression of the optic nerve in the optic foramen, whilst the associated paralysis of the spinal nerve is produced as they pass through the intervertebral foramina.

By studying the secondary degenerations in five cases of hemianopsia, Vialet, of Paris, [171] Mar.,'94 has made a valuable contribution in regard to the *position of the visual centres* and the course of the nerve-fibres carrying that class of impulses. The cuneus possesses fibres of projection, and these, being conductors of the visual impressions, unite the cortex of the bend of the pulvinar and the external geniculate bodies and ganglionic visual centres. Far from being isolated by the lamina fibrosa, the cuneus is joined to the lingual lobe by a powerful bundle of association fibres, and presents the histological characters of that lobe. In regard to the anatomical significance of the external layer of the sagittal substance of the occipital lobe, it is divided into two distinct layers,—one composed of sensory visual fibres, the other of association fibres. The first two cases observed by him were instances of pure cortical hemianopsia, the visual defect in one being on the left side. The autopsy revealed an old spot of softening which appeared to be limited to the anterior portion of the cuneus. The microscope, however, showed that the entire anterior two-thirds of that lobe was affected as well as the anterior half of the calcarine fissure, the bottom of the internal perpendicular fissure, and the foot of the cuneus, from which it extended as far as the foot of the hippo-

campus, this region corresponding to that supplied by the anterior branch of the occipital artery. The secondary degenerations had affected two large groups of fibres: (*a*) the fibres of projection or visual radiation, and (*b*) the association fibres running between the hemispheres. In the second case there was a right homonymous hemianopsia. The microscope showed that the area of softening had destroyed the cuneus with the exception of a small portion of cortex, had spread over both lips of the calcarine fissure, and had encroached upon the white substance of the lingual lobe. In conjunction with this lesion, there was degeneration of the visual radiations. The third case, one of right hemianopsia, was associated with a pure form of word-blindness. There was an old spot of softening at the base of the cuneus, which extended over the posterior part of the lingual and fusiform lobe as well as the inferior temporo-occipital sulcus of the left hemisphere. In this case also there was a secondary degeneration of the radiatory zone, limited in a quite remarkable manner to the region of Wernicke and all that part of the latter normally covering the posterior and external portions of the external geniculate bodies. In the remaining cases there was word-blindness with hemianopsia due to a lesion of the fibres of Gratiolet. The author concludes, with Seguin and Dejerine, that the hemianopsia which is associated with this form of ocular disturbance can only be produced by a destruction of the visual fibres in the interior of the brain, and that the most limited cortical lesions capable of producing these conditions are situated on the internal surface of the occipital lobe and spread into the territory of the calcarine fissure. The visual cortical centre occupies the entire extent of the internal surface of the occipital lobe, being bounded anteriorly by the internal perpendicular fissure, above by the superior edge of the hemisphere, below by the inferior edge of the third occipital, and behind by the occipital lobe. The fibres emanating from the cuneus follow two distinctive paths, those coming from the superior course passing above the forceps major by encompassing the superior wall of the occipital horn, and those which are given off from the inferior part and unite with the fibres of projection coming from the calcarine fissure and the lingual lobe.

The same author $_{\text{June, '94}}^{173}$ reports two new cases of cortical hemianopsia where autopsy revealed the lesion to be situated upon the

internal surface of the occipital lobe. Both instances occurred in old men, and there were no other symptoms denoting cranial disturbance. The hemianopsia followed an apoplectic attack in each. Comparing the findings of the autopsies with those of other cases reported by him, the author points out that, notwithstanding the different degrees in which the cortex is involved, the visual lesion always presents the same characteristics,—a proof that the cortical area in which the visual fibres terminate is not as limited as Henschen admits. It also confirms him in his opinion that the visual area comprises the entire internal surface of the occipital lobe,—*i.e.*, the three circumvolutions of the cuneus and the lingual and fusiform lobes.

At the autopsy of an old man who had suddenly become blind without visible alteration of the fundus, and with conservation of the pupillary action, Dejerine and Vialet [927 Dec. 9, '93] found a double area of *cortical softening* upon the internal surface of the occipital lobes, with secondary degeneration of part of the corpus callosum. In the right hemisphere the lesion occupied the cuneus and the lingual and fusiform lobes,—that is to say, the entire extent of the cortical visual centre. In the left hemisphere it was situated more especially upon the centre of the internal surface of the occipital lobe and attained its maximum degree of intensity at the level of the lingual lobule. Both sides of the calcarine fissure had undergone pathological change.

Pic, of Lyons, [78 Apr., '94] reports a case of *tumor of the occipital lobe*, with hemianopsia, occurring in a girl 13 years old. The symptoms appearing shortly after a traumatism, the diagnosis of neoplasm was rendered uncertain for a time. Nevertheless, it was thought there was a tumor either at the level of the fibre of Gratiolet or in the cortex itself in the right occipital lobe. This diagnosis was substantiated later on at the autopsy. The growth was found to be limited anteriorly by the internal perpendicular fissure, from whence it extended under the anterior part of the cuneus and the lingual lobe and re-appeared at the level of the fusiform lobe. Antero-posteriorly it spread from the median portion of the cuneus up to a line cutting the temporo-occipital convolution at a level of the posterior part of the optic layer. Histologically the neoplasm was of an embryonal nervous type, apparently originating in the calcarine fissure. The author con-

cludes his report of the case with the following summary: 1. Hemianopsia, without being frequent, is not exceptional in the course of cerebral tumors. It is cortical in origin or depends upon a lesion of the conducting apparatus. 2. When cortical it is produced by the development of a tumor upon the internal surface of the occipital lobe at a level or in the neighborhood of the calcarine fissure. In the case reported there were all the signs of ordinary cortical hemianopsia (homonymous bilateral hemianopsia of the opposite side without hemianopic pupillary inaction sign). This was, as is usual, accompanied with visible ophthalmoscopical lesions (choked disc). 3. The detection of an hemianopsia is of great importance in the topographical diagnosis of a cerebral growth, and for this purpose perimetric examination should be as precise as possible, the symptoms existing but several days in a typical condition during the evolution of a neoplasm.

Jocqs, of Paris, $^{173}_{\text{June,'94}}$ reports an instance of double hemianopsia, with conservation of central vision, in a 58-year-old woman who was free from neurasthenic symptoms. Two years after a right homonymous hemianopsia the patient had an apoplectic seizure which was followed by complete blindness. The central vision gradually improved until an acuity of $\frac{2}{3}$ was obtained. Peripherally the field remained abolished. From a study of this case, the author is inclined to think that there are two distinct cortical areas,—one presiding over the central and the other over peripheral vision. E. Koenig, of Paris, $^{173}_{\text{Mar.,'94}}$ has observed an instance of temporal hemianopsia in a woman 22 years old. The lines of demarkation of the visual fields were sharply cut and passed directly through the fixation-point. The patient was subject to epileptiform attacks. Anosmia was also an attendant symptom. Both optic-nerve heads were partially atrophic. The author thinks that the symptoms were caused by a tumor of the pituitary body pressing upon the chiasm.

Eales, of Birmingham, $^{32}_{\text{Aug.,'94}}$ gives the notes of a case of *binasal hemianopsia, with contraction of the remaining half fields*, in a man 74 years of age. There was partial optic atrophy, apparently post-neuritic in type. An instance of *tabes with homonymous hemianopsia* has been observed by Peterson, of New York, $^{1}_{\text{June 30,'94}}$ in a man, 50 years of age, who had contracted syphilis twenty-eight years previously. There was partial optic atrophy and the field

of vision in the right eye was limited to the upper temporal quadrant, while that of the left eye was confined to the upper nasal quadrant. The Argyll-Robertson pupil was present. Turner, of Essex, Eng., [47 Winter,'93] reports a case of persistent left homonymous hemianopsia associated with a small occipital lesion. Neither the cuneus nor the angular gyrus was involved. The patient was a demented female, 54 years of age, who had had an attack of apoplexy with resulting paralysis of the left arm and leg. The mental condition rendered it impossible to accurately define the limits of the field, but the blind area appeared to extend to fixation.

Friedenberg, of New York, [814 Feb.15,'94] relates a case of binasal hemianopsia with subnormal red and green color-perception, in a man 41 years of age. The discs were atrophic. The general condition of the patient was excellent, there being no cerebral symptoms. Bernstein, of Baltimore, [9 June 30,'94] records a case of *fleeting hemianopsia* in a man, 30 years of age, who had contracted syphilis two years previously. The visual defect, which extended from fifteen degrees above the horizontal meridian on the nasal side over the superior field to within fifteen degrees below the horizontal on the temporal side, always made its appearance after the eyes had been used at near work for a few hours. During this period the veins seemed more engorged in the temporal portion of the fundus than at other times.

In an article upon the relation of ophthalmoscopical findings to diseases of the *cerebral cortex*, as illustrated by a series of observations upon nearly two hundred cases of epilepsy and general paralysis of the insane, Oliver, of Philadelphia, [112 Mar.,'94] makes the following tentative observations:—

"1. The ophthalmoscopical findings of the living intra-ocular tissues, especially those of optic-nerve and retinal structure, in cases of epilepsy of sufficient moment and standing (as seen in the detained subjects of asylum life) to give numerous well-pronounced and uncontrollable seizures, are often of such a grade and of such a character as to constitute a type.

"2. The objective peculiarities of such living tissues, as seen in all grades under the magnifying power employed in the direct method of ophthalmoscopy, are characterized by a low and chronic form of retinitis and perivasculitis, associated with a dirty red-gray incipient degeneration of the optic nerve. These changes may be

summarized as follows: increase in thickness of the fibre-layer of the retina; enlargement, waviness, and tortuosity of the retinal vessels (especially the veins); opacity and thickening of the retinal lymph-channels; superficial overcapillarity with a decided grayness in the deeper layers of the optic disc; broadening and sharply-cut appearance of the scleral ring, especially to the temporal side of the disc; and a granular condition of the choroid in the macular region.

"3. The ophthalmoscopical findings of the living intra-ocular tissues—especially those of optic-nerve and retinal structure—in cases of so-called general paralysis of the insane are so certain and so persistent in characteristic appearance, and are so increased in amount and degree in proportion as the general disease assumes its latest phases of retrogradation of the subject, that they become eminently characteristic of the type of the affection, and assume a definite expression of the stage of the disorder.

"4. The principal retinal and optic-nerve changes, which are more pronounced in the third than in the second stage of the disorder, where they may be frequently recognized in their incipiency, are: fibre-layer of the retina, as a rule, diminished in thickness; retinal striation, very pronounced, in a few instances during the third stage of the disease rendering the disc-edges quite hazy; retinal arteries reduced in size, and at times slightly tortuous; retinal veins, as a rule, undersized, tapering in some instances as they enter the disc, and quite tortuous in a number of cases; retinal lymph-reflexes very few, being generally limited to the walls of the main vascular stems; fine pin-point opacities in the retina, between the disc and the macula, in a few cases; optic discs decidedly and unequally semiatrophic, especially in the latter stages of the disease, the degeneration being more pronounced in the deeper layers, and to the temporal side of the nerve-head; materially lessened capillarity of optic-nerve-head substance, the greatest amount of blood-supply being recognized in rather narrow crescentic areas to the nasal side of the disc; the latter, in a few cases seen in the third stage of the disease, being suffused and gelatinous in appearance, the disc-edges plainly visible, and the surrounding retina somewhat œdematous; scleral ring sharply cut, and, as a rule, broad, this being more noticeable to the temporal side of the optic-nerve head; broken crescents of absorbing pigment to the inner and outer edges

of the disc, these being broader and more crescentic to the temporal border of the nerve-head; and, in the majority of cases, granular and disturbed choroid.

"5. The microscopical findings in the cerebral cortex, in most cases of epilepsy in which there have been long-standing, frequent, and well-marked general seizures, consist principally in degeneration changes in the nerve-cells, especially of the second layer, and a secondary increase and tortuosity of the vessels themselves, with nuclear infiltration of their walls. Here the nerve-cells themselves become granular, diminished, and shrunken. The periganglionic spaces augment in size, and the perivascular lymph-spaces become dilated, while at times there is an irregular increase of the neurogliar tissue in certain places.

"6. The microscopical findings of the cerebral cortex in cases of so-called general paralysis of the insane consist of degenerative changes in the nerve-cells and increase of the vessels, with thickening and infiltration of the vessel-walls. Here, from the earliest stages, when the arterioles appear distended and their lymph-channels blocked with proliferated nuclear protoplasm, producing diapedesis of leucocytes and hæmatoidin-crystals and pressure paralyses of the smaller groupings; until the development and increase in size of the scavenger cells of Deiters, with a proliferation of their nuclei which feed upon the atrophying nerve-material, until the nerve-cells and nerve-fibres are replaced by granular and oily *débris*, which is absorbed and carried off through the larger blood-vessels and lymph-channels and spaces,—the morbid process is one of vascular infiltration and nerve-degeneration; and finally, when the neuroglia itself becomes converted into coarse fibrillæ and the nuclei of the cells are alone visible, the picture of cortex-disintegration is complete.

"7. A careful analysis of the above definitive ophthalmoscopical findings, with the known and recognized microscopical changes in the cerebral cortex in the two diseases, not only shows a correspondence in the types of the pathological conditions of the vascular and neural structure of the two membranes in question, but evidences an absolute relationship as to degree and amount of tissue change, though, of course, not as to kind, in the several stages of the two diseases.

"8. When it is remembered that the recent researches of

Hatschek conclusively show that the eye of the vertebrate springs directly from a portion of the cortex of the embryonic brain, and that the inner or retinal wall of the optic cup undergoes a series of ontogenetic changes similar to those experienced by the related cortex tissues; and when it is realized that there is an almost exact anatomical relationship in the various superimposing ganglionic and cellular layers between the structures of the post-natal cerebral cortex and the retina, it will be fairly presumable that a diseased condition of the former membrane, if extended over a long period of time, may produce in the latter pathological pictures the counterpart of those in the former.

"The conclusion, therefore, from these observations is naturally that the morbid process of cortex disease, as seen under the microscope after death, if long continued and if of any moment, can be recognized ophthalmoscopically before death in the optic-nerve head and retina by similar relative changes of diseased action in these latter tissues."

Ranney, of New York, $_{\text{May 12,'94}}^{59}$ reports a series of cases of *chorea*, all of which were cured or very much benefited by graduated tenotomies. In a case of *epileptiform* seizures in an unmarried girl of 18 years, with hypermetropia, Conners, of Oil City, $_{\text{Nov. 4,'93}}^{9}$ has effected an apparent cure by correcting the error of refraction. Taylor $_{\text{June 22,'94}}^{2}$ reports three groups of cases of *optic neuritis with brain-tumor*. In the first series of three cases the growths were removed. In the second, comprising three cases, symptoms of cerebral tumor were present, and in two the growth was detected by trephining, but was not removed; while in the third no tumor was visible at the time of operation, but was detected after death. In the third group there were two cases of removal of cerebral growths, and a third in which an intra-sarcomatous cyst was tapped and two years later part of the growth was removed. The author reports the cases in order to emphasize the fact that not only in instances where a tumor is removed from the brain does the optic neuritis subside and the discs assume a normal appearance, but that even in other cases of tumor in which the skull is opened, but the tumor not removed or interfered with further, a similar subsidence of the swelling of the disc takes place.

A case of *double optic neuritis* of moderate intensity, paralysis of the left external rectus, and paresis of the left facial nerve was

seen by Rogman, of Ghent, $^{171}_{\text{Sept.,'93}}$ in a woman 30 years old. The symptoms developed suddenly *during lactation*, and were accompanied by vomiting and a violent cephalalgia, which the author took to be indicative of cerebral involvement. It is of interest to note that the appearance of the ocular and the cerebral symptoms were simultaneous with the sudden cessation in the lacteal secretion.

Sealy, of Cheshire, $^{2}_{\text{Oct.14,'93}}$ has seen complete recovery in six days from *total blindness* resulting *from concussion of the brain.* The patient, a boy, had been rendered insensible by a blow on the head. Upon regaining consciousness visual acuity in the left eye was found to be diminished, and within one hour's time light-perception was abolished. Later, vision in the right eye became similarly affected.

Hansell, of Philadelphia, $^{9}_{\text{Oct.28,'93}}$ has seen two cases of *ocular sequelæ* resulting *from exposure to the sun.* The first case occurred in a boy 8 years old. Both optic nerves were pallid and the veins were dilated. Vision was greatly reduced. The right external rectus was paralyzed. In three months' time, under appropriate treatment, the ocular conditions returned to normal. In the second instance—a woman aged 30 years—there was enormous swelling of the discs, more pronounced in the lower quadrant. The field was contracted to within ten degrees of fixation. Vision in the left eye increased to $\frac{6}{6}$, but that of the right failed to improve materially. With the hope of separating any adhesion that might have formed between the sheath of the nerve and the walls of the canal, the optic nerves were stretched. Although no apparent change in the appearance of the disc followed the procedure, yet vision improved to $\frac{6}{60}$.

Of one hundred cases of *disseminated sclerosis*, Buzzard, of London, $^{2}_{\text{Oct.7,'93}}$ found pallor of the disc of varying degree in 43 per cent. While he has seen a condition of the disc which is describable as "somewhat resembling the tint of hyperæmic gray matter of the cerebrum," he has never seen what is usually called optic neuritis or papillitis. The author describes an "hysterical type" of the affection in which there may be unilateral transitory blindness, with a history of transient emotional periods, with loss of power or sensibility in a limb. The reflexes may be exaggerated. Many of the cases diagnosed as hysterical blindness are in reality this form of disseminated sclerosis, and later examination would

probably give unmistakable evidence of the disease, with a condition of partial atrophy of the nerves. An instance of associated optic atrophy and *locomotor ataxia* is recorded by Jones. [61 Sept.15,'94] There was rapid nystagmus, and the Argyll-Robertson pupil was present. The special feature of the case was the absence of the ataxic gait.

In regard to *congenital blindness*, Martin, of Bordeaux, [153 Dec.14,'93] concludes as follows: Congenital blindness may be of two kinds. The pathological variety is rare, the teratological more frequent. The cause of the blindness does not seem to have any appreciable effect upon the rest of the intellectual condition, moral and physical, unless in the limit of the suggestions which the absent function furnishes to the different cerebral acts. The hereditary acquisition and, later, the support furnished by the sensory apparatus are the sources of ideas. When one apparatus is in error, the ideas which are engendered by it may be transmitted to a greater or less degree by another sense. The relative inferiority of the congenitally blind demonstrates the leading rôle of sight in the genesis of intellectual manifestations. Thomson, of Spokane, [249 July,'94] gives the notes of a family in which the father, with blue eyes, and the mother, with black eyes, had blue-eyed children with normal sight, while those who were black-eyed became blind, probably as the result of optic atrophy. Nieden, of Bochum, [254 Dec.,'93] cites an instance of *erythromelalgia*, with pronounced eye-symptoms, in a man, 46 years old, who presented the characteristic vasomotor, trophic, and secretory disturbances of the skin of the distal ends of all four extremities, in addition to the general condition of irritability of the skin of those regions. The patient had suffered from several relapses of the same disease, and during the course of the last recurrence ophthalmoscopical examination revealed a one-sided optic neuritis. The patient was a miner, and suffered from nystagmus. The general condition was attributed to a paralysis of the muscular coats of the blood-vessels of central origin, the disease being apt to spread to organs in intimate association with the brain, such as the optic nerve.

From the results obtained in fifteen consecutive cases, Rockwell, of New York, [102 Nov.,'93] accords *electricity* the first place *in the treatment of exophthalmic goitre.*

Snell, of Sheffield, [2 Mar.3,'94] has made a careful study of the *ocular*

conditions in a series of cases of *dinitrobenzol toxæmia*. The characteristic symptoms were: failure of sight, often to a considerable degree, more or less equal on the two sides; concentric contraction of the visual field, with a central color-scotoma in many cases; enlargement of the retinal vessels, especially the veins; some blurring, never extensive, of the edges of the disc and a varying degree of pallor of its surface. These conditions of the retinal vessels were found in workers in the substance, independently of complaints of defective vision. Removal of the exciting cause leads to recovery.

While studying the *intra-ocular tension* by means of a new instrument, Nicati, of Marseilles, [14 Jan. 31, '94] came to the conclusion that *a sure sign of death* is found in the first diminution in pressure at the moment when the pulse stops, and in a definite diminution, demonstrable in a high degree, several hours afterward.

SECTION VI.

THERAPEUTICS AND INSTRUMENTS.

Believing that the *dangers of infection from collyria* are greater than their advantages, de Wecker, of Paris, [171 June, '94] pleads for their limitation in ocular therapeutics, especially in corneal ulcers, in which the following procedures are indicated: 1. Careful disinfection of the lids, particularly of the ciliary border. 2. Curetting of the ulcer, combined with irrigation, to cleanse the infected parts. 3. Injection of several drops of a 10-per-cent. solution of corrosive sublimate in the neighborhood of the infiltrated parts. 4. Rigorous application of an occlusive dressing without the employment of any collyria, care being taken to renew the dressing as seldom as possible. G. E. de Schweinitz, of Philadelphia, and E. A. de Schweinitz, of Washington, [2038 p. 110, '93] have examined the pipettes and collyria taken from a treatment-case used in ophthalmic practice, and found that the cultures yielded by the cocaine pipette and cocaine solution contained the micrococcus aquatilis, the bacillus liquefaciens, and the proteus vulgaris. The boric-acid solution was found to contain the same germs, with the exception of the bacillus of Vignal. The atropine lotion, which, when first examined, showed no growth, but afterward a fungus, contained,

two months after the first examination, the micrococcus prodigiosus and the bacillus liquefaciens. The homatropine lotion contained the bacillus liquefaciens and a fungus. At the first examination the eserine pipette produced a growth on three different culture-media, but the solution of the drug appeared to be sterile. Two months later the same solution, although tightly corked, showed a marked fungous growth (aspergillus glaucus). The bacillus liquefaciens and bacillus implexus were also present. Of these organisms the proteus vulgaris, the micrococcus prodigiosus, and the bacillus implexus, introduced into the anterior chamber of the iris, were determined to be capable of producing a purulent inflammation of the iris, cornea, and deeper coats of the eye. Exactly similar inoculations with the bacillus liquefaciens resulted in an hyperæmia of the iris, possibly a slight iritis, which disappeared in a week; with the micrococcus aquatilis the effect was negative. The growth of the fungus in these solutions appears to have little deleterious effect upon the eye, but, as noted, has the power, with eserine at least, of changing its chemical composition.

Rolland, of Toulouse, [173 June, '94] has employed *antipyonine* in a series of cases, and concludes that this drug, without compromising the integrity of the eye, prevents the development of elements which generate pus upon the surface or in the interior of the eye. In small doses it is efficient in cases of phlyctenular keratitis and similar affections of that membrane, while in stronger doses it is of service in the treatment of corneal ulcers, catarrhal conjunctivitis, etc. The strongest doses should only be used in purulent ophthalmia and panophthalmitis. In the treatment of *traumatisms* of the eye, Edwards, of Nashville, [86 Feb. 4, '94] applies the bichloride of ammonia to all cases, and, after cleansing, employs campho-phénique; especially if sutures have been used.

Braquehaye, of Paris, [274 May, '94] recommends *gelatin plates* in occlusive dressings of the eye and face. He makes use of the following formula: Oxide of zinc, 10 grammes (2½ drachms); gelatin, 35 grammes (9¼ drachms); glycerin, 20 grammes (5 fluidrachms); water, 35 grammes (9¼ fluidrachms). The following advantages are claimed for this method: 1. It never produces sufficient pressure to give cephalalgia, and is therefore especially applicable to cases in which there is ocular, frontal, or temporal pain. 2. Being applied solely to the eye, it does not interfere with the daily

toilet of the face and head. 3. The gelatin forms a perfectly-impermeable dressing, thus preventing infection when applied to healthy eyes. Its employment is only contra-indicated (*a*) when energetic pressure is desired to be exerted; (*b*) when there is much lachrymation; (*c*) in children who are difficult to dress.

Gepner, Jr., of Warsaw, $^{190}_{\text{June,'94}}$ has employed *formaldehyde* as a lotion, finding it excellent after enucleation, as it prevents any muco-purulent discharge. He also had good results in operations upon the lids. He uses it in the strength of from 1 to 2000, never stronger than 1 to 1000.

Macnaughton-Jones, of London, $^{6}_{\text{June 20,'94}}$ in an excellent article entitled "Rest, Physiological and Therapeutical, in the Treatment of Eye Diseases," discusses various methods by which this may be attained. In all inflammatory diseases of the eye the first principle of cure is the establishment of rest, secured by whatever means that may be, direct or indirect.

McGillivray, of Dundee, $^{2}_{\text{Sept.15,'94}}$ holds that the beneficial effect of *cold* does not cease with the early stage of inflammation, but that if it be applied continuously, in the form of iced compresses, the temperature of the injured part can be reduced to a degree at which the growth of the bacteria is retarded without injuring the tissue, and that it may thus be considered as an antiseptic.

In treating the ocular manifestations of syphilis, Parisotti, of Rome, $^{171}_{\text{Apr.,'94}}$ has employed subcutaneous injections of an oily solution of the *biniodide of mercury* in nine cases, and states that, when the danger is great and a rapid action is necessary, calomel is to be preferred; the biniodide, however, being better for the general run of cases. Braquehaye, of Paris, $^{274}_{\text{Nov.,'93}}$ has experimented with the oil of the biniodide as an antiseptic in certain ocular affections, and has concluded that in the strength of 1 to 1000 it is an excellent therapeutic agent for all the microbic inflammations of the ciliary border, provided its application is preceded by a vigorous curetting. It is to be recommended in neglected corneal ulcers consecutive to trauma, or in hypopyon. It should be rejected, however, when ulceration succeeds an inflammatory condition of the eye, as in phlyctenular conjunctivitis. It should be tried in granular cases.

Gepner, Jr., of Warsaw, $^{190}_{\text{Jan.,'94}}$ reports a series of cases in which he successfully employed *subconjunctival injections of corrosive sublimate*, a method recommended by him in all acute inflamma-

tions of the cornea and iris, especially where the use of mercury in any form is indicated. In twenty cases of myopia complicated by choroiditis, the treatment was attended with some improvement in all. The procedure is best suited to stubborn cases of iritis complicated by occlusion of the pupil and hypopyon. The author makes use of the same procedure as that employed by Darier. Alt, of St. Louis, [347 Feb., '94] has found that the subconjunctival injection of 2 minims (0.13 gramme) of a 1 to 1000 solution of corrosive sublimate is not only without danger, but is of great value in cases of inflammation of the uveal tract. Lagrange, of Bordeaux, [25 Dec., '93] reports a series of cases successfully treated by the same method, which was also used by Veasey, of Philadelphia. [80 Jan. 15, '94] In one case of scleritis the result was good, while in another it was negative after the first injection. In iritis and iridocyclitis the method gave prompt and effectual relief. Some cases of corneal affections were also benefited. Muttermilch, of New York, [171 Sept., '93] has found subconjunctival injections of corrosive sublimate to be inefficient as an antiseptic, although the drug thus used has valuable absorptive powers. In the hands of Briggs, of Sacramento, [61 Sept. 15, '94] the subconjunctival injections proved of most value in the treatment of spyhilitic diseases of the choroid and of septic ulcers of the cornea. Zossenheim, of Hamburg, [254 Sept.] made use of them in a series of diverse cases, with varying degrees of success according to the disease in which it was employed.

De Wecker, of Paris, [171 Nov., '94] has employed *injections of Brown-Séquard's fluid* in many cases of eye disease, and never has had a bad symptom follow its use. Although the injections strengthen the general condition of the patient, he never relies solely upon the remedy. Bourgeon, of Paris, [171 Nov., '93] gives the notes of four cases of atrophy of the optic nerve that were treated by the same agent, and states that he has never seen a particle of benefit follow its employment in this class of cases, even when the disease was associated with ataxia.

In the treatment of carcinoma of the face, Darier, of Paris, [173 June, '94] has had excellent results to follow the application of *methyl-blue* in the strength of 1 to 20. Where the tumors are deeply imbedded, hypodermatic injections should be made into the growth; but when they are superficial an application to the surface, conjoined with the employment of grafts of epidermis, suffices. Fuma-

galti, of Pisa, [173 Aug.,'94] has employed *chlorate of potassium* in the treatment of epithelioma, believing that this drug favors cicatrization of the ulcerations. If it do not suffice for a cure, an operation is indicated. J. Hutchinson, of London, [306 Apr.,'94] has found a combination of *belladonna*, *cinchona*, and *opium* very efficacious in cases of intolerance of light in children. In combating amaurosis due to quinine, Gouvea, of Rio Janeiro, [173 June,'94] has had the best results from the administration of *diffusible excitants* and *amyl-nitrite*, combined with a change of altitude.

After careful experiments with artificially-inoculated rabbits' eyes, Baas, of Freiburg, [204 B.39,H.4] concludes that *tuberculocidin* and *tuberculin* are equally inefficient to arrest or in any way affect the resulting tubercular process, and that they have no power to kill the tubercle bacilli, but apparently the effect of increasing their number. In several rabbits the tubercular process appeared in the other eye two months after enucleation of the inoculated one.

In the treatment of tobacco-amblyopia, Hope, of Dallas, Texas, [2013 May 2,'94] has had good results follow the administration of *cocaine*. Hilbert, of Sensburg, [254 June,'94] has observed yellow vision, lasting for two hours, follow the administration of 0.3 gramme (4½ grains) of *picric acid*. He also reports two instances of chromatopsia following the injection of intoxicating substances. In the first instance red vision was caused by the instillation of 5 or 6 drops of a solution of *duboisine* (0.05 to 10.0). The patient, who was anæmic and neurasthenic, became much excited. In the second case the injection of *santonin* caused all objects to appear grass-green. The general system was not in the least disturbed.

Rommel, of Neuzelle, [204 B.39,H.3] has experimented with a number of organic cardiac poisons in order to ascertain their anæsthetic effect upon the eye: Helleborein primarily affected the conjunctiva and the sclera, and secondarily the cornea. Convallamarin had a lasting anæsthetic effect upon rabbits, and probably a quicker action upon the human cornea. Strophanthine in $2\frac{5}{10}$-per-cent. solution was used with the best results in the removal of foreign bodies from the cornea, the slight conjunctival and subconjunctival injections caused by the drug disappearing on the following day. Adonidin possessed the advantages of not dilating the pupil and of not causing irritation. Carpainum hydrochloricum and muawinum hydrobromicum exerted a strong anæsthetic action

upon the cornea, lasting but half an hour. Caffeine, digitaline, scillipikrin, sparteine, muscarine, apocynin, and neurine gave negative results.

Ciserani, of Milan, [171] employs subcutaneous injections of *cocaine* in all operations upon the lids. He does not find it necessary in the extraction of cataract or in the performance of iridectomy, but has had satisfactory results from its use in strabotomy and enucleation. Vignes, of Paris, [178] substitutes the *phenate of cocaine* in the strength of 1 to 100, claiming that toxic effects are much less frequent than when the hydrochlorate is used. The phenate is more analgesic, is antiseptic, and remains longer unaltered.

Swann [6] claims that cocaine is more than a mere temporary local anæsthetic; that it is truly antiphlogistic, acting through the sympathetic and causing constriction of the blood-vessels; that it gives relief in a certain class of cases which are aggravated by atropine; that it forms a very useful adjunct to atropine and prevents the pain which, with atropine alone, would be inevitable; that it produces diminished tension and may with advantage be used with a small quantity of eserine; and that it is of great assistance in preventing iriditic adhesions and breaking them down when formed.

Raehlmann, of Dorpat, [171] has found that a solution of *scopolamine* in 10 to 100 strength has a more energetic, prompt, and sedative action upon diseases of the anterior segment of the eye than atropia in 1-per-cent. solution, not only breaking down synechiæ, but also shortening the duration of inflammation. He has never seen any severe general symptoms follow, even after the prolonged use of the drug, the worst effects being giddiness, fatigue, and sleepiness.

Bokenham [2] has made a study of the *action of scopolamine, tropacocaine, and hyoscine hydrobromate.* The first drug was employed in solutions of the strength of 1 to 250, and instilled three times at hour intervals, being found an efficient and safe mydriatic. Tropacocaine proved to be a satisfactory anæsthetic and free from mydriatic properties. The author does not consider hyoscine superior to homatropine, but believes that it is of value when atropine is undesirable. From a series of experiments performed upon men and animals, Vierling, of Giessen, [217] found that

scopolamine produces complete mydriasis in rabbits five minutes after the instillation of 1 drop of a 0.002 to 5.0 solution, which lasts for fifteen minutes without abating in intensity, whilst reaction to light is not re-established until fifteen or sixteen hours afterward. When 1 drop of a 0.005 to 5.0 solution is dropped into the human eye the first effect is noticed, on an average, in twelve and one-half minutes, whilst dilatation *ad maximum* is not attained until after thirty-one minutes. The maximum dilatation lasts about twenty-four hours, and the pupils do not react to light-stimulus until seventy-four hours after the instillation. No appreciable difference upon the action of the sphincter of the pupil is noticed by the employment of a stronger or a weaker solution of the drug. The first effect upon the accommodation is noticed eleven minutes after the instillation. Total paralysis appears at the end of forty-five minutes, and lasts twenty-five and one-half hours, while the effects of the drug do not pass away entirely for seventy-four hours. The author believes the use of the drug to be indicated where rapid and continuous dilatation of the pupil is required, and he has never seen any irritation follow its employment. From a series of experiments conducted with the same drug in a 0.05-per-cent. solution, Ritchie $^{776}_{\text{July,'94}}$ concludes that it apparently first affects the iris, the dilatation commencing in from ten to twelve minutes and ceasing in a minimum period of three days and a maximum period of six days; that accommodation is affected a minute or two later than the iris, the effect persisting from forty-eight to seventy-two hours. Derby, $^{99}_{\text{Dec.28,'93}}$ of Boston, has experimented with a 1- to 5-per-cent. solution of the drug in a series of seven cases, finding that the maximum dilatation occurred at a period ranging from twenty to forty minutes after instillation.

As the result of a comparative study of the *effects of atropine, hyoscine, and discs of homatropine and cocaine*, Wood, of Chicago, $^{1007}_{\text{Mar.,'94}}$ concludes that, if two gelatin discs containing $\frac{1}{50}$ grain (0.0013 gramme) each of homatropine and cocaine be placed in the conjunctival sac at an interval of twenty minutes, the eye being all the while kept closed, the muscle will in most instances be found to be fully paralyzed in from seventy to one hundred minutes after the introduction of the first disc. In persons under 25 years of age, or whenever ciliary spasm is suspected, the best results are

obtained by the use, in another twenty minutes, of a third disc, or one containing $\frac{1}{25}$ grain (0.0026 gramme) of homatropine alone, the examination in that case being best made between ninety and one hundred and twenty minutes after using the disc. The first two discs containing cocaine are sufficient to furnish the chief advantage of the alkaloid,—viz., of increasing the absorbing powers of the cornea for agents combined with it, while the increased dose of homatropine produces a more thorough relaxation of the ciliary muscles. An eserine disc $\frac{1}{1000}$ grain (0.000065 gramme) inserted the following morning will enable the patient to do near work within an hour or two. The discs should be inserted on the tip of a damp camel's hair brush, and should always be applied to the ocular conjunctiva at its inferior and outer surface, the patient looking up and in, while the lower lid is drawn down. Any adherent or sticky gelatin may be easily wiped off the palpebral edges with a damp cloth or a piece of wet absorbent cotton.

Hehir, of India, $^{289}_{\text{July 16,'94}}$ has observed constitutional disturbance with paralyses of accommodation, lasting three and one-half days, follow the accidental introduction with the finger of a small quantity of homatropine solution (2 grains to 1 ounce—0.13 gramme to 31 grammes) into the eye. His experience has been that the effects of this drug upon accommodation usually last for "several days." Taylor, of Wilkesbarre, $^{1018}_{\text{July,'94}}$ has seen *melancholia* develop in a patient who was being refracted under mydriasis *obtained by* the instillation of a few drops of a solution of *atropia*, 4 grains to the ounce (0.26 gramme to 31 grammes). He regards the appearance of the insanity as a coincidence, as the patient was predisposed to the disease by heredity, and had just experienced a profound physical and mental strain. Baker, of Cleveland, $^{347}_{\text{Nov.,'93}}$ reports a case of *poisoning by cocaine* following the hypodermatic injection of about ½ drachm (2 grammes) of a 6-per-cent. solution into the region of the lachrymal sac. From the study of the literature of cocaine poisoning, he is led to conclude that probably not more than 1 grain (0.065 gramme) should be employed until, by repeated trials, the tolerance of the patient to large doses can be assured. Patients who have exhibited the slightest symptoms of poisoning should be carefully watched, and the drug used with great caution. Morton, of Minneapolis, $^{1018}_{\text{July,'94}}$ has seen two cases of homatropine idiosyncrasy following the instillation of a few drops

of a 4-grain to 1-ounce (0.26 gramme to 31 grammes) solution of the drug. In the first case there was staggering gait, partial collapse, and hallucinations, whilst in the second the mydriasis persisted for three weeks after the last instillation.

Birnbacher, of Gratz, $^{190}_{\text{Aug.}}$ has devised an *apparatus for the illumination of the eye.* A small electric light, situated at an angle of thirty-five degrees, is guarded by a glass covering eight millimetres in diameter and seventy millimetres in length; the greater part of the light is thus made to leave the glass tube at its sharpened end as the result of total refraction. Heckel, of Pittsburgh, $^{59}_{\text{Mar.10,'94}}$ has devised an apparatus for the display of *test-cards,*



CONTRIVANCE FOR VISUAL AND COLOR PERCEPTION. (WARD-COUSINS.)
British Medical Journal.

which consists of a triangular box capable of being revolved, provided with grooves for the reception of strips of cards bearing test-objects. The accompanying sketch represents the appearance of a contrivance for visual and color perception designed by Ward-Cousins, of Southsea, England. $^{2}_{\text{June,'94}}$ A test-chart, the five lower lines of which are capable of being changed, has been presented by Helfrich, of New York. $^{776}_{\text{Oct.,'93}}$ The apparatus is set in motion by means of a pneumatic arrangement, combined with a series of weights, and is operated from the side of the patient by squeezing a bulb connected with a motor by rubber tubing.

A portable *perimeter*, constructed by Charles L. Dana, of New York, $^{1}_{\text{Apr.21,'94}}$ consists of a slightly-curved handle to the end of

which is attached at right angles a graduated semicircular disc; to the centre of the disc there is a movable rod for carrying the test-object. A new *ophthalmoscope* has been devised by Skeel, of New York,[2035 p. 22, '94] which possesses the advantage that the entire range of lenses in the primary disc can be brought before the operator by an uninterrupted motion. This is accomplished by rotating the lenses by means of a sliding piece attached to an endless chain which extends through a slot in the handle of the testing instrument. This piece has a range of movement of two inches and is controlled by a thumb-piece.

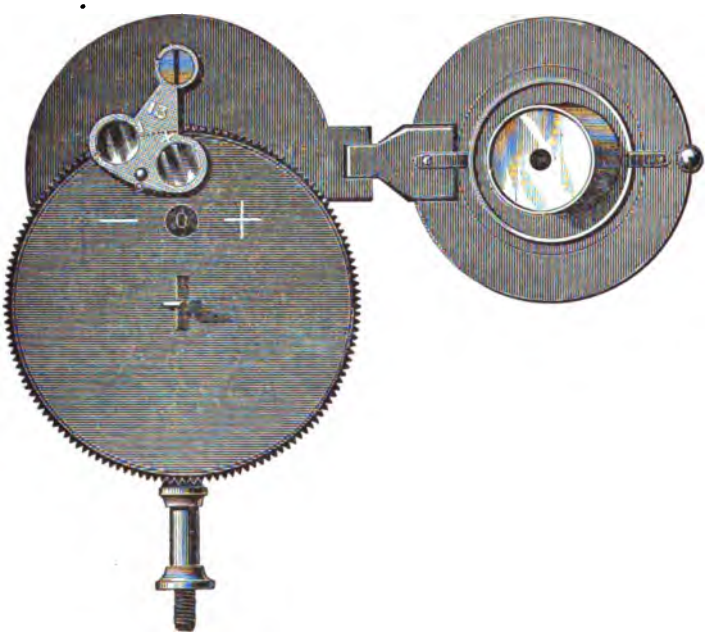

OPHTHALMOSCOPE. (FAGE.)
La Normandie Médicale.

The accompanying illustration represents an ophthalmoscope contrived by Fage, of Amiens.[203 Dec., '93] It consists of three mirrors capable of rapid adjustment, and a series of convex and concave spherical lenses running from 1 to 6 dioptres, mounted in a single disc. In order to obtain lenses of higher spherical powers a convex and a concave lens of 13 dioptres are appended on a separate disc.

Dennett, of New York,[2035 '94] has obtained satisfactory illumination of Javal's ophthalmoscope by two 16-candle Edison lamps, so arranged that when the arc is horizontal one is above and the

other is below the tube which shades the field-lens. They are made to turn with the instrument. By means of a small concave mirror so placed that an image of the carbon filaments is thrown on the face, the author claims to be able to tell at a glance when the instrument is in proper position.



REFRACTOMETER. (LAMBERT.)
New York Eye and Ear Infirmary Reports.

In order to facilitate the performance of retinoscopy by the rapid change of lenses before the eye, Lambert, of New York,[2035 '94] has devised a *refractometer*, consisting of a disc containing an aperture before which convex vertical lenses ranging from 1 to 10 dioptres and concave ones from 1 to 10 dioptres can be moved.

In front of this disc a double quadrant, holding convex and concave spherical glasses of ¼ and ½ dioptre, in addition to a + 1 D. and a — 10 D. spherical lens, is placed. The cylinders are fixed in slides. The disc is rotated by means of an L-shaped arm, and can be operated by the patient. The latest form is so arranged that it can be placed in front of the patient. The illustration on preceding page shows this modification.

MODIFIED SKIASCOPE. (THORINGTON.)
Philadelphia Polyclinic.

It being at times desirable in retinoscopy to have a large mirror, particularly in cases of high astigmatism, where, as the examiner approaches the point of reversal of one meridian he departs considerably from the point of reversal of the other, Jackson, of Philadelphia, 119 Mar. 24, '94 employs a full-sized mirror of thirty-eight millimetres, over which may be fitted a cap reducing it to ten millimetres.

Thorington, 119 Nov., '93 of Philadelphia has modified the *skiascope* by reducing the diameter of the mirror to two centimetres and that of the sight-hole to three millimetres. The mirror is not perforated and is mounted upon a black disc four centimetres in diameter, as shown in the sketch.

In order to avoid the inconvenience of removing the trial-frame from the face and applying it over a diagram before the axis of a cylinder can be obtained in cases where the revolving cell has been done away with, Prince, of Springfield, 1018 Jan., '94 has devised an *astig-goniometer*, which is illustrated on next page. It consists of a protractor suspended from a pivot so arranged

that the inclination of the rod is indicated by the corresponding division on the protractor.

Thorington, of Philadelphia, $\frac{9}{\text{Mar.3,'94}}$ has designed a device to aid in determining the principal meridians of the corneal curvature in practicing skiascopy. It consists of a disc of gutta-percha with a central opening twelve millimetres in diameter. Upon its face are

ASTIG-GONIOMETER. (PRINCE.)
Annals of Ophthalmology and Otology.

ASTIG-GONIOMETER. (PRINCE.)
Annals of Ophthalmology and Otology.

MERIDIAN INDICATOR. (THORINGTON.)
Medical News.

two heavy white lines which bisect the disc. The instrument is placed in the trial-frame and, after correcting the meridian of lowest refraction, is revolved until the band of light and the lines are continuous. The degree marked on the trial-frame to which the line points indicates the axis for the cylinder.

Dimmer, of Vienna, $\frac{353}{\text{May,'94}}$ describes a *new trial-frame.* The

chief merit of the contrivance is that the cylinder can be placed either anterior or posterior to the spherical lenses, the latter being rotated by a screw that may be operated by the patient.

The accompanying cut represents a trial-frame devised by Oliver, of Philadelphia. [1018 Jan.,'94] By removing all useless and ornamental material from the contrivance, by making all those parts upon which there is no bearing and no strain of aluminium, and by constructing all the movable and adjustable portions of the mechanism of light and movable portions of brass and steel, the instrument has been rendered lighter in weight, simpler in mechanism, and stronger in construction, while greater scope has been given to its action. The most important addition to the frame is

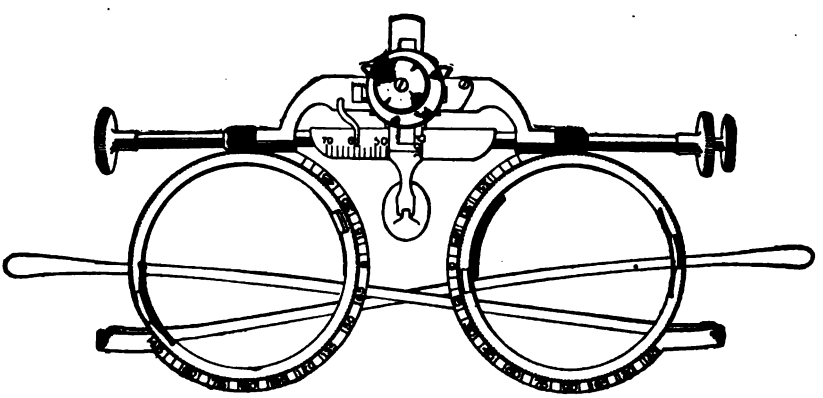

REVOLVING TRIAL-FRAME. (OLIVER.)
Annals of Ophthalmology and Otology.

an arrangement by which prisms and cylinders can be revolved separately or combinedly in any direction, from either the right- or the left- hand upper extremities of the contrivance.

Herbert, of Philadelphia, [1007 Mar.,'94] has introduced an *adjustable bracket*, with test-lens holder, for testing anomalies of refraction in the various forms of heterophoria.

Weiland, of Philadelphia, [1018 Jan.,'94] has devised an *optometer* adapted for distant test-objects as they are now used at twenty or more feet, and in which the spheres and cylinders are not inclosed in a tube. As shown in the figure, the instrument consists of a firm stand capable of vertical movement at *A* and of horizontal rotation at *B*. It is provided with a + S. 10 D. and a — S. 10 D. There are two minus cylinders of 3 dioptres. By means of

an adjustable plate the cornea is made to lie about fifteen millimetres from the imaginary plane between the two cylinders. The advantages claimed are: 1. The instrument is used for distant objects, thus avoiding the tendency to accommodation so often excited by an artificial punctum remotum. 2. The objects appear of the same size as the test-lenses from the trial-case in the usual position make them appear. 3. No tube is used that may embarrass the patient and excite the ciliary muscle. 4. It allows of correcting astigmatism by the direct use of cylindrical glasses, and may also be used as an improved Stokes lens. 5. By using,

OPTOMETER. (WEILAND.)
Annals of Ophthalmology and Otology.

in connection with the highest plus and the lowest minus spheres, only negative cylinders (also the practice of Javal), one is more likely to get the fullest correction for hypermetropia and to avoid an overcorrection in myopia in cases where a mydriatic cannot be employed.

Hotz, of Chicago, [1018 Jan.,'94] has modified his *astigmometer* by giving the rotary disc a radius of three and one-half centimetres and the holes a diameter of four millimetres, whilst they are placed one centimetre apart, the outer one being one centimetre from the end of the disc. The central aperture is done away with. This modification simplifies the construction of the instrument, as it does

away with the complicated mechanism necessary for revolving a disc on a central aperture. The edges of the excentric holes can be made very thin and sharp by beveling the metal on the posterior surface, while the front of the disc is left perfectly even and smooth. The two test-holes can be placed so much nearer to each other that it becomes much easier for the patient to tell when their long axes are in line.

Believing that many cases of supposed amblyopia are due to optical causes, Tscherning, 274 Oct.,'93 has devised an instrument to which he has given the name of *aberroscope*, and which consists of a plano-convex lens of 4 dioptres, provided with a micrometer upon its plane surface. By means of this instrument the author has made a series of observations upon his own eyes, and has arrived at the conclusion that a certain amount of amblyopia which he possesses is due to an irregularity in the pupillary area of his cornea, and not to any retinal anomaly.



TRIPLE TRIAL-CYLINDER. (PRINCE.)

Annals of Ophthalmology and Otology.

The accompanying illustration represents a triple trial-cylinder devised by Prince, of Springfield. 1018 Jan.,'94 The axes of the simple cylinder are so mounted that either, by the rotation of the handle, they may be alternately presented before each principal meridian or before the axis of the cylinder that may be in the trial-frame. The junction angle corresponds with the axis of each cylinder in the combination, and the strength is indicated on the handle.

A scale for the speedy and accurate determination of the anomalies of ocular muscles has been devised by Herbert, of Philadelphia. 1007 Feb.,'94 It consists of a black background with ten white squares each to the right, left, up, and down from a central square, thus forming a cross, each block being one centimetre square, and so arranged that the separation of each square is equivalent to a deflection of a prism-dioptre at one metre. The size of the squares can be made in proportion to the distance used. Smith, of Chicago, 451 Sept.,'94 has invented an instrument termed an *optomyometer*,

designed (1) to measure the orbital muscles of the eye without exciting the accommodation and the consequent convergence incident thereto; (2) to determine the strength of any particular muscle or set of muscles, and to ascertain the degree of prism necessary to relieve the weakness of the same; (3) to measure the zone in which the eye is moved by the orbital muscles; (4) to diagnose the field of torsion; (5) to exercise any particular muscle with a view of strengthening the same. The accompanying illus-

OPTOMYOMETER. (SMITH.)
International Medical Magazine.

tration shows the form of the apparatus. An instrument for the complete examination of the ocular muscles has been devised by Wilson, of Detroit. 776 Apr., '94 To this he has given the name of *ophthalmomyometer*. It consists of an upright stand, to which a bracket containing a rotating prism before the left eye is attached. In the right side there is a wheel carrying a double prism of 6 degrees, a convex cylinder of 8 dioptres, a prism of 10 degrees, one of 15 degrees, and an open space. The author claims that with it the equilibrium of the eyes with respect to the horizontal and

vertical planes may be measured in any or all of three ways: (*a*) by means of two images, one fixed and the other movable (as in the phorometer of Stevens); (*b*) by means of three images, the two outer ones fixed, the middle one movable; (*c*) by means of the line of light, as in using the Maddox rod. The equilibrium of the eyes with respect to the oblique planes—*i.e.*, with respect to rotary motions of the eyes—may be measured by the method of Savage. The power of adduction, abduction, and right or left sursumduction may be estimated. If a resultant prism is to be used to correct a given degree of compound heterophoria, this phorometer will give at once its exact strength and axis.

Risley, of Philadelphia, $^{119}_{\text{Apr.14,'94}}$ has had constructed a *frame for carrying prisms.* It is made of light, nickle-plated wire. It is designed to rest upon the nose in front of the correcting glasses. Brown, of Minneapolis, $^{61}_{\text{Sept.15,'94}}$ has devised a convenient arrangement of rotary prisms for muscle exercise, consisting of two 30-degree prisms capable of being rotated separately in opposite directions. Barnes, of New York, $^{59}_{\text{May 26,'94}}$ has had constructed a device adapting the Maddox cylinder to the phorometer. The instrument consists of a carrier with a mechanism by which the rod may be rotated into exact vertical or horizontal positions, these positions being accurately secured by means of a pin and stop.

Parinaud, of Paris, $^{171}_{\text{June,'94}}$ has devised a *stereoscope* for clinical purposes, consisting of two convex lenses of 4 dioptres' strength and of two 10-degree prisms, so mounted that they are capable of being adjusted at different positions. Binocular vision is elected by the application of one or two prisms with their bases in either an external or internal position, as the case may be.

Andrews, of New York, $^{1}_{\text{Nov.11,'93}}$ has had constructed a portable apparatus for sterilizing eye-instruments by boiling in water, and an aluminium shield for protection of the eye against injury after operations. Ostwalt, of Paris, $^{78}_{\text{Jan.,'94}}$ describes a new and suitable oven for disinfection and culture purposes.

An instrument for introducing tabloids into the conjunctival sac has been devised by Cousins. $^{22}_{\text{Nov.15,'93}}$ It consists of a small elastic ball with a celluloid tube terminating in a little cup which will exactly receive the tablet. The tabloid is drawn up into the cup and gently deposited into the *cul-de-sac* by pressure and relaxation of the ball.

Vass [2 July 15,'94] presents a simple instrument for raising the upper lid. It consists of a thin, cylindrical rod having longitudinal corrugations. The terminal half-inch is applied to the skin of the lid parallel to and a short distance from the ciliary border. It is rotated whilst being thrust under the margin of the orbit, thus carrying the eyelid with it. La Grange, of Bordeaux, [780 Nov.,'93] has reconstructed an old form of perforated *lid-elevator* for disinfection

LID-ELEVATOR AND EYE-DOUCHE. (OATMAN.)
New York Medical Record.

of the conjunctival sac before operation in purulent ophthalmia, and especially after operation for the cure of the granular form.

The above sketch represents a lid-elevator and eye-douche devised by Oatman, of Nyack, N. Y. [59 Jan.6,'94]

An adjustable lid-elevator for cataract operations has been introduced by Swasey, of Worcester. [59 Sept.1,'94] The lid-hook is attached to a flat-link chain, which is secured to a head-band by means of a shallow, blunt hook. Dunn, of Richmond, [59 Nov.25,'93] presents a double hook for pulling the eyeball forward while the optic nerve is being severed in enucleation. The same author has modified

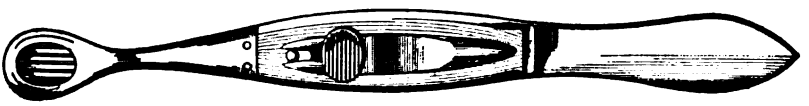

MASSAGE FORCEPS FOR TRACHOMA. (FALTA.)
Cent. f. prakt. Augenheilkunde.

the Stevens hook for the extraction of dislocated lenses by adding a second prong.

To aid in the removal of metallic foreign bodies from the cornea, Henry, of Birmingham, [6 June 23,'94] has had constructed a steel spud magnetized to saturation and shaped so as to bring the pole as near as possible to the extremity of the instrument.

Welchli, of Buenos Ayres, [274 Jan.] has constructed a *forceps* with a so-called "antiseptic articulation." The above sketch represents a forceps invented by Falta, of Szegdin, [190 Oct.,'93] to be used in the

massage treatment of trachoma. The author claims that the instrument is so made that, after it is armed with a tampon of cotton, it is well calculated to bring the bichloride solution in contact with a diseased conjunctiva.

Weymann, of St. Joseph, $^{814}_{\text{Mar.1,'94}}$ has devised a *hook-knife tenotome* for operating in strabismus, consisting of a small hook having a club-shaped extremity, the concavity of the hook containing a sharp cutting-edge for the division of the tendon. Stafford, of New York, $^{645}_{\text{Feb.,'94}}$ presents a combined strabismus-hook and cutting instrument, to which he has given the name of *ophthalmo-myotome.*

A combined *lachrymal gouge* for the removal of exostoses and necrosed bone from the walls of the nasal duct has been constructed by Schwarzschild, of New York. $^{59}_{\text{Nov.25,'93}}$ The apparatus consists of four parts,—cannula, director, gouge, and porte-caustique. The cannula is made of German silver, and with the director inserted corresponds to a Bowman sound No. 10. The gouge is constructed



FORCEPS FOR USE IN ANTERIOR CHAMBER. (SWASEY.)
New York Medical Journal.

of steel, the shank being strong and flexible. The cutting-edge of the instrument is highly tempered; the grooved portion, when fully inserted, extends seven millimetres below the end of the cannula, permitting chiseling to be performed. Todd, of Minneapolis, $^{1}_{\text{May 5,'94}}$ has had a lachrymal *syringe* constructed, consisting of a rubber bulb to which cannulæ of various sizes may be attached.

Boyle, of New York, $^{776}_{\text{Jan.,'94}}$ has devised an instrument to which he has given the name of *canaliculatome.* It consists of a sheathed knife, which is made to act as an ordinary lachrymal probe until the stricture in the canal is passed, when the knife is unsheathed by sliding a button in the handle of the knife, and the stricture incised. By means of this device the author claims to be able to cure stricture of the duct without slitting the canaliculus.

Swasey, of Worcester, $^{1}_{\text{Sept.,'94}}$ has made the above ingenious forceps for the removal of foreign bodies situated in the anterior chamber.

Bourgeois, of Reims, [173 May,'94] has slightly modified Tyrrell's hook in such a way as to make it an excellent instrument for the removal of such objects as cilia or pus from the anterior chamber.

Ferguson, of New Zealand, [76 Feb.,'94] has devised a new form of *capsule scissors* for incising a toughened capsule, differing from those of de Wecker in having its blades turned in the opposite direction, being sharp on the outer as well as the inner edges. Briggs, of Sacramento, [61 Sept.15,'94] has modified his *ablation scissors* for use in opticociliary neurotomy by the addition of a pair of claws, so as to assure the removal of the cut section of the nerve. A new form of *enucleation scissors*, devised by Ritchie, of New York, [776 Apr.,'94] is shown in the following sketch. The concavity in the blades is made with the object of forcing the optic nerve back whilst it is being divided.

Asmus, of Breslau, [204 B.40,H.1] has modified Lamont's magnetoscope

ENUCLEATION SCISSORS. (RITCHIE.)
Journal of Ophthalmology.

for ophthalmic purposes, and has given to it the name of *sideroscope.* By its use the presence of iron and steel chippings in the eye may be ascertained, either with a simple magnet needle or with the astatic needle. The location of these chippings is possible by an examination of all the meridians and by a comparison of the different indices of the scales.

Macnaughton-Jones, of London, [6 June 30,'94] has devised an *ophthalmic ice-bag* which is readily detached from a head-band by means of a single clamp.

In order to avoid the necessity of using two pairs of glasses after an operation for cataract, Bourgeois, of Reims, [173 July,'94] has constructed spectacles so arranged that the high convex lens used for reading is neutralized, when distant vision is required, by a concave glass of 4 or 5 dioptres superimposed upon the former by means of a hinge. For the purpose of applying direct massage in the treatment of corneal opacities, Morton, of Minneapolis, [9 Sept.,'94

employs a fenestrated spoon. He emphasizes the importance of applying massage not only over the entire cornea, but upon the sclera in the ciliary zone.

The accompanying cuts give the appearance of an improved cell of glass and celluloid, for the preservation and exhibition of macroscopical eye-specimens, invented by Oliver, of Philadelphia. 451 Feb.,'94 The present form has, for the following reasons, been considered the best that could be adopted for the purpose: 1. The containing power of the cell is quite great, thus allowing large

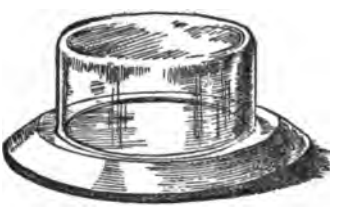

FIG. 1.

FIG. 2.

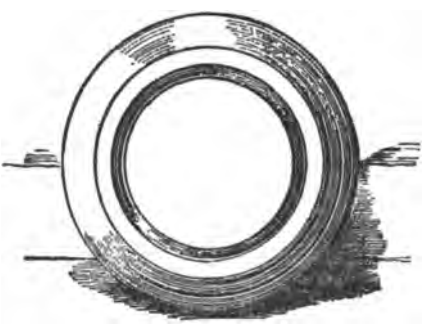

FIG. 3.

CELL FOR MACROSCOPICAL EYE-SPECIMENS. (OLIVER.)

Fig. 1. Appearance of the cell. Fig. 2. Top of the cell. Fig. 3. Bottom of the cell.

International Medical Magazine.

specimens—as, for instance, pathologically-distended globes and eyeballs with adherent extra-ocular tissue—to be placed in the best position for proper macroscopical study. (Fig. 1.) 2. The top of the cell is made of a carefully-ground cylinder of clear, transparent glass that is perfectly free from blemish. (Fig. 2.) 3. The base, which is composed of a strong, durable piece of unpolished celluloid, has been made circular. A broad-beveled edge has been given to it so as to permit of marking the nature and character of the specimen by lead-pencil, ink, or wax-pencil. (Fig. 3.) 4. The

external surface of the top of the cell has been made absolutely flat, thus avoiding any distortion of the contained specimen by lenticular aberration. 5. The parallel surfaces of the parts of the cell through which the most important portions of the contained specimen are to be studied are so arranged as to allow any exposed part of the specimen desired to be more carefully studied to be placed under any series of magnifying powers not too strong to necessitate a closer encroachment of the lenses than is obtainable with the ordinary dissecting microscope. This plan of a single movable lens for any and all of the specimens at command is much cheaper, more convenient of manipulation during study, and avoids any lessening of illumination and apparent distortion of the various parts of the specimen, which most certainly would take place with any of the fixed forms of convex lenses that are either ground, blown, or cemented upon the top surface of the glass cell. 6. The floor of the cell has been raised into the cavity of the cell. This, which insures a perfect filling of the cell with the preservative menstruum, has been accomplished by sinking a deep and broad circular groove (Fig. 3) into the top of the base, so as to allow the free circular edge of the glass cell to sink deeply into the top of the base when the glass cell and specimen are placed in exact position, thus forcing the specimen farther toward the top of the cell and insuring a perfect filling of the cavity. 7. A deep and broad circular groove has been made in the top of the base. This, when the glass cell is fitted into it, serves to make an air-tight joint, thus preventing either the entrance of air into the cavity of the cell or the exit of any water that might form by evaporation from the gelatin. If further protection is desired, a ring of some resinous cement, as asphalt or Canada balsam, might be made around the glass at its junction with the base, on the plan of an ordinary microscopical mount; or, if preferred, Lloyd Owen's method of imbedding the specimen in a stratum of glycerin-jelly, under which there is a layer of a mixture of the jelly and oxide of zinc, can be employed.

For the ready study of microscopical preparations, Manz, of Freiburg, $\frac{353}{\text{Mar.,'94}}$ has constructed a demonstration lens made of two plano-convex lenses,—one thirty-nine millimetres in diameter, the other being of a ten-centimetre focus. These are mounted in a short tube so arranged that a proper focus is obtained by turning the

ocular. As a means of preserving eye-specimens and retaining the transparency of their refracting media, Kruckmann, of Rostock,[353 June, '94] suggests that, after the specimen has been kept from two to four days in a liquid-gelatin solution, it be dipped into a $\frac{1}{12}$-per-cent. solution of formalin.

UNCLASSIFIED.

Valude, of Paris,[152 Apr. 6, '94] does not believe that the presence of any diathesis, either albuminuric or diabetic, contra-indicates the performance of operations on the eye, though union of the wound is slow.

Lydston, of Chicago,[347 Feb., '94] has studied a fossil which he thinks is a typical example of a petrified eye. The different layers and structures of the human eye could be readily made out both macroscopically and microscopically.

Davis, of New York,[462 Oct., '93] makes a strong plea for the establishment of suitable institutions for the treatment of contagious diseases of the eye.

Osborne, of Hamilton, Ont.,[249 Jan., '94] has examined the eyes of 132 inmates of an asylum in that province, and has found that 29.6 per cent. of the cases were due to congenital and lamellar cataracts, 16.06 per cent. to ophthalmia neonatorum, 11.36 per cent. to atrophy of the optic nerve, 7.57 per cent. to sympathetic ophthalmia, 6.82 per cent. to traumatism, 6.82 per cent. to trachoma, and 5.3 per cent. to retinitis pigmentosa. Statistical comparisons made by Chase, of Denver,[19 Nov. 7, '93] appear to refute the prevalent belief that diseases of the eye which are induced or aggravated by bright light, heat, and dust are more common in the Rocky Mountain regions. The lower percentage—1.1 per cent.—of senile cataract cases recorded the author attributes to the youthfulness of the population. Sym, of Edinburgh,[86 July, '94] states that the proportion of blind persons to the population of Scotland is at present 1 to 1439, compared with 1 to 1182 in 1881. Blindness is more prevalent in sections most remote from medical centres,—a strong argument in favor of requiring all graduates of medicine to have a knowledge of disease of the eye.

OTOLOGY.

By CHARLES S. TURNBULL, M.D., Ph.D.,

AND

ARTHUR AMES BLISS, A.M., M.D.,

PHILADELPHIA.

EXTERNAL EAR.

Auricle.—Epithelioma of the auricle has been reported in a number of instances during the year, treatment being little changed from the already well-established methods of excision by the knife or cautery. Foucher, of Montreal, [122 Jan.,'94] reports a case in which a large part of the helix was involved, as well as the external auditory meatus. Chlorate of potassium in solution was applied to the diseased tissue, which was afterward dusted with iodoform and boric acid in equal parts. The author states that the growth yielded to this very conservative line of treatment.

Injuries to the lobule of the ear have been recorded as the result of the use of ear-rings. The employment of this primitive method of adornment (?) dates from such ancient times that we do not realize the possible dangers that may be caused by it. Max Thorner, of Cincinnati, [2008 '94] calls attention to the "pathological conditions following piercing of the lobules of the ears." In his own experience he has met with three cases of erysipelas of the auricle and face, two cases of cleft lobule, several instances of eczema of the auricle, one case of fibrochondroma of the auricle, one of fibroma of the auricle, and one of keloid of the auricle and face,—all resulting from the irritation produced by ear-rings. In addition to such cases of his own, he mentions the comparatively numerous instances, reported by Hufeland, Dieffenbach, Knapp, Agnew, Turnbull, Finley, Bürkner, Schwartze, Politzer, Bacon, and others, of fatal trismus, fibroids, keloids, necrosis and gangrene, erysipelas, and malignant growths. The author remarks: "It is time that this relic of barbarism be relegated where it belongs,—to the by-gone follies of superstition and fashion."

As a further contribution to this subject, we may cite the article by Fournier, of Paris, $_{\text{July 15,'94}}^{24}$ in which are reported two cases of lupus the result of perforation of the lobules for ear-rings.

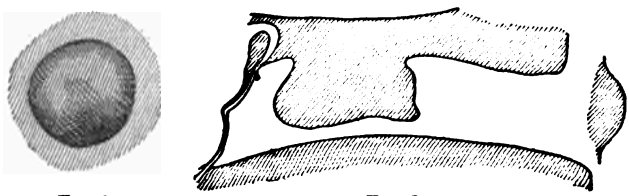

FIG. 1. FIG. 2.

EXOSTOSIS OF EXTERNAL AUDITORY CANAL. (BARCLAY.)

Medical Review.

He refers to some cases of Leloir showing this same condition; also a similar infection reported by Unna. In some of the tubercular cases a direct history of infection could be obtained.

Traumatism of the Auricle and External Canal.—Ménière, of Paris, $_{\text{Mar.,'94}}^{11}$ at a meeting of the Laryngological Society of Paris,

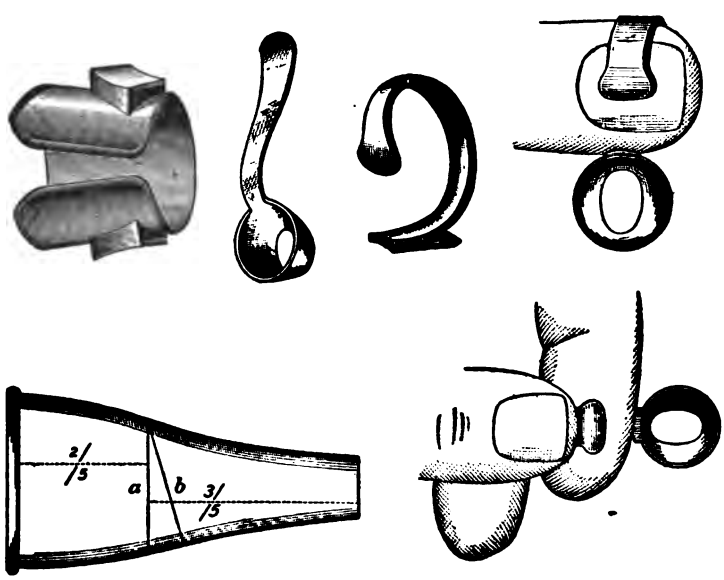

AURAL SPECULUM. (BARCLAY.)

Medical Review.

November 3, 1893, described a case of attempted suicide in which the ball, shot from a revolver, the muzzle of which was placed in the concha, passed through the temporal bone down into the

pharynx, and was found in the mixture of blood, etc., vomited by the patient. Strange to say, the patient lived. There was facial paralysis; the meatus and external auditory canal were greatly widened, the fibrocartilaginous portion being rent under the pressure of the explosion. The drum-head was destroyed. Fluids syringed into the ear passed into the pharynx and mouth. Examination of the hearing showed that the voice, raised to loud tones, could be heard at four metres; bone-conduction was normal; Weber's test was negative. In the process of healing the auditory meatus became closed by cicatrization.

Five cases of fracture of the external auditory canal are reported by Barclay, of St. Louis. [82 May 12, '94] Hæmorrhage from the ear occurred in all these cases, thus simulating a fracture at the base of the skull. The author remarks that fracture of the external osseous canal and its integumentary tissues by force transmitted through the inferior maxilla is not infrequent, and its importance arises from the fact that it may be overlooked entirely, or else mistaken for a fracture of the base of the skull or for a ruptured membrana tympani.

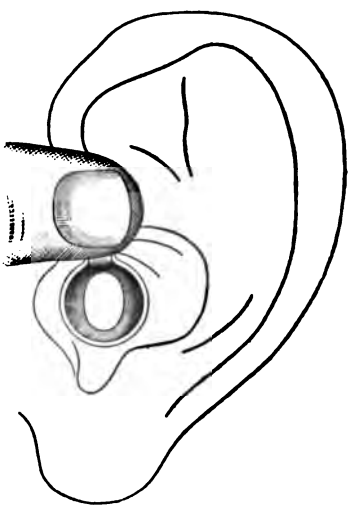

APPLICATION OF AURAL SPECULUM. (BARCLAY.)
Medical Review.

Barclay also reports a case of exostosis of the external auditory canal, in which the bony mass was removed by a reamer and round burr. Hæmorrhage was profuse, but was controlled by pressure of cotton plugs and by syringing with hot water. The entire growth was removed. (See Fig. 1 and Fig. 2.)

The author found the ordinary specula to be of little service, and devised the form illustrated in the accompanying cuts. This speculum is cut off at the point where the ordinary instrument projects beyond the intertragal notch. A handle is attached so that it can be retained in place by the examiner's fingers.

A rare affection of the auditory canal is mentioned by Treitel, [69 Dec. 29, '93] viz., a case of diphtheria, in which, besides the false

membrane in the mouth, nostrils, and upon the auricle, a deposit, much resembling a diphtheritic membrane, was observed in both auditory canals. The author states that the true character of this membrane was not determined, and acknowledges the possibility of its having been due to staphylococci. He believes, however, that the membrane was diphtheritic and the case is to be considered an extremely rare one, such deposits in this locality having been reported in but a few instances. A far more common deposit in the auditory canal, and yet one not frequently met with, is cholesteatoma. Scholefield, of London, $^{6}_{\text{Oct.14,'98}}$ reports such a case in which the condition appeared to have been caused by the presence of a bug within the canal. Syringing the canal with warm water brought away a cholesteatomatous mass having a small specimen of *Cimex lectuarius* in its centre.

Furuncles of the auditory canal have been frequently reported during the year. Courtade, of Paris, $^{37}_{\text{Dec.,'98}}$ describes a new method of treating these abscesses of the external auditory canal by "*tubage.*" He used a small drainage-tube for dilating and, at the same time, draining the canal, in a case of membranous closure of the auditory canal and in cellulitis and abscess of this tract, with remarkable results. He claims to have relieved cases at once by this form of treatment after pain had prevented sleep for from eight to fifteen days. The object gained by the tube is sufficient dilatation of the canal to allow the passage of antiseptic washes to and from the fundus, which clean away the accumulation of pus and exfoliated epithelial scales. In one case, where a membranous diaphragm closed the external canal, the tube was of service in maintaining the artificial opening which had been made, and for removing pus and epithelium which had collected in the deeper parts of the canal. Symptoms of cerebral disturbance had developed in this case, as a result of pressure and infection from the mass.

Foreign Bodies in the External Auditory Canal.—This common accident and the results of careless extraction have received much attention in the journals of the year. Guillaume, of Reims, $^{577}_{\text{Dec.,'98}}$ has devised a new method of removal which is simple and may be quite effective in cases where the body is not wedged too tightly in the canal or has been surrounded by a ring of swollen tissue. He melts some gutta-percha in an iron spoon, and

with a fine probe of iron wire, having a small ring at its extremity, he takes up some of the liquid gutta-percha on the ring and passes it into the auditory canal; the gutta-percha is applied to the foreign body and held against it until the latter is firmly adherent. The probe is then withdrawn, bringing away the foreign body sticking fast to the gutta-percha head.

In the extraction of foreign bodies, Natier, of Paris, warns against the employment of forcible syringing, especially if such procedure cause vertigo, or if a perforation of the drum-head exist. He also condemns the use of a loop of metal wire.

D'Aguanno, of Palermo, $_{\text{Aug.,'94}}^{37}$ reports two cases of larvæ in the ears of patients,—*Musca carnaria sarcophaga.*

Delie, of Ypres, $_{\text{Aug.,'94}}^{37}$ experienced much difficulty in removing a mass of impacted cerumen from an ear in which there was an exostosis of the external auditory canal. The bony growth depended from the superior wall of the canal, and was supposed to have developed as a result of irritation caused by scratching the canal with a needle.

Among the odd and unusual substances reported as having been removed from the external canal may be mentioned a water-melon-seed, found by Westervelt, of Alice, Texas. $_{\text{Aug.,'94}}^{207}$ The seed had been shot into the child's ear and had remained there for five years. Vallin $_{\text{July 14,'94}}^{220}$ found a pearl in the fundus of an auditory canal of a child between 4 and 5 years of age, while Tansley, of New York, $_{\text{Aug.,'94}}^{51}$ distanced all competitors by removing a *diamond* from the ear of a small patient. Schmiegelow, of Copenhagen, $_{\text{No.11,'94}}^{375}$; $_{\text{Sept.,'94}}^{673}$ has met with a sad example of the disastrous effects which may follow roughly-executed attempts to remove a foreign body from the auditory canal. The efforts to remove, in this instance, a stone from a child's ear, induced an attack of purulent otitis media, and, later, fatal tetanus.

MIDDLE EAR.

Excision of the Ossicles.—The numerous reports of operative procedures upon the sound-conducting apparatus of the ear which have appeared in this year's journals have not led the editors to alter the opinions expressed in the ANNUAL of last year regarding the value of these operations and their proper place in aural surgery. Many of these papers were prepared for presentation before otological societies, and are the carefully-expressed thoughts, very

often the after-thoughts, of the most distinguished aurists. The subject of stapedectomy has received an especial degree of attention. As a sort of introduction to the discussion of this procedure, we quote from the article of Politzer, of Vienna, $\frac{11}{\text{May, '94}}$ on "A Primary Affection of the Labyrinthine Capsule," read before the Section of Otology at the Eleventh International Medical Congress. This affection is characterized most especially by progressively-increasing loss of hearing, as well as of the auditory function. As a result of post-mortem investigations the author concludes that in such cases there is present, with an affection of the mucous membrane of the middle ear, a primary disease of the osseous part of the labyrinthine capsule, which results in a proliferation and enormous development of the same. This disease of the osseous part is most often developed in that portion of the capsule which surrounds the fenestra ovalis, and tends to cause ankylosis of the stapes by proliferation of new tissue. This tissue has the characteristic appearance of new-formed bone-tissue, and causes not only a great thickening of the labyrinthine wall, but extends equally above the fenestra ovalis and the base of the stapes, which latter is joined by ankylosis with the labyrinthine capsule itself. A series of preparations made by Politzer showed different degrees of this condition. In cases of deafness of a minor degree the new-formed osseous mass had caused the disappearance of the annular ligament, and had produced a partial ankylosis. In other preparations the whole base of the stapes had been completely absorbed by the osseous mass, thickened by many times its diameter, and formed a structure of bony tissue which completely closed the fenestra ovalis. In another series of preparations the osseous formation was seen to issue from the labyrinthine capsule and penetrate not only into the base of the stapes, but also into the triangular space formed by the crura of this ossicle; so that the base of the stapes, seen from without, was covered completely by this new formation. In cases of still higher degree of deafness the stapes appeared to be transformed into a triangular bone, which closed the fenestra ovalis and the niche. One preparation was shown in which almost the entire labyrinthine capsule appeared transformed in this manner. The osseous proliferation extended even in the direction of the cochlea and completely filled the scala tympani with new-formed osseous material.

The author states that the etiology of this condition is obscure. It occurs, for the greater part, in very aged individuals. In two cases the patients suffered from gouty manifestations. It was not possible to establish a syphilitic origin for the affection.

In reference to treatment, Politzer discusses the operation for extraction of the stapes. It seems to him scarcely possible that this procedure, even if resorted to early in the course of the affection, when the first symptoms were recognized, and while the stapes was yet movable, can lead to any useful result; since, as is shown by his pathological investigation of this subject, the newly-formed bone in the labyrinthine capsule tends to advance constantly in the direction of the fenestra ovalis. We must conclude from this fact that, even after extraction of the stapes, the fenestra would be ultimately closed by ossification. When once ankylosis has occurred extraction is impossible, because the immovable base of this ossicle tends to break away from the body of the bone under traction.

Politzer recommends the internal use of iodide of potassium, beginning early in the course of the affection with moderately large doses, intermitting its employment at intervals.

Bezold, of Munich, $^{66}_{\text{Jan.,Apr.,'94}}$ records the results of a minute examination of the aural conditions found in "a case of ankylosis of the stapes and a case of nerve-deafness, with manometric examinations and autopsies." In the case of ankylosis there "was bilateral excessive hardness of hearing, with negative Rinné and increased bone-conduction, notwithstanding old age. There was, also, as is found in all these cases, a shortening of the lower portion of the scale for air-conduction. He diagnosed ankylosis of the stapes in life and the autopsy confirmed the diagnosis. The patient had died from pleuro-pneumonia. There was a fresh middle-ear suppuration of mild degree, which was to be considered as a symptom of the terminal pneumonia. Diplococcus pneumoniæ was found in the aural discharge. The second case—one of nerve-deafness—showed perception on the left side for only about one and a half octaves in the middle register. Bone-conduction was completely wanting. The autopsy of this second case demonstrated an atrophy in the organs of the sound-perceiving apparatus. The pathological conditions found in the case of ankylosis of the stapes are illustrated on page C–9.

Fig. 1 (stapes ankylosis) shows vertical section through the outer labyrinth-wall anterior to the pelvis ovalis and the first and second turns of the cochlea. The diseased bone is recognized by its pale color (hæmatoxylin stain). A small portion near the tympanic cavity is spongy with many cavities. The larger portion lying between the first and second turns consists of osteoid substance with numerous cells, the medullary cavities being completely filled with cells. The periosteum on the side of the tympanic cavity is thickened and vascular, and the superficial layer of the mucosa is infiltrated with pus-cells (terminal otitis media purulenta acuta).

Fig. 2 (same magnification) shows vertical section through the pelvis ovalis and the foot-plate of the stapes. The diseased bone is darker, as the specimen was stained with carmine. The upper portion of the foot-plate is much thickened, involved in the spongy, transformed bone, and adherent to the margin of the pelvis ovalis. The inner surface only is covered with cartilage. At the lower margin of the foot-plate the pathologically-changed margin of the pelvis ovalis is rarefied and destroyed; so that the annular ligament appears very broad. The diseased bone extends upward to the canal for the nerves of the vestibule and the two upper ampullæ. The periosteum in the pelvis ovalis is much thickened,—on the labyrinthine side of the foot-plate not perceptibly.

At the Eleventh International Medical Congress, otological section, Bezold reported his experience in a case of stapedectomy for the relief from tinnitus aurium and to obtain an increase of hearing-power. The patient was a woman, 48 years of age, whose middle ears were in the process of sclerosis after purulent otitis media. Hearing-tests gave:—

	Whisper.	Ordinary Conversation.
Right	2 cm.	20 cm.
Left	10 cm.	90 cm.

	Lower Tone-Limit.	Upper Tone-Limit.	Rinné.
Right	C (64)	Galton 1.7	—7 sec.
Left	A (110)	Galton 2.3	—5 sec.

"*A*" on vertex, hearing-ear not determinable	+12 sec.
a' on vertex, hearing-ear not determinable	—2 sec.

Extraction of the stapes was performed on the right ear. The result of the operation for the first few days was absolute

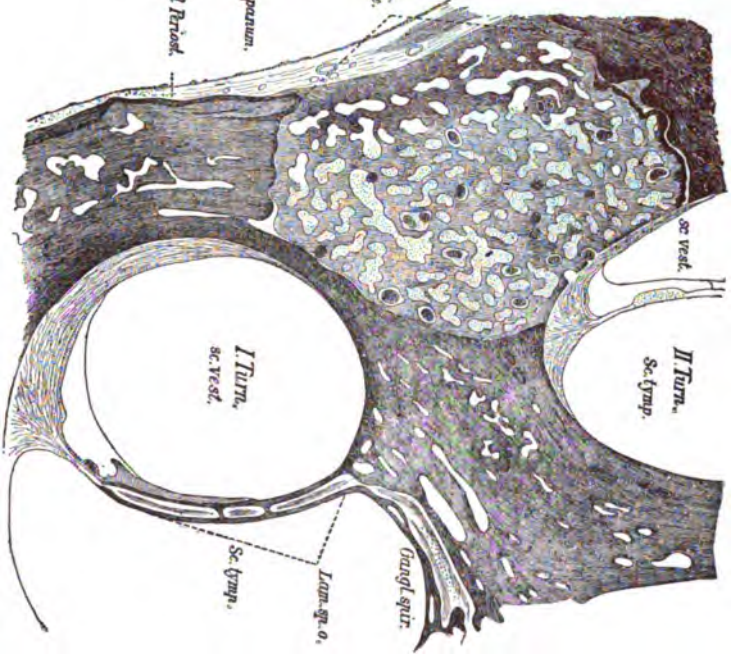

Fig. 1.

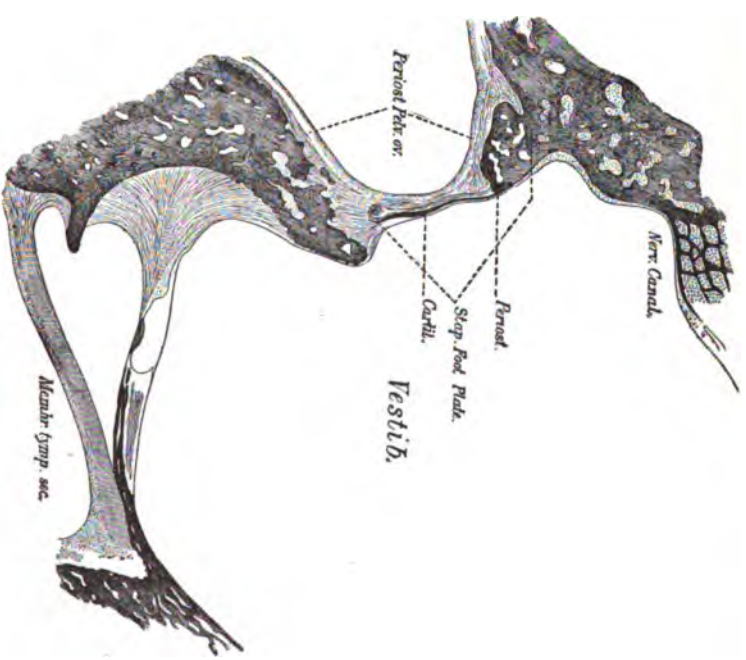

Fig. 2.

ANKYLOSIS OF THE STAPES AND A CASE OF NERVE-DEAFNESS. (BEZOLD.)

Archives of Otology.

deafness. After three weeks some hearing returned, but remained always much less than before the operation. Excessive dizziness followed the operation, and continued for three weeks. There was continuous tinnitus, but chiefly in the ear not operated upon. Bezold closes his report with the statement that Blake, of Boston, had informed him that in his (Blake's) two cases there was no permanent improvement, but, in one, a decrease from $\frac{12}{65}$ to $\frac{5}{65}$ for the fork. Ludewig had reported to him that he had found deafness in six cases of *unintentional* extraction of the stapes.

Blake, of Boston, presented his views in an article read before the Eleventh International Medical Congress upon extraction of the stapes in chronic non-suppurative disease of the middle ear. His conclusions do not favor this procedure, and are of especial interest, as they represent the opinions of the distinguished American aurist who first suggested and practiced this operation. Blake has reported twenty-two cases of stapedectomy. Out of these he was able, in one single instance only, to effect improvement in hearing, and in this case the fixation of the stapes was not complete. In the remaining twenty-one cases there was no improvement, and some of them, indeed, became decidedly worse in respect to hearing-power and tinnitus. In five cases vertigo came on as the result of the operation, and in these it still persists. Blake therefore cannot recommend removal of the stapes in cases of chronic non-suppurative otitis media. It involves a risk of danger to the labyrinth. Colladon, remarking upon Blake's paper, says that the author seems to settle, in a definite way, the subject of stapes extraction in non-suppurative cases. In his (Colladon's) opinion this operative procedure ought to be confined to suppurative affections of the middle ear. Gellé, of Paris, in a discussion of Blake's paper upon "Exploratory Tympanotomy," draws attention to the fact that improvement had been gained only in cases where the fixation of the stapes was consequent upon otitis purulenta, while all indicated the complete failure of stapedectomy in cases of sclerosis of the tympanic cavity. Cozzolino, of Naples, stated that his experience, also, had led him to feel that the surgery of the middle ear is very uncertain in its influence upon the hearing-power, and transient in its results in cases of primary adhesion or hyperplastic processes in the tym-

panum. In place of stapedectomy Blake advocates the formation of a small opening in the posterior half of the drum-head, through which the sound-conducting apparatus can be inspected and the tensor or stapedius muscles or any adhesions can be divided. The parts may be rendered insensitive by cocaine. After the operation the application of a paper dressing moistened in sterilized water serves to close the opening, and healing is so complete that the operation can be repeated at intervals if required. De Rossi remarked that, in his operation for mobilization, after puncturing the centre of the drum-head with a lancet-shaped needle, he introduces a blunt-pointed bistoury in this opening, incises upward the whole length of the manubrium, and makes a hinged flap, which he draws outward toward the meatus. The incudo-stapedial joint, thus exposed, is then divided, and the long branch of the incus is disarticulated. Adhesions found about the incus are then cut through, and the flap is reset in its place and maintained there by cotton-wool dipped in boroglycerin. Closure occurs in two or three days.

Returning again more exclusively to the subject of *excision*, we would mention the paper of Garmault, of Paris, at the Eleventh International Congress, upon stapedectomy. He reports three cases in which this operation was performed, all of which were sclerotic cases, one having, at an earlier date, been a suppurative process. In all these cases there was considerable reaction after the operation, shown by increase of tinnitus, nausea, vertigo, and diminished hearing. Tinnitus disappeared in two of the cases. There was no practical increase of hearing in any of them. The author is not enthusiastic about stapedectomy, and states that its results cannot compare with those following extraction of cataract, this ocular and the aural operation having been mentioned by some as analogous. The author finds that the symptom of tinnitus may be relieved by stapedectomy. He has several times found difficulty in seeing and reaching the fenestra ovalis, and is surprised that operators who have frequently mobilized the stapes make no reference to this point. In discussing the paper Masini stated that, in cases of sclerosis of the tympanum, he had practiced the mobilization of the stapes on many occasions, and had been enthusiastic about it; but now, after many observations, he thought that the results were not lasting. He was convinced that

it was exceedingly difficult to displace the stapes out of the fenestra ovalis without breaking the limbs of the ossicle.

No better authority upon the surgery of the middle ear can be found than C. H. Burnett, of Philadelphia. His article on "Relief of Chronic Deafness, Tinnitus Aurium, and Vertigo by Removal of the Incus and Stapes" $_{\text{Nov.18,'98}}^{61}$ gives his later impressions regarding "excision" in sclerotic conditions. Five cases are reported, and in each instance the incus was removed, but the stapes in only one case. Referring to this one case of stapedectomy, Burnett states that the results were so good, so much better than in some instances in which the stapes was only liberated by removal of the incus, that in any case of tympanic vertigo in which liberation or partial removal of the stapes does not give as much relief as is desired, puncture of the foot-plate of the stapes, in order to relieve the labyrinthine tension, would be justifiable. Burnett thus sums up his conclusions: 1. That removal of the retractive force of the sound-conductors upon the stapes is the efficient means of relieving the tinnitus, deafness, and vertigo due to the lesions of chronic catarrh of the middle ear. 2. That the removal of the retractive force upon the stapes can be accomplished efficiently and simply by removal of the incus alone, and even by resection of its long process. 3. That the improvement in these cases is due to the liberation of the stapes from the retractive power of the tensor tympani muscle, and the consequent unimpeded action of the stapedius muscle, which, relieved of the antagonism of the tensor tympani, tends all the more to draw the stapes from the oval window, thus aiding in the isolation and improved mobility of the bonelet, as well as in removing its undue pressure inward upon the labyrinth fluid. 4. It seems wiser, therefore, in most cases of chronic catarrhal deafness, tinnitus, and tympanic vertigo, not to sever the stapedius tendon and remove the stapes, but to be content with the removal of the incus only. 5. Removal of the incus alone, the membrane, malleus, and stapes being left *in situ*, gives more space to the drum-cavity, *increases its resonance*, and permits freer access of sound-waves to the stapes, thereby improving the hearing. 6. The progressive improvement in the hearing noted in many instances, especially in Case 1, must be due to the continuous passive motion exerted upon the ankylozed stapes by sound-waves, which are enabled

to reach this bonelet much more freely after the removal of the incus.

Suppurative Otitis Media; Operative Procedures.—F. L. Jack, of Boston, [99] reviews the results of his operations in stapedectomy, already published, and details a few later cases. Of the original 16 cases, 3 were in active process of suppuration at the time of the operation; 9 were the effects of chronic purulent inflammation. These ears, with one exception, have remained healed. There were 3 cases of otitis media insidiosa (sclerosing, plastic or non-suppurative inflammation). The results have, on the whole, been rather favorable. In those cases where the foot-plate remained, there was practically no change from preceding tests. On the other hand, where the oval window had been completely cleared the hearing was practically the same as found immediately after the operation.

In reviewing the year's work the following conclusions are drawn: 1. The operation is followed by the best results in the class of cases where, from the increase of tissue,—the effects of suppuration or hypertrophic inflammation,—the stapes offers an obstruction to sound-waves; by its removal the hearing is improved. The results in cases of otitis media chronica insidiosa, on account of failure to extract the foot-plate, are not encouraging. 2. Inflammatory reaction is unusual and followed by no bad results. 3. The hearing is not necessarily impaired by the subsequent growth of a thin cicatricial membrane over the fenestral niche. 4. Some cases of tinnitus and aural vertigo are relieved, and there is little chance of causing permanent vertigo in cases where it had not previously existed. 5. It rarely happens that a patient improves for all tones. Improvement in hearing the human voice is out of proportion to the improvement for other sounds, and the reverse sometimes occurs. 6. Failure in some cases may be due to hæmorrhage into the labyrinth at the time of the operation. It is believed to be a rare complication, but was thought to have occurred in one or two cases. 7. In removing carious ossicles, the stapes, if found diseased, should also be removed.

Among the celebrated aurists who discussed the subject of excision at the Eleventh International Congress was Ludewig, of Hamburg, whose paper on "Extraction of the Auditory Ossicles"

was received with interest. He states that diagnosis of caries of the hammer and anvil is, in many cases, uncertain. Even granulations coming through and in front of the membrana flaccida do not always indicate its existence. A more certain sign is destruction of the drum-head in the posterior superior quadrant. In operating, Ludewig advises that the union between the end of the manubrium with the margin of the bone should not be interfered with until the tensor tendon is cut through and the incudo-stapedial articulation is severed. Otherwise, the free end of the malleus is moved out of place and it becomes difficult to snare the ossicle. In extracting the incus it is necessary to direct attention to a process of bone which is found over the entrance to the antrum. Here the incus-hook is apt to catch when the latter is too long.

In his fifty cases of excision performed in Hamburg, Ludewig had no fatalities nor injurious complications; no fever, no facial paralysis, no vertigo worthy of mention, and no damage to hearing. The incus was found carious in 85 per cent. of cases. The indications for extraction of the hammer and incus should be carried farther than at present. When a chronic middle-ear suppuration continues in spite of treatment lasting over a month, the next step is to carry out the extraction of the incus and hammer through the meatus, quite independent of the question whether caries of these bones has been diagnosed with certainty.

Politzer, of Vienna, in discussing this paper recommended that the term "spina tegminis" should be given to the bony process at the entrance of the antrum, which sometimes caught the incus-hook during efforts at extraction of the incus. Regarding the indications for the operation, he remarked that the extraction of the hammer and incus is only practiced by him if the greater portion of the drum-head is destroyed, and the hammer, therefore, is of no value for the function of hearing; also, when there is cholesteatoma in the attic. In perforation of Schrapnell's membrane, on the other hand, when suppuration is limited to the attic and the hearing-power is nearly normal, the hearing becomes diminished by extraction of the ossicles, and, in such cases, operative interference ought to be limited to opening the outer attic. Only after this treatment has proved ineffectual should extraction of the ossicles be practiced. In cases where extreme deafness existed there was observed an improvement in hearing after extraction of the

ossicles, but, when hearing was very near normal, the operation diminished it very much.

Reinhardt, of Duisburg, stated that, in his experience, cholesteatoma of the antrum or of the attic complicated caries of the ossicles so frequently that the mere extraction of these bones did not cause a stoppage of the suppuration, and that the opening of the antrum by Stacke's method was necessary.

Morton, of Minneapolis, [105] Feb. 1, '94 has operated upon seventeen cases, performing different phases of the "excision operation." Most of his cases were of the non-suppurative variety of otitis. He obtained certain degrees of improvement in his cases,—so much so that he regards this form of surgical interference with considerable favor.

Moure, of Bordeaux, [188] Dec. 21, '93 recording his experience from a series of cases of excision of the ossicles for the cure of otorrhœa, refers to the removal of the stapes. He finds this a far from easy operation, without causing fracture of the bone, in its removal for chronic non-suppurative inflammation, as well as in cases of otorrhœa. There is a certain amount of danger of perforation into the vestibule, septic material thus being introduced into the labyrinth.

The patients operated upon are apt to be alarmed by intense vertigo, muscular spasms, and disturbances of circulation. With the stapes in place, there is less danger of infection reaching the inner ear from the tympanum. Excision of the hammer and anvil is of advantage in all cases where an "alteration" of those ossicles has been observed and in such cases of chronic otorrhœa as have resisted other modes of treatment.

B. Alexander Randall, of Philadelphia, [80] Feb., '94 has given the various excision procedures a fair degree of test, and finds that his results do not agree with the published statements of several operators who record most brilliant results and who appear to have no failures. The text of his paper is condensed in its conclusion: "The cases suitable for excision form a small group, including very few catarrhal cases and only some of the really obstinate suppurations. Most of the serious purulent affections demand more radical intervention, of which this may form one step."

Miot [87] July 15, '94 again refers (giving notes of cases with very good

results) to the operation for mobilizing the stapes, the technique of which procedure is sufficiently well known. The indications for its performance are: undoubted proof of middle-ear sclerosis; bone-conduction in excess of air-conduction; the existence of tinnitus aurium and vertigo; thickening of the drum-head; deafness becoming less marked when the patient is in a noisy place. The author finds that mobilization of the stapes is frequently the only means of changing certain pathological conditions which resist all other treatment. To obtain good results it is necessary to observe the indications for operation. With antiseptic precaution the procedure is without danger. After-treatment and proper hygienic conditions are necessary to maintain the good results obtained.

The Otitis Media of La Grippe.—Herck [136 Oct.15,'98] reports two marked cases of this condition,—one occurring in a man 32 years of age, the other in a woman aged 58 years. In both cases there had been an attack of influenza, toward the end of which symptoms of middle-ear inflammation had developed, with the characteristic slight bleeding from the auditory meatus. In one case the bleeding appeared to come from a small bulla on the membrana tympani; in the other case, from the walls of the external auditory canal close to the drum-head. The author cites seven cases of Delstanche not heretofore given. He refers, also, to Delstanche's method of treatment, which consists in injections of iodoformed vaselin *per tubam.* This, the author claims, not only relieves the pain of the otitis, but also notably arrests the progress of the inflammation. In his own two cases Herck used pure vaselin-oil with good results.

Wolff, [1096 Oct.18,'98; 51 Feb.,'94] also, in an article entitled "Simultaneous Appearance of Grave Otitis Media in Three Children in One Family," has evidently recorded the symptoms of an influenzal otitis media. Two girls, 11 and 10 years old, and their brothers, aged 9 and 8, had general catarrhal symptoms for about a week, croupy cough being present. Suddenly, in the night, the younger girl was attacked by pain in the left ear and high fever; two days later the right ear became painful. On the fourth day a purulent discharge from the left ear began, and the elder girl complained of pains in both ears, her temperature rising to 41° C. (105.8° F.). Six days later the mastoid regions in both children were red, œdematous, and very painful. Paracentesis of the right tympanic mem-

brane was done in the younger girl, a quantity of pus escaping. The other membranes had ruptured spontaneously. One of the boys was taken ill with high fever and intense pain in the left ear, also beginning suddenly and at night. The following morning paracentesis was performed, and blood and pus came away. The boy recovered rapidly and the girls after several weeks, the elder one only after radical curetting of the necrosed mastoid process on the right side. Bacteriological examination showed the presence of short bacilli and pyogenic micrococci, especially the staphylococcus pyogenes aureus, but no pneumococci nor bacilli of influenza were found. It is most probable that these were cases of influenza. The hæmorrhagic form of the otitis media in one of the children tends to support this hypothesis.

Otitis Media Complicating Infectious Diseases.—Savigny[108] warns the medical attendant to watch carefully for any involvement of the middle ear in infectious diseases. Such a complication is announced often by a rise of temperature, pains in the ear and side of head, and "cerebral symptoms" of a more or less severe character. Too often the cause for these is sought in other parts of the body rather than at the real seat of inflammation. The author advises that the nasal, post-nasal, and pharyngeal mucous membrane should be cleaned with mild antiseptic solutions and powders. Otitis, when it develops, may be arrested by the employment of 1 part to 50 parts salicylated oil, a few drops of this being instilled into the auditory canal every three hours. If pain is intense, besides the use of these drops, it is advised to apply from 3 to 5 leeches at the tragus or over the mastoid region. To children small doses of Dover's powder may also be administered at night. If pain continue, poultices are of great benefit not only in allaying pain, but in hastening the perforation of the drum-head and the liberation of pus. Where it is possible, this latter end may be accomplished by paracentesis. [Some exception might be taken to the use of cataplasms. Hot applications are of decided benefit when the otitis has assumed a purulent type with rupture of the drum-head. These are best applied in the form of dry heat, or by means of flannel in layers, wrung dry after being dipped in boiling water. While steaming hot they should be placed over the affected ear and the surrounding area, covered with dry flannel, and renewed at intervals. At the same time

it is well to drop into the auditory canal a few drops of a 10-per-cent. solution of cocaine hydrochlorate. Before suppuration is threatened, but while the inflammatory process is active, it is well to apply the leeches, as Savigny directs, and to follow up the use of these depleting agents by the use of an ice-bag. The otitis of the infectious diseases, especially in young children, is a trying ordeal for the general practitioner far removed from a specialist's aid. He will not go far wrong if, when so situated, he resort to the simple measures described.—EDS.]

Otitis media from hereditary syphilis has been given some attention by Gradenigo, of Turin, $^{11}_{May,'94}$ who has observed that in this disease, in addition to the well-known form of complete bilateral deafness, one meets with less marked cases of progressive deafness presenting the characteristics of chronic otitis media, with rapid diffusion to the labyrinth. In this less severe form of hereditary syphilis the characteristic symptoms are, as a rule, little marked, the most frequent being interstitial keratitis. This symptom is often absent, and diagnosis must depend on the patient's general condition and the family or personal history; also, on the malignancy shown by the morbid process in the middle ear, extending to the inner ear. The less severe form is found chiefly in the female sex, as is, also, the more severe form; but it differs from the latter, which usually appears at the age of puberty, in appearing, as a rule, much later in life,—generally between 20 and 30 years of age. Catarrhal lesions of various grades in the nose and naso-pharynx are found as direct exciting causes of the mischief. The treatment of these lesions, although useful, does not, however, give such brilliant results as in simple otitis media. A mixed specific treatment produces no worthy improvement in a certain number of cases. [Given a case of specific inherited interstitial keratitis accompanying an otitis of suspected or obscure origin, a full specific treatment must give as satisfactory a result as does this usual treatment of such a typical specific inherited eye disease.—EDS.]

The association of true ear disease with neurasthenic conditions is referred to by Cozzolino, of Naples, $^{11}_{June,'94}$ in a paper on "Oto-neurasthenia, Primary, Secondary, and Associated, or Neurasthenia due to Diseases of the Ear and to Diseases of the Rhino-pharynx." There may be (1) oto-neurasthenia, pure and simple

(*essential form*), or (2) ear disease accompanied by neurasthenic symptoms (*associated form*). In the essential form the symptoms depend upon intra-cranial affections, and are bilateral. In the associated form they are unilateral. In essential oto-neurasthenia, instead of loss of auditory power, we find hyperacusis, which increases the electrical excitability of the acoustic nerve comparable to nervous asthenopia, with which it may either co-exist or alternate. The subjective aural symptoms—vertigo, tinnitus, etc.—are paramount in this form. These symptoms have, as a characteristic, that, in the essential form, they fail to improve under local treatment; that they improve very slightly in the associated form; while they do yield—though in a somewhat transient way—to the general treatment used for neurasthenic subjects. The symptoms are not isolated, but are accompanied by other local neurasthenic phenomena, while they are made worse by any excess of brain or psychical disturbance. The auricular neurasthenic symptoms attain the greatest development in the cranial form of cerebro-cardiac neurasthenia. In individuals whose hearing-power is normal, or nearly so, but who complain of considerable entotic disturbance,—*i.e.*, subjective aural symptoms,—the condition of the cerebro-spinal system should be studied to learn the part that this plays in causing want of muscular and vascular tone in the intra-auricular structures. The tensor tympani and stapedius, as well as all the other muscles, lose their tonicity in cerebral neurasthenia, and consequently the subjective labyrinthine troubles can also, in essential oto-neurasthenia, be referred to the cavity of the tympanum, if we examine the subject from the pathogenic point of view. Auricular vertigoes, pure or mechanical, are those of which the symptoms indicate the compression of the round or oval windows; but auricular vertigo may be confounded often with vertigo proper to neurasthenia, because one may note the aural subjective symptoms. The author does not accept without reservation the opinion that vertigo is exclusively a psychical stigma to be added to the list of those which characterize mental degeneration. It is precisely these varieties of forms and of intensity which prevent one from confounding neurasthenic vertigo with auricular vertigo, passing from simple confusion to severe dizziness with oscillation of the ground and sensation of falling. In neurasthenic vertigo, the patient, it is true, thinks he is falling; but he does not fall, as

happens in auricular vertigo. In this latter the patient feels as though the earth opened at his feet and swallowed him like the trap on the stage of a theatre. The illusions produced by the subjective noises, as well as the psychical disturbances relating to the sense of hearing which are caused by sudden, unexpected noises, are only possible in neurasthenic individuals, especially in the subjects of psychical degeneration. A combination of auricular neurasthenic symptoms may be found combined with those of hysteria, and may present the phenomena of oto-hystero-neurasthenia,—of importance in medico-legal investigation. The most striking characters of such associated forms are their tenacity and their gravity, due to their persistence. We have, in addition to hemineurasthenia described by Beard, oto-hemineurasthenia, in which auricular and other noises may be limited exclusively to our ear, without the existence of any material lesion of the auditory apparatus. The gravity and greatest trouble caused by associated oto-neurasthenia are in direct relation to the clinical form of neurasthenia with which it is associated, especially in cerebral and cardiac psychical affections. In the former, headache is an accompanying symptom. Diagnosis and prognosis, as well as treatment, demand an early recognition of the different forms of oto-neurasthenia. Certain forms of general neurasthenia with secondary cerebral characteristics must be admitted, due to diseases of the ear and of the rhino-pharynx.

Tansley, of New York, $^{51}_{Feb.,'94}$ reports a case of acute suppuration of the tympanum after an operation on the vault of the pharynx. The case developed an acute inflammation of the attic, with grave cerebral symptoms. The operation within the pharynx consisted of the removal of an hypertrophied pharyngeal tonsil, which extended rather low along the posterior wall of the pharynx. This operation was undertaken for the relief of deafness due to subacute otitis media catarrhalis. It was performed with extreme care, all antiseptic measures being observed. The author employed his "bullet-mold forceps," using his finger behind the velum as a guide. Two days after the operation the patient developed a very sharp pharyngo-tonsillitis with high temperature. Three days later an acute suppuration of the middle ear (left) manifested itself, and on the following day cerebral symptoms, with high temperature and rapid pulse, were noted. The pupils were small;

there was great headache, chiefly at the vertex and frontal region; great restlessness, and considerable pain in the ears. The author concluded, from the subjective and objective symptoms, that he had to deal with a suppurative inflammation of the attic space superimposed upon a similar condition in the tympanum proper. As a means of relieving the parts, the author used a short Graefe cataract-knife in the following way: with cutting edge directed upward he pierced the drum-head just behind and upon a level with the short process of malleus, and then forcibly cut directly upward and outward for about half an inch. The knife was felt to pass over rough bone. Following this incision, which appeared to effect local depletion, relief of tension, and to encourage drainage, there was an immediate abatement of the severe symptoms, and the patient, a boy of 14 years of age, soon recovered.

Traumatic Deafness.—Bates, of New York, $\frac{1}{\text{Nov.11,'93}}$ has seen six instances in which traumatic deafness was associated with rupture of the drum-head. He believes that such cases require immediate treatment, and recommends, as beneficial, the same lines of procedure usually employed for otitis media catarrhalis. Politzerization early in the treatment may not benefit, but will improve the hearing after the drum-head has healed.

Therapeutics of Middle-Ear Disease.—Heath, $\frac{61}{\text{Nov.,'93}}$ of Indianapolis, reports good results, in the treatment of otorrhœa, with papoid, or pepsin, and dermatol. Szenes, of Budapest, $\frac{11}{\text{May,'94}}$ read a paper on the "Therapeutic Value of Europhen, Alumnol, Diaphtherin, and Antiseptin in Suppurative Otitis Media." Diaphtherin caused sensations of burning, and the author was not favorably impressed either with this agent or with antiseptin. Europhen proved to be an antiseptic dusting-powder in suppuration of the external meatus,—the more so, as it adhered to the walls of the meatus and produced a slight decrease of secretion. Alumnol caused, in a few cases, burning sensations which continued for one or two hours, remaining as an unpleasant sense of warmth during succeeding days. In other cases no unpleasant sensations were noted. In slight suppuration it united with the pus to form stone-like pellets. These concretions, deep in the external canal, even if they were but of small size, are not to be disregarded, and this peculiarity condemns its use. Diaphtherin caused an increase of secretion, and the author was obliged to discontinue its use.

Cozzolino, of Naples, $^{37}_{\text{Nov.,'95}}$ recommends microcidin as an antiseptic medication in suppurative cases. This consists of beta-naphthol and caustic soda (naphtholate of soda). It is without odor, does not stain tissues or instruments, and is not an irritant. In antiseptic strength microcidin stands next to mercuric bichloride and alpha-naphthol. In suppurative otitis media the author has seen good results in the use of 4-per-cent. solutions of this compound,—perhaps quicker results than would have followed the use of boric acid. It is of use, also, in cases of acute mastoiditis and in simple furunculosis of the canal.

Deschamps, of Grenoble, $^{37}_{\text{Apr.,'96}}$ speaks favorably of the use of vapors of formol, or formic aldehyde, in affections of the middle ear. The method was suggested, several years ago, by Berlioz. The vapor, it is claimed, renders aseptic the parts against which it is insufflated, and solutions of about 5 per cent. can be used.

Weber's Test.—Corradi, of Verona, $^{2022}_{\text{'96}}$ has given much attention to the value of Weber's test, desiring to learn if its results were affected by the asymmetry in the cavities in the two temporal bones and the difference of structure and form in the bones of the cranium. His investigations tend to show that such abnormalities of structure do not affect the value of the test; and, if no disease exist within the ear, the sound of a tuning-fork placed at the vertex of the head, centrally, continues to be referred to the centre of the head.

MASTOID.

Stacke's Operation.—This operation, a modification of the old classical operation for opening the mastoid cells and antrum, is referred to so frequently by German aurists and general surgeons; is employed so successfully for the cure of long-standing, chronic, purulent otitis media, even when uncomplicated by mastoiditis; it has given such brilliant results; and it is based upon such sound scientific principles, that the excellent article by C. R. Holmes $^{66}_{\text{Oct.,'95}}$ upon the subject deserves the fullest report. This writer describes Stacke's operation as modified by Schwartze, and we reproduce the accompanying illustrations as of great value in elucidating the subject.

This operation "aims *to remove all diseased tissue found in the middle ear*, and to accomplish this one or all of the cavities are laid open. Stacke operates from within the osseous canal,

enlarging in the direction desired by removing concentric layers of bone until the accessory cavities are exposed and all diseased tissue is removed. To guard against cicatricial contraction of the meatus and to transplant healthy epithelium to the denuded cavity he devised the very successful method of preparing flaps from the membranous canal. The patient should be prepared for the operation by the usual careful cleansing with antiseptics now employed in all surgical procedures,—even for the old form of mastoid opening. "The ear is pulled gently forward, and the incision is begun one centimetre above the insertion of the auricle and is

FIG. 1.—VIEW SHOWING THE PARTS AS THEY APPEAR WHEN THE OPERATION UPON THE BONE IS FINISHED AND WE ARE READY TO REPLACE THE SOFT PARTS; ALSO INDICATING POSITION OF RETRACTOR AND LOOP. (C. R. HOLMES.)

Archives of Otology.

carried downward one centimetre behind and parallel to the insertion of the auricle, as far as the apex of the mastoid." If more room is required, make a free incision backward, at right angles to the first incision. (See Fig. 9.)

"Denude bone with raspatory backward, so as to expose mastoid, and forward into internal osseous canal to a point where the lining becomes membranous. Then, with a Stacke knife, cut through the soft parts, and we now have the whole of the lining of the canal protruding from the detached auricle like a funnel."

The auricle, with the cartilaginous part of the auditory canal attached to it, is then drawn forward and held well out of the

way by a retractor or, as Holmes advises, by a loop. The second retractor is adjusted to draw the posterior margin of the wound backward. (See Fig. 1.)

Diseased tissues now showing are followed up by curette or chisel. If the outer table of the mastoid is normal, the way to the antrum must be found by certain landmarks. (See Fig. 2.) The two landmarks are: the *linea temporalis*, an horizontal ridge formed by the extension backward of the zygomatic process. (See

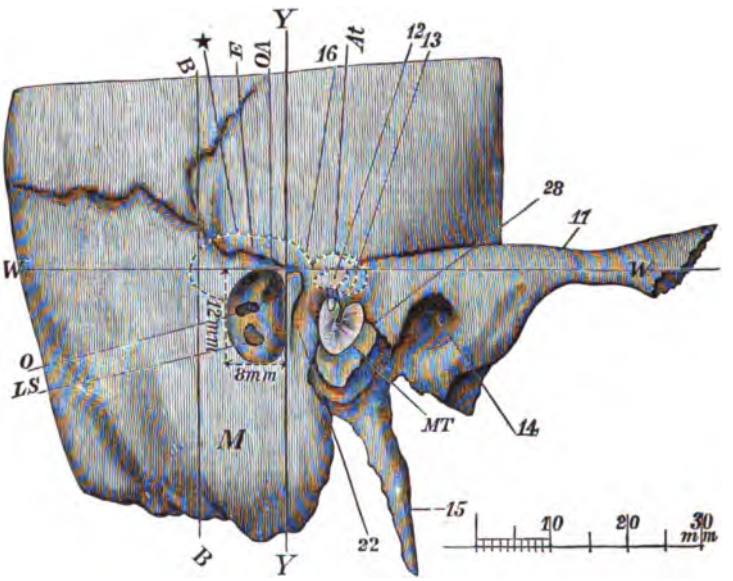

FIG. 2.—SIDE-VIEW OF TEMPORAL BONE. (C. R. HOLMES.)

W W and *Y Y*, lines indicating the horizontal and perpendicular planes of the skull; *O*, opening in mastoid leading to antrum; *OA*, opening into antrum; *LS* shows where lateral sinus is generally encountered if displaced far forward; *M*, mastoid process; *22*, wedge formed by posterior wall of external meatus and opening in mastoid; *15*, styloid process; *MT*, membrana tympani; *14*, glenoid cavity; *28*, Glaserian fissure; *17*, zygomatic process; *12* and *13*, outlines showing position of hammer and anvil and location of attic; *16*, spina supra meatum; *, dotted lines showing position of antrum, varying much in different subjects; *E*, linea temporalis.

Archives of Otology.

Fig. 2, *17*.) "This line, in about 80 per cent. of cases, lies lower than the middle cerebral fossa, and in the remainder either on a level with it or higher; for which reason we must never carry our operation above this line." The second landmark is the *spina supra meatum*. (See Fig. 2, *16*).

If neither landmark is apparent, perpendicular and horizontal lines (see Fig. 2, *Y Y*), touching the posterior margins of the *spina* and external meatus, are crossed by *W W*, Fig. 2, touching the upper margin of the meatus and corresponding

to the lower edge of the *linea temporalis*. The junction of these two lines indicates our starting-point.

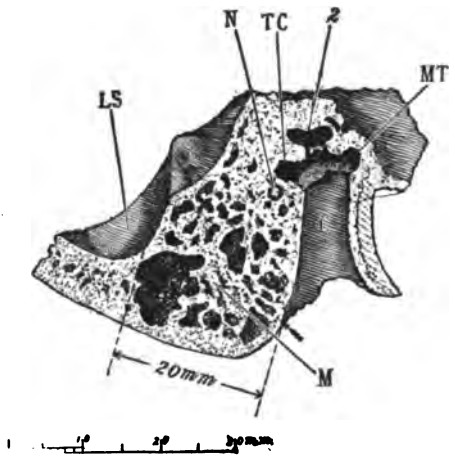

FIG. 3.—HORIZONTAL SECTION THROUGH RIGHT TEMPORAL BONE, SHOWING DISTANCE BETWEEN LATERAL SINUS AND EXTERNAL CANAL. CUT BEGINS BELOW CENTRE OF EXTERNAL CANAL, PASSING OBLIQUELY UPWARD AND INWARD. (C. R. HOLMES.)

LS, lateral sinus; *M*, mastoid; *N*, facial nerve; *TC*, tympanic cavity; *2*, vestibule; *MT*, membrana tympani; *C*, external canal; small arrow indicates the point where a perpendicular line from the spina supra meatum would touch.

Archives of Otology.

Fig. 2, *C*, indicates the base of a cone, 12 millimetres by 8 millimetres, whose apex lies in the antrum. This cone is exca-

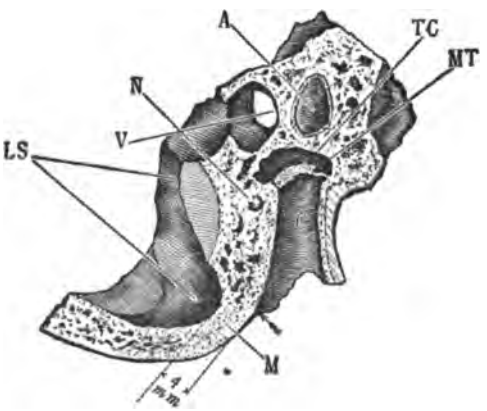

FIG. 4.—HORIZONTAL SECTION THROUGH RIGHT TEMPORAL BONE, CUT NEAR CENTRE OF EXTERNAL MEATUS, SHOWING HOW CLOSE LATERAL SINUS MAY COME TO EXTERNAL CANAL IN SOME CASES. (C. R. HOLMES.)

A, internal carotid artery; *V*, internal jugular vein. For explanation of other letters, see Fig. 3.

Archives of Otology.

vated by means of chisels of various sizes, beginning with the largest ones, working inward and slightly forward, almost parallel

with the posterior wall of the meatus, leaving a partition-wall (bridge) of bone between our excavation and the external auditory canal. This partition-wall should measure, at the meatus, 1 millimetre; near the membrana tympani, 4 millimetres. To avoid wounding the dura and lateral sinus, give to the upper surface of the excavation a slightly-downward inclination; to the lower and posterior surfaces, a decided forward and upward slant. Fig. 2, *LS*, shows where the lateral sinus *is usually found*, but Figs. 3 and 4 indicate what wide variations in its location may exist.

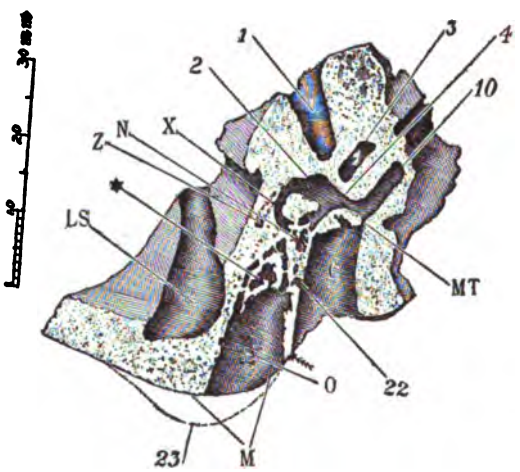

FIG. 5.—HORIZONTAL SECTION THROUGH RIGHT TEMPORAL BONE, CUT TWO MILLIMETRES ABOVE CENTRE OF EXTERNAL CANAL. (C. R. HOLMES.)

O, opening in the mastoid leading to the antrum: the heavily-dotted lines indicate the depth to which the opening penetrated in the upper section of this bone; small arrow indicates relative position of spina; *22*, wedge between opening in mastoid and external meatus; *M*, mastoid; *23*, dotted lines indicating how osteosclerosis may increase the depth to which it is necessary to penetrate; *C*, external canal; *, large cell in direct communication with the floor of antrum above; *LS*, lateral sinus; *Z*, posterior semicircular canal; *N*, facial nerve; *X*, horizontal semicircular canal; *2*, vestibule; *1*, internal canal; *3*, cochlea; *4*, fenestra ovalis; *10*, Eustachian canal; *MT*, membrana tympani.

Archives of Otology.

Here the chisel must be of large size, held obliquely, and only thin shavings of bone removed. After penetrating the cortex some of the cells leading to the mastoid process are generally opened. If diseased, such tissue is removed with chisels and sharp spoons. If normal, the work of excavating is continued, following the posterior wall of the auditory canal and using narrower chisels.

The depth at which the antrum is found varies greatly. (See Figs. 2 and 6.) After entering the pneumatic cells an olive-pointed probe should be frequently introduced to determine when

we have reached the antrum, always measuring, for the depth of the antrum, from the *spina supra meatum*. (See Fig. 2, *16*.) The varying distances to important structures are shown by Fig. 5.

From spina to facial nerve	15 mm.
From spina to horizontal semicircular canal	16 mm.
From spina to posterior semicircular canal	18 mm.
From spina to foot-plate of stapes	22 mm.
From spina to end of short process of incus	16 mm.

"It may be accepted, as a general rule, that the only safe guide to the extreme distance which we may penetrate is the distance

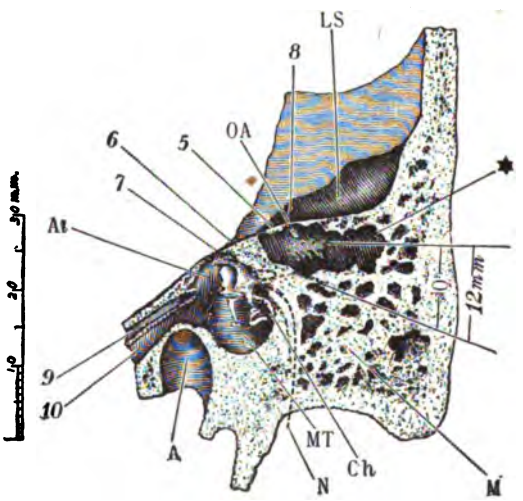

FIG. 6.—PERPENDICULAR SECTION THROUGH RIGHT TEMPORAL BONE. (C. R. HOLMES.)

The section begins at line. *BB*, behind opening, *O*, in mastoid (see Fig. 2), and is directed inward and forward, cutting Eustachian tube in its long axis. *N*, dotted lines show the course of facial and chorda tympani nerves; *M*, mastoid; *Ch*, chorda tympani nerve; *MT*, membrana tympani; *A*, canal for internal carotid; *10*, Eustachian tube; *9*, processus cochleariformis; *At*, attic; *7* and *8*, showing defects in the bone covering attic and antrum; *OA*, opening into antrum (see Fig. 2); *LS*, lateral sinus; *, antrum; *O*, lines indicating funnel-shaped opening (see *O*, Fig. 2).

Archives of Otology.

from the spina to the posterior superior margin of the drum-membrane, which, in health, fluctuates but little from fifteen millimetres."

Figs. 2 and 5, *22*, indicate the direction of the excavation and the thickness of the wedge of bone. The inclination of the floor upward is shown by the two lines in Fig. 6, at *O*, opening into the neck of the antrum and close to the extremity of the processus brevis of the incus.

"Having opened the antrum, we can, with a small probe bent at an obtuse angle of about seven millimetres from the point, enter

the attic, the probe generally passing over the short process and behind the body of the incus and head of the malleus (see Fig. 2, *12*, *13*) in the direction indicated by, but lower than, the head of the arrow. (See Fig. 6.) Leaving the probe *in situ* as guide, the wedge (see Figs. 2 and 5, *22*) is now cut away, using extreme care in removing the last portion. A large chisel is recommended. The incus is now exposed, disarticulated from the stapes by Schwartze's tenotome, and removed with forceps. The drum-head is detached from the annulus tympanicus with a membrane-knife and the malleus removed. The upper part of the osseous canal is

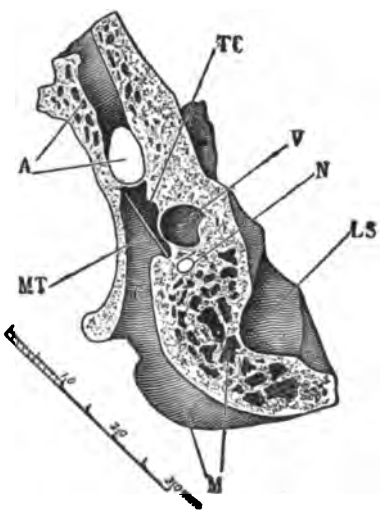

FIG. 7.—HORIZONTAL SECTION OF TEMPORAL BONE CUT NEAR FLOOR OF EXTERNAL MEATUS. (C. R. HOLMES.)

A, canal for internal carotid; *TC*, tympanic cavity; *MT*, membrana tympani; *V*, bulbus of internal jugular vein; *N*, facial nerve; *LS*, lateral sinus; *M*, mastoid.

Archives of Otology.

cut away, and the antrum, attic, tympanum, and external meatus are now united into one large cavity, all parts of which can be freely inspected, even to the entrance of the Eustachian tube. (See Fig. 6, *10*.)

All dead tissue and cholesteatoma found in any of the cavities are cleared away, using the greatest care when employing curettes in the tympanum, because of the paper-like thinness of the walls. (See Fig. 7.) For the same reason care must be observed in the attic. (See Figs. 6, 7, and 8.) Anteriorly we can readily wound the internal carotid. (See Fig. 4.) The parts must be left smooth.

Where the wedge was cut away (Figs. 2 and 5, *22*) there still remains a ridge between the external auditory canal (Fig. 5, *C*) and

FIG. 8.—APPEARANCE AFTER REMOVAL OF FIRST DRESSING IN CASES WHERE WOUND WAS CLOSED ENTIRELY AFTER OPERATION. (C. R. HOLMES.)

Irregularities along the line of union caused by suppuration and scar following a former mastoid operation (see Fig. 9).

Archives of Otology.

the antrum (Fig. 5, *), which increases in height as it approaches the middle ear. This can be removed safely up to within ten

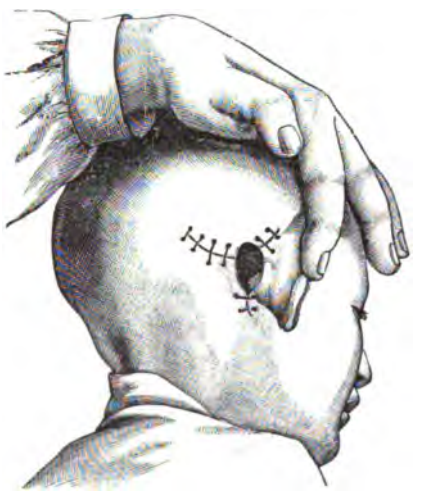

FIG. 9.—APPEARANCE AFTER REMOVAL OF FIRST DRESSING IN CASES WHERE WOUND IS LEFT OPEN AFTER OPERATION. (C. R. HOLMES.)

The white elevation on anterior lower margin of opening is a wad of cotton passed through external canal.

Archives of Otology.

millimetres of the annulus tympanicus, measured along the lower and posterior portion of the canal, until the ridge containing the

facial canal and horizontal semicircular canal is reached. Owing to great variations in the location of important parts in different individuals, the nearer the antrum is approached in chiseling the posterior wall of the canal, the greater must be the care observed. The cavities being now opened and cleaned, it is necessary to cover as much as possible of the denuded bone with flaps formed from the membranous portion of the auditory canal. This funnel-like process, attached to the auricle, is now split along its posterior superior wall in the direction of its long diameter (axis) up to the concha. Another incision is then made at right angles through one-half the diameter of the "funnel." The two flaps thus formed

FIG. 10.—APPEARANCE OF A CASE AFTER THE PARTS HAVE BEEN PERMITTED TO CLOSE. (C. R. HOLMES.)
Archives of Otology.

are turned back over the denuded bone, and are secured to the upper and lower margins of the wound with catgut sutures inserted into the edges of each flap. Thus healing is hastened, epithelium tends to cover the middle-ear cavity, and cicatricial contraction of the meatus is avoided.

Where disease involves the ossicles and mucous membrane only, the author closes the large primary incision with silk sutures. When it is determined to leave the wound open the cavity is packed with iodoform gauze through the external canal as well as through the artificial posterior opening. (See Fig. 9.)

The external dressings are then applied and the patient is

kept quiet, and dressings are unchanged for three days. The opening back of the ear is allowed to close between the fourth and sixth week, when the appearance generally is well illustrated by Fig. 10. The closure is delayed if there has been extensive loss of bone from caries.

Holmes reports twelve operations, in full detail, all undertaken in severe cases of long-existing otorrhœa, with (except in a few instances) extensive caries of bone and cholesteatoma. Indeed, the majority of these cases were of such a severe type that a fatal termination could have been prognosed for most of them. The operation was completely successful in all the cases,—five of the patients still in the stage of convalescence at the time of writing. The shortest time for the parts to heal was six weeks; the longest, four months. *The hearing was improved in all cases.* Eight times, or in 66 per cent., the malleus, and six times, or 49 per cent., the incus, were affected. In 33 per cent. both these ossicles were affected or entirely destroyed, and in 16 per cent. both ossicles were normal. Cholesteatoma was found in 25 per cent., and in one case there was also present an extra-dural abscess. There were no accidents of any kind during or following the operations. With but one exception there has been no recurrence up to date; so that, of those discharged, 85.8 per cent. remained free from any evidence of the disease for which the operation was undertaken.

[No one can gainsay that these results far exceed anything to be hoped for from the older mastoid operation performed upon twelve similar cases. Stacke's operation and the modification of it described by Holmes are comparatively little used, as yet, in this country. Only in city hospitals blessed with very progressive aural surgeons can our readers have the opportunity of seeing this most rational operation. It is a well-recognized procedure in Europe, and we trust that our outline of Holmes's paper may explain its details, so as to be of practical value to many readers who cannot see the operation demonstrated clinically.—Eds.]

Allen, of Cincinnati, $_{\text{Jan.,Apr.,'94}}^{66}$ writes a rather severe criticism of Holmes's paper on the Stacke operation, with the anatomical part of which he finds fault, claiming that the sections are not truly horizontal, but have been cut in a different position from that which the temporal bone assumes when held in true horizontal

and vertical planes. The editors feel, however, that readers can safely rely upon the measurements as given by Holmes.

McBride, of Edinburgh, [36] Apr., '94 in a paper on the "Diagnosis and Prophylaxis of Intra-cranial Complications from Ear Disease," speaks most favorably of Stacke's method of opening the antrum. He claims that the diagnosis of cerebral involvement is most difficult and uncertain, and that the same is true of the differential diagnosis between thrombosis of the lateral sinus, meningitis, and cerebral abscess.

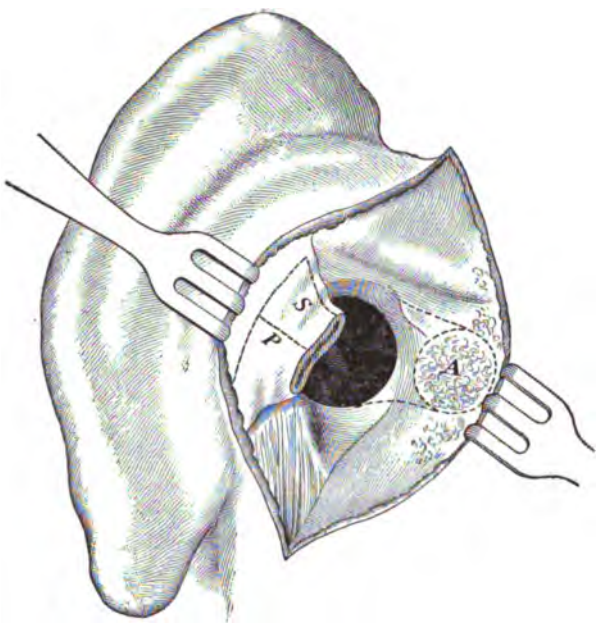

FIG. 1.—THE DETACHMENT OF THE AURICLE AND SHELLING OUT OF THE MEMBRANOUS MEATUS. (VULPIUS.)

The dotted lines on the latter mark the cuts by which one (*S* = Stacke) or two (*P* = Panse) transplantation flaps are formed. The vertical cut is the same for both. The dotted lines behind the meatus circumscribe (*A*) the region for the typical mastoid operation and for the resection of the posterior wall of the meatus.

Medical Record.

Vulpius, of New York, [59] June 16, '94 contributes a very clear statement of Stacke's radical operation for obstinate chronic otorrhœa.

Fig. 1 illustrates the incisions for detachment of auricle, the area for opening into the mastoid cells,—when necessary,—and the formation of the transplantation flaps (Stacke's and Panse's). The auricle being thus detached, the further procedures of Stacke were, originally, to pass his curved protector into the attic and to chisel off with a bent gouge that part of the upper wall of the osseous

canal which prevents a free inspection of the attic and the tegmen tympani from the outer meatus. The carious ossicles—or what was left of them—were then removed and a curved probe passed backward through the aditus or neck of antrum, to make out, if

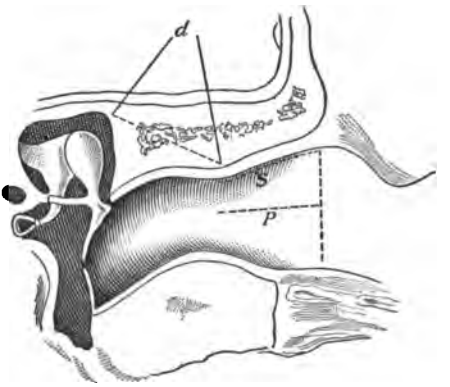

FIG. 2.—POSTERIOR HALF OF A FRONTAL SECTION THROUGH THE AUDITORY CANAL AND DRUM-CAVITY OF A LEFT EAR. (VULPIUS.)

Dotted line, *d*, shows what has to be chiseled off to make the attic and tegmen tympani accessible from the outer meatus. *S* and *P* signify the same as in Fig. 1.

Medical Record.

possible, whether this cavity was diseased, and, if so found, to serve as a guide for chiseling it open through the posterior wall of the osseous canal (Fig. 1). Experience has shown that the carious

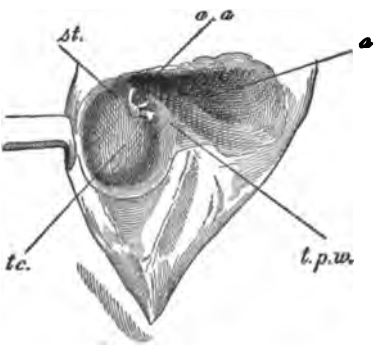

FIG. 3.—DRUM-CAVITY WITH STAPES (*st.*) IN RELATION TO THE OPERATIVE CAVITY. (VULPIUS.)

tc., tympanic cavity; *a a*, aditus ad antrum; *a*, antrum; *t.p.w.*, rest of posterior wall of meatus.

Medical Record.

and necrotic processes are seldom limited to so confined an area. It has, therefore, been found more convenient first to open the antrum after the typical method, to pass a probe forward into the drum-cavity, and to remove the big wedge-shaped piece of bone,

which forms, with its anterior side, the posterior wall of the meatus, laterally the border between the meatus and the wide mouth of the funnel-shaped operative cavity, and, with its narrow medial portion, the lateral wall of the aditus ad antrum.

Fig. 2 illustrates the bone to be removed in Stacke's original

FIG. 1. FIG. 2. FIG. 3. FIG. 4. FIG. 5.

INSTRUMENTS USED IN STACKE'S OPERATION. (VULPIUS.)

Medical Record.

operation; Fig. 3, the relation between the drum-cavity and the excavation.

We append a series of cuts illustrating the instruments used in Stacke's operation. The set is made after Vulpius's suggestions. Fig. 1, scalpel for primary mastoid incision; Figs. 2 and

3, a short, strong periosteum levator for denuding mastoid cortex and a double-pointed, slender one for peeling off the cutaneous coating of the meatus; Fig. 4, two small, angular knives for cutting the membranous canal transversely, for the right and left side respectively, devised by Vulpius; Figs. 5 and 6, a pair of sharp-pronged retractors, and a blunt one with a rounded hook on one end and a slender, rectangular arm on the other. The latter

FIG. 6. FIG. 7. FIG. 8. FIG. 9. FIG. 10.

INSTRUMENTS USED IN STACKE'S OPERATION. (VULPIUS.)

Medical Record.

serves to press the posterior wall of the membranous canal against the anterior one, if Panse's method (cases with wide meatus) is followed. Figs. 7 and 8, four straight and one curved gouges; Fig. 9, an osteotome-chisel for the excision of the posterior wall of the meatus; Fig. 10, a modification of Stacke's "protector"; Figs. 11 and 12, probes; Figs. 13 and 14, an angular dressing-forceps and a stronger one (Urbantschitsch's) for the removal of ossicles and semi-detached splinters of bone; Fig. 15, a double

curette for the final clearing of the operating-cavity from granulations, caseous matter, etc.

Notes on Cases of Necrosis.—Kirchner, of Würtzburg, $^{11}_{May,'94}$ reports a case of complete necrosis of the mastoid. During the course of an operation for opening the mastoid cells the entire mastoid process, together with a part of the squamous portion of the temporal bone, was removed in the form of a large sequestrum.

FIG. 11. FIG. 12. FIG. 13. FIG. 14. FIG. 15.

INSTRUMENTS USED IN STACKE'S OPERATION. (VULPIUS.)
Medical Record.

No loss of hearing nor injury to the drum-head attended or followed this loss of tissue. Kirchner reports also a case of necrosis of the cochlea in which hearing for the tuning-fork remained. He tries to account for this fact (retention of a degree of hearing) on the ground that a certain amount of the terminal apparatus of the auditory nerve may have remained intact; or this perception of sound may have taken place through the stem of the auditory nerve; or, again, that a certain amount of perception of sound

was possible through the nerve-apparatus in the vestibule and ampullæ.

Barck, of St. Louis, [61 Nov.18,'93] relates a case of carious destruction of the entire pyramid of the temporal bone. The accompanying illustrations show the extent of this carious process.

Lubet-Barbon, of Paris, [286 Oct.'93] narrates the particulars of a severe case of suppurative otitis media with caries of the internal walls

FIG. 1.

FIG. 2.

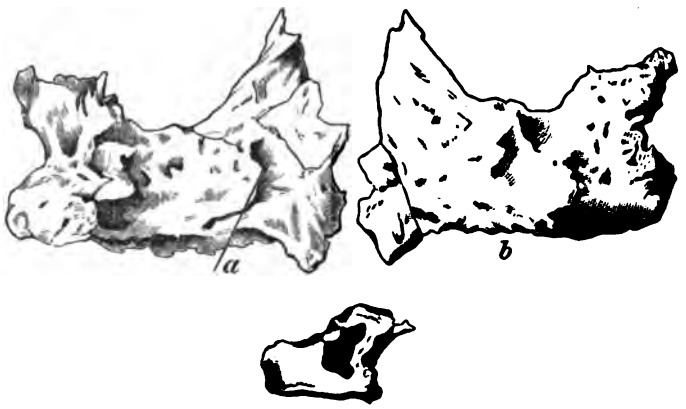

FIG. 3.

CARIOUS DESTRUCTION OF THE ENTIRE PYRAMID. (BARCK.)

a, vestibule; *b*, from other side.

Journal of the American Medical Association.

of the tympanum and facial paralysis. Stacke's operation was resorted to, but the patient died. The cut on next page illustrates the gravity of the lesions, and shows the direct communication formed between the tympanum and the cranial cavity.

Gosse, of London, [6 Apr.28,'94] refers to an unusual case of mastoiditis following otorrhœa, in which a deep cervical abscess formed, extending backward over the occipital region. The mastoid antrum was opened by trephine and chisel. About one drachm (four

grammes) of bad-smelling pus was liberated. Later, it became necessary to open into the enormous, brawny swelling over the neck. Deep fluctuation was found between the mastoid process and the occipital spine. This region was opened by an incision just above and to the left of the *atlas*. Here the occipital bone was denuded. There was profuse suppuration, but the patient recovered. The author believes that perforation of the mastoid portion of the temporal bone took place through the digastric fossa, the pus being conducted backward by the occipital artery, the patient being on his back.

"Purulent Otitis Media leading to Caries of the Temporal

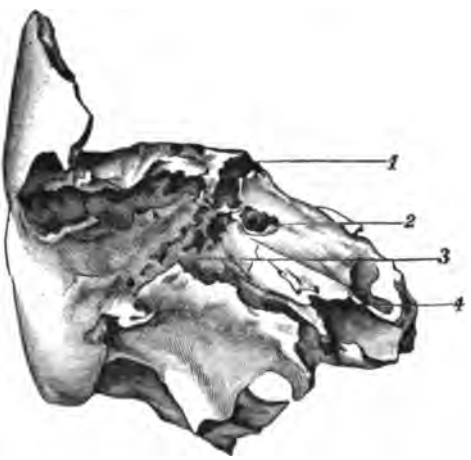

SUPPURATIVE OTITIS MEDIA. (LUBET-BARBON.)

1. Transverse semicircular canal. 2. Wall of labyrinth destroyed. 3. Promontory. 4. Eustachian canal.

Archives International de Laryngologie, de Rhinologie, et d'Otologie.

Bone, Epimeningeal Abscess, and Death, while the Mastoid Process Remained Intact" is the title of a paper by Reüling, $^{66}_{\text{Jan.,Apr.,'94}}$ of Baltimore, describing a case occurring in his practice. The accompanying plate illustrates the temporal bone. The post-mortem findings are thus described:—

"After opening the skull a high state of hyperæmia was seen, occupying the whole right side of the brain, and, on lifting the right temporal lobe, about two tablespoonfuls of bloody pus were found in the fossa temporalis and along the pyramid of the os petrosum. The inner wall of the squama ossis temporalis was perforated by many small fissures, which, on the slightest pressure

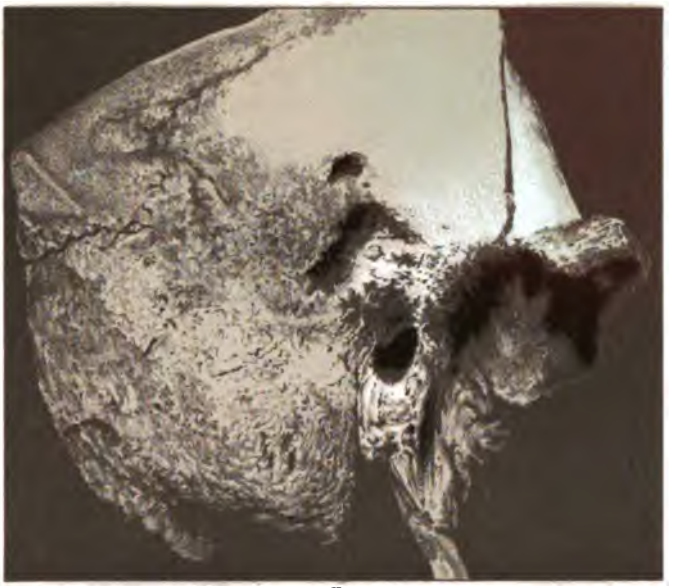

Fig. 1.

Fig. 2.

Purulent Otitis Media Leading to Caries of the Temporal bone. Epimeningeal abscess, and death while the mastoid process remained intact. (Reuling)

Archives of Otology.

Burk & McFetridge Co. Lith. Phila.

made by the finger, would break down and leave, finally, in the macerated os temporum an irregular, rough-edged hole of six lines long and five lines broad, communicating through the thickness of the squama with an opening of about the same dimensions and situated directly over the upper wall of the meatus auditorius externus. There was also a pus-cavity extending almost an inch horizontally between the diploë of the squama toward the processus mastoideus, ending blindly without entering its cells, evidently owing to the fact that the mastoid in this case was of dense texture and not of the large alveolar variety. Along the upper ridge of the pyramid were extensive carious destructions, extending along the whole margin."

Ligation of the Jugular.—This procedure has been undertaken in several instances in which thrombosis of the lateral sinus was diagnosed and an operation resorted to for removal of the clot.

A. Af. Forselles, of Helsingfors, [336 No.3,'94; 2 Mar.2,'94] states that thrombosis of the lateral sinus, even when uncomplicated, is not always characterized by the formulated series of symptoms. The fact that of six cases in which the author operated three were fatal shows that surgical interference, though alone capable of doing good, is not always very promising. Trephining of the mastoid antrum and cells is regarded as useful only as a prophylactic measure and as a means of removing infective material. In well-established thrombosis the author would advocate opening of the sinus and removal of its contents, and, at the same time, ligature of the internal jugular vein. The position of the knee or anterior curvature of the sigmoid sinus may be marked on the surface of the skull by a point nine centimetres in front of the inion, in a line drawn from this protuberance to the upper margin of the orbit. The author would trephine at this point in those cases—which, however, must be very rare—in which it is not found necessary to explore the mastoid process. It would very rarely, if ever, be necessary to trephine here, inasmuch as, when the mastoid antrum has been exposed, the sinus can be readily laid bare by extending the original opening in the bone. In operating for sigmoid thrombosis the author prefers the trephine and bone-forceps to other instruments, with the use of which there is less risk of concussion at the seat of operation and of separation of the

clot. The expediency of securing the internal jugular vein by ligature is proved by his statistics. In 13 cases in which the vein had not been tied the mortality was 40 and the recoveries 53.8 per cent.; in 16 cases in which this part of the operation had been carried out the mortality was 37.5 and the recoveries 62.5 per cent. Körner $\frac{336}{\text{No.3,'94}}$ also advocates surgical intervention in cases of sigmoid phlebitis as soon as the diagnosis has been made. This author has collected 20 cases of operation; of these, 13 were successful,—4 out of 8 in which the jugular vein had not, and 9 out of 12 in which it had, been tied. In only 4 of these cases had the vein been secured before the exposure and clearing out of the sinuses; in all of these the patients recovered.

Grunert $\frac{328}{\text{B.36,H.1}}$; $\frac{336}{\text{Mar.3,'94}}$ reports, also, a case of jugular ligation, after which both the peripheral end of this vein and the transverse sinus were cleansed by injection. The patient was a girl 10 years of age. Otitis of the right side developed after an operation for removal of "adenoid vegetations." Five days later the left mastoid showed evidence of inflammation. Opening of the antrum liberated pus. It became apparent later that pus was retained in the cranial cavity, and the transverse sinus was laid open by operation and found to be infiltrated with inflammatory products. The jugular was tied and vein and sinus washed out by injections of salt solution. The case was relieved from all pyæmic symptoms and progressed to complete recovery.

Reinhardt $\frac{11}{\text{May,'94}}$ employs Schwartze's method for laying open the middle ear, antrum, and mastoid in cases of cholesteatoma. In sixty cases in which the antrum was opened he found cholesteatoma nineteen times; and, of these, he treated fifteen by the persistent retro-auricular opening. In cases where the operation-wound closed again a new formation and disintegration of skin set in. Where the opening was retained,—in cases watched for three years,—this complication never occurred. He maintains this opening (1) by the introduction of flaps of skin from the skin of the patient's head; (2) by transplantation from animals, in suitable cases; (3) by taking flaps from the posterior surface of the concha. He prefers this latter method when he knows definitely before the operation that cholesteatoma is present. Out of the nineteen cases operated upon fifteen had a persistent opening, and in them there was no recurrence.

General Notes on Mastoiditis.—Cozzolino [11, June, '94] has drawn some interesting conclusions, derived from a study of one hundred and twenty cases of mastoiditis, observed and treated at the Clinical Hospital of Naples, from 1883 up to February, 1894. The author divides his cases into three classes: (1) endomastoiditis, treated by perforation of the mastoid or by the enlargement of osteo-cutaneous fistulæ; (2) the same, treated by Wilde's incision and antisepsis of the auricular cavities; (3) the same, treated by antisepsis of the auditory meatus, the tympanum, the mastoid antrum, etc.

The cases of suppuration of the middle ear treated during this period were 2010; of mastoiditis, 120 (6 per cent.). As regards the mortality in cases of mastoiditis, in the first class there were 80 cases and 9 deaths (11.2 per cent.); second class, 30 cases; third class, 10 cases. Observation shows that, for the extension of the suppurative process from the attic to the antrum and to the mastoid cells, it is necessary that conditions exist favoring the blocking of pus. This may result from inflammatory engorgement of the cutaneous and osseous layers of the meatus in subacute suppurative otitis media, and of simple or polypoid granulations; or of multiple polypi, or necrosis, in the chronic form. The results of this "blocking" and the development of pyogenic micro-organisms are most pronounced in scrofulous and tuberculous individuals. The nine cases of death occurred in instances where the process had extended into the intercranial region. Thus was produced septic thrombo-phlebitis and abscess of the intercerebral lobe. In cases of mastoiditis resulting from influenza the pneumococcus was found in addition to the staphylococcus usually present. In chronic forms the latter and the streptococcus were the only microbes of importance. In treatment the author has obtained his best results from microcidin, as an antiseptic and antipyogenic. He uses it in 5- or 6-per-cent. solutions. Chloride of iodine has also given good results as an antiseptic in chronic forms with granulations. In the eighty cases of Class 1, perforation or trepanning of the mastoid, through an intact external osseous wall, was practiced twenty times, with two deaths. Two patients suffering from intra-mastoid cholesteatoma were both cured,—the one by the method of Küster; the other, by the old method of perforation of the mastoid antrum.

As results of mastoiditis there were observed, in addition to necrosis and caries, hyperosteitis or condensing osteitis of the external portion and rarefying osteitis of the walls. These results of mastoiditis were found in the eighty cases of the first category in the following relations:—

Caries of the external wall,	71
Caries of the anterior wall,	2
Caries of the anterior cranial surface (Bezold's),	4
Caries of the anterior cranial wall corresponding to the sigmoid groove for the lateral sinus,	3
	80
Hyperostoses,	0
Rarefying osteitis or atrophy of the walls (criticised in the case of cholesteatoma of the mastoid antrum, and in accumulations of pus dating from several years),	0
Cholesteatoma,	0
Disease of the petrous bone,	0
Caries of the osseous cushion of the Fallopian canal,	0
Partial extrusion of the cochlea,	0
Caries of the carotid canal,	0

B. Alexander Randall, of Philadelphia, [66 July, '94] has made a careful investigation to determine whether important topographical relations of the temporal bone can be determined from the form of the skull. The question is answered in part by five hundred skull-measurements. It is intended to carry out the measurements upon a series of one thousand skulls. Fig. 1 will show the author's scheme of measurements, Figs. 2 and 3 the instruments employed. (See pages C–43 to C–45.) We can only give a few of the practical lessons to be drawn from this most important, thoroughly-scientific, but as yet uncompleted study:—

"Safe or dangerous relations with maximum or minimum dimensions of the intervening structures may be found on either side and in any type of skull. The surgeon must conduct his operation as though he were sure that the lateral sinus or the middle cerebral fossa lay in his path so nearly that only the utmost care would avoid opening them unintentionally. The drill and trephine must be henceforth regarded as distinctly less safe than the chisel. The upper posterior border of the auditory meatus, with its *spina*, constitutes the most reliable guide to the point of entry; and the tract made by chiseling, beginning slightly behind the *spina*, should be carried inward, forward, and slightly upward, and the antrum should be found at a depth of less than twenty

millimetres. Deeper penetration is rarely safe, although my measurements would indicate that the facial canal and the external semicircular canal lie never less than sixteen millimetres from a point five millimetres behind the *spina*."

Moos, of Heidelberg, $^{66}_{July,'94}$ discusses "an hitherto undescribed course of a disease of the mastoid process." The chief rôle in this condition is played by the mastoid fissure, which forms upon

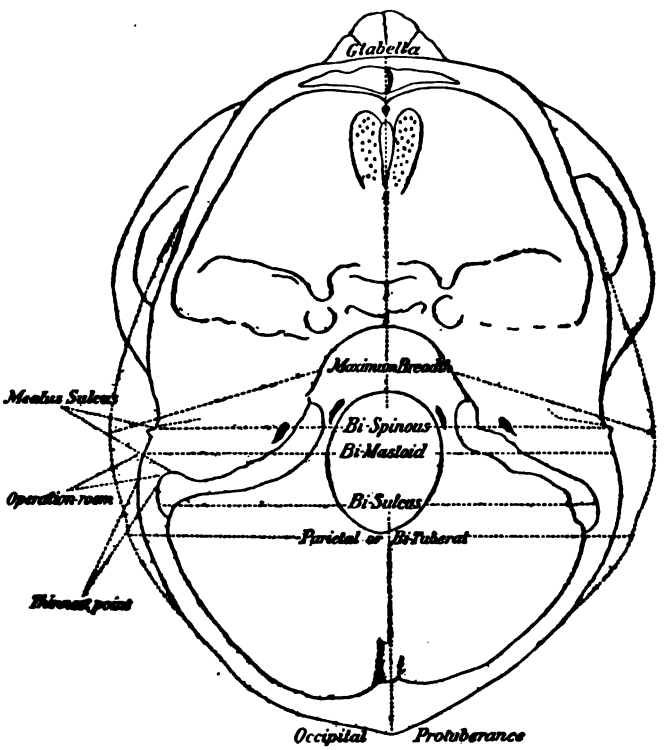

FIG. 1.—SCHEME SHOWING THE MOST IMPORTANT DIMENSIONS OF A SKULL IN THE WRITER'S COLLECTION. (RANDALL.)

Archives of Otology.

the exterior of the mastoid process the continuation of the petro-squamous suture. The condition is rare. The abscess over the mastoid process, in such cases, is characterized by frequent recurrence. A case described exhibited this tendency, together with pharyngeal catarrh and a painless course. The pus-enlargement lay at the lowermost end of the apophysis and a little to the middle line, but the greater part of the apophysis was free from swelling.

Appended to the article is a description of the results of examination of fissures, pseudofissures, and crack-like bony cavities in the collection of skulls in the Anatomical Institute at Heidelberg: Total number of skulls, 239, of which 29 were from children. Three various types of particular formation of fissures on the mastoid process:—

1. Type of the true fissure in the anatomical sense, beginning at the incisura parietalis squamosa of the temporal bone, runs on

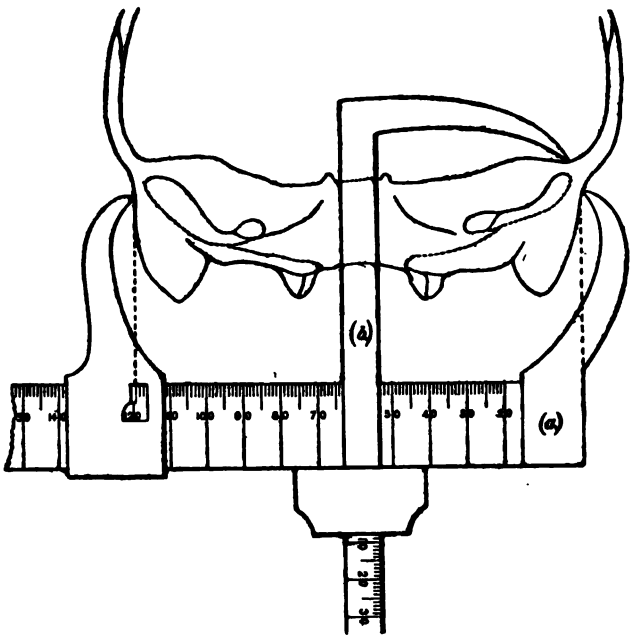

FIG. 2.—SCHEME OF THE INSTRUMENT EMPLOYED TO LOCATE THE LOWEST PORTION OF THE FLOOR OF THE MIDDLE CEREBRAL FOSSA AND MEASURE ITS RELATION TO THE SPINA SUPRA MEATUM. (RANDALL.)

Archives of Otology.

the mastoid process to its tip, and then bends forward and upward toward the external auditory meatus. The linea semicircularis occipitalis superior runs separate behind the mastoid fissure to the point of insertion of the sterno-cleido-mastoid muscle.

2. Total absence of the fissure. Well-marked tuberosities on the mastoid, a small emissary high up, a little higher still than the spina supra meatum. The linea semicircularis occipitalis superior does not extend to the mastoid process. The chief emissary lies in the occipital bone.

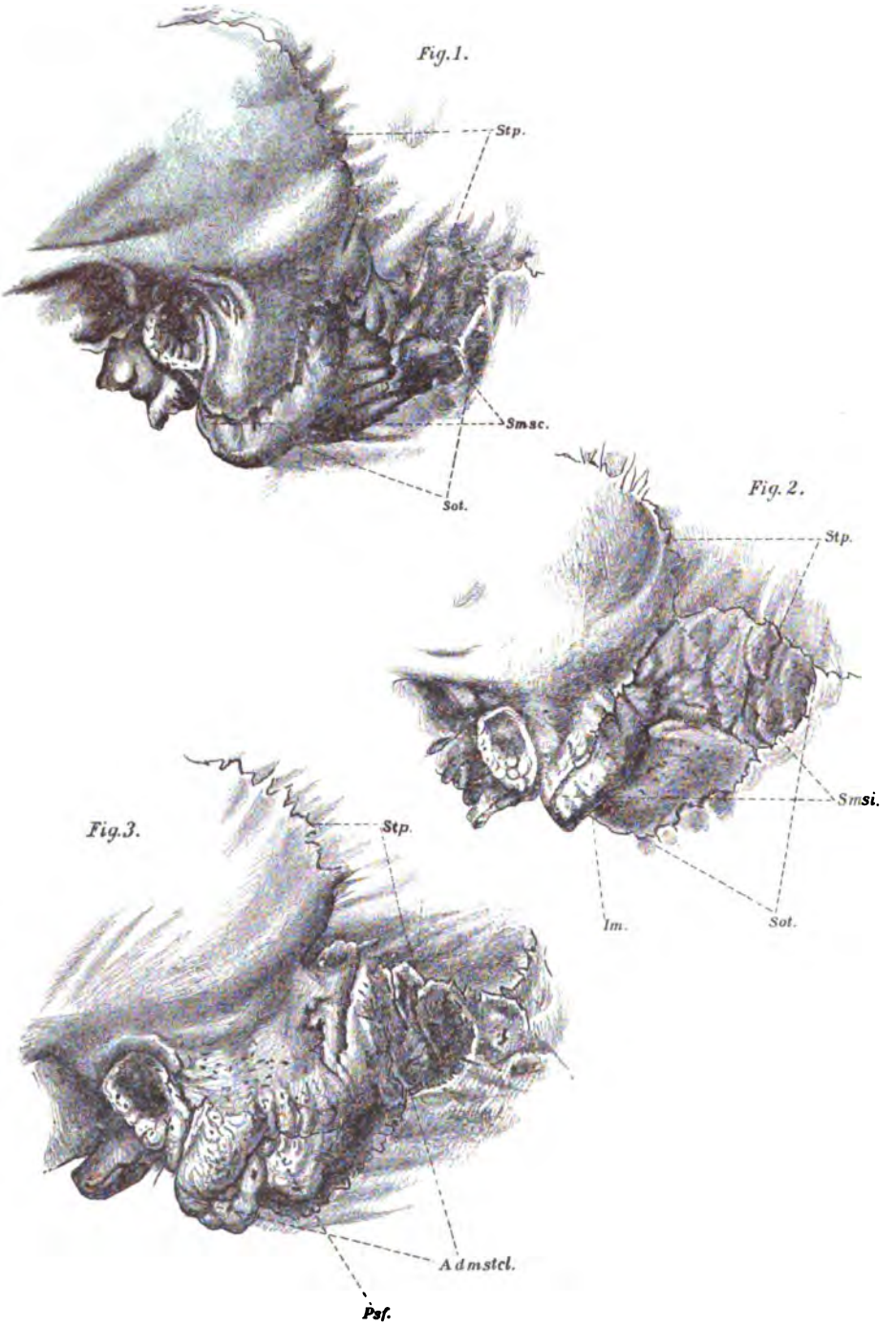

An Hitherto Undescribed Course of a Disease of the Mastoid Process (Moos).

Archives of Otology.

3. Type of the pseudofissure formation: (*a*) The linea semicircularis occipitalis superior extends into the exceedingly well-marked tuberosity, the zigzag, projecting edges of which simulate a fissure. The emissary is at the upper beginning of the pseudofissure. (*b*) Type of the pseudofissure which is so highly developed that there is a deep slit, probably caused by the abundant holes in the vessels. In this the upper portion of the tuberosity exhibits no fissure at all.

The summary of results of the above examinations follows: Two hundred and thirty-nine skulls in all exhibit some sort of a fissure of the three above types 54 times; that is to say, about 22

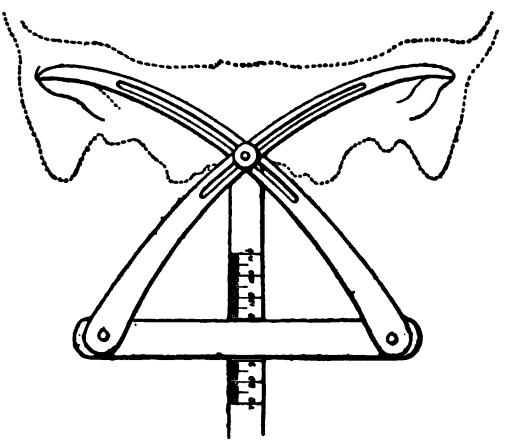

FIG. 3.—INSIDE CALIPERS EMPLOYED TO MEASURE THE MAXIMUM DISTANCE BETWEEN THE SIGMOID SULCI. (RANDALL.)

Archives of Otology.

per cent. Perfect fissures in 24 skulls,—11 times double, 4 times on the right side alone, and 9 times on the left alone.

According to Kirchner and Kiesselbach, the fissure remains as a complete suture in the first year of life only. Kirchner found this closed in 77 per cent. of adult skulls, in a collection of 300. Fifteen were double and 17 unilateral; that is, in 5 per cent. closed on both sides and in 5 per cent. unilaterally closed, of which but 4 were on the right perfectly closed. Bezold found the fissure persistent but 4 times in 200 skulls, and in 122 suggested by holes and crevices on the external surface.

Explanation of Plate.—These are all natural size. Fig. 1: *Stp*, sutura temporo-parietalis; *Smsc*, sutura mastoidea-squamosa completa; *Sot*, sutura occipito-temporalis. Fig. 2: *Stp*, as before; *Sot*, as before: *Smsi*, sutura mastoidea squamosa

incompleta; *Im*, incisura mastoidea. Fig. 3: *Stp*, as before; *Admstcl*, insertion of the sterno-cleido-mastoid muscle; *Psf*, pseudofissure, which at a glance is hardly to be distinguished from the true fissure, but which in its totality is impermeable even for the passage of a fine thread.

Points in Diagnosis.—Percussion of the mastoid process is discussed by Koener and von Wild, of Frankfort-on-the-Main,[66 Jan.,Apr.,'94] who have given much attention to this method of diagnosis. Where external symptoms are absent, and where there is but slight pain and a continued normal temperature, the positive establishment of bone disease is often difficult or impossible. In this respect the method of bone-percussion rendered in two cases surprisingly good service. The air present in the mastoid cells has no effect on the resonance, the percussion-sound depending much more on the resonance of the healthy or diseased bone-substance itself. We seek to draw conclusions as to the condition of the bone from the resonance produced by forcible blows of a hammer the striking-surface of which is eight millimetres broad and slightly convex. The examination must always be comparative between the two sides of the patient's head. The handle of the hammer is made of a thin, tapering piece of whalebone, and is sixteen centimetres in length.

The area to be percussed is (1) below the linea temporalis, as this line denotes approximately the upper border of the mastoid; (2) above the insertion of the tendon of the sterno-cleido-mastoid muscle, because this thickens the covering over the bone; (3) behind the border of the auricle (percussion is influenced if the auricle is drawn forward and the skin thus stretched); (4) in front of the insertion of the hair.

Comparative percussion allows of a conclusion as to the condition of the bone only when the soft parts are unaltered. A "one-sided perforation" or accumulation of pus within the tympanum has no effect upon the percussion-note.

In conclusion the authors sum up as follows the results of their observations and experiments: 1. By means of bone-percussion it is possible to recognize a central ostitis of the mastoid at a time when the disease does not betray itself by any external noticeable signs. 2. It is the disease of the bone itself, and not the obliteration of its air-spaces, that alters the resonance.

Moos, of Heidelberg,[66 Jan.,Apr.,'94] in an article upon the value of percussion of the mastoid process, is not so enthusiastic as the

last-named writers. He has tested the percussion method and has arrived at the opinion that only a *positive* result is conclusive, a *negative* result not being so,—that is to say, an affection of the mastoid, and, indeed, even a severe one, may exist without lessening the resonance.

Okunew [551 v.4,p.528] has reported a new method for diagnosing the deep affection of the mastoid in otitis media purulenta. A gutta-percha tube (seventy-five centimetres long) is supplied with a bony end-piece, which is placed in the auditory meatus of the examiner. The other end of the tube is supplied with a hard-rubber funnel, which is held against the bone to be examined. A tuning-fork is then set in motion and is placed on the temporal bone and the region of the mastoid process. The sound thence carried to the examiner's ear is compared with the tone heard at other points on the skull. When pus or a carious process is present there will be heard a dull, uncertain tone which is plainly to be distinguished from the tone heard over normal bone.

Clarke, of London, [6 v.2,p.75,'94] calls attention to what he considers a "landmark" of great value in making an opening into the antrum. This is a certain depression in the bone, behind and above the supra-meatal ridge. It is perforated by many vascular foramina. It owes its origin, probably, to the development of the antrum. In more than two hundred temporal bones of adults, and in many children, the author has observed that through this depression, in a direction inward, forward, and downward, there is an easy path to the interior of the antrum. "In many cases where disease is of old-standing and there is extensive necrosis, or where cholesteatomata are present in the tympanum, it is preferable to open up both the antrum and the tympanum by gouging away the whole of the posterior wall of the meatus, but in some cases it is, I believe, sufficient to open the antrum."

INNER EAR.

Ménière's Disease.—Mettler, of Chicago, [61 Oct.7,'98] has written a very suggestive paper on the subject of "Aural Vertigo (Ménière's Disease)." He finds that the mental phenomenon known as vertigo reveals, upon close study, a far more complicated nature than a mere disarrangement of the function of any one organ, such as the semicircular canals. The maintenance of balance

cannot be assigned to any single centre. Equilibrium is dependent upon a normal consciousness of the proper relationship of things outside of the centres of consciousness. It is not purely psychical. There is the sensation of a motor process in it. As to the part played by the ear in this complex phenomenon, it may be considered that only the semicircular canals are affected in *true* Ménière's disease. To this part Ménière himself restricted the lesions. Now Politzer and Lucæ both report instances in which the semicircular canals were absent or filled with blood, and yet the patients did not suffer from any disturbance of equilibrium. The author believes, from Gellé's experiments, as well as from the general symptoms presented, that the cochlea is in no way the source of vertiginous impressions. Hence, in Ménière's disease the lesion must concern the whole labyrinth or lie entirely outside of it. Aural vertigo, indeed, may not be aural at all, except only so far as having certain aural symptoms associated with the vertigo. We are not justified, he thinks, in view of the few physiological and pathological data still at hand, in assigning all cases of vertigo with loss of hearing to an unknown and undemonstrable lesion of the internal ear.

Mackenzie, of London, $^{2}_{\text{May 5, '94}}$ implies that there is a constant tendency among physicians to confuse the subject by classifying cases of vertigo caused by middle- and inner- ear disease with cases in which vertigo results from arterial changes or from nerve influence affected by errors in the digestive tract. He lays out a plan for the management of acute attacks and for the interparoxysmal periods. For the acute attack, efforts should be made to subdue the excitability of the nerve-centres. Rest in the recumbent position, with bromide of potassium internally, in 10- to 20-grain (0.65 to 1.3 grammes) doses, three times daily. Where a gouty diathesis is evident, antirheumatic treatment, preceded by a mercurial purge, is indicated. Counter-irritation by a small blister behind the ear is also of service, and the local conditions of the ear requiring treatment must be attended to. During the periods between attacks great attention must be paid to the derangement of function in the various organs. The diet must be regulated and the patient's life ordered for the best. The author, following Charcot, has found quinine, in 3- or 4-grain (0.2 or 0.26 gramme) doses, three times daily, of considerable service. This dose can

be much increased or even doubled. Salicylate of sodium is sometimes useful in warding off attacks. Great care must be observed in preventing a tendency to increase of arterial tension, as indicated by the pulse. This is especially to be observed, as the great majority of cases occur in the latter half, or degenerative period, of life, when the kidneys tend to become granular, the arterial tension to be increased, and cardio-vascular changes to occur. For these conditions the author finds mercury, in some form, the most valuable drug. Blue-pill can be given once or twice weekly, and calomel, in 3- to 5-grain (0.2 to 0.32 gramme) doses, can be within the patient's reach, to be taken when any premonitory symptoms are developed, such as increased tinnitus, fullness in the head, or headache.

A report is made by Simon, of Baltimore, 764 Sept.,'94 upon two cases illustrative of the influence of heredity in Ménière's disease,—a point upon which he has failed to find any reference to this subject in medical literature. His two cases presented all the phases of Ménière's disease, while the parents and other members of the family suffered either from similar symptoms or from nervous manifestations. In the first case treatment consisted in moderate doses of ammonium bromide and nux vomica, together with a pure meat diet. After two weeks the diet was made slightly more liberal,—zweibach, stale bread, potatoes, wine-jelly, baked apples, prunes, and a moderate amount of fresh butter. For six months this patient had been free from attacks. In the second case nux vomica was used, in from 10- to 25-drop doses, thrice daily. A degree of improvement, first noted, soon disappeared. Quinine was tried, after Charcot's method, but tended to increase the trouble. Nux vomica was then used again, together with ammonium bromide. The result was an improvement in symptoms, but attacks still occurred. The patient was then placed upon a diet similar to that used for the first case, and the galvanic current was applied daily to the head, beginning with 5 milliampères and increasing gradually to 15 milliampères. Under this treatment the patient improved steadily, and, at the time of writing, had had no recurrence of the old trouble.

Gradenigo, of Turin, 11 May,'94 finds the typical picture of Ménière's vertigo to be only a phase, in the diffusion to the labyrinth, of a chronic catarrhal affection of the middle ear. If this diffusion is

very slow, the symptoms of reaction on the part of the ampullary apparatus may be nearly or completely absent; if less slow, the symptoms at a given period of the morbid process, when the affection gains the ampullary apparatus, present a typical picture of attacks of vertigo with exacerbations; if still more rapid, the symptoms may be so severe as to produce a condition of continuous vertigo. Ménière's vertigo, then, may be met with in the most varied affections of the middle ear when these extend to the labyrinth, especially in the forms of otitis produced by trade occupation, by syphilis, and by tuberculosis. It does not deserve, therefore, to be regarded as a separate disease, but is simply a symptom common to advanced stages of many different morbid processes within the ear.

Traumatic Deafness.—A very interesting case is reported by Corning, of New York. $_{\text{Jan.20,'94}}^{1}$ As a result of a severe kick directly over the right ear, received during a game of foot-ball, the patient, a lad 18 years old, became totally deaf in the right ear. The drum-head of this ear was found to be in normal condition. Aërial and bone conduction were both lost completely. There was no evidence of fracture at base of skull. Corning was very uncertain regarding the etiology of this case and its diagnosis; but, as a means of treatment, he employed a rapidly-interrupted faradic current, which was allowed to pass through the ear for about ten minutes. The hearing was then so far restored that the patient could hear the watch at a distance of six inches. Tinnitus was also relieved. Hearing is now entirely restored. There was no suspicion of hysteria in the case. Webster, in discussing this report, stated that the deafness had been due probably to concussion either of the auditory nerve or of the labyrinth. Booth stated that he had employed the galvanic current with marked benefit in a number of cases of tinnitus aurium.

Cerebral Abscess.—Among the numerous reported cases of this condition which have appeared in otological literature during the year, Moure's, of Bordeaux, $_{\text{May,'94}}^{11}$ is of especial interest. He calls attention to the possibility of the existence of a large cerebral abscess consecutive to a median suppurative otitis, without any severe symptoms which would lead one to suspect the presence of this grave condition. Two cases are reported as illustrative of this deceptive condition, and the author lays stress upon the necessity

of making an exploratory opening into the mastoid process in all instances where loss of sleep results from crises of aural pain which are persistent, lancinating, fixed, and associated with otorrhœa. In the discussion upon this paper by Politzer, de Rossi, Grazzi, Moos, Gellé, and Cozzolino, similar cases were referred to where sudden death terminated a suppurative otitis media in which the more pronounced symptoms of cerebral abscess had been wanting. Cozzolino and Politzer cited the case of the celebrated archæologist, Schliemann, who had in no way realized the gravity of his condition, but had died suddenly, having been found lying half-paralyzed in a street in Naples. He had just placed himself under treatment for otorrhœa.

Tests Regarding Hearing.—A number of articles have appeared as a result of studies upon hearing, and among these an "Investigation with Tuning-Forks of Middle Register in Over Six Hundred Cases," by Alderton, of Brooklyn, N. Y., $^{66}_{July,'94}$ deserves careful reading. The author has not yet finished his valuable series of investigations. A paper on a phase of this subject, by Bezold, of Munich, $^{66}_{July,'94}$ entitled "Investigations Concerning the Average Hearing-Power of the Aged," is the result of most careful study. Among the important points to which reference is made are the following: "In the decades following that from the fiftieth to the sixtieth year there is not only a successive decrease in the number of those with nearly normal hearing, but there is also a successive increase in the degree of the deafness. With old people there is a marked difference (in the hearing-power) between the sexes. The number of men who perceived whispering at 1 metre to $\frac{1}{\infty}$ is relatively much larger than the number of women. The explanation is to be sought in the many hurtful influences of their (men's) noisy occupations, detonations, trauma, alcohol, nicotine, etc. These injurious influences, however, produce chiefly a moderate grade of deafness. The female sex, in old age, also shows itself to be less resistant; at least, toward those influences which cause a high grade of deafness. From the appearances of drum-heads examined it may be concluded that obstruction of the Eustachian tube, by which these anomalies of form are caused, is an affection especially of children.

"The different sequelæ of former inflammatory processes are found in a much greater number from the fiftieth year on. In age

the middle-ear affections are less frequent as compared to inner-ear troubles. In old age, bone-conduction, in itself, does not experience a reduction, but sinks proportionately with the lessening of the hearing-distance."

Related to this same subject is another paper by Zwaardemaker, of Utrecht, $^{66}_{July,'94}$ upon the "Presbykousic Law," the ideas of the writer being embodied in the following conclusions: 1. The compass of the human hearing contracts a half-octave at its upper limit up to the period of advanced old age. (Average, a fourth; maximum, one-fifth.) 2. During advanced age proper the contraction of the scale increases. 3. The upper limit is in youth at e^7; in advanced age, at a^6 (average values). As extreme, g^6 becomes the limit in normal-hearing old people. A lower limit may be taken as a sign of pathological conditions.

DEAF-MUTISM.

The two most important contributions to the study of this subject during the year are Robertson's (Newcastle-on-Tyne) article,—"Deaf-Mutism: An Examination of the Inmates of the Northern Counties Institution for the Deaf and Dumb," $^{6}_{Sept.2,'94}$ and the English translation of Holger Mygind's (Copenhagen) book on "Deaf-Mutism." In a concise and yet complete manner the latter gives a full exposition of this subject in all its details, embodying the results of his own careful investigations among the deaf-mutes of Denmark, with the work of all other students in this department of otological work. Robertson's paper goes over the ground which has been traversed by others already, but the field is fertile, and the author has condensed his findings into carefully-prepared tables, so that his facts are well exhibited. The observations were made upon the anterior and posterior nares and ears of 124 deaf-mutes. This number is not sufficiently large to render conclusions therefrom entirely certain; yet, taken in connection with similar work done in Glasgow by Kerr-Love, on 175 deaf-mutes, and by Bliss, of Philadelphia, on 512 deaf-mutes, the work is of great value. The examinations of the ear are most carefully made. The results of the work correspond quite nearly with those obtained by other observers, as may be judged from the author's statement regarding the frequency of catarrh and hyperplasia of the mucous membrane bordering on the ear. This

condition is, he finds, as frequent, perhaps, among deaf-mutes as among children at an aural clinic for the treatment of deafness. The number of congenital cases is strangely large, considering that the diagnosis between acquired and congenital deaf-mutism is an exceedingly uncertain process.

Bliss, of Philadelphia, in a series of lectures[2043/94] upon "Abnormalities of the Upper Respiratory Tract and Ear Found Commonly Among Deaf-Mutes," considers the training of deaf-mutes, basing his conclusions upon his examinations of five hundred and twelve pupils in the Pennsylvania Institution for the Deaf and Dumb. The examination embraced the entire upper respiratory tract and ears. The following are the conclusions arrived at:—

"1. We have evidence that abnormalities of the nares, naso-pharynx, and pharynx are found very commonly among deaf-mutes, and that such lesions tend to interfere, in varying degree, with the successful training of the deaf pupil in vocalization.

"2. Although in no way claiming that such mechanical causes are the only grounds for failure in acquiring speech, it is reasonable to believe that, in many instances, the presence of hypertrophied tonsils, masses of overgrown adenoid tissue in the naso-pharynx, deformities of the nasal septum, and hypertrophy of the turbinated bodies cause such obstruction to respiration and such interference with the movements of parts concerned in articulation, that the oral pupil becomes an 'oral failure.' In addition, where such an extremely unsatisfactory result is not produced, the voice formed in spite of these obstructions is far from being as pure and distinct as would have been the case had the parts been rendered more nearly normal.

"3. Before beginning the oral training the pupil should undergo inspection, by the laryngologist of the school, in regard to the conditions of his nares, posterior nares, pharynx, and ears, and all diseased conditions should be noted. When occlusion to parts of the upper respiratory tracts is so pronounced as to cause persistent mouth-breathing or pressure against the tongue or the soft palate, the parts should be rendered as nearly normal as possible before education of the pupil is commenced. When, however, such conditions are less marked, the child should be placed in the hands of the teachers, to be by them referred back to the surgeon, if, after a fair trial, it is found that such a pupil fail to

progress in vocalization. In short, operative work must be resorted to when necessary. It can be limited to a relatively small number of individuals; yet it is to be resorted to in all cases where experience proves that such procedure is required.

"4. It seems evident that by far the majority of deaf-mute pupils have lost hearing as a result of diseases subsequent to birth,—*i.e.*, their deaf-mutism is acquired.

"5. The most common lesions which appear to have caused loss of hearing are to be classified under the term 'sclerosing processes of the middle ear.' In a certain proportion of cases—the exact percentage I cannot give—this process within the middle ear is associated with a similar condition which has attacked and altered the elements of the sound-perceiving apparatus,—*i.e.*, the labyrinth. Congenital deafness is a most uncertain diagnosis, and can be positively elucidated only on the post-mortem table,—a location as unsatisfactory for the pupil and his friends as it is interesting to the scientific investigator. I believe it to be a far from common condition, and found mainly among the offspring of persons suffering from alcoholism, syphilis, epilepsy, or whose cerebral development is imperfect, such as cretins and idiots.

"6. The common cause for the middle-ear diseases associated with loss of hearing are the exanthemata, the neglect of proper hygiene during childhood, injudicious treatment during attacks of acute inflammation of the nares, pharynx, and middle ear, and the existence of abnormalities of the upper respiratory tract, which cause occlusion of the air-passages, pressure on the lower portions of the Eustachian tubes, and chronic inflammation of the entire tract.

"7. I believe that attempts to restore hearing to a child almost totally deaf, and also mute or semimute, will result, usually, in failure, and that such children should be placed in institutions for oral training as early as possible. When the attempt at medical treatment appears to be rational, it should not be continued for a term of months after its hopelessness has been made manifest. A few months, at most, should decide this matter, and the child should then be referred to the proper school for its oral training."

DISEASES OF THE NASAL AND ACCESSORY CAVITIES, PHARYNX, LARYNX, TRACHEA, AND ŒSOPHAGUS.

By CHARLES E. SAJOUS, M.D.,

PARIS.

NASAL CAVITIES.

Anatomy and Physiology.—The Fourth Annual Report of the Committee of Collective Investigation of the Anatomical Society of Great Britain [11, Dec., '95] contains a study of the variation in the number of meatuses in the nasal fossæ, based upon the examination of 452 anterior cavities. In 3 instances the superior turbinated bone was absent; in 85 the conditions were those usually observed; in 62 there was a fourth meatus, owing to the presence of a concha suprema or extra upper turbinated bone; in 2 there were five meatuses, the highest underlying a small projecting lamella of bone situated on a higher level than the concha suprema. In one instance the superior turbinal was absent and there was a plate of cartilage which projected horizontally into the nasal fossæ from the septum on a level with the inferior turbinal. The relation of the various apertures of the accessory sinuses into the nasal fossæ are also recorded. In a series of cretin skulls Harrison Allen, of Philadelphia, [2175, '94] found the hard palate shortened in all and the depth of the inferior meatus increased in proportion. Baumgarten, of Budapest, [136, No. 1, '94] records a case of double nose with two cartilaginous septa and three nares.

Raugé [87, Mar., '94] carefully studied the formation of vowels and consonants and recognized a distinction between buccal and nasal vowels, the nasal resonance accompanying the latter and not the former. He therefore suggested that the terms "open" and "closed rhino" be replaced by the more explicit ones of "rhino" and "stoma."

Histology.—Suchannek [66, v. 22, p. 4, '94; 1, June 22, '94] recognizes in the human olfactory mucous membrane, in addition to the supporting fibres, typical olfactory and basal cells: 1. Genuine leucocytes, nine-pin

shaped and oval, with hyaline contents. 2. Cells which resemble leucocytes, but which prove to be cellular elements with a pedicle. 3. Transition cells from the pigmented "bell cells," having a small amount of pigmentation and hyaloid contents. He has never seen this form except in cases of diabetes mellitus, and he leaves it an open question whether they are normal or pathological. 4. Distinctly pigmented, round, long, or transversely oval cells, the longitudinal axis being generally parallel to the longitudinal axis of the rest of the epithelial cells. He calls these migratory cells.

Bacteriology.—Strauss, of Paris, $\overset{10}{\text{V.32,No.27}}$; $\overset{2}{\text{Aug.4,'94}}$ conducted an interesting series of experiments at the Laennec and Charité Hospitals to determine whether tubercle bacilli could lodge in the nasal cavities of persons presenting no suspicion of tuberculosis and yet retain their virulence. Tampons of sterilized cotton-wool were introduced into the nasal cavities of 6 healthy nurses living in the hospital, of 7 healthy pupils making daily visits, and of 3 inmates suffering from chronic non-tuberculous affections, and afterward shaken up in sterilized bouillon or water. This liquid was then injected into the peritoneal cavity of 29 guinea-pigs. In 7 cases the animals died of septicæmia or purulent peritonitis; in 13 cases they remained apparently well and no definite lesion was discovered post-mortem; the remaining 9 cases died or were killed at the end of three to five weeks and presented decided tuberculous lesions. Apparently, therefore, (1) tubercle bacilli may enter the system through the nose, (2) they may, while remaining in the nasal cavities, fail to infect the individual, and yet retain sufficient virulence to prove infectious when inoculated into guinea-pigs. Strauss's observations also seem to show that the subjects of repeated epistaxis not infrequently become tuberculous.

Moure and Sabrazès, of Bordeaux, $\overset{37}{\text{July 15,'94}}$ in a case of mucous polypi, found a collection of caseous matter imbedded behind the growths. Bacteriological examination revealed the existence not only of mucus, pus, and epithelial cells undergoing fatty degeneration, but also numerous microbes and a large quantity of aspergillus. Notwithstanding the greatest precautions and the utilization of many different media, cultures could not be obtained. The authors, therefore, are of the opinion that the aspergillus had been destroyed by the nasal mucus in accordance with the views of Wurtz and Lermoyez. On the other hand, these views are

combated by Jonathan Wright, of New York, [1018 Apr.,'94] who found numerous pathogenic micro-organisms in apparently healthy noses.

Acute Rhinitis.—Seifert, of Würtzburg, [84 Nos.24,25,26,June,'94] studied the pathological anatomy of this disorder by removing portions of the inflamed mucous membrane. The epithelium showed but slight modifications; the cilia were absent and in some spots the superficial stratum was missing. There was intense cellular infiltration of the substrata. Stained with Ehrlich's triacid the leucocytes, found in great number in the subepithelial tissue and in the epithelium proper, were shown to be eosinophile, a few undergoing a peculiar degenerative process. These cells, it will be remembered, are found in a large number of inflammatory processes of the mucosa.

As usual, many methods of treatment were proposed during the year, practically all being remedies or combinations of well-known remedies. Gérard [31 '94] obtained very satisfactory results from the use of chloroform, recommended by Cohen as far back as 1872. The inhalation is to be practiced several times until the first signs of anæsthesia appear. Gérard states that, even in cases in which the catarrhal condition was severe and extension to the bronchial tubes imminent, he saw the disease aborted. Anfruns [633 V.9,No.5,'94] highly extols a spray of benzoate of soda during the first stage and continued at frequent intervals during twenty-four hours. Menthol is recommended by several writers. Beale, of Branksome, England, [229 Apr.,'94] observed that the effects of the drug were increased by scraping a piece of it and placing the fine particles obtained between two small pledgets of cotton-wool; these held between the fingers are thus gently heated and the fumes are given off with considerable freedom. An anonymous author [229 Mar.,'94] advises that it be strongly inhaled for a few minutes until the warmth of the vapor is felt in the throat. Valentin [568 Aug.,'94] recommends sulphanilic acid, 6 grains (0.39 gramme), with an equal quantity of bicarbonate of soda in a tablespoonful of water two to four times daily.

Acute Rhinitis in Children.—In infants acute rhinitis presents increased danger owing to the interference with suckling and to the suffocative attacks that may present themselves at the moment of going to sleep. Tissier, of Paris, [118 Jan.,'94; 2 Jan.27,'94] ably reviewed the

subject. The suffocative attacks just alluded to may, he states, be confounded with croup, the symptoms being cyanosis of the face, movements of the alæ nasi, nasal râles, violent action of respiratory muscles, leading sometimes to complete temporary arrest of respiration, and ending, perhaps, in convulsions. While sucking, the respiratory need may become suddenly so great that the infant throws back its head and makes an inspiratory movement, which may lead to milk being drawn into the larynx. Leaving on one side diphtheria and syphilis, three varieties of acute rhinitis may be recognized: 1. Simple rhinitis commonly attributed to exposure to cold; the secretion, at first transparent, becomes muco-purulent and crusts form about the nostrils, but the upper lip is not excoriated; pulmonary and aural complications are frequent, but the prognosis is, as a rule, good. 2. Membranous coryza, due to infection with streptococci derived from the maternal passages, and generally associated with septic fever in the mother. 3. Purulent coryza, strictly analogous to purulent ophthalmia neonatorum, and probably due, like it, to infection with gonococci derived from the maternal passages. This form appears soon after birth, and is purulent from the first; the pus quickly excoriates the upper lip, and the whole nose swells and becomes red, glistening, and tender. Purulent inflammations of the pharynx and nose are common complications, and, the nasal obstruction being very complete, the asphyxial attacks above mentioned are very apt to be severe. The prognosis, for this reason, is bad; in any event the inflammation is likely to continue for two months or more, and is probably one of the causes of ozæna. There may be at first some difficulty in distinguishing this condition from diphtheria and from abscess of the nose, but the history as to infection and the after-course of the cases differ. There is a milder form of this type of rhinitis associated with a more chronic (white) discharge from the maternal passages. Tissier recommends that, if the mother had suffered from a vaginal discharge shortly before delivery, the nose should be cleansed with some antiseptic application; in purulent rhinitis coming on soon after birth, and therefore probably gonorrhœal, recourse should be had at once to applications of nitrate of silver; a solution of 1 in 20, or even 1 in 10, may be applied on a cotton-wool swab. Injections (1 in 200) may also be used twice a day. When the

most acute stage is passed, antiseptic powders may be insufflated. In simple rhinitis boric-acid lotions and the insufflation of powdered boric acid are sufficient.

Lewy, of Berlin, also reviews the subject [158 B.17,H.5,6,'94] and recommends hydrate of terpene, 0.05 to 0.10 gramme ($\frac{7}{8}$ to $1\frac{3}{4}$ grains), according to whether the infant is below or over 1 year of age. The remedy is to be administered three times a day.

Hypertrophic Rhinitis.—Réthi [2061 '94; 60 May 10,'94] studies, under the name of "polypoid rhinitis," hypertrophy of the posterior ends of the inferior turbinated body, while Wingrave [11 Oct.,'94] studies the same affection under the appellation of "turbinal varix," called thus owing to the permanent distension characterizing the venous sinuses,—a plausible reason. Why Réthi should load the already overburdened nomenclature with a term so poorly representing existing conditions as "polypoid rhinitis," however, is difficult to understand. His efforts to supplant the terms "polypoid degeneration," "soft papilloma," "epithelial neoplasia," etc., is, to say the least, an unsuccessful one; it can but increase the confusion. Otherwise the work is a good review of the subject, based upon two hundred cases in which the projecting portion of the turbinal was removed by the galvano-caustic loop. Wingrave also reviews the subject and insists upon the presence of several layers of visceral muscle-fibres around the vascular channels, which are ignored by the majority of authors. The strawberry-like microscopical appearance of the surface he found to correspond with a cystic invagination of the surface epithelium, covering distended loops of vessels with very thin walls, imbedded in mucoid tissue. The muscular walls of the vascular sinuses presented well-marked atrophy and degeneration, varying from simple thinning to complete disappearance. Some parts seemed to have undergone fibrotic changes. Through the mucoid degeneration and infiltration of the sinuses the walls of the latter had lost their powers of active recoil, the cavities remaining perfectly distended, thus constituting a varix. As regards treatment, Wingrave removed with the snare, or ring-knife, all growths refusing to contract under the influence of cocaine. Over two hundred cases were thus treated by him at the Central London Hospital during the last three years without evil result, some of the operations having included the removal of a portion of the turbinated bone. The pathology and methods of

treatment of hypertrophic and other forms of rhinitis, with special reference to the work of the general practitioner, is ably reviewed by Albert Pick, of Boston. [1 Nov.17,'94] The same may be said of an article by Roth, of Vienna. [118 Nos.10,11,'93]

The year has been prolific of protests against the excessive and injudicious use of galvano-cautery in the nasal cavities. According to E. Fletcher Ingals, of Chicago, [61 Sept.15,'94] serious results in this procedure are due to carelessness or inexperience on the part of the operator, which induces him to make extensive wounds or to repeat burning too frequently. He summarizes his conclusions as follows: (1) it is important that antiseptic applications be regularly employed after cauterization of the nasal mucous membrane, and that the nostril be closed with cotton for several days whenever the patient is out of doors; (2) as a rule, at least two weeks should intervene between operations on opposite sides, and three or four weeks between those on the same side; (3) no serious results are likely to follow cauterizations made in this way. Practically, all cases of hypertrophic rhinitis may be cured by this treatment, although, occasionally, portions of the turbinated bodies must be removed. Daly, of Pittsburgh, [61 Sept.22,'94] also makes an earnest plea in the same direction, recommending the most watchful care to prevent serious inflammation of the middle and internal ear, or, indeed, expose the patient's life. Ferreri [1105 v.1,p.819] reports the case of a man, aged 46 years, in whom galvanic cauterization led to severe otitis media and mastoiditis, the latter necessitating trephining of the mastoid cells. Wilkinson [151 July,'94] reports a fatal case of meningitis due to the same cause, the affection having followed an acute suppurative otitis which had presented itself six days after the use of the cautery mildly applied.

Synechiæ, or bridges between the opposing surfaces of the cauterized nasal surfaces, if overlooked, may greatly compromise the patency of the cavities. W. J. Freeman, of Philadelphia, [119 Dec.,'93] reviews this interesting subject which has received but little attention. He states that mere incision often suffices,—a statement which is not verified by my experience. If allowed to form, their tendency is to immediately recur if the surfaces are in comparatively close apposition unless active measures are taken to prevent it. Cotton wads have often to be removed; the same is the case with iodoform tampons, to say nothing of the unpleasant odor to

which the patient is submitted. Molinié [11 Jan., '95] spoke highly, at the meeting of the French Society of Laryngology, of celluloid laminæ, recommended some time ago by Garel and which he had employed in a large number of cases. Freeman quotes Randall as recommending a careful course of treatment. The bands are thoroughly stretched by the contraction incident upon the contraction of the erectile tissue and may then be easily broken through with a probe.

In the treatment of hypertrophic rhinitis, whatever its form, Mounier [152 Jan. 19, '94] recommends a solution of perchloride of iron (30 per cent.) diluted with distilled water in proportions of 1 to 1, 1 to 2, 1 to 4, according to the age of the patient and the intensity of the trouble. The solution is applied by means of cotton pledget, fastened to the end of a thin probe. It is especially available in young children, being an astringent caustic almost painless in its action. In infants at the breast, in whom, in addition to adenoid vegetations, there is commencing rhinitis, generally strumous in character, the remedy relieves the obstruction to breathing very satisfactorily.

Atrophic Rhinitis.—Wingrave [11 Feb., '94] defines this disorder as "a progressive and persistent form of dry rhinitis, characterized by a shrinking of the mucous membrane, which tends to invade contiguous chambers, and is accompanied by the formation of crusts with more or less fœtor of a special character." Histologically the main changes he observed were: (1) transformation of the columnar ciliated and special olfactory cells into stratified squamous epithelium; (2) the disappearance of the hyaloid basement membrane; (3) the presence of special hyaloid bodies and pigment masses; (4) changes in the glands; (5) changes in the lymphoid tissue and blood-vessels; (6) changes in the bone.

The hyaloid bodies present appear to increase in number with the duration and severity of the disease. Later on they break up into minute refractile bodies, resembling spores imbedded in a transparent matrix. The disease appears, or at least is most frequently observed, about the age of puberty. Females are far more frequently affected than males. The author offers an ingenious theory as to the cause of the fœtor. He remarks that the nasal mucosa is a transformed epidermal structure derived originally from an involution of the buccal epiblast. During the

course of a case of atrophic rhinitis in the stratification of the surface epithelium a structural reversion to the primitive type takes place, and in the gland epithelium the establishment of a perverted function,—in other words, the nasal mucosa becomes converted into a cutaneous structure, with a corresponding change of secretion. Bromidrosis and rhinal fœtor have a close kinship, and in this kinship may be found an explanation of the peculiar odor observed in such cases.

In the opinion of Tissier, of Paris, [37 Sept., '94; 11 Nov.] atrophic rhinitis is dependent upon a necrotic otitis of the ethmoidal cells or sphenoidal sinus. The saprogenetic bacteria invade the cavities, and the putrefaction ensues through their presence, atrophic degeneration of the epithelium and of the glandular system following as a result. The part played by the accessory sinuses had already been emphasized by Grünwald [34 Nos. 43, 44, '93] and Bresgen. [34 Nos. 10, 11, '94] Hajek, of Vienna, [84 No. 4, '94] opposes these views, contending that the probe, used to determine the bone necrosis, communicates at all times the so-called characteristic roughness, the instrument always coming in contact with bone in the ethmoidal sinuses. It is, therefore, impossible to determine whether caries exists, while, if it were as frequently present as stated by Grünwald, the extensive anatomical researches of Zuckerkandl would certainly have brought it to light. Hopmann, of Cologne, [34 No. 3, '94] also opposes Grünwald's views, and ascribes the disorder to shortness of the septum and excessive breadth of the nasal cavity or cavities involved; genuine ozæna may thus exist without caries. The author admits that a proportion of the cases may be ascribed to necrosis, and recommends the use of the probe as a medium of diagnosis. Hypertrophy does not precede atrophy, in his opinion. In D. Braden Kyle's (Philadelphia) opinion [44 June, '94] the disease is secondary to hypertrophic rhinitis. The transition from hypertrophy to atrophy does not, however, of necessity imply the presence of ozæna. In some cases in which the nasal capacity had greatly increased the author could detect no odor whatever. In most of the cases in which odor was detected the bacillus was found upon microscopical examination of the secretions. In such cases there is usually the history of repeated head-colds followed by anterior and posterior nasal discharge. The secretion, at first thin and slightly colored, becomes gradually more and more albuminous, and shows a tendency

to dry and form crusts. Co-existing with the local symptoms, a certain degree of general anæmia is usually present. Under the euphonious name of "degenerative fetido-saprophytic keratosis," Cozzolino, of Naples, [126 Oct.15,'9] gave a comprehensive review of atrophic rhinitis, and ascribes the disorder to a special morbid entity having nothing in common with the accessory cavities.

Lœwenberg, of Paris, [262 v.8,No.5,'94] studied the bacteriology of the disease at the Pasteur Institute, and was able to verify the opinion advanced by him in 1881, that the pathogenic element was a micro-organism greatly resembling Friedländer's pneumococcus. The organism was found in great quantities in all cases of ozæna, and up to the present time has not been found in any other disease. Although it resembles Friedländer's in appearance, and stains like it, it is nevertheless distinct from it. The characteristic odor could not be obtained from the different cultures, and neither was it possible to induce ozæna in animals by inoculation. It proved itself, however, highly pathogenic,—a circumstance not to be forgotten when treatment is to be considered. Paulsen [126 Oct.15,'94] also found a large number of these bacilli in the secretions of cases examined by him. Owing to the great resemblance of the cultures to mucus, he gave the bacillus the name of "capsulated muciparous bacillus." He found it inoffensive to pigeons, rabbits, and guinea-pigs, but fatal to white mice and rats, in the blood of which animals the organism was found in great profusion. It could not be differentiated from that of Friedländer in appearance. Although, like Lœwenberg, he always found it in the secretions of atrophic cases, he could not detect it in the nostrils of 46 healthy subjects, 28 cases of acute rhinitis, 4 cases of fibrinous rhinitis, 13 cases of hyperplastic rhinitis with polypi, or in 13 cases of chronic suppurative disorders associated with syphilis, affections of the accessory cavities, etc. Strazza [461 Jan.,'94] went farther in his investigations, and bacteriologically examined fragments of the mucous membrane. His efforts remained fruitless in the affirmative sense, not one of all the stains tried indicating the presence of the bacillus. He does not consider the organism found in the secretions as the pathogenic agent of the disorder; the latter does not seem to be contagious, nor does it present any of the characters of an infectious disease. In his opinion, it is but the ultimate phase of an ordinary chronic rhinitis; in some, the latter disease becomes hypertrophic in its

tendency, in others it tends toward atrophy on account of a constitutional vice. The bacillus described by Lœwenberg is not entitled to the place given in the pathogenesis of the disease; it is but one of the elements of the local chemical decomposition.

Many already-known methods of treatment were published during the year,—mere repetitions which do not enter within the limits of this work. Vibratory massage was highly recommended by Hans Daae, of Christiania. [996 Sept.10,'94] Salunium—a compound of alumina and salicylic acid—was used with marked advantage by Heymann, of Berlin, [6 Aug.11,'94] as a stimulating astringent. The same author also recommends aluminum salicylum ammoniatum 20 parts in 30 of water and 50 of glycerin, the compound forming a convenient "paint" for local application. D. Braden Kyle, of Philadelphia, [9 May 5,'94] recommends an oily solution of oil of mustard, 5 to 8 drops to the ounce, as a local irritant after thorough cleansing with peroxide of hydrogen and drying. Einstein, of Paris, [2031 '94] recommends free washing with microcidin, 1 in 1000, and the application of silver-nitrate solutions of 1 in 20 to 1 in 5, or chloride-of-zinc solution of 1 in 100 to 1 in 10. Faradism is recommended by J. B. Garrison, of New York. [786 Feb.,'94] After thoroughly cleansing the nasal cavities he introduces a flexible nasal probe, about two inches in length by one-half inch in width, covered with well-moistened cotton, and vibrates the instrument while it is *in situ*, the sponge electrode being held in the patient's hand. A very mild current is to be used, and the applications made three times a week. Reviews of the general subject were published by Cohnstadt, of Erfurt [496 No.2,'94]; O. M. Waterman, of Milwaukee [61 Nov.25,'93]; Price Brown, of Toronto [451 Aug.,'94]; Emilio Martinez, of Havana [2162 '94]; and T. J. Schestakow, of Geneva. [2030 '94]

Syphilitic Rhinitis.—Although many articles were written during the year upon this subject very few contained any feature worthy of note. Le Bart [2031 '94] studied primary chancre of the nasal mucous membrane, and could find but thirty-seven cases in the literature of the subject, including cases of his own and reported in the paper. Four cases were reported during the year. In Thibierge's case [363 Apr.28,'94] the diagnosis was particularly difficult owing to considerable inflammation of the surrounding parts of the nose, which inflammation was the result of his occupation (woollens) and the employment of wrong medicamentous dressings. In

Chapuis's [100 July 19,'94] the ulceration was extensive and located three centimetres above the nostril, the surrounding parts being greatly infiltrated. The other two were described by Yerwant [461 July,'94] and Cimmino. [136 Dec.15,'94]

Sheinmann [11 July,'94] called attention to the difficulty of diagnosis in gummata of the inferior turbinated body and gave the details of several cases in support of his conclusion.

In the first there was severe dysphagia and obstruction of the left nasal passage. A large gumma was found upon the posterior pharyngeal wall. The posterior end of the left inferior turbinal was swollen and touching the septum. The surface was smooth and of a red color. Its anterior extremity was normal.

In the second case an ulcer was found upon the posterior pharyngeal wall, upon the tonsil, over the right arytenoid cartilage, and upon the false vocal cord. A hard swelling existed upon the anterior end of the left inferior turbinal, of a red color.

In the third case the patient, a medical man, had been under treatment for some months on account of increasing obstruction in the nostril. The posterior end of the right inferior turbinal was swollen and pressed up against the septum. No ulceration was present. A gumma was present upon the posterior pharyngeal wall. Gummata are to be distinguished from hyperplastic formations by their solid consistence, and from malignant growths by their smooth surface. All readily yielded to iodide of potassium, proving that at times the diagnosis is only possible after the administration of antisyphilitic remedies.

J. Dunn, of Richmond, [1 Jan.20,'94] reported a case in which the destructive process had thrown the nasal and accessory cavities into one vast chamber. Mendel [421 June,'94] relates an instance in which a sequestrum had been retained in the nasal cavities four and one-half years. A comprehensive review of the entire subject of syphilis of the upper air-tract was published by Seifert, of Würtzburg, [69 Oct.19,Nov.2,9,'93] and Bazenerye, of Paris. [2081 '94]

Nasal Tuberculosis.—Chiari, of Vienna, [1151 B.1,H.2,'93] reports 6 cases of tuberculoma observed in about 6000 cases of disorders of the upper air-tract treated by him during the last four years. These, added to the cases found in the literature of the subject, made a total of 21 cases reported. In 12 of these auto-infection is the only conclusion to be reached, either from sputum reaching an

excoriated part of the septum or through the lymphatics. In the other cases the infection must have come from without. In 1 case the infection arose from the antrum of Highmore. In 18 cases the position of the tuberculoma was the cartilaginous septum. Generally an ulcer first appears, from whose edges there rapidly arise granulations that soon become confluent and give rise to bleeding and stenosis. In appearance the tuberculoma is red, covered with mucus or crusts; its surface is irregular, bleeds easily, and is somewhat soft. Subjective symptoms are: Discharge from the nose, crust-formation, epistaxis, and stenosis. Later on the growth may break down, leading to perforation of the septum.

Herzog [451 June, '94] gives a very thorough review of this subject and tabulates eighty cases, including ten previously unpublished. His conclusions may be thus briefly stated: 1. Tuberculosis of the nasal mucous membrane is not as rare a disease as formerly supposed. 2. It is generally a secondary affection. 3. It is frequently secondary to pulmonary and laryngeal phthisis. 4. It occurs in the form of ulcerations, tumors, and a combination of both. 5. It occurs most frequently between 10 and 40 years of age. 6. It does not show any predilection as to sex. 7. Its seat is preferably the septum cartilaginum. 8. Its course is very chronic. 9. It is, *per se*, not dangerous to life, but may eventually lead to fatal complications. 10. One of its most important direct complications, by continuity, is that with tuberculosis of the naso-lachrymal duct and the conjunctiva. 11. It may be complicated with tuberculosis of the pharynx, palate, tongue, skin, lupus of the nose, tuberculosis of the cervical glands, etc. 12. Lupus of the face or of the nasal mucous membrane may lead to tuberculosis of the nasal mucous membrane. Dionisio, of Turin, [505 No. 17, '98] reports a case of primary tuberculosis. The diagnosis was verified by bacteriological examination. Two cases were also described by J. W. Farlow, of New York. [1 Nov. 4, '98]

Lupus.—Milligan [11 Aug., '94] reports a case in which the thorough application of galvano-cautery, supplemented by swabbing with a 4-per-cent. solution of pyoktanin and chalybeates and codliver-oil internally, brought about local resolution of many months' duration, the patient being well when the article was written. Dundas Grant, of London, [11 July, '94] also described a case, and Molinié,

of Toulouse, [1088 Dec.24,'93] two,—the latter paper giving a short general review of the subject.

Fibrinous Rhinitis.—It will be remembered that Neumann [20 v.5,p.128] found the substance forming the characteristic feature of this affection to be composed of cholestearin. In a case recently reported by P. McBride, [11 Oct.,'94] an examination conducted by Noel Paton also revealed the fact that the mass "consisted chiefly of cholestearin," thus presenting analogy to certain cases of biliary calculi. The cases in which cholestearin is the only element present are doubtless rare,—broken-down leucocytes and masses of bacteria forming the bulk of the cheese-like material so far examined. A case is described by Burn Murdoch, of Edinburgh, [11 Oct.,'94] in which the affection appeared many times in the same patient, several months intervening between some of the abscesses. Three cases were reported by Cimmino [624 v.12,No.9] and one by Scheinmann. [41 July 16,'94] A review of the subject was published by Tissier, of Paris, [100 Mar.17,'94] and by Schiffers, of Liége. [11 Jan.,'94]

M. Vladár, [622 No.16,'94] after using iodoform in five cases, concludes that this drug is a specific in fibrinous rhinitis. The powder was insufflated after irrigation, the patient being requested to inhale deeply, in order that the medicament might be made to cover as much of the surfaces as possible. The following morning all exudation had disappeared, a raw surface being left, which soon yielded to the influence of the drug. Dermatol or the subnitrate of bismuth was occasionally employed to assist the granulation process.

Rhinoscleroma.—Castex [69 Apr.5,'94; 11 Jan.,'95] gave a review of the subject and added two new cases observed in Paris, although the disease is quite rare in France. It is more common in Hungary (Juffinger reports 53 cases in Austria and 26 in Russia) and in America, where Alvarez has made the interesting discovery that indigo produced from the fermentation of the leguminous *Indigofera tinctoria* contains a microbe very analogous to that of rhinoscleroma. This investigator has also been able to produce the special fermentation of a sterilized decoction of indigofera by a pure culture of rhinoscleroma; hence the deduction that this leguminous plant might be the primary cause of the disease. However, inoculations made with a therapeutic purpose have had no result. In the discussion that followed the reading of the paper, Raugé said that he had

always been struck with the resemblance of Frisch's bacillus to Lœwenberg's bacillus of ozæna. Both are, however, very similar to Friedländer's pneumococcus.

Louis Secretan, of Lausanne, [87] after studying the extent at which the disease existed in Switzerland, concluded that it was also rare in that country. He had found the Frisch bacillus in all cases, the microbian etiology being confirmed, also, by the fact that the disorder had broken out in two brothers almost simultaneously.

As to treatment, Secretan recommends the extirpation of all voluminous nodules and the dilatation of cicatricial bands by means of intubation with Schrötter's sound. This course brought about lasting amelioration, the patients being enabled to return to their work. The nodules, however, tended to return in about a year, but distended tissues remained so. Pawlowsky, of Kiew, [69] treated two cases with an extract of cultures of the bacillus of the disease after having observed that the formation of cultures was much diminished by adding the extract to the culture fluid. Experiments on rabbits had also shown him that the extract had no injurious effect. The injection of glycerin extract into a patient 18 years old was followed by feverish reaction, reddening, and swelling of the affected nose. A month later, after fifteen injections, the plaques were softened, and examination showed signs of acute inflammation. After one year of continuous treatment the disease had made no progress. In a second case the disease made no progress during half a year of treatment. The author believes that he has found in this injection a diagnostic and therapeutic agent for the treatment of rhinoscleroma. Stükovenkoff, of the same city, [109] recommends the subcutaneous injection of arsenic, which he tried in the case of a peasant, aged 21, who was admitted into his clinic in February, 1892, with symptoms of about three years' standing. At first the disease had been limited to the right nostril, but subsequently, in spite of the area having been excised, spread to the left side of the nose. Immediately after the patient's admission, daily injections of Fowler's solution were begun, the punctures made being at first quite superficial, but later on deep. For the first four days a 1 to 100 mixture of Fowler's solution, with water, was used; for the next three days, a 4 to 100; for the next five, an 8 to 100; while sub-

sequently a 12-per-cent. mixture was invariably employed. At first the quantity injected (into four to six points) at a *séance* did not surpass 1 gramme (15½ grains), but from the ninth day it was permanently increased up to 4 grammes (62 grains). After the eighth injection the nodules markedly decreased in size; after the forty-fifth they disappeared entirely. The treatment continued fifteen successive months, the total number of the injections amounting to two hundred and twenty-two. When seen, about six months after the last *séance*, the young man showed no trace of relapse and was enjoying good general health. Unfortunately, arsenical injections are very painful.

Nasal Polypus.—Casselberry, of Chicago, $^{11}_{\text{July,'94}}$ concluded, after an analysis of forty cases, that this variety of growth is but a symptom or concomitant of other nasal diseases, the most frequent of which is ethmoiditis. The several varieties, classified according to concomitant disorders, are the following: Type I. Nasal polypus with hypertrophic rhinitis is characterized by simple enlargement of the inferior and middle turbinated bodies, and without evidence of ethmoiditis other than the suggestiveness of the polypi. Drainage is defective and the accumulation of mucopurulent secretion in the middle meatus seems to encourage polypoid growth. Recovery without recurrence follows removal of the polypi and reduction of the hypertrophied turbinated bodies by the cautery. Only six of the series of forty cases were of this type. Type II. Nasal polypus with simple myxomatous ethmoiditis is characterized by great enlargement of the middle turbinated bodies, which have a glistening aspect and a pultaceous touch, indicative of œdematous or myxomatous degeneration, and pressure in the ethmoid region, productive at times of infra-orbital swelling and broadening of the base of the nose. After resection of a considerable part of the middle turbinated bone the mucoperiosteum of the parts of the ethmoid bone thus exposed—the borders of the hiatus, bulla ethmoidalis, etc.—are found in a state of myxomatous degeneration and covered by polypoid excrescences, the same extending upward into the ethmoid cells. Fourteen of the series of forty cases were of this nature, and five of them were subjected to the operation of resection of the middle turbinated bones. Type III. Nasal polypus with vasomotor ethmoiditis is regarded as a variation of type II, and presents the

same evidences of myxomatous degeneration of the muco-periosteum of the ethmoid region. In addition asthma was a universal symptom, which to some extent influenced the grouping together of these particular cases under the conviction that asthma of this particular variety was a similar vasomotor tumefaction of the bronchioles. The group comprised nine cases, and four of them suffered from hay fever, which further indicated the possession of a fundamental neurotic habit. They were all affected by supersensitiveness to the extent that various irritants, such as dust, coal-smoke, fog, aroma from horses, etc., would suffice at any season to excite a form of nasal tumefaction suggestive of vaso-dilatation, and in most cases the ethmoid region seemed especially sensitive. Type IV. Nasal polypus with suppurative ethmoiditis is characterized by a purulent discharge from the ethmoid cells, co-existing frequently with empyema of the maxillary, frontal, and sphenoid sinuses. It is regarded as a sequel to type II or type III, suppuration occurring only after myxomatous tissue has accumulated sufficiently to obliterate the natural drainage channels, which view is substantiated by a case in which suppuration of the frontal sinus occurred in conjunction with obliteration of its outlet. This group comprises six cases, of which five were subjected to resection of the middle turbinated bone on one or both sides in addition to other measures. Type V. Nasal polypus with necrosing ethmoiditis. Woakes's contention that nasal polypus indicated a chronic inflammation of the ethmoid is in a large measure substantiated, but that necrosis or even caries of bone is a "usual" accompaniment is not confirmed; so that it would seem wise to limit the term "necrosing ethmoiditis" to the class of cases in which necrosis or at least caries actually exists. Only five cases were accompanied by unmistakable necrosis of bone. In a case reported by Pröbsting, of Wiesbaden, $^{37}_{\text{Nov.,'94}}$ the patient had received a blow between the two eyes which caused violent epistaxis and occlusion. Six months later she consulted the author, who examined the nasal cavities and found no polypi. After another period of six months examination elicited the presence of polypi on the right side. These recurred several times after removal. Finally, frontal and ethmoidal empyema was diagnosticated and its presence verified by operation. No recurrence took place after this procedure was carried into effect. Ritter $^{1178}_{\text{June,'94}}$ saw a case in which

a polypus extending into the antrum had been diagnosticated as a sarcoma of the jaw, its true nature being revealed on opening the antrum. Jonathan Wright, of New York, [1 Nov. 4, '98] studied the histology of the œdematous form, differing from the typical form in that there is no homogeneous groundwork taking a deep-blue stain with hæmatoxylon and dotted with branching eosin-stained cells. The œdema is always most marked at the most dependent parts, but does not penetrate the epithelial layer. The watery discharge is probably due to the irritation of the growth on the surrounding mucous membrane, the mechanism of the production of the fluid in the polypi being a matter of speculation. "Clinical observation and histological study suggest that it is caused in some way by an antecedent chronic inflammation of the nasal mucous membrane." It contains serum-albumin and large quantities of mucin; the exudation of small round cells into the stroma is frequently very marked. Œdematous nasal polypi contain much fewer glands than normal tissue. Glands are relatively more abundant as the serous infiltration is slight. Blood-vessels are scanty and small. Cyst-formation is occasionally a striking feature, although a large number of glands may be seen in various stages of degeneration. A glandular cyst might go on growing in a polyp until it occupied the whole of it. Occasionally a cyst is formed by a dilated blood-vessel. Hyaline bodies, fat-cells, or spiculæ of bone the writer has never seen in the growths.

Luc, of Paris, [286 Nov., Dec., '98] reported a case in which an inflamed myxoma appeared to be in active sarcomatous transformation. The growth completely occluded the left cavity. Though it resembled an ordinary polyp, it bled profusely at the slightest touch. With considerable difficulty it was eventually removed, practically by evulsion with a double curette passed beneath it, and the hæmorrhage was so profuse as to produce demisyncope. The growth was of the size of a large prune and of irregular configuration, defying all comparison.

At a meeting of the Laryngological Society of London, Semon [11 Mar., '94] reported a case of nasal polypi in which symptoms of incomplete Graves's disease, and, later on, complete premature baldness, followed removal of the growths from both nostrils, by means of the snare and galvano-cautery. Cresswell Baber alluded to a case in which the same procedure caused diplopia on looking

to the right, with want of power of the external rectus. The ocular symptoms disappeared, in about six weeks, under the administration of perchloride of mercury and iodide of potassium. The same symptoms had appeared after an operation with forceps two years previously in the same patient. A case of death following the removal of polypi by galvano-cautery was reported by J. Broeckaert, of Ghent.[87] Erysipelas of the septum and upper lip began the evening of the operation, but yielded to free incisions. Ten days later, however, it recurred and was followed by meningitis. Although trephining over the fissure of Rolando was resorted to and a large quantity of pus was evacuated, the patient, a child aged 15 years, died in convulsions, twenty days after the operation. Besides a leptomeningitis involving mainly the right temporal lobe and the falx cerebri, the maxillary, ethmoidal, and sphenoidal sinuses were found filled with pus at the autopsy.

A. Pauné, of Nevers,[286] records an instance in which he found it necessary to make a resection of the nose and keep the parts temporarily ununited for three weeks, in order to relieve a patient from mucous polypi. The nose was separated from the face on the left side and thrown over the right cheek, the organ being replaced after each sitting, but prevented from reuniting by the interposition of strips of gauze between the raw surfaces. Four operations by curetting and cauterization, at intervals of a few days, were resorted to. A. J. Brady and J. M. Creed, of Sydney, record[267] a case in which the removal of a large mass of polypi was accomplished under anæsthesia produced by hypnotic suggestion. The nasal cavities having been occluded for twenty years, the patient had acquired the habit of breathing only through his mouth, and, unless his attention was especially directed to it, he continued to do so after the removal of the obstacles. Under suggestion when hypnotized, he at once commenced to breathe through the nose, keeping his mouth closed without conscious effort.

In a clinical lecture upon the subject of mucous polypi, Duplay, of Paris,[680] recalled that he had been the first to suggest the substitution of the snare (Wilde's) for the forceps in the removal of these growths,—a fact generally overlooked.

Cysts.—Although formerly this form of growth was very

rarely alluded to, the literature of the year contains quite a number of papers giving reviews and reporting cases. Dunn, of Richmond, 1 Feb. 24, '94 in describing a case in which the tumor was located upon the floor of the cavity, quotes Bosworth's statement that they are among the rarest of occurrences. Bico, of Liége, 11 Dec., '94 reported four cases, one of which was remarkable on account of its size and its tolerance. It occupied the left nostril, pushing the septum to the side sufficiently to place it in contact with the right external wall and induce sufficient pressure to cause depression into the antrum. The nasal bones were separated twelve to thirteen centimetres and the transverse diameter of the orifice of the nostrils was thirty-eight millimetres. The growth was emptied of its contents, fluid resembling that in hydrocele, and its stump cauterized and resected along with a part of the wall. H. Knapp, of New York, 11 Mar., '94 removed a sero-mucous cyst from beneath the left ala, of seven years' standing. W. Scott Renner, of New York, 170 Oct., '93 reported a case, giving at the same time a brief review of the subject. In a case operated by Ficano, of Palermo, 624 Aug., '94 the tumor had grown over the site of a polypus removed three years before.

Papilloma.—Jonathan Wright, of Brooklyn, 59 July 7, '94 in a paper in which papillary hypertrophy was compared with true papilloma, stated that there was much confusion in the literature of rhinology, from the loose use of the term "papilloma" as applied to intra-nasal excrescences. Hopmann has described a pathological formation which the Germans speak of as papilloma, but it is not true papilloma at all. Such growths in the nose are rare.

As contrasted with the true papilloma, almost any fold of papillary hypertrophy communicates with the central mass without any appearance of a "budding" process. The line of surface epithelium is not especially thickened or irregular. The papilloma is without glands, has only small capillaries, a slight branching frame-work of connective tissue, and is covered everywhere by a large number of regularly-situated layers of flat epithelial cells. The papillary hypertrophy consists of all the constituent parts of the mucous membrane of the inferior turbinated body. The dilatation of the venous sinuses is especially marked. Glands are present, but scanty. The fibro-connective tissue is greatly increased. This, at the periphery, is divided into regular processes

which are covered by epithelium and separated from each other by depressions giving a nodular surface.

Sarcoma.—Cozzolino, of Naples, [1105 v.2,No.2,'94] reports a case of myxosarcoma of the anterior portion of the right inferior turbinated body and a fibrosarcoma of posterior extremity of the left inferior turbinated body.

Foreign Bodies in the Nose.—Nothing very interesting was reported during the year. Herzfeld [312 Sept.,'93] found it necessary to give chloroform in a case in which the foreign body had slipped into the post-nasal space, and prevented its falling into the larynx by allowing the head of the patient to drop backward over the edge of the table. Hecht [116 No.8,'93] also removes foreign bodies during narcosis,—a procedure not to be recommended unless it is absolutely unavoidable. Gradenigo and Mattirolo [739 No.5,'93] describe a case in which the foreign body, although a soft substance,—a piece of apple,—had remained in the nasal cavity two years. Lederman, of New York, [59 Apr.14,'94] treated a case of suppuration of the middle ear in which the etiological factor was a coffee-bean, introduced into the nose by the patient,—a child 3 years of age.

Rhinoliths.—These formations are usually considered as resulting from the presence of a foreign body which ultimately becomes the nucleus. Moure, of Bordeaux, [136 Mar.15,'94] added a case to those already reported in which the calculus had formed around a blood-clot; in this instance, however, the centre of the mass was found to contain a large quantity of micro-organisms. That a blood-clot could form the starting-point of a calculus was recognized by Flater as far back as 1736; the mycotic origin of a certain proportion of these formations was found to merit recognition by Czarda in 1884. The principal pathogenic organism is the leptothrix,—a frequent cause of salivary calculi. The comparative absence of chloride of sodium among the chemical constituents of nasal rhinoliths causes the author to conclude that the tears are in no way connected with their production. A case that would probably prove interesting in this connection is that of Morley F. Agar, of London, [22 Nov.22,'93] but, the calculus not having been opened its cause was not determined beyond the fact that the patient, had received a blow upon the nose. In a case treated by Noquet, of Lille, [136 Aug.1,'94] the rhinolith produced neither discharge nor pain. The only symptom present was the ozæna. Cozzolino,

of Naples, [37 v.19,No.2,'92; 5 Jan.,'94] reported a case in which the calculus had produced partial destruction of the nasal septum, and, having penetrated into the opposite cavity, thus occupied both the right and left nares. The only case of this kind so far reported was published by Zuckerkandl. [2163 B.2,p.158,'92] Cozzolino [35 June,'92] also described a case in which two rhinoliths occupied the same cavity. He makes a distinction between true rhinoliths—in which the calcareous deposit becomes formed around a nucleus of mucus or of blood—and false rhinoliths,—the more common, in which a foreign body, such as a cherry-stone, a bead, or the like, has formed the nucleus. The former, he states, are rarely found before the fortieth year of age; the latter may be found at any age, the foreign body often having been inserted in play during childhood. W. H. Wakefield, of Winston, N. C., [1063 Feb.,'94] reported a case in which he removed a calculus from a man, aged 33 years, in whom the cause was ascribed to cherry-stones introduced into the nose when he was a child.

Harrison Allen, of Philadelphia, [451 Apr.,'94] published two instructive cases. In the one, a physician of standing and ability had attributed to hypondriasis the symptoms of what proved to be a large rhinolith in the nasal chamber. An undue narrowing of the nasal cavity having rendered a satisfactory diagnosis difficult, Allen dilated it by digital divulsion, which consists in forcing the tip of the little finger in the nostril on the level of the floor of the nose, or as near to it as is possible. Ether is administered in the first stage. The advantages claimed for this procedure are: 1. The increase of diameter of the nasal passage not only in the vestibule, but in many cases in the entire length of the nasal chamber. 2. A more free depletion of overdistended vessels than is possible in any other way. It is well to divulse each chamber in separate sittings, if the procedure be essayed in the office. True rhinoliths, he thinks, as distinguished from foreign bodies which are more or less incrusted with calcareous deposit, are more apt to form in a narrowed nasal passage, though it is evidently the case that other associated causes are necessary, or they would be oftener met with in practice.

Myiasis.—Botchvaroff [109 June,'94] states that myiasis is very common in Bulgaria, attacking both man and animals. The following varieties of fly are the most prolific producers of larvæ in that

country: *Pyrelia cadaverina*, *Musca vomitoria*, *Lucilia Cæsar*, *Lucilia serriata*, *Lucilia macellaria*, *Lucilia anthropophaga*, *Ochromyia anthropophaga*, and *Sarcophila Wohlfarti Portchinskii*. The latter seems to be the most dangerous, as is the case in Russia. Two cases are reported by E. A. Durham, of Calvert, Tex., $\frac{192}{\text{Dec.,'98}}$ and two, also, by C. R. Oatman, of St. Louis. Chloroform was used in all four, with satisfactory results.

SEPTUM.

Abscess; Perichondritis; Perforation.—Schiffers, of Liége, $\frac{37}{\text{Aug.,'98}}$ studied the pathogenesis of perforating ulcer. In his opinion, congenital dyscrasia can be excluded as origin of the loss of substance. The edges of the ulcer, its course, its invariable position, and its tendency to cicatrization eliminate syphilis as a cause. It cannot arise from tuberculosis, this affection being characterized by infiltration and the presence of Koch's bacillus. The same may be said of lupus and cancer, which present their own typical characters, while a nervous origin can also be excluded on account of the absence of modification of sensibility. The bacterial origin is also denied, the micro-organisms present being the staphylococcus pyogenes and the streptococcus pyogenes, accompanying ordinary ulcerative processes. If the latter is investigated it will be found to result from a disorder located at one point of the mucosa and extending in such a way as to form a truncated cone with a superficial base,—*i.e.*, the characteristic form of infarction. This spot is frequently the origin of hæmorrhages. Whether the cause be an infarctus or a venous thrombosis, the part is cut off from circulation, becomes macerated by the nasal mucus, and local degeneration takes place. It can, however, in exceptional cases present itself as a catarrhal ulceration. In Schiffer's opinion, therefore, simple ulcer of the septum constitutes a definite morbid entity.

Moure, of Bordeaux, $\frac{25}{\text{Apr.,'98}}$ in a series of three cases in young subjects—18 to 20 years of age—in whom a syphilitic or tuberculous origin of the trouble could with certainty be eliminated, removed, by means of a punch-forceps, all the ulcerated area and submitted the specimens to careful histological examination. This showed that in two of the cases the pathogenesis could not be ascribed to an obliteration of blood-vessels by thrombosis, but to

a true necrobiosis of the mucous membrane and cartilage finding its origin in an infectious process. Micro-organisms in large quantities were found in the excentric zone of the ulcer. In the third case the perforation was due to an adeno-epithelioma, which did not recur after removal with the punch-forceps. Cases and reviews of the subject were published by Marcel Natier, of Paris $_{\text{July,'94}}^{62}$; J. Hutchinson $_{\text{Oct.,'93}}^{806}$; $_{\text{May 16,'94}}^{22}$; C. C. Rice, of New York $_{\text{June,'94}}^{134}$; Lacoarret, of Toulouse $_{\text{Mar.,'94}}^{1149}$; W. S. Anderson, of Detroit $_{\text{June,'94}}^{846}$; A. Moran $_{\text{'94}}^{2164}$; and Wroblewski, of Warsaw. $_{\text{No.42,'94}}^{520}$

Deviation, Crests, and Spurs.—Anton $_{\text{B.35,H.3,4,'94}}^{328}$ takes exception to the statement frequently published, that deviation of the septum never presents itself before the seventh year. In recent years cases were published in which it existed in children 5, 4, and even 3 years of age, while Onodi and Patrzeck have cited cases observed in the newborn. With the latter point in view, Anton examined 50 bodies of still-born fœtuses, and found malformation of the septum in 9,—*i.e.*, 16 per cent. In one instance there was pure deviation; in the other 8 there were spurs, situated in the antero-inferior portion of the septum and extending about one centimetre posteriorly; the septum leaned toward the free side. He ascribes these spurs to the displacement of the inferior portion of the quadrangular cartilage. W. Martin $_{\text{Oct.21,'93}}^{9}$ insisted upon the connection between hypertrophic rhinitis and septal deviations. A. Coolidge, of Boston, $_{\text{Aug.16,'94}}^{99}$ examined 100 cases taken at random in a hospital clinic. A well-marked ridge in one or both nostrils was found along the cartilage-vomer synchondrosis in 58; along the cartilage-ethmoid in 51. A noticeable bend occurred in 40. In 6 there had been a dislocation of the cartilage from the vomer, and in 4 an old fracture of the cartilage. The author considers that "there can be no doubt that most, if not all, of the cases are of traumatic origin,"—a statement not in accord with the opinion of the majority of scientists. He rightly considers it a mistake to remove the thickening observed at the apex of angular curvatures, apparently a provision of nature to strengthen a weak point, the bend being frequently increased by such a procedure.

Moure, of Bordeaux $_{\text{May,'94}}^{11}$ discussed the value of his method of applying electrolysis in the treatment of spurs, as compared with other methods before the Laryngological Section of the International Congress. The method itself was already described in

these columns. As to its comparative application, the author thought that electrolysis should be employed alone or associated with galvano-cautery when the septal thickening was great. In small spurs, galvano-cautery alone in the form of ignipuncture would often prove sufficient to obtain the desired result. These means presented the advantages of being particularly painless and bloodless. While not supplanting other methods of treatment it could be considered as one of the best. Bresgen $_{\text{Jan.,'96}}^{11}$ considers the scope of electrolysis as limited to (1) those cases in which it was not possible to carry out more energetic treatment,—for example, in delicate persons or those who were suffering in other ways; (2) cases in which radical treatment was refused. The use of electrolysis is of value in cartilaginous and bony outgrowths of the nasal septum, as also for swelling of the mucous membrane. Before all things it is necessary to carry out careful cocainization, and care should be taken to avoid causing distress by introducing the current quite slowly. Double needles are preferable to single ones; yet Bresgen uses the single ones in such a way that the one, for example, may be introduced straight into the anterior surface of an outgrowth of the septum, the other one, bent at an angle, being introduced into the posterior surface; in that way a quicker and more thorough effect is produced. For the side-walls of the nose he uses a double needle which, at two or four millimetres from the point, has a rectangular bend; so that these needles can also be driven perpendicularly into the tissue. During the action of the electric current there quickly forms a quantity of froth at the negative pole, through which a considerable amount of electrical force is lost. In order to prevent this it is necessary to blow away the froth into the back of the nose or to introduce the needles in a new place. The after-pains, which may occur after the use of electrolysis, are generally so slight that the patients are not prevented from carrying on their usual mode of life. The slight hæmorrhages which occasionally take place at the positive pole are best stopped by means of a 20- to 40-per-cent. solution of chromic acid. Bresgen, on analyzing his experience, finds that electrolysis is not, nor ever can be, a therapeutical measure which can be used by other than experienced specialists, because when carried out by unskilled hands it can only lead to disaster. As regards its comparative value, he declared that he only used elec-

trolysis when not permitted to use other means. Hajek, Stoerk, and Heymann also considered it inferior to other means.

At the International Congress Ruault recommended electrolysis when a pyramidal outgrowth compromising the lumen existed. In his opinion, plastic operations are purely theoretical. Rosenfeld also advocated the measure for solid thickenings of the septum difficult to remove with scissors or knife. Chiari stated that he employed it for crests, but that he considered it as a slow measure. The method was also extolled by Mettenheimer [366 B.57,H.1,'94] and reviewed by Karl Hess, of Falkenstein. [84 Sept.28,'94]

T. R. French, of Brooklyn, [1 N.555,'94] from a study of the results of perforations made by others, and from his own and other experiences with perforations with unhealed edges, expresses his belief that, with proper care in the after-treatment, perforation can be deliberately made without injury and with great relief in a certain class of cases; that if the breath-way through the obstructed side cannot be obtained without leaving a hole in the septum, such a procedure is justifiable if the patient can be impressed with the necessity of leaving the parts alone, and it is reasonably certain that the case can be carefully followed until healing of the edges has occurred; otherwise it is an unjustifiable method of operating. He, however, excepts from that statement the perforations made near the entrance of the nostrils, particularly in a septum bent obliquely across both openings, by the Blandin punch. In the matter of membranous adhesions, after reviewing the recognized causes of this annoying sequel of operations within the nasal passages, the author called attention to a cause heretofore overlooked, viz., that cut surfaces on the septum will become adherent to scar-tissue on the turbinates made by the galvano-cautery at some previous time. Therefore, in patients who present for treatment whose nares have never been subjected to operative procedures, and in whom there is need of the destruction of turbinated tissue and removal of obstructing cartilage or bone, the septum should be operated upon first, when, after a month or more has elapsed, and it is certain that the mucous membrane is completely reformed, the turbinates can be safely destroyed by any method. When, however, patients object to a cutting operation on the septum, but are willing to submit to the destruction or removal of turbinated hypertrophy, preference should be given to

the use of the snare or acids, in order to avoid the possibility of leaving a surface which might become adherent to a wound opposite in the event of a cutting operation on the septum being performed later. Without doubt, adhesions are frequently occasioned by saws with unprotected ends and the unskillful use of trephines and cutting-forceps in narrow passages. Botey, of Barcelona, [37, July, '94] has obtained satisfactory results from an operation of his own, although occasionally a small perforation is left. He makes an horizontal incision along the lowest portion of the septum at its junction with the floor, including the membrane and the cartilage. Three perpendicular cuts are then made,—the first at the point of union with the blade of the ethmoid, the second in the centre of the concavity, the third near the anterior portion of the deviation. The central fragment is then shortened somewhat after denuding the cartilage and the whole is forced into the central line, this being easily done on account of the cuts. Iodoform-gauze pledgets are then inserted to keep the fragments in position. The parts usually heal completely in a couple of weeks. As splints to hold septal fragments in position, Passmore Berens, of New York, [2165, Jan., '94] uses wedge-shaped pieces of cork anointed with iodoform collodion, a groove having first been cut out to accommodate the inferior turbinated body. Finally, H. Levy [2166, '94] counsels great reserve in the employment of operative means, almost concluding, with Tillaux, that it is impossible to straighten a deviated septum satisfactorily, and that it had better be left alone. Good reviews of the subject of treatment in this class of cases were published by J. O. Roe, of Rochester [1, Apr. 7, '94]; W. A. Martin, of San Francisco [61, Sept. 29, '94]; Ziem, of Dantzig [312, No. 7, '94]; Sarremone [2031, '94]; and Hamburger, of Breslau. [2167, '93]

A. C. Getchell, of Boston, [99, July 5, '94] disagrees with the majority of authors regarding the importance of hæmorrhage after operations on the septum, and, in an interesting article upon the subject, concludes, after personal experience in several instances, that: 1. Operations upon the nasal septum may be followed by hæmorrhage sufficient to very materially affect the health of the patient. 2. The artery of the anterior (cartilaginous) septum may lie near the surface, be of considerable size, and, if atheromatous, may cause serious hæmorrhage. 3. Operations upon the nasal septum in adults should be advised only after carefully considering the

good to be accomplished and the possible risk incurred. H. H. Curtis, of New York, [61 Nov.28,'93; 451 July] cautions against operating on the septum of hæmatophiles, or of a person whose blood contains less than 7 per cent. of oxyhæmoglobin. One "should not interfere with a deflection unless there are reflex or direct troubles arising from the stenosis produced." The relief of a nasal stenosis is often an important factor in the cure of anæmia in a young person. In three cases the writer had seen a severe attack of gout develop within three days after a septal operation in a gouty subject.

Tumors of the Septum.—J. S. Gibb, of Philadelphia, [119 Feb.10,'94] and Lacoarret, of Toulouse, [136 May 15,'94] each relate a case of hæmatoma, the result of traumatism in both instances.

Angioma and Lymphangioma.—F. C. Cobb, of Boston, [99 Nov.23,'93] found sixteen cases of angioma in literature and adds a well-authenticated instance to the list. The tumor was removed by means of the snare, with very slight hæmorrhage. Schadewald [37 v.19,No.5,'93] and Garel and Collet [37 Nov.,'93] also report cases of this growth besides several of lymphangioma. Five of the latter variety of tumors were described by Heymann, [136 Mar.15,'94] and one by Scheier. [11 July,'94] In a case seen by Strazza the frequent attacks of epistaxis to which the patient had been exposed had so undermined her health that surgical measures were contra-indicated and the author employed electrolysis. The unipolar method was given preference and the positive needle introduced into the growth, owing to the property, possessed by the positive pole, of causing coagulation. Four sittings, with an intensity of 12 milliampères of ten minutes each, were sufficient to cause almost complete disappearance of the growth, ten days having intervened between each application. Strazza concludes that electrolysis is indicated for the removal of growths in which surgical procedures offer great dangers. Broca, of Paris, [14 Sept.26,'94] observed a case in which a tumor of this variety had been taken for serous cyst and punctured, the result being severe hæmorrhage. The surface was white and presented all the appearances of a cyst. Microscopical examination showed it clearly to be a capillary angioma with sarcomatous and lipomatous areas. The exaggerated development of sebaceous glands might also have caused it to be taken for an epithelioma.

Osteoma.—Our corresponding editor in Jamaica, H. Strachan,

reported [2 Jan.27,'94] an interesting case of bony overgrowth of each side of the bridge of the nose. It was congenital and grew with the child; smooth, hard, and of the size and shape of an elongated pigeon's egg, and springing from the nasal process of the superior maxilla and nasal bones. There was no pedicle or constriction. The growths somewhat encroached on the anterior nares. They were removed by chisel and proved to be chiefly hypertrophic development of the superior maxilla (nasal process), and, to a less degree, of the nasal bone, and consisted of compact bony tissue externally, with a cancellous core. The author points out that Lamprey [2 Dec.10,'87] had already reported three cases of bony growth of the infra-orbital ridge, occurring in negroes of West Africa, and regarded them as a racial peculiarity. Two cases of true osteoma were described by Tichow. [21 Aug.11,'94]

Sarcoma.—Onodi, of Budapest, [136 Jan.1,'94; 5 May] reports a case in a man 50 years of age. The disease began early in 1888 as one of multiple bilateral benign polypi, with recurrence toward the close of the year. Evulsion of the growths and igneous cauterization of the suspicious places procured uninterrupted relief for ten months. Eleven months later one side of the nose was filled up again with growths, this time exclusively sarcomatous; the other side remaining entirely free of them. The nose was resected and complete extirpation practiced, including the turbinated bodies. Suppuration was found involving the lachrymal sac, the frontal sinus, the sphenoidal sinus, and the ethmoidal cells; all which parts were thoroughly cleansed. The patient has been well ever since. In a case reported by S. W. Richardson, [1018 Jan.,'94] occurring in a boy 5 years of age, the growth had apparently begun at the middle turbinated bone and included the antrum. All the parts involved, together with a part of the palate and pterygoid plate, were removed. Resolution was quite prompt, but the growth re-appeared and speedily grew, death occurring four months after the operation. It was found to contain, besides myxosarcomatous elements, a quantity of striated muscular fibres. Mermet [7 July,'94] reported a case of fibrosarcoma, in a girl of 16 years, in which the growth was as large as a hen's egg, filling the naso-pharynx and a good part of the buccal pharynx. An inoperable case was described by Robert Levy, of Denver [1 Mar.17,'94]; another case, defined as a mixed sarcoma containing melanotic pigment, by Horace

Clark, of Buffalo [9 June 20, '94]; and a small-celled sarcoma, complicated with abscess and necrosis of the orbit, by Bethune Patterson, of Atlanta, Ga. [117 Dec., '93] In a case treated by A. d'Aguanno, of Palermo, [37 Sept., '93] the growth was situated on the right side of the septum of a girl 11 years of age, and had only been growing about one month. It was removed with the cold-wire loop, the base being afterward scared with the galvano-cautery. The microscope showed the neoplasm to be a mixed sarcoma, composed in part of small round cells and in part of embryonic or encephaloid tissue, resembling lymphosarcoma and "fuso-cellular" sarcoma in different regions. There was no recurrence at the end of two months. Two cases of myxosarcoma were reported by Cozzolino, of Naples. [1105 V. 2, No. 2, '94]

Carcinoma.—Two cases of carcinoma of the turbinated body are reported by W. S. Jones, of Camden, [80 Mar. 15, '94] the diagnosis in both being verified by microscopical examination. The growths were removed by snare and curette in both instances. No recurrence had taken place at the time the report was made,—eighteen months after the operation in the one case and a year in the other.

Congenital Occlusion.—An interesting case of osseous occlusion of the choanæ was reported by Gouguenheim and Hélary, of Paris. [37 Jan., '94] Rhinoscopical examination of the vault disclosed a mass of adenoid vegetations and the fact that the left choana was completely obstructed by a smooth, bony wall. There was pronounced deafness in the left ear and the sense of smell was completely abolished. The adenoid growths were first removed, but all attempts to pierce the bony wall with the galvano-cautery were unsuccessful. Under cocaine anæsthesia it was perforated with a drill (the Eustachian prominence being protected from injury) and the opening enlarged with the galvano-cautery. A second opening was then made and the two united by means of the galvano-cautery. Over a year later the respiration was good, hearing much improved, and sense of taste normal. In a case treated by Beausoleil, of Bordeaux, [188 July 8, '94] the patient, aged 11 years, had long complained of ozænous coryza; the left naris was incompletely blocked by an osseous septum in the postero-superior part of the choana. In the right nasal cavity the occlusion was absolute, and the osseous septum seemed to be an appendage of the pterygoid apophysis of the

sphenoid bone. Perforation of the septum was obtained with the galvano-cautery, and dilatation of the opening by a probe. Complete cure resulted. Cresswell Baber, of London, $^{11}_{\text{Mar.,'94}}$ reported a case in which the occluding tissues were found to be partly bony and partly membranous, the osseous portion consisting in a projection of the septum about half an inch thick. Whether it was adherent to the inferior turbinated body could not be ascertained. Cases were also reported by Dundas Grant, of London $^{11}_{\text{Mar.,'94}}$; Scheppegrell, of New Orleans $^{1018}_{\text{Apr.,'94}}$; Frèche, of Bordeaux $^{188}_{\text{May 6,'94}}$; Heins, of Marburg. $^{2168}_{\text{'94}}$ In the latter case all efforts to perforate the osseous obstruction remained futile. Why anything else should be expected is difficult to understand.

Epistaxis.—Baumgarten, $^{680}_{\text{v.4,No.15,'94}}$ in statistics of 250 cases, including 150 males and 100 females, found that the seat of the hæmorrhage was upon the cartilaginous portion of the septum in 219 instances, the causes being varied; small varicose veins or erosions furnished the stream in all but 11 cases, these being of arterial origin. In 3 severe cases of grippal origin de Roaldes, of New Orleans, $^{59}_{\text{Oct.14,'93}}$ found it located, on the contrary, in the posterior third. In a fourth case of the same kind, in a girl 7 years of age, death ensued as a result of the anæmia caused by the nasal hæmorrhage Verneuil, of Paris, $^{73}_{\text{June 2,'94}}$ divides the disorder into three forms: (1) the juvenile, (2) the hepatic, and (3) the hereditary hepatic. In children he believes that it is almost always the result of latent disease of the liver. In adults the hæmophilic form is generally associated with arthritism, and especially with the lesions of the liver caused by arthritic disease. A number of cases in which this association was very plain are cited. The practical bearing of this is important as regards treatment. Instead of tonics and milk diet, so often prescribed and so injurious to the liver, an alkaline and vegetable diet, with general and local douches, should be ordered. In several cases of his own this plan of treatment was very successful. Panas also believed that nasal hæmorrhage in childhood was not spontaneous, that hepatic affections possibly played some rôle, but there might also be other causes. He had seen cases due to dyspepsia with gastric dilatation, and also to obstinate constipation. In elderly subjects arterial lesions were the chief cause. Tautil $^{2031}_{\text{'94}}$ considers epistaxis as more common in the aged than is

generally thought, and cites eleven cases, nine of which were in women. Vascular degeneration is considered as the most prolific cause.

Dionisio [589 Mar.19,'94] recommends vibratory massage, 2000 to 3000 vibrations per minute. Cozzolino, of Naples, [14 No.101,'93] condemns perchloride of iron and extols the use of a solution of trichloracetic acid,—1 gramme (15½ grains) of the acid to 30 or 40 grammes (1 or 1¼ fluidounces) of distilled water. A tuft of cotton is wound around a splinter of wood and the solution applied directly to the cartilaginous septum, whence the hæmorrhage generally comes. In order to prevent the disagreeable sensation of burning, a little cocaine or tropacocaine may be added. The remedy acts rapidly; a scab forms on the cauterized spot, which falls off and the wound heals. Miot [37 June,'94] states that positive interstitial electrolysis should be the method of choice when extensive epistaxis occurs from erectile or varicose tissue. It is also of value in the treatment of more limited hæmorrhagic areas. Electrodes of copper or silver are preferable. The intensity of the current should average from 16 to 20 milliampères, and the length of the *séance* from eight to ten minutes. Three or four applications are sufficient in exceptional cases, one or two in ordinary instances. Hæmostasis in this region is easily secured, although its vascular relations with the brain are important.

De Roaldes, of New Orleans, [59 Oct.14,'93] condemns post-nasal tamponing owing to the aural complications so frequently observed. He considers that the cases in which it may be employed are exceedingly few. Continuous antero-posterior packing with iodoform gauze is considered by him as effective as it is innocuous. A temporary absorbent-cotton plug is first passed behind the palate, attached to a piece of thread passing out through the mouth. This plug serves as a wall, against which the iodoform gauze is packed through the anterior nostrils until the cavity is well filled. The cotton plug is then drawn out through the mouth. Dionisio also condemns [37 July,'94] posterior nasal plugging. Freshly-prepared ergotine solution (B. P.), 15 drops injected hypodermatically, is highly praised by Cleaver, of Sheffield, [22 Dec.15,'93] and 15 drops of fluid extract of ergot and 3 drops of tincture of digitalis by J. H. Lowrey, of Neola, Iowa. [1 July 21,'94] A good review of the whole work was published by S. Kohn. [59 June 9,'94]

NEUROSES.

Hay Fever.—J. Molinié, of Marseilles, [2169/'94] in an interesting thesis, studied the connection between hay fever and spasmodic coryza. He concludes that these diseases only differ in the excess-producing causes, the pathology of both being identical. An arthritic diathesis is considered as the main etiological factor; it is in this class of subjects that the neurotic idiosyncrasies usually manifest themselves. A nasal disorder is not uniformly necessary in the pathogenesis of the disease; the irritating external agents merely act upon an hyperæsthetic Schneiderian membrane, which, through centripetal nerve-connection, influence the bulb, the central origin of remote nervous manifestations. The irritating particles may, in his opinion, act upon other organs and determine reflexly secondary symptoms within the nose. As regards treatment, Molinié advises the administration of remedies calculated to diminish the hyperexcitability of the nerve-centres and especially local measures in the nose intended to produce an alteration of the mucous surfaces that receive the peripheral impressions. For the latter purpose he recommends galvano-cautery or glacial acetic acid. A long list of cases is appended, several of which followed a satisfactory course under the influence of local measures repeated year after year, the attacks gradually diminishing in intensity. In the opinion of Seth S. Bishop, of Chicago, [61/Nov.28,'98] hay fever is due to an excess of uric acid in the blood; he quotes several authors to show various elements of analogy in the production of uræmic manifestations. The mineral acids are recommended. Dilute sulphuric acid, 10 to 30 drops three times daily, and acid phosphate of soda in doses of 1 or 2 teaspoonfuls are administered, a dose on rising being insisted upon. As a preventive Bishop gives the salicylate or the phosphate of sodium for about forty days before the expected attack. Galvano-cautery is employed when indicated by local organic lesions. John Aulde, of Philadelphia, obtained [71/Aug.,'94] very satisfactory results with the arsenite of strychnia, $\frac{1}{100}$ grain (0.00065 gramme) every two or three hours. When asthma complicates the cases he administers small doses of nuclein. Mollière, of Lyons, [211/Jan.21,'96] has observed that inhalations of the ordinary cologne-water produced a marked sedative effect during paroxysms, a few whiffs being sufficient at times to arrest the intense pruritus.

Anosmia.—De Renzi [596 Mar.,'94] relates a case in which a prolonged illness had caused the gradual loss of the sense of smell, the strongest odors—musk, asafœtida, etc.—remaining unperceived. The nose presenting no organic lesion whatever, the author tried static electricity, applied within the nose. The first application, of five minutes' duration, completely restored the lost sense. A case of the same kind is reported by Labbé, of Paris. [879 Apr.,'94] The static electricity in this case, however, was used for the treatment of neuralgia of the shoulder and arm, the cure of the anosmia being unexpected. Seven years have elapsed since, and the patient's sense of smell is perfect.

REFLEX NEUROSES.

Asthma.—Dauchez, [118 July,'94] in a study of infantile asthma, concludes that it is of reflex origin, in the majority of cases, originating in a disorder of a mucous membrane, the skin, or the viscera. If taken early it is generally curable; the older the child, the smaller the chances of recovery. The influence of heredity is also very great; the absence of asthma in the family history greatly increases the likelihood of cure. The period at which asthma is most common in children is between the ages of 5 and 10 years. A case is related [11 Aug.,'94] in which marked asthma was due to the presence, in the posterior nares, of a button three-fourths of an inch in diameter.

Speaking of the failures in the treatment of reflex asthma, Louis E. Blair, of Albany, [59 Aug.18,'94] states that they are mainly due to the fact that, after the removal of local causes of disturbance, the operator fails to restore the tone of the weakened nerve-centres and to thus antagonize the "habit of asthma" gradually acquired by the patient. After placing the respiratory region in the best possible position for the proper performance of its physiological functions, an early and earnest effort should be made to build up the strength by adequate internal medication, appropriate food, and especially out-of-door exercise. To arrest the paroxysms of asthma, Laborde, of Paris, [81 Mar.31,'94] recommends his method of rhythmic tractions of the tongue. The organ being held between the fingers,—the latter having previously been covered with a napkin, to prevent slipping,—it is drawn out, at regular intervals, eighteen to twenty times per minute, imitating the respiratory rhythm.

The subject of reflex asthma is reviewed by Courtade, of Paris, [24 May 20,'94] several cases being reported.

Epilepsy.—T. J. Harris, of New York, [1018 No.1,'94] reports a case of epilepsy occurring as the result of a blow received upon the nose. The vomer had been fractured, the perpendicular plate of the ethmoid was distorted, and the cartilaginous septum dislocated. The right nasal cavity was thereby completely occluded. The epileptic attacks ceased when the nasal lesions had been corrected by means of surgical procedures.

Torticollis.—C. H. Knight, of New York, [814 Mar.15,'94] reports a case in which torticollis followed the removal of adenoid vegetations with the curette. Twenty hours after the operation it was noticed that the patient, a girl aged 9 years, carried her head with the face toward the right shoulder, and it was found that she was unable to move it back. She began to improve within twenty-four hours, and in the course of ten days the rigidity of the head and the traces of the operation had disappeared. Knight ascribes the complication to a lesion of the nerve-filaments in the nasal mucous membrane, resulting in a reflex irritation of the muscular fibres engaged in the rotation of the head.

Psychoses.—J. Hutchinson, of London, [806 Jan.,'94] cites the case of a woman in whom there existed an alternation between attacks of coryza and melancholia. When in the latter condition she never takes cold and seldom needs a handkerchief. As soon as her normal mental state returns, however, she is frequently attacked with coryza, and the first sign of the latter indicates the disappearance of the depression.

Glycosuria.—Bayer [118 No.15,'94; 9 May 19] reported a case of occlusion of the nares, attended with various trophic disorders and with glycosuria, in which the symptoms disappeared after the removal of the nasal obstruction. The occurrence of the glycosuria is ascribed to the diminished oxidation and the circulatory disturbance resulting from interference with respiration and to a reflex effect upon the medulla oblongata.

Cutaneous Disorders.—In a study of the influence of intranasal conditions upon the external affections of the nose D. Bryson Delavan, of New York, concludes [814 Jan.,'94] that (1) intrinsic nasal disorders are capable of exerting a decided influence upon certain external conditions of that organ; (2) that in a few instances, at

least, the external condition depends largely, if not entirely, upon intrinsic influences; (3) that, while in some cases the extrinsic condition may depend largely upon general causes, or causes not immediately associated with intrinsic exciting conditions, nevertheless the extraordinary activity of the nasal circulation, together with the existence of special nasal irritation, may exert a decided influence upon the extrinsic condition of the nose; (4) in the latter case, while general treatment of the extrinsic condition must be mainly relied upon, relief of the internal condition by means of local treatment will materially assist in effecting a cure. A review of the principal diseases of the skin that especially affect the nose—rosacea, erysipelas, seborrhœa, rhinoscleroma, lupus, and epithelioma—was published by G. T. Jackson, of New York.[814] Jan.,'94

Felix Semon, of London,[11] Mar.,'94 presented before the London Laryngological Society an exceedingly interesting case of alopecia, which had followed symptoms of incomplete Graves's disease, occurring as a result of operative procedures in the nose. The patient, a clergyman aged 39 years, had been shown to the Clinical Society of London on April 12, 1889, when exophthalmos of the right eye with Gräfe's and Stellwag's symptoms had developed after repeated operations (by means of the snare and galvanocautery) for removal of recurrent nasal polypi from both nostrils. In the discussion which followed the paper doubt was expressed as to the causal connection of the symptoms last named with the operation, especially as neither enlargement of the thyroid gland nor cardiac symptoms had then occurred. Shortly after the demonstration, however, it was noticed that the pulse-rate, which had been normal until then, had increased to over 100, and ever since it had varied between 100 and 110. There had been no heart palpitations, and the thyroid gland had not increased in size. The patient in 1889 left for India. On his return in the spring of 1893 the exophthalmos had somewhat decreased, but the pulse-rate, on the average, was still about 100, and complete baldness—extending over both sides of the head—had developed shortly after the patient left Europe. The hair had also come off from other parts of the body. In what relation, if any, this alopecia stood to the symptoms formerly observed seemed quite obscure. The patient, whilst abroad, had not suffered from any other disease which could produce alopecia. Treatment by feeding with thy-

roid glands, which was tried at the patient's own suggestion, had not yielded any results.

Ophthalmic and Aural Disorders.—Norval H. Pierce, of Chicago, [61 Nov.18,'93] describes two cases in which a marked difference in the relative size of the pupils was found to be due to nasal disorders. In the first case the left pupil was twice the size of the right. The middle turbinated body of the same side was found to present a localized hypertrophic mass pressing against the septum. Upon this growth being removed with the snare, the pupillary dilation was greatly reduced. During the process of resolution the congestion caused momentary pressure against the septum and return of the abnormal dilation. As the resolution progressed, however, this pupillary reaction improved and finally became normal. The second case presented much the same sequence of events, only that the pupil remained somewhat larger than its mate. The same author reports a case in which a constant pain in the right half of the tongue was permanently relieved by cauterization of a large hypertrophy of the inferior turbinated body of the same side. M. L. Foster, of New York, [2165 Jan.,'94] reports the case of a woman, aged 31 years, in whom asthenopia was relieved by cauterization of an hypertrophied turbinated body which also pressed against the septum. Cresswell Baber [11 Mar.,'94] mentioned the case of a man, aged 26 years, in whom, after removal of polypi with the cold snare, diplopia occurred on looking to the right, with want of power of the right external rectus. The ocular symptoms disappeared in about six weeks under the administration of perchloride of mercury and iodide of potassium. Numerous small growths were subsequently removed, but there was no return of the ocular disturbance. He stated that he had had a similar attack when operated on with forceps two years previously. There was marked erection of the inferior turbinated bodies. R. S. Charsley [11 Mar.,'94] observed marked enlargement of the glands in the neck and protrusion of eyeballs, lasting for a period of three months, after operation for removal of a turbinated body with the galvano-cautery. The pulse had ranged as high as 110, but complete recovery ensued. The influence of intra-nasal disease in producing ocular disorders through implication of the lachrymal ducts was studied by E. L. Parker, of Charleston, S. C., [43 July,'94] and Tacquet, of Paris. [2031 '94] In an interesting article sup-

ported by practical evidence, Sargent F. Snow, of Syracuse, N. Y., [59 Aug.18,'94] insists upon the influence of contact between the septum and turbinated bodies in the production of middle-ear troubles.

ACCESSORY CAVITIES.

Empyema of the Antrum.—Holger Mygind, of Copenhagen, [11 Jan.,'94] considers that the question as to what phenomena the transillumination of the healthy antrum produces has not as yet received the attention it deserves, and that this is necessary before a correct estimate of its diagnostic value can be obtained. He therefore examined two hundred individuals in whom antral disease could be excluded with the greatest certainty possible. They belonged to both sexes and their ages varied from 2 to 76 years. The conclusion arrived at is that the non-illumination of the eye cannot at present be considered as being of decisive diagnostic value, as stated by Davidsohn; since it cannot only be caused by pus in the antrum, but also by conditions not pathological. Among these are the thickness and consistency of the bones of the face and of the antral mucous membrane, the dimensions and shape of the antral cavity and the amount of adipose tissue within the orbits, while the physical conditions of the bulbus oculi itself is, in all probability, an element capable of modifying the results obtained. The value of transillumination as a positive diagnostic means would seem, then, to depend upon the question as to whether the illumination of the eye is a reliable sign of the absence of pus. This can only be determined by thorough examination of a large number of cases of empyema. If the pus should always prevent penetration of the light from the mouth to the eye, the method could be considered as a thoroughly reliable one in empyema of the antrum. G. W. Caldwell, of New York, [1 Nov.4,'93] establishes a difference in the transmission of rays according to the character of the tissues present. Turbid fluid pus and polypoid degeneration of the mucosa and solid tumors give shade; large mucous polypi concentrate light and increase brilliancy.

Herzfeld, [2170 B.4,'94] after numerous experiments in healthy and diseased individuals, concludes (1) that unilateral lighting of the face or pupil does not exclude the possibility of the presence of pus in the antrum; (2) that both pupils may remain dark without a conclusion being warranted, as this also occurs in healthy sub-

jects; (3) that the lighting up of one pupil may serve as collateral evidence only when other symptoms point toward the presence of empyema. Garel, of Lyons, [11 Aug., '94] considers transillumination as an adjuvant to other means of diagnosis, and draws the following conclusions: 1. Electrical illumination by transparence is the best supplementary proof when we suspect the existence of an empyema of the maxillary sinus from the ordinary symptoms complained of by the patient. 2. The absence of subjective luminous perception on the affected side established by our method fixes definitely the diagnosis, if there remain any doubts in the appreciation of the opacity of the cheek. 3. The proof of the existence of pus by exploratory puncture through the inferior meatus then becomes useless for the confirmation of the diagnosis. 4. This proof is ordinarily obtained, in the majority of cases, by means of simple irrigation through the natural orifice of the sinus. Burger, of Amsterdam, [136 Jan. 1, '94] indorses Davidsohn's method, but contends that luminous sensations of the eyeball are far more distinctive tests than illumination, as a very feeble light suffices to excite the subjective sensation.

Gradenigo, of Turin, [11 July, '94] in a series of 103 cases of diseases of the upper air-tract, found empyema of the antrum 17 times,—*i.e.*, 18 per cent.,—while a second series showed a proportion of 26 per cent. He therefore concludes that this disease is more frequent than is usually thought. He establishes a distinction between muco-purulent "collections" in the antrum and true empyema, owing to the absence of any causative lesion and the frequency of bilateral involvement in the former, which he attributes more to a nasal than to a dental origin. He found cysts, containing serum or pus, in the antra of 2 per cent. of the cases examined.

Acute inflammation of the antrum following influenza received considerable attention owing to an interesting article by Semon, of London, [2 Feb. 2, '94] in which he related a personal experience. An attack of influenza lasting but a couple of days had left a very general and rather severe catarrh of the air-passages. Three weeks later, while in Berlin, a sensation of fullness suddenly appeared and increased to a sense of intolerable distension of the zygomatic region. The skin over the part became distinctly swollen and reddened and tender to the touch. Temperature, 100.5° F. (38.1° C.). There was no frontal neuralgia. After these symptoms had lasted twenty-

four hours a violent blowing of the nose brought away an ounce (31 grammes) of turbid, greenish, sero-purulent fluid, followed by more of the same on lowering the head inclined to the right. A few hours after this more of the same fluid escaped. Later on a third escape took place. The acute complication now subsided, although two days later another discharge of greenish fluid of a mucoid character took place, which signalized the end of the affection. The author refers to the rarity of an acute affection as compared with the acknowledged frequency of the more chronic condition. Usually the acute type is met with after influenza, and is invariably recovered from. The points worthy of attention are: (1) the sudden and violent increase in pain during sneezing or coughing; (2) the limitation of the pain to the affected region, and, finally, the tendency of influenza to single out the locality of its sequelæ in the most capricious manner in different individuals, this being supported by the fact that the author's first attack had been followed by an equally-violent inflammation of the pulp of a previously-healthy canine tooth, which his dentists after extraction found to be almost gangrenous. In both attacks, therefore, the sequelæ had occurred in the domain of the fifth nerve. Cases of the same kind were reported by M. C. Moxham, $_{\text{Feb.24,'94}}^{2}$ R. J. Ryle, $_{\text{Mar.17,'94}}^{2}$ Lennox Browne, $_{\text{Mar.31,'94}}^{2}$ Rolland, $_{\text{Apr.29,'94}}^{188}$ and Todd. $_{\text{July 21,'94}}^{2}$

An interesting discussion $_{\text{Nov.10,'94}}^{1}$ took place at the Annual Meeting of American Laryngological Association after the reading of a paper by Daly, of Pittsburgh, $_{\text{p.566,'94}}^{1}$ in which he recommends early intervention and a small exploratory opening, for purposes of diagnosis, just above the second bicuspid tooth, the drill-head being made to perforate what partitions the lower part of the antrum might present. The cheek covers the opening, though not perfectly. De Roaldes, of New Orleans, had found but little difficulty in washing out the antrum through the natural opening. If an artificial one were necessary it should be relatively large, he thought. Brown preferred to make the opening low down between the roots of the teeth, and thus go through a portion of the alveolus itself and enter the antrum through the floor, enlarging the opening, if necessary. The drainage-tube should be removed early, as its prolonged use keeps up the discharge. Irrigation through the natural opening is feasible, but tiresome. J. H. Bryan, of Washington, pleads for conservative surgery. A diagnostic opening could be

made through the middle or inferior meatus, according to the method of Moritz Schmidt. For irrigation only the mildest solutions should be used. Schields had often found that the discharge would cease after the tube was removed. Casselberry believed that antrum disease rarely exists alone. Other cavities are also affected at the same time, which suppurate, and so prolong the case. Hence, even drainage of the maxillary sinus can never cure these cases. J. N. Mackenzie preferred to gain entrance through a tooth-socket, the great advantage being that it secured perfect drainage. It could easily be plugged. Roe advocated injections through the natural passages at first, and, if necessary, through the socket of a carious tooth; if the latter were sound, through the zygoma. Garel, of Lyons, [11 Aug.,'94] concludes that: 1. Irrigation by the natural orifice is at the same time the most expeditious therapeutic method, and the first that ought to be tried. Cure is obtained often in less than a week. 2. In the choice of method it is useless to try to penetrate by the most dependent part, because, as statistics show, cases which resist irrigation by the natural orifice are equally rebellious to irrigation practiced through artificial orifices in the most dependent parts. 3. When catheterization by the natural orifice is impossible, we must have recourse to an artificial opening to enable the patient to irrigate for himself as may be required for several months. In this case our choice must be fixed on the inferior meatus. 4. Alveolar perforation ought only to be thought of in the last instance, when we cannot use the other methods except in the infrequent cases in which the extraction of a tooth imposes itself before any other intervention. 5. Lastly, opening by the canine fossa and curetting are to be reserved exclusively for rebellious cases which have resisted all treatment by irrigation. 6. As regards the nature of the liquid to be employed, boric acid suffices in all cases. E. Harrison Griffin, of New York, [59 Mar.31,'94] prefers to make an opening through the alveolus. After thorough cleansing the cavity is packed with iodoform gauze. As to injections the author prefers solutions of peroxide of hydrogen, from one-fifth to one-half strength, and, in some cases, full-strength solutions. After the injection a lotion of iodoform suspended in albolin-oil (10 grains to 1 ounce—0.65 gramme to 31 grammes) is syringed into the part. This forms a covering of iodoform all over the lining membrane of the antrum, and rapid improvement fol-

lows. The parts should always be kept well open until all signs of purulency have disappeared.

M. Lermoyez, of Paris, [87 Jan.,'94; 5 May] criticises the evacuation of the antrum through the natural passage, because the opening is deeply concealed behind the inferior lip of the hiatus. Even though the beak of a syringe be successfully engaged within the orifice it would be extremely difficult to push it on into the cavity of the sinus, inasmuch as the ostium forms a canal directed from above downward and from behind forward,—a direction exactly opposite to that of an instrument which has been placed in the middle meatus. Furthermore, the antrum cannot be thoroughly washed out even when the cannula has been inserted, because the passage is too narrow to admit of the discharge of gummous pus; and it has so happened that observers have extracted large masses of congealed pus by way of a large alveolar opening, when lavage by the natural orifice had extruded nothing but the liquid injected returned slightly turbid. Puncture through the middle meatus is objected to as not only being at too high a level, but as exposing the orbit to the risk of penetration. Puncture through the lower meatus is objected to because the necessary ablutions are very painful and cannot be executed by the patient. The alveolar puncture is deemed preferable in all cases except where it is necessary to scrape the sinus, and then the sinus should be entered from the canine fossa.

Bauer, of Nuremberg, [136 Oct.1,'94] reported a case of traumatic suppuration of the antrum, and Fromaget [87 Aug.,'94] a case in which iritis presented itself as a sequel of antral empyema. Good reviews were published by Capdepont, [2031 '94] Mermod, [197 Aug.20,'94] Lichtwitz, [14 Oct.26,'93] R. Levy, of Denver, Col., [1099 Sept.,'94] and M. H. Fletcher, of Cincinnati. [61 Dec.20,'93]

Tumors of the Antrum.—Charles McBurney, of New York, [96 Feb.,'94] presented a woman, 53 years of age, from whom, in November, 1890, he had removed a malignant tumor of the left upper jaw, which had caused the cheek to project prominently. The skin was discolored from tension. The left hard palate had entirely softened so that a needle could be thrust through it at any point. The left nostril was full of vascular, readily-bleeding tissue, and there was more or less prominence beneath and external to the malar bone, showing that the disease extended well out in that direction. The diagnosis was osteosarcoma of the upper jaw.

The growth was exposed by an incision along the nose, through the lip, and under the eye. The disease proved to be so extensive that the incisions were necessarily very free. The whole left upper jaw was removed, together with most of the bony floor of the orbit. The diseased tissue extended beneath the malar bone and a considerable distance beyond it. All recognizable diseased tissue was removed. Recovery from the operation, however, was excellent, and the patient had remained absolutely free from any sign of recurrence. The tumor was examined and pronounced to be an osteosarcoma of the round-celled variety. Curiously enough, the patient, who was treated for a long time by a specialist for ordinary polypi of the nose, has recently developed an ordinary mucous polypus in the other nostril. R. C. Myles $_{\text{Sept.6,'94}}^{59}$ also reported a case of sarcoma of the antrum in which a part of the sinus, the pterygoid process, and the pterygoid muscles had been removed two months before. An exploratory operation for diagnostic purposes is strongly advocated. There were ordinarily very few symptoms, and hence, at first, these cases were apt to be obscure. He thought that, if diagnosticated sufficiently early, all of them would recover. W. L. Rodman, of Louisville, $_{\text{Dec.16,'93}}^{224}$ also reported a case.

De Roaldes, of New Orleans, $_{\text{Nov.17,'94}}^{1}$ described a case of follicular odontoma involving the right antrum and obstructing the corresponding nasal cavity; Otto Umgren, $_{\text{V.2,No.5,'94}}^{1180}$ a cyst; John Dunn, of Richmond, $_{\text{Sept.,'94}}^{81}$ a mucocele; and H. W. Loeb, of St. Louis, a polypus of the antrum. The latter form of growth, uncomplicated with empyema, in this location is rare; in this instance a polypus was also found in the antrum of the opposite side.

Foreign Bodies in the Antrum.—Ziem, of Dantzig, $_{\text{Sept.,'94}}^{37}$ recalled two cases in which cannulæ were broken off immediately above the alveolar opening. In both cases he used a snare wire, withdrawing the fragments as a cord is withdrawn from the interior of a bottle. Combe, of Paris, $_{\text{June,'94}}^{37}$ described a case in which a drainage-tube, which had been put in a dental alveolus, had become lost. In spite of enlargement of the alveolus, no foreign body could be found in the antrum. Four years after, the tube, measuring two centimetres, was spontaneously eliminated through the nasal passages. It was covered with sticky, black matter and calcareous incrustations. Raugé $_{\text{June,'94}}^{37}$ observed a similar case.

Moure records the case of an individual operated upon for empyema of the sinus, who, in order to remove a piece of food, pushed a match through the alveolar opening. This broke and one piece remained in the antrum. The foreign body was extracted through the canine fossa, aided by an injection through the alveolar opening. A. Yerwant, of Padova, [624 June,'94] relates a case in which a laminaria inserted by a dentist broke at the alveolar opening and remained in the antrum for six years, causing marked purulent rhinorrhœa of the corresponding side. It presented itself at the alveolar aperture and was withdrawn with forceps.

Empyema of the Frontal Sinus.—M. P. Mayo Collier, of London, [6 Jan.27,'94] observed a case of acute abscess of the frontal sinus simulating orbital cellulitis. The patient complained of severe pain and swelling in the left orbit. The eyeball was displaced downward and outward, and there was inflammation of the parts around the eye. The nasal passages were the seat of chronic obstruction. Pus was evacuated from the swelling by incision, and a small hole just behind the trochlea was detected by means of a fine probe. This opening, which led into a suppurating and denuded frontal sinus, was enlarged and made to communicate freely with the nose. A case of the same kind, but complicated with necrosis, was reported by C. Ramage, of Manchester. [6 Mar.10,'94]

Fatal cases of frontal empyema are reported by James Nichols [2165 Jan.,'94] and J. Hoppe. [779 Nov.,'93] The former's patient was a woman, 20 years old, who had suffered from cephalalgia and nasal obstruction three years. There was marked exophthalmos, ectropion, and keratitis ulcerosa, besides fistulæ opening immediately below the supraorbital arch. The nasal cavities were found to contain numerous mucous polypi; these were removed and irrigation ordered. The patient having died of pneumonia, it was found that the ethmoidal cells and the orbits formed but one large cavity. Hoppe's case was attributed to necrotic teeth, involvement of the antrum, the frontal sinus in turn, destruction and absorption of surrounding bone, and meningitis.

Lichtwitz, of Bordeaux, [37 T.10,No.8] cured a case by local injections of antiseptic solutions, continued one year, making, with Schutter's case, two on record thus successfully treated. G. Martin, of Bordeaux, [188 May 6,'94] adds further evidence to the value of persistent effort in this direction. In his case, however, a few months were

sufficient, notwithstanding the presence of very marked objective symptoms. Solutions of iodoform in glycerin, in ether, of nitrate of silver, and of carbolic acid were successively employed. After thorough irrigation of the cavity with an antiseptic solution, either one of the above was injected by means of a cannula. Successful cases treated by trephining are reported by Lauenstein, of Hamburg [2171 '98]; Gallemaerts, of Brussels [868 Jan. 20, '94]; Quarry Silcock, of Paddington, Eng. [1077 Sept. 26, '94]; and Mayo Collier, of London. [11 Aug., '94] In the latter case the whole of the interior of the sinus was filled with polypi, which blocked it completely. These were removed and the surfaces bathed with a solution of chloride of zinc, 40 grains (2.60 grammes) to the ounce (31 grammes), and drainage through the nose instituted.

Empyema of the Ethmoidal Sinuses.—In an interesting paper Hajek, of Vienna, [57 May 12, '94] criticises the conclusions advanced by Grünwald, who reviewed twenty-eight cases found in the literature of the subject and added thereto thirty-two cases of his own. According to him, these conclusions are too general and the diagnoses are not based upon solid foundations. In six cases seen by Hajek, it was only after careful and prolonged study that he could locate, with certainty, the trouble in the ethmoidal cells; in four of the cases there was, moreover, concomitant empyema of other sinuses, leaving but two cases in which the ethmoidal sinuses alone were involved. He failed to understand that, in the face of Zuckerkandl's researches, observers, and especially Grünwald, should speak of caries of the ethmoidal necrosis as a frequently-met-with disorder. F. H. Bosworth, of New York, in a discussion before the American Congress of Physicians, [2139 '94] said that, when dealing with the ethmoidal cells when suppuration was present, the treatment should consist in breaking these cells down into one large cavity. Ethmoidal disease was the cause of a train of symptoms, such as a watery discharge from the nose, sneezing, neuralgia, asthenopia, etc. A very large proportion of cases of supposed acute rhinitis were probably instances of ethmoidal disease. As a general rule, where there was chronic inflammation of a mucous membrane within a closed cavity, the tendency was to abscess formation. He did not attach much importance to the use of the probe in diagnosis and depended chiefly on the appearances observed about the middle turbinated

body. He advocated the use of the Thudichum douche, one or two gallons of very hot saline water being passed through the nasal cavity at least twice daily. There was no danger of exciting ear trouble by this treatment if the patency of each nostril were tested previously, and if the stream of water were made to enter through whichever naris was found narrowed. After the occurrence of suppuration the cells should be uncapped by means of a snare, and then, with the dental burr, they should be broken down into one large cavity. It was often necessary to repeat the operation many times. In a case seen by Ruault, of Paris, [8 May 12, '94] the patient, a child of 8 years, had a fistula in the inner angle of the left eye, near the base of the nose and over the lachrymal sac. Drops of pus flowed from it. It had formed after an abscess resulting from scarlatina. The ethmoidal cells were curetted and a large orifice was made in the nasal fossæ, through which the pus escaped. Cure was rapidly obtained. Hicquet [1175 Jan. 15, '94] reports three cases treated successfully in the same way. Cases of empyema of the ethmoidal sinuses are also described by Milligan, of London, [11 Aug., '94]; Flatau, of Berlin, [41 June 26, '94]; C. C. Rice, of New York, [51 July, '94]; and Vergniaud. [136 Sept. 1, '94] G. W. Caldwell, of New York, contributes [1 Nov. 4, '93] an interesting paper upon the diagnosis of diseases of the accessory cavities, and states that the ethmoidal cells may be illuminated by a lamp pressed between the eyeball and the inner orbital wall.

Sphenoidal Sinus.—Ankindinoff [100 May 29, '94] studied six cases of empyema of this cavity which came under his care. In his opinion, lesion of the sphenoidal sinus alone is rare, complication in the direction of the ethmoidal, frontal, or maxillary sinuses being almost invariably present. A diagnosis without the introduction of the probe he considers as impossible. In a case seen by Sandford, of London, [2 May 12, '94] the abscess caused double optic neuritis and subsequent post-neuritic atrophy with complete blindness, about twenty-seven years before the patient's death. Betz, of Maïnz, [37 Nov., '94] treated an officer in whom the trouble was found to have been caused by the introduction, during a fit of sneezing, of a piece of straw two centimetres in length. The straw was found imbedded in the left sinus and withdrawn, this operation causing all symptoms to cease. Herzfeld, of Berlin, [11 July, '94] reported four cases, two of which were bilateral. In one of these there was

also suppuration of the maxillary antra; in the other there was, besides these, caries of the ethmoidal cells. In all four cases the anterior wall of the sphenoidal sinus was carious. In three cases a distinct swelling appeared close to the septum, which he considered important as a diagnostic point. He considered probing of the normal aperture rarely possible. In three of the cases there were severe headaches. In the discussion that followed Flatau said that, although he had seen twenty-six cases of empyema of the sphenoidal sinus in two years, only once had he seen it in connection with ozæna. Polypi seldom accompany it, but are more frequent when the ethmoid cells are affected. Perforation and formation of fistula are quite rare; still, without perforation, meningitis and sinus thrombosis can arise. In one case death occurred, with symptoms of meningitis, two days after the operation. The author supposed that the meningitis was latent, and only became manifest after the operation. Complications with disease of the other nasal sinuses, especially of the posterior ethmoidal cells, were common. The etiology was in many cases doubtful; in others the empyema followed the acute fevers, such as typhoid, influenza, erysipelas, and scarlatina.

After describing an interesting case, Dundas Grant, of London,[11] Aug.,'94 suggested that, when one finds a growth apparently arising from the middle turbinated body, but which it seems difficult or impossible to surround by means of a snare applied, as it would be, to the middle turbinated body, we have to suspect that the growth is situated on the anterior aspect of the body of the sphenoid. At the same time, the benefit derived from the removal of the enlargement of the middle turbinal, even when the disease is situated in the sphenoidal sinus, is explicable by the greater freedom for the escape of the discharge from the latter. It will be remembered that the orifice of the sphenoidal sinus is situated behind and somewhat above the posterior extremity of the middle turbinated body; and when the latter is enlarged and when, at the same time, there are granulations growing from the front of the sphenoidal sinus, it is obvious that the orifice of the sinus may easily get blocked up, but that the removal of a swelling of the turbinated body may render the exit for such discharges considerably more easy. An excellent review of the subject of empyema of the sphenoidal sinus was published by Moure, of Bordeaux.[136] Oct.1,'98

DISEASES OF THE NASO-PHARYNX.

Tuberculosis of Naso-Pharynx.—Dmochowski, of Warsaw, examined [520 Nos.2,3,4,'94] the naso-pharynx of sixty-four subjects in which the cause of death had been tuberculosis, and found tuberculous lesions in the naso-pharynx twenty-one times. These were almost all in cases of acute miliary tuberculosis. The bacilli had first determined superficial lesions, then deep ones, finally appearing in the form of tubercles disseminated in the lymphatic tissues.

Lermoyez, of Paris, [3 July 28,'94; 2 Sept.22] called attention to what he considered to be an hitherto-undescribed variety of post-nasal growths. Last year he had under observation two children who, after the removal of adenoid vegetations under normal circumstances, wasted rapidly. More recently he had seen a girl, who had suffered from similar growths since infancy, in whom the removal of the vegetations was the starting-point of pulmonary tuberculosis, which ran a subacute course. In this case, infection by the instrument used being excluded, there remained only two possible explanations of the occurrence: either the operation had rekindled a latent pulmonary tuberculosis or else there were tuberculous foci in the vegetations themselves, and the operation had been the means of bringing about an auto-infection. The latter hypothesis was supported by another case, that of a boy suffering from complete obstruction of the nose caused by abundant adenoid vegetations. These were removed; recurrence, however, speedily took place, and the child began to show signs of cachexia. A second operation was performed, when microscopical examination proved that the supposed vegetations were composed of young, fully-organized tuberculous tissue in which no sign of degenerative change could be discovered; this condition, in short, was one of tuberculosis of the pharyngeal tonsil, infection having taken place from within outward by the blood-vessels. Such cases, the author admits, are extremely rare, but they are sufficient to show that a tuberculous variety of adenoid vegetations really exists. There is, so far as the author knows, no way of making a diagnosis except by removing a piece of growth for microscopical examination; but, inasmuch as this method may, like an incomplete operation, be the starting-point of infection, it is better not to have recourse to it. The possibility of such a condition should always be borne in mind when one has to deal with a case present-

ing the usual signs of adenoid vegetations in which there is a family history of tubercle. Operative treatment to be successful must be thorough; the *serre-nœud* or the galvano-caustic loop might with advantage be used in such cases. Medical treatment must not be neglected. Lermoyez recommends a course of "intensive chloride-of-sodium medication" as in the surgical tuberculosis of children. In the discussion which followed Marfan suggested that the facts reported by Lermoyez might equally well be explained by supposing that the patients were the subjects of latent pulmonary tuberculosis, and that sputum containing bacilli was the vehicle of infection, especially after operation. Chantemesse pointed out that one is not justified in pronouncing a tuberculosis to be endogenetic merely because the lesions are deep-seated; in Lermoyez's cases, therefore, the disease might have been exogenetic in spite of the microscopical appearances. Lermoyez, in reply, claimed to have shown that there is a tuberculous variety of post-nasal growths which simulate ordinary adenoid vegetations, and which, whatever may be their origin, may be the starting-point of general tuberculous infection.

Naso-Pharyngeal Tumors. — D'Aguanno, of Palermo, [11 Sept. '94] studied the retrogression, or spontaneous cure, of pharyngeal and naso-pharyngeal tumors, and reached the following conclusions: 1. The reduction, or spontaneous disappearance, such as may take place in tumors in general, may also occur in neoplasms of the pharynx and the naso-pharynx. 2. This retrogression may take place not only in benign tumors and adenoid vegetations, in which it is almost the rule, but also in neoplasms of a malignant nature, and especially in those very rich in vessels. 3. The retrogressive phase occurs most frequently, in addition to the cases of special parasitic infection, through alterations in the walls and contents of the vessels.

Fatal cases of sarcoma of the naso-pharynx were reported by Scheinmann, of Berlin, [36 Apr. 1, '94; 136 Sept. 15] and J. D. Paige, of Savannah. [99 v. 122, p. 645] The value of electrolysis in the treatment of these cases is illustrated by a case reported by J. Solis-Cohen, of Philadelphia. [9 v. 52, p. 545; 814 Mar. 1] The patient was a male, aged 23 years, who, for the past twelve years, had suffered from a tumor in the nose and pharynx, which bled upon the slightest touch. The case was first referred to surgeons for resection of the superior maxilla, so as to afford direct

access to the mass, but such a radical procedure was regarded as unjustifiable. Indirect methods through the nose and mouth could not sufficiently circumscribe the growth. As much of the latter was removed by the incandescent snare as possible, and then electrolysis was begun. The latter treatment was very difficult, but was persevered in. In all, between twenty or thirty sittings were held, the last one being in the latter part of June, 1893. The patient was seen again in October, and every vestige of the tumor had gone. No bad after-effects were noticeable except a band across the pharyngeal outlet of the left Eustachian tube, probably due to an adhesion between the soft palate and the vault of the pharynx,—a result of the operative procedures. This could easily be removed any time. Mermet, of Paris, [7 July 14, '94] removed a fibrosarcoma implanted upon the posterior end of the inferior turbinated bone. The ablation was easily performed with the finger. Zematzky [852 v.4, p.364, '94] successfully removed a chondrosarcoma from the vault by subhyoid pharyngotomy. There had been no recurrence when the case was reported (six months after the operation). A case of carcinoma of the vault was reported by Roncalli. [1105 v.1, p.169]

Wagnier, of Lille, [136 Nov. 15, '93; 451 July, '94] described three cases of large myxomata, or myxofibromata, of the naso-pharynx, which, by a process of kneading with the forefinger introduced into the naso-pharynx, were very considerably reduced in size. In the first case a very short kneading was followed by such a reduction in the volume of the tumor that it could be easily seized in the snare. In the second case, in which the tumor filled the naso-pharynx and descended to the free border of the soft palate, kneading so diminished its size that the writer was able to wind the pedicle about his forefinger and extract the growth. In the third case treatment was interrupted, after two short sittings, on account of an intercurrent malady. The growth, however, was left very much reduced in size. Many cases of these frequently-met-with growths were reported during the year, but none presented elements of sufficient interest to warrant special mention.

In a case reported by Annette E. Lamphear, of New York, [59 Aug. 4, '94] microscopical examination of a removed growth—a retention-cyst—showed both the inner and outer surfaces to be covered with stratified pavement epithelium. The cyst seemed to result from

adhesions between the lateral folds of an hypertrophied pharyngeal tonsil, its wall being formed by the complete closing in of the median fissure.

Adenoid Vegetations.—Beausoleil, of Bordeaux, [188 July 6,'94] contributes a case to prove that intellectual development is interfered with by the presence of adenoid vegetations. Régis [188 Aug.12,'94] does not believe that this is the case, but thinks that vegetations frequently co-exist with other malformations in imbecile and backward subjects,—an opinion in which he is supported by Moure. The latter author states that the imperfect hearing frequently met with as a result of adenoid vegetations often causes the patients to be wrongly considered as mentally weak. As regards physical development, however, proofs innumerable already established the influence of adenoid vegetations in this particular beyond the domain of speculation. Castex and Malherbe [14 Mar.4,'94; 2 June 9,'94] report observations on the rate of growth of children after removal of adenoid vegetations of the naso-pharynx. Measurements were taken before operation and at varying intervals after. In all, thirty-five cases were traced for three, six, nine, or twelve months. The general conclusion drawn is that during some months after the operation the rate of growth, as estimated by increase of height, weight, and chest-measurement, was thrice the average rate as given in the statistical tables of Quételet for height and weight and of Pagliani for chest-girth. This conclusion was reached from averages calculated on the assumption that an increase noted in half a year would be half that which would occur in a year.

Independent analysis of the tables given by Castex and Malherbe shows that there were certainly great differences in the rates observed in different cases. Thus two boys, aged, respectively, 12 and 13 years, were examined after a year. In the former the increase in chest-girth was a little above the average, the increase in height practically the same as the average, and in weight a little below. In the other boy the increase in weight was slightly greater than the average, but in height thrice the average. In three girls the improvement was more distinct; in one aged 11 years the increase in weight and chest-girth was very considerably more than a third above the average, though the increase in height was less than the average. In a girl aged 12

years the increase in all three dimensions was more than a third (in chest-girth more than one-half) above the average. In a girl aged 15½ years the increase in chest-girth was more than four times the average (measurement made at mammary level), and the increase in height and in weight was about twice the average. In a girl aged 5½ years the increase in weight was distinctly below, that in height slightly above, the average. In three boys aged 12, 13, and 17 years, respectively, measured six months after operation, the weight and chest-girth had increased more in that period than in the average boy in a year; but in another boy, aged 14½ years, the increase in weight was only slightly greater than the average, and the increase in height and in girth was distinctly below the average. In four girls, aged, respectively, 10, 10, 12, and 17½ years, examined six months after the operation, the rate of increase in all three dimensions was very notably in excess of the average.

P. S. Jakins [11 v.7,No.9; 5 Mar.,'94] reported a remarkable instance in which a boy 5 feet 3½ inches in height at 17 years of age increased to 5 feet 10 inches within two years after the removal of adenoid vegetations and hypertrophied tonsils. The gain in weight was proportionately great. His brothers had attained a height of six feet before they were his age.

Grönbech, of Copenhagen, [373 No.10,'93; 673 May,'94] has examined the shape of the hard palate in 77 cases of adenoid vegetations and found it normal in only 10 cases. In 67 cases (87 per cent.) there was some abnormality, and in 10 the palate exhibited signs of rickety deformity. In the remaining 55 patients an abnormal increase of the palatine arch was observed, a section through it forming either a polygon or a Gothic arch; there was also very often a decrease of the distance between the right and the left alveolar process, and an irregularity in the position of the teeth, especially in front. In all these cases the interior maxilla presented a normal appearance, —a circumstance on which the author lays great stress, as it is a proof that the abnormality of the upper jaw in the 55 cases was not of rickety origin, but caused by deficient development of the nasal cavity, the normal pressure of the septum decreasing in intensity. The oral breathing has, according to the author's view, also some influence on the development of the deformity, the air of expiration pressing against the palate of the infant, thus

augmenting the size of the vault. (Report of Corr. Editor Holger Mygind, Copenhagen, Denmark.)

The subject of choice of an anæsthetic for removal of adenoids was carefully treated by Siegmund Moritz, of Manchester, [90 Aug.,'94] in a general review. Wyatt Wingrave, [2 Sept.22,'93] who has administered anæsthetics for tonsillotomy and removal of adenoids upward of eleven hundred times, states that in about 90 per cent. of these cases he gave nitrous-oxide gas alone, administered through a modified Clover gas and ether inhaler, the patient being in a sitting posture and a mouth-prop being inserted before applying the face-piece. The whole operation was usually completed in less than forty seconds. The supplementary administration of a few whiffs of ether was not always satisfactory as it increased the struggling and bleeding. In less than twelve cases a second administration of gas was required. He warns against the use of chloroform in these operations and collates five cases of death under chloroform for removal of adenoids, recorded in the *British Medical Journal* and *Lancet* since May, 1892. He remarks that the use of gas was prompted more "by humanitarian" reasons than with the object of combating serious pain. Moritz has latterly employed the plan of Wroblewski, of Warsaw. [1151 v.1,p.802,'94] This author either paints the parts to be operated upon with a solution of antipyrin (2 parts), cocaine (1 part), and water to 10 parts; or, better still, paints with a 10-per-cent. cocaine solution, and injects a few minutes after in two or three places, under the mucous membrane in each place, 2 minims (0.13 gramme) of a 50-per-cent. antipyrin solution. Wroblewski was able to remove in this way, painlessly, lamellæ of a deviated nasal septum, operations which lasted half an hour; and the author confirms Wroblewski's statement, that not only tonsils and adenoid vegetations may in this way be removed without pain, but that there is no pain afterward.

G. H. Bailey, of London, [6 Jan.18,'94; 11 Mar.] recommends for the shorter cases "gasalene," continued, if necessary, with a whiff of ether. For others the preliminary gas, then ether to the full anæsthetization of the patient, followed by chloroform administered by Junker's inhaler. Where general anæsthesia is indicated for the removal of adenoids, attention might also again be drawn to bromide of ethyl, recommended by Hollaender at the Berlin Inter-

national Medical Congress. Unfortunately, several deaths have been recorded, but Hollaender and others ascribe these to the use of an impure preparation, as, until recently, it was somewhat difficult to obtain the pure drug,—"ethyl-bromide," C_2H_5Br,—owing to the frequent admixture of ethylene-bromide,—$C_2H_4Br_2$, a very poisonous drug. Hollaender administers ethyl-bromide with an Esmarch chloroform-inhaler, holding it close over the mouth and nose to exclude air, and continually dropping the fluid on until anæsthesia is established, which takes place in thirty to forty seconds, and frequently in ten to twenty seconds. The anæsthesia so obtained is not complete, but is sufficient for small operations. The corneal reflex is not abolished, and it is not advisable to wait for its abolition, but only until the uplifted arm falls powerlessly down. Hollaender then at once proceeds to operate; the anæsthesia lasts two to three minutes, and the patient is fully awake in another minute. The pulse remains unaltered; it sometimes becomes even fuller; the pupils are not influenced; vomiting, a stage of excitement, headache, and other bad effects are said to be rare. From 1 to 3 drachms (4 to 12 grammes) of the drug are usually sufficient for an administration. A slow or continued administration of large doses causes considerable excitation and prevents a narcosis altogether. Though bromide of ethyl is said not to influence the heart, it should not be administered to patients with heart disease. Schmidt also recommends this drug for anæsthesia in removal of adenoids and tonsils, but he finds that he usually requires a larger quantity of the anæsthetic. He has never seen any serious after-effects; but vomiting, he says, takes place occasionally. He therefore prefers to operate early in the morning, and not to give solid food previous to the operation. Schmidt also mentions that frequently the mouth is tightly closed, through contraction of the masseter muscles, so that a gag becomes requisite. E. Meyer $_{\text{Jan.1,'94}}^{4}$ used it without accident in two hundred cases. He pours the entire quantity to be used, 10 to 20 grammes (2½ to 5 drachms), upon the inhaler, anæsthesia being obtained in twenty-five to fifty seconds, after a slight phase of excitement.

Wilhelm Meyer, of Copenhagen, $_{\text{Sept.10,'94}}^{996}$ states that in the Mongolian race adenoid vegetations may more or less be observed according to latitude. They are most frequently found in cold

regions. T. K. Hamilton, of Adelaide, $^{11}_{\text{Nov.,'93}}$ states that adenoids are very common in South Australia and that he had seen as many cases from inland dry regions as from the coast. Injudicious feeding is looked upon as an important cause. Huber, of New York, $^{51}_{\text{Jan.,'94}}$ reports six cases in nurslings under 6 months old, one of these being but 1 month of age.

D. Bryson Delavan, of New York, $^{19}_{\text{Aug.11,'94}}$ in reply to the question "Do adenoid vegetations disappear if left to themselves, leaving the vault in a normal, healthy condition?" says that, generally speaking, they do not. 1. The enlargement may not subside, and a degree of hypertrophy sufficient to cause serious injury and annoyance may continue to exist for many years. In this connection the so-called "Tornwaldt's disease" appears to be nothing more than neglected adenoid hypertrophy. 2. Disappearance of the hypertrophy may be attended with an atrophic condition of the vault of the pharynx, the result of which is a pathological state detrimental to the patient and difficult to cure. 3. The above conditions may influence not only the locality in which they arise, but may have far-reaching and disastrous effect upon other organs. The ultimate prognosis as to the local condition, therefore, in cases of neglected adenoid hypertrophy is unfavorable.

Guément $^{780}_{\text{Jan.,'94}}$ concludes that the presence of adenoid vegetations is not always a concomitant of enlarged tonsils, but that the growths induce the development of the latter. He substantiates his position by clinical evidence, and cites cases in which the removal of the post-nasal neoplasms caused the reduction of the enlarged tonsils.

At a meeting of the Laryngological Society of London, $^{2}_{\text{Apr.21,'94}}$ Semon, of London, objected strongly to the induction of complete anæsthesia when adenoids were to be removed. The anæsthetic should always be given slowly until the ocular reflex was abolished, but the cough reflex, the last to cease, should remain, as after its abolition nothing could prevent the entrance of blood into the larynx and trachea. The discussion indicated great diversity as regards the best agent to employ. W. G. Holloway, of London, $^{2}_{\text{Jan.13,'94}}$ and R. H. Wood, of Dublin, $^{22}_{\text{Aug.1,'94}}$ make an earnest plea in favor of the use of nitrous-oxide gas in these cases; they substantiate the views of Lennox Browne and Dundas Grant as

to its absolute safety, especially when compared with that offered by chloroform, which caused two deaths in adenoid cases during the year. Grant Morris [2] and Dykes Bower [2] recommend chloroform, owing to the opportunity given the operator for a complete operation.

In a paper upon the choice of operation for the removal of adenoid vegetations, Chiari, of Vienna, [8; 451] based his conclusions upon 233 cases seen in private practice and 152 seen at his clinic. The majority of the cases were under 20 years of age; 16 patients were over 30, but 14 had rather small growths. In 1 patient, aged 46, the adenoids covered the posterior nares. This patient had asthma, which disappeared after the removal of the adenoids. The etiology is obscure. There are often slight signs of scrofulosis, but often strong, healthy children have adenoids, to which, in some cases, there seems to be an hereditary predisposition. Posterior rhinoscopy was successfully employed in 206 of the private patients. The method of treatment was almost always removed by cold-wire snare introduced through the nose and controlled by means of posterior rhinoscopy. Other instruments used in the hospital were the Gottstein knife, Löwenberg and Michael forceps, Trautmann's curette, and the wire snare introduced through the mouth. Before operation through the nose the nares are cocainized. Bleeding is slight; pain is absent or insignificant. Of 163 private cases operated on solely by the snare, 66 were cured in one sitting, 56 in two, 33 in three, 7 in four or five, and 1 in nine. In 24 cases the method had no, or only partial, results, due to narrow nostrils. Two children of 3 years of age, two of 4, eleven of 5, five of 6, and twelve of 7 years of age were easily operated on by this method. This procedure is absolutely free from danger, causes slight bleeding, is followed by no reaction, is free from pain, and can be applied under cocaine anæsthesia. C. W. Richardson, of New York, [61] considers the finger-nail the most satisfactory instrument for the removal of adenoids, which are sufficiently soft to yield readily. Rapidity, precision, intelligent use of the tactile sense, and comparative freedom from hæmorrhage are the advantages claimed in favor of the method, which is also strongly advocated by Guillaume [37] and P. Macleod Yearsley, of London. [2] P. J. Gibbons, of Syracuse, N. Y., [1] presents an adenotome, a new instrument

based upon the tonsil guillotine, for the purpose of removing adenoid growths.

Two cases of fatal hæmorrhage after removal of adenoid vegetations were reported during the year. J. E. Newcomb, of New York, $\frac{5}{\text{Nov.,'98}}$ after enumerating the various sequelæ of the operation,—(1) bronchitis from inhaled blood; (2) septic bronchitis; (3) suppurative otitis media; (4) hæmorrhage,—describes a case in which he operated on a healthy child, 3 years and 9 months of age, under an anæsthetic, for post-nasal growth. In four hours after the operation hæmorrhage set in; assistance was not sent for until twelve hours later, and the child died one-half hour after, the lungs evidently containing much blood. No post-mortem was performed. In Barkan's case $\frac{147}{\text{V.2,p.118,}}$; $\frac{9}{\text{Apr.14,'94}}$ the child was a strumous boy, 6 years old, who presented considerable enlargement of the faucial and pharyngeal tonsils. He was a constant mouth-breather and experienced great respiratory difficulty during sleep; the voice was altered, but hearing was not impaired. The mother of the child also had enlarged tonsils. The right and then the left tonsil were successively removed with the guillotine. There was a more profuse hæmorrhage than usual, though not enough to interfere with the immediate removal of a large pharyngeal tonsil by means of a Gottstein curette. The bleeding was copious, but soon subsided. One-half hour after the operation the child was sent home with his father, and instructions were given to keep him quiet and give him iced milk and liquids. Several hours later, after nausea and restlessness, the child vomited a large amount of clotted blood. On examination of the throat no bleeding-point could be detected; neither was there hæmorrhage from the naso-pharynx. Three hours later, after a period of excitement and restlessness, the boy cried and coughed a good deal, bringing on an attack of vomiting, large clots of bright-red blood being ejected, and clear blood flowing from the mouth and nose at the same time. The child now appeared moribund. Several injections of whisky were made, a large enema of warm salt water was administered, bottles of hot water were applied, and milk and whisky were given. It was now determined to etherize the boy and cauterize the exposed surfaces with a thermocautery, and this was accordingly done. After the operation and the child had recovered, it was noticed that blood was trickling from the nose. An attempt was made to

examine the throat to determine the source of hæmorrhage, but the child resisted. During the struggles, a sudden gush of blood took place, accompanied by a peculiar sound as if blood had found its way into the trachea. The child gave a gasp and ceased breathing, and all attempts at revival proved fruitless.

MISCELLANEOUS.

Diagnosis.—Sandmann, of Berlin, $\frac{11}{\text{Feb.,'94}}$ contributes a graphic method of ascertaining the degree of breathing-space afforded by the nasal cavities. As is well known, when the nose is pressed against a pane of glass the warm breath forms a deposit of condensed vapor upon the glass, giving a "pneumotype" or breath-picture of the nasal respiration. The method, therefore, is simply to have the patient breathe, without effort, upon a piece of cold glass, and the extent of condensation of moisture tells the tale. A normal nose makes two heart-shaped figures upon the glass, that barely touch in the centre or that are parted by a dry line, when the glass is held vertically just touching the end of the nose. If the glass is held horizontally, touching the upper lip, the figures are larger and more butterfly-shaped. With complete obstruction of one side only half of the figure is seen; lines of contact between spurs and turbinated bodies may divide the figure transversely on the side where they are situated or swollen turbinated bodies may leave but half of it, but an exact diagnosis of what produces the obstruction cannot be made. It demonstrates the extent of the nasal stenosis, nothing else. The great drawback in this experiment is that the figures produced are of too transient a nature, and it is desirable to adopt a process by which they may be fixed and made permanent, in order to compare them before and after operation. After many experiments he adopted the following plan: Pieces of pasteboard are covered over with slate-paper. The plate is held vertically against the point of the nose, the patient is asked to breathe upon it, and before the breath evaporates from the surface a fine powder is blown upon it through a pulverizer. Pure pulverized sulphur is excellent for this purpose, but powdered boric acid or similar substances may be used. The superfluous powder is easily shaken or knocked off, and there is left a well-marked figure of the breath,—a "pneumotype." This is then fixed with a spray of varnish, such as painters

use for fixing chalk-drawings (a spirit solution of shellac). It may be applied with an atomizer.

A plate illustrating the shapes obtained in six patients is appended: *A.* Both nostrils free. *B.* A nasal spur on the right side; operated upon. A small spur is still standing; swelling of the left turbinated. Treated with caustics. *C.* Nasal spur and swelling of left turbinated bone. Right nostril free. *D.* Hypertrophy of the lower turbinated bones, right and left. *E.* A case of chronic rhinitis. *F.* An S-shaped deviation of the septum on a level with the (swollen) turbinated bone and the left lower turbinated. Division and deviation of the air-current. The illustrations are about one-fourth of the size of the originals.

Anæsthetics.—Wroblewski [520 No. 41, '93; 673 Aug., '94] has employed antipyrin with great success as a local anæsthetic, injecting from 3 to 6 grains (0.2 to 0.39 gramme) in 50-per-cent. solution into the tissue to be operated upon. Complete anæsthesia occurred in from ten to fifteen minutes and lasted from eight to twelve hours; so that the patients were free from pain for some time after operation. He has used antipyrin in scores of cases, as in removing tonsils, scraping tubercular growths in the larynx, cauterizing granulations in the posterior portion of the pharynx, etc., and has never had any unpleasant results. (Report of Corr. Editor Szadek, Kiew.)

G. Wilkinson, of Omaha, [61 Nov. 25, '93] in view of the numerous and disastrous cases of cocaine habit which have fallen under his notice, suggests that medical men should unite to combat promptly and vigorously this growing evil, and to secure legislative bars to the vending of such preparations. George C. Stout, of Philadelphia, publishes [119 May 26, June 2, '94] interesting cases showing some of its deleterious effects.

SOFT PALATE AND UVULA.

Anatomy and Physiology.—Seifert, of Würtzburg, [136 No. 4, '94] reports a unilateral instance of separate investiture of the palatoglossus muscle of the left side which he has recently observed in a man 20 years of age. A good wood-cut shows the tonsil through the slit in the palatine fold. A number of reported cases are collated. In a case recorded by H. D. Hamilton, of Montreal, [282 Apr., '94] in a man aged 25 years, the anterior pillars of the fauces presented two longitudinal slits, or fissures, the left being slightly the larger, and measuring one-half inch in length by about three-sixteenths

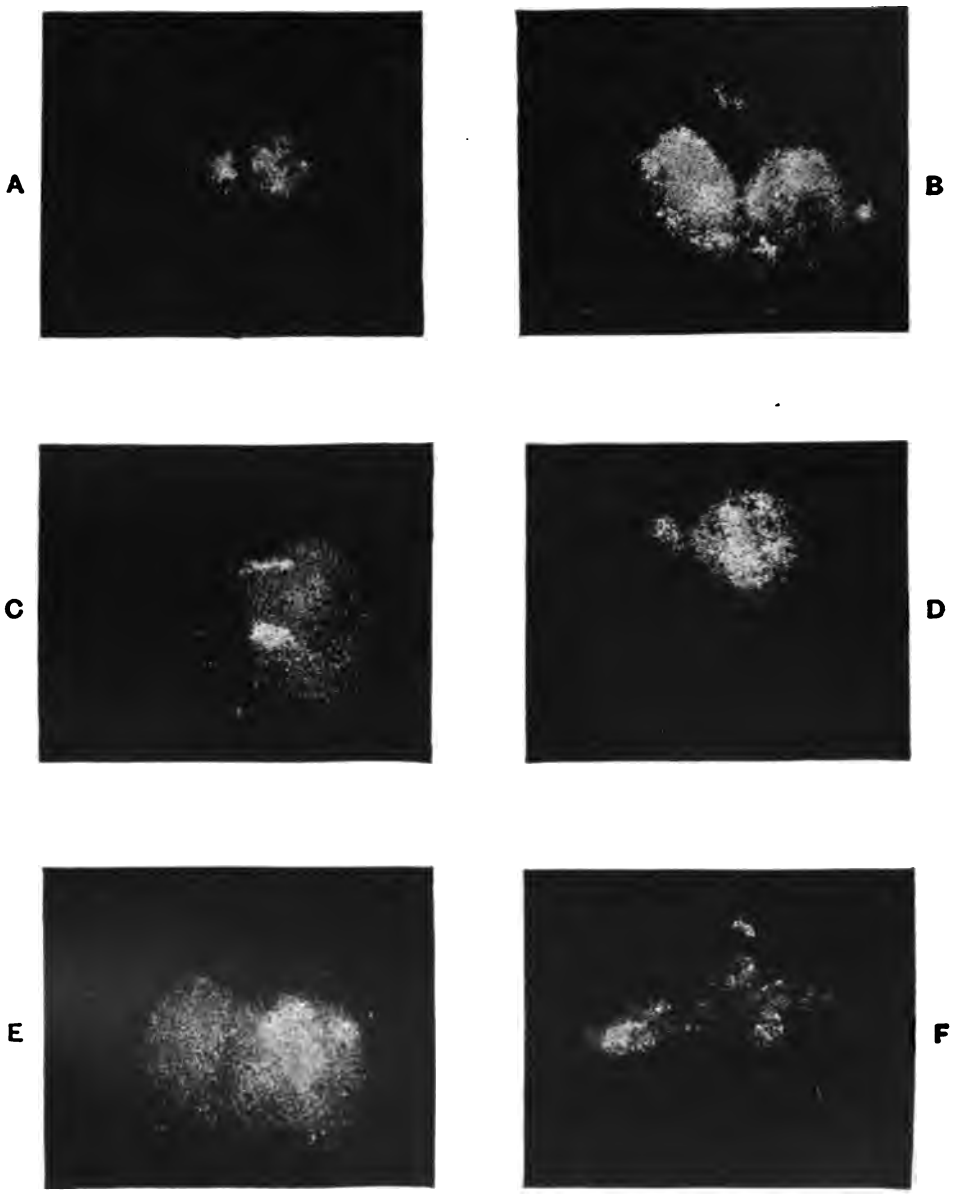

Autograms of Nasal Respiration (Sandmann).

Journal of Laryngology

inch in width at the widest part. The openings are of a somewhat oval form, extending down to the sides of the base of the tongue. Garel, of Lyons, [3 May 12, '94] reports two cases of anomaly of the pillars. In the one there was symmetrical congenital perforation on both sides, causing slight impediment in deglutition; in the other the perforation was unilateral and on the left side. He disagrees with Fowler and Morrice, who thought that these perforations were due to phlegmonous processes, such as those occurring in tonsillitis, scarlatina, and diphtheria, and ascribes them, with Testut, to embryonic resorption.

Neuroses.—Lecocq, of Mons, [37 Aug., '94] reported the cases of two girls, aged from 18 to 20 years, robust and in good health, without previous history of disease, whose nasal voice and difficulty in deglutition made him think, in the first instance, of paralysis of the soft palate. This paralysis was complete, bilateral, and, in addition, was accompanied by absolute anæsthesia. The affection came on gradually several weeks before without any perceptible inflammatory lesion, and, indeed, diphtheria could not be appealed to in these cases. The facial nerve, in its passage through the petrous bone, gives off motor branches for the palatal muscles. Its responsibility could not be accepted either, because there was no paralysis of the muscles of the face. There was no mesocephalic or bulbar affection to which these symptoms of paralysis could be attributed. Lecocq concluded that it was an essential paralysis of the palate. The affection is little recognized in medical literature, but it is explained, following the works of certain French authors, by neuritis starting in the small nerve-branches themselves, without there being any inflammatory extension coming from neighboring organs. He prescribed internal medication, purgatives, and strychnine, without any result; and the employment of continuous currents, both weak and powerful, had no better effect. The interrupted current, on the other hand, succeeded surprisingly, and from the first sitting improved the deglutition and the voice. From this moment the cure proceeded rapidly, and has continued up to the present.

Tumors.—Several cases of *epithelioma* of the soft palate were reported during the year. In the case operated upon by Cleveland, of Philadelphia, [9 Apr. 28, '94] although a considerable portion of the velum was removed, no difference in enunciation could be detected.

No recurrence had taken place a year after the operation. Faguet and Cabannes, of Bordeaux, [188 Jan.14,'94] described a case in which the growth appeared nine years after the removal of a labial cancroid. In an inoperable case seen by Watson Williams, [11 Apr.,'94] an attempt was made to arrest the growth by the inoculation of pure cultures of the streptococcus erysipelatosus, but without success. Cases of *sarcoma* are reported by Carmelo Gustinelli, of Florence, [1167 Aug.,'94] and Eisenmenger, of Vienna. [801 B.89,H.1,2]

Scanes Spicer, of London, [11 Apr.,'94] reported a case of *papilloma* of the uvula. The patient, A. H., aged 15, complained of tickling in the throat, which led to irritating cough and "spasm" of the throat. These symptoms had been noticed three months. On examination a papillomatous, pedunculated mass, the size of a pea, was seen to be attached to a somewhat elongated uvula. The latter was shortened and all symptoms disappeared. A case of epithelioma of the uvula and the left palatine arch was described by Schiffers. [11 Jan.,'94]

Palatal Calculus.—C. A. Parker [11 Mar.,'94] removed a calculus from the right side of the soft palate, the site of which looked like, and had been taken for, a large ulcer. The parts were much swollen and inflamed and felt exceedingly hard. Great soreness was experienced, especially during deglutition, while sharp pain shot into the ear. The stone weighed 55 grains (3.56 grammes). It was hard, but easily crushed, and dissolved, for the most part, in hydrochloric acid; the insoluble remainder consisted of epithelial *débris*, spores, and gladothrix mycelium.

A new uvulatome was described by Samuel Goldstein, [59 Sept.3,'94] working on the principle of the Mathieu tonsillotome. A. H. Cleveland, of Philadelphia, [9 May 26,'94] devised a palate which seems to present advantageous points.

LINGUAL TONSIL.

Hypertrophy.—Casadesus, of Barcelona, [207 Oct.,'94] reports the case of a man, aged 39 years, in whom hypertrophy of the lingual tonsil gave rise to nocturnal attacks of asthma. There was cough and a subjective sensation of foreign body in the throat. The hypertrophied lingual tonsil was found to touch the anterior surface of the epiglottis. The author looked upon this contact as a cause of the asthma, because the condition was cured by treating the

hypertrophied mass with the galvano-cautery. Villecourt [100] observed the case of a woman, 30 years of age, in whom intense inspiratory dyspnœa suddenly appeared, followed by cyanosis on the following day. She experienced the sensation of a foreign body in the throat, which gave rise to frequent deglutition and copious sialorrhœa. The right arm appeared heavy, motion was difficult, the cutaneous sensitiveness obtunded, and the electrical contractility of the muscles diminished. Examination of the throat revealed the presence, at the base of the tongue, of two symmetrical growths, each the size of a bean and surrounded by disseminated granulations. The application of perchloride of iron caused the local trouble to improve by the third day; on the eighth all the peripheral disorders had disappeared. Seifert also reported a case of the kind some years ago. [4] Good reviews of the inflammatory disorders of the lingual tonsil were published by Marion [2081] and by Simanovski. [586]

Abscess.—Mounier, [37] in reporting two cases, expresses the opinion that abscess of the lingual tonsil may pass unperceived by reason of its slight gravity and the slight inflammatory appearances in the pharynx, to which may easily be attributed all the symptoms. Prognosis ought, however, to be guarded, having regard to the proximity to the larynx and possible œdema glottis. In case of respiratory trouble the abscess ought to be largely opened with the galvano-cautery.

Tumors.—Rueda, of Madrid, [918] reports a *retention-cyst* observed in a woman aged 25 years. The sensation suggesting the presence of a foreign body and the frequent deglutition usually observed in growths located in this region constituted, in this case, the main subjective symptoms. The tumor was opened and galvano-cautery utilized to destroy the sac. Onodi [136] reports a case of *fibrosarcoma.* He only found two similar cases in literature,—an evidence of its rarity. The diagnosis was confirmed by the microscope, but the patient, a girl aged 17 years, refused to submit to a radical operation.

PHARYNX.

Anatomy.—In a paper upon the innervation of the pharynx Réthi, of Vienna, [1006] states that, after exposing the muscles and nerves in narcotized animals and electrically stimulating the

nerves, he found that the motor fibres of the stylopharyngeus muscle pass over into the vagus-trunk while still within the foramen jugulaire and pass to their destination as branches of the pharyngeus vagi. The levator veli palatini is innervated from the lower fibres of the middle root-bundle. In their peripheral course these fibres maintain their union with the vagus, passing out as the upper twig of the pharyngeus vagi. They are not associated with the accessorius, as stated by Beevor and Horsley. The nerves for the constrictors of the throat arise in the middle root-bundle and pass out in the pharyngeus vagi. Those for the palato-pharyngeus constitute the middle part of the lower division of the same ramus, while those for the palatoglossus pass out in its upper division. The studies were made on dogs, cats, rabbits, monkeys, etc.

Membranous Pharyngitis.—Wm. C. Glasgow, of St. Louis, reports $_{\text{No.880,'94}}^{1}$ a case, in a child aged 10 months, which he considered as one of the protean manifestations of influenza. After an unusual exposure to cold the attack began with a febrile otalgia of two days' duration, followed by febrile coryza, with copious discharge of acrid mucus, excoriative to all cutaneous tissues with which it came in contact. Then an exudation became developed on the tonsils, uvula, soft palate, and pharynx; but none was visible in the anterior nares. There was aphonia and urgent dyspnœa; so that the larynx was in all probability involved also. Under constitutional treatment with sodium benzoate, salol, and brandy, and the topical use of hydrogen dioxide with boroglyceride, convalescence was markedly rapid and complete, being only slightly interrupted by a suppurative otitis. Veillon $^{2031}_{\text{'94}}$ found the same microbes in the various forms of angina,—*i.e.*, the catarrhal, phlegmonous, and pseudomembranous. The streptococcus, the pneumococcus, and the staphylococcus. The streptococcus is the most virulent and the principal factor of these inflammations. The variety of anginas is the result of the different localization of the microbe and the degree of virulence exhibited. The streptococcus of angina is similar to the microbe of erysipelas and of suppuration. Sendziak $_{\text{July,'94}}^{87}$ states that histologically the false membrane is the same as that caused by the Lœffler bacillus. Brandenberg $_{\text{Oct.15,'93}}^{214}$ found the oïdium albicans in two cases. Réthi, of Vienna, $_{\text{No.1,'94}}^{84}$ observed little round epithelial

plaques upon the soft palate and the tonsils in patients affected with influenza. The plaques persisted for some days and then disappeared. He believes them to be thickened portions of the epithelium. In a discussion at Heidelberg, before the South Germany Laryngological Society, $\frac{84}{\text{June 26,'94}}$; $\frac{1}{\text{Aug. 25,'94}}$ Helbing called attention to the good effects obtained in phlegmonous pharyngitis by frictions of the upper part of the neck with croton-oil. These effects had been particularly noticeable in relapsing phlegmonous pharyngitis, provided the patient himself made the frictions as soon as he felt any pain in the pharynx. The effect was perceptible as early as on the second day. The speaker said it was necessary that the oil should be freshly prepared and of the proper color; under these conditions it would not cause an eruption. Sacki had witnessed the efficacy of one or two drops of croton-oil applied by friction at the level of the angle of the lower jaw. Faber had never used croton-oil in these cases, but he had used a concentrated solution of iodine and obtained results quite as satisfactory. Seifert had tried croton-oil, but without the least success. Bauer stated that relapsing attacks of phlegmonous angina could be avoided by removing the tonsils or by cauterizing them with trichloracetic acid, the galvanic cautery, or some other cauterizing agent. Kahreitz thought that phlegmonous angina was due to a local infection, and that it should be treated locally with antiseptics and disinfectants. Bresgen maintained that the relapse was often due to a concomitant suppuration of the nasal passages, and that this suppuration should be the chief subject of treatment. Finally, Schmidt had seen no effect from croton-oil further than rebellious eczemas, without the least action upon the disease of the pharynx. Perrin, of the French army, $\frac{243}{\text{p.245,'93}}$ describes a form of membranous pharyngitis which soldiers bring about in their own throats to obtain leaves of absence, by applying cantharidal powder to the mucous surfaces.

Syphilis of the Pharynx.—W. K. Simpson, of New York, described $\frac{814}{\text{May 15,'94}}$ a case in which the ulceration began one month after the initial lesion, spreading very rapidly to the naso-pharynx, down to the larynx. The soft palate was also involved, and this resulted in the loss of the uvula. The patient was reduced to extreme emaciation owing to his inability to swallow. The ulcerations and emaciation improved very rapidly as soon as deglutition

was established, and he was able to take the iodide of potassium; the highest dose administered was 25 grains (1.6 grammes) three times daily.

G. Monaco, of Buenos Ayres, [1050 Nov.,Dec.,'93] reports a case in which syphilitic stenosis of the pharynx was sufficiently grave to cause intense dyspnœa and necessitate tracheotomy. The cicatricial web was gradually dilated by means of the Mackenzie dilator and free respiration re-established. Lichtwitz, of Bordeaux, [87 Aug.,'94] observed a case in which the soft palate had become united to the pharynx, thus closing up the naso-pharyngeal isthmus. Dilatation by means of Béniqué's bougies—applied four times a week and one hour at each sitting—soon brought on free respiration; after this the sittings were farther apart. E. H. Griffin, of New York, [11 July,'94] advocates the use of a double-edged knife, curved on the flat. The edges of the wound made by it are cauterized and a pair of dilators used for some time afterward. P. R. W. de Santi, of London, [6 June 22,'94] describes five cases showing the great value in tertiary syphilitic ulcers of the pharynx of a solution—20 grains (1.3 grammes) to the ounce (31 grammes)—of sulphate of copper,—an old remedy unfortunately overlooked in the search for new ones. J. H. Raymond, of Chicago, [61 Feb.24,'94] reports a case of diphtheroid chancre on the posterior wall of the pharynx and gives an excellent review of the subject.

Tuberculosis of the Pharynx.—Catti, of Fiume, [84 June 14,'94] proposes to call such cases of miliary tuberculosis in which the affection begins in the pharynx and larynx a pharyngo-laryngeal type analogous to the typhoid, the meningeal, the broncho-pneumonic, and the chronic types of the disease. The author has observed this form in two cases. Like the meningeal type, it occurs especially in children. The disease begins with more or less difficulty in swallowing. The uvula, soft palate, epiglottis, and aryepiglottic folds are seen to be swollen and œdematous, more or less red, showing in some cases small ecchymoses. There is also a profuse eruption of, in part, gray, transparent, miliary tubercles rising somewhat above the level of the mucous membrane, and, in part, yellow miliary tubercles just under the surface of the mucous membrane. Except for an hyperplasia of the lymph-glands of the neck and thorax and a markedly increased heart-beat, there are no other symptoms. The disease is very rare and may be easily mis-

taken for a diphtheritic affection of the larynx on account of the symptoms of stenosis.

Felix Semon, of London, [11 July, '94] showed a case before the Clinical Society of London in which pharyngeal ulceration had resisted treatment by scraping and the use of lactic acid, which had completely arrested the apparently similar disease in the larynx. Examinations of scrapings from the pharyngeal ulcers had recently failed to show the presence of tubercle. The ulceration had healed of itself, and the patient stated that it had done so before; hence its exact nature was still doubtful. Creasote had been given internally in large doses, and much of the success of the case was attributed to its constant use. Clifford Beale quoted the experience of the Chest Hospital practice, where creasote had been given very freely both in large and small doses, and also in concentrated vapor. It appeared to be singularly well borne by the delicate stomachs of tuberculous patients, but there was as yet no positive evidence to show that in the cases of rapid and active disease any marked effects were produced.

Rheumatic Pharyngo-Tonsillitis.—In an elaborate article Roos, of Kiel, [4 June 16, 25, '94; 2 July 28] thoroughly reviews the subject and relates several cases. The disease may present itself as a prodromal symptom of acute rheumatism, the latter being, in all probability, an infective process, the actual cause of which, the author thinks, may gain access through the faucial mucous membrane. Rheumatic pharyngitis he considers, however, as not very common. Pain on swallowing, swelling and redness of the fauces, especially of one or both tonsils, with or without suppuration, the occasional presence of a purulent deposit on the tonsils, and the relatively long duration of the affection are to be noted. Former rheumatism will assist in the diagnosis. This rheumatic angina will probably explain the presence of valvular lesions in some cases in which there is no history of rheumatism. Correct diagnosis is important, as the salicylates rapidly cut short the disease and perhaps prevent the articular affection. Rheumatic angina cannot at present be distinguished from other forms of angina. Articular rheumatism may appear after the follicular form. It is possible that after certain anginas the infection may involve the joints (polyarthritis anginosa). This polyarthritis after angina sometimes differs from rheumatism by reacting badly to the salicylates

and by its long duration. In this it resembles the polyarthritis seen after scarlet fever and diphtheria. The author thinks that a number of these cases of polyarthritis after angina will resolve themselves into examples of infective processes when the etiology is better known. He refers to cases in which etiologically the disease should be looked upon as pyæmic and yet no suppuration occurs in the affected points. Here the micro-organisms may have lost their virulence (modified pyæmia). It appears strange that after suppuration in a tonsil a simple polyarthritis should occur. The author then refers to the researches of Sahli in respect to the causation of rheumatism by the staphylococcus. He concludes that either the angina preceding the polyarthritis is rheumatic or that after certain forms of angina a pseudorheumatic affection may occur, with localization in the joints or serous membranes. There is much to favor this latter view.

Auclair [14 Feb. 15, '94; 11 Apr.] states that pharyngitis can be observed in the great majority of cases of acute rheumatism; in general it appears two or three days before articular manifestations—sometimes, but more rarely, in the course of the disease. This angina is characterized by some diffuse redness of the margin of the soft palate, the tonsils, and the posterior part of the pharynx; now and then an œdematous tumefaction of the uvula or other part of the mucous membrane is present. This redness and inflammation extends over the whole of the fauces or is confined to one side. Dysphagia, pain in the ears, and difficulty of speech exist, as in other forms of angina. These symptoms diminish as soon as the articular manifestation appears, but the pain and the redness decrease slowly during seven or ten days. Generally the intensity of the pharyngitis is proportionate to the gravity of the general disease.

J. E. H. Nichols [1018 Oct., '93; 11 Feb., '94] divides the affection into the following forms: (*a*) myalgia pharyngitis,—no affection of mucous membrane, only of muscles of pharynx and anterior cervical region; (*b*) chronic hypertrophic pharyngitis,—may have acute exacerbations; (*c*) acute catarrhal pharyngitis; (*d*) pharyngeal neurosis. Males suffer more frequently (five to three); all have rheumatism in family, or gout, affected by atmospheric changes. They all suffer with attacks of sharp, rasping pain in the pharynx, often in the salpingo-pharyngeal fold, and are relieved by salicylates. Re-

views and cases were published by Gouguenheim, of Paris [55 Feb.3,'94]; Natier, of Paris [62 July,'94]; and G. B. Richmond, of Salinas, Cal. [77 Sept.,'94]

Tumors of the Pharynx.—Eisenmenger, of Vienna, [8 Nov.22,'93] reported four cases of lymphosarcoma, all ending fatally. In spite of this, however, he does not agree with Kundrat, that lymphosarcoma is always fatal, and recommends energetic treatment by means of arsenic, having seen a case cured by this means. Two cases, both ending fatally, were described by Koschier, of Vienna, [136 May 15,'94] and Montaz. [895 July,'94; 11 Nov.,'94] Weiss, of Nancy, [31 June 22,'94] thinks that operative measures are warranted in carcinoma of the pharynx when the neoplasm is clearly limited to the palatine and tonsillar regions and when the retro-angular glands, though enlarged, are still movable. When, however, the carcinomatous mass itself and the glands are adherent to surrounding parts and immovable, and especially when the chain following the carotid is involved, the case should be considered as inoperable. Krönlein [214 Aug.1,'94] showed a patient before the Central Switzerland Society from whom he had removed, seven years before, the pharynx, tonsils, and tongue for carcinoma. The man, aged 63 years, was in perfect health and his speech and deglutition were normal. R. H. Woods, of Richmond, Eng., [22 Nov.1,'93] successfully removed a cancer of the posterior wall of the pharynx by subhyoid pharyngotomy. The difficulties which have caused this operation to be condemned—(1) insufficient room, (2) the possible reflex spasm—were not experienced by him. The gaping was sufficient to allow the greatest freedom of manipulation and a perfect view of the operation, while there was no trouble from local movement or coughing.

Avellis [680 Oct.10,'93; 814 Mar.1,'94] reports the case of a newly-born female child in whom suffocation was imminent. Inspection of the pharynx showed, lying on the upper part of the surface of the tongue, a pale-reddish tumor which filled up the space between the root of the tongue and the soft palate up to a little fold on the right side. The uvula was wanting and the soft palate was fissured posteriorly. In inspiration the mass was drawn down toward the larynx. After the tumor had been drawn forward by the forceps, this attachment was seen to be in the general region of the left tonsil. It was removed by the galvano-cautery snare without hæmorrhage. Immediately all untoward symptoms began to disappear, and the

child was soon in a comfortable condition. On the next day two small bits were further removed from the same region. Full recovery then ensued, but death resulted three weeks later from influenza-bronchitis. Diagnosis, from microscopical examination, was teratoma (rudimentary parasitic fœtus).

Pharyngo-Mycosis.—Fletcher Ingals, of Chicago, $_{\text{Sept.1,'94}}^{1}$ in an analysis of twelve cases treated by him, found that in 58 per cent. of these the patients had for many years suffered more or less from sore throat, and in 66 per cent. soreness of the throat had been present from four to eight weeks immediately preceding the discovery of the mycosis. Symptoms of dyspepsia were present in three cases, or 25 per cent., but in 50 per cent. of the cases it was distinctly stated that the patient was in general good health. The treatment had been to burn off the growth and to pass an electrode, heated to a bright-red heat, about one-eighth of an inch into the tissue beneath it. Two or three patches were cauterized at each sitting, and the operation was repeated at intervals of about five days, according to the patient's convenience, two or three days being allowed to elapse between the disappearance of the soreness caused by one cauterization and the repetition of the operation. The author believes that, in some cases, the disease had existed for many years before it was discovered; but in most of the patients he had seen it had apparently been of only a few weeks' duration. From his experience in two of the cases he believed that the disease might sometimes disappear under natural causes. H. M. Thomas, of Chicago, $_{\text{Jan.6,'94}}^{59}$ also considers that galvano-cautery affords the most efficient means of cure. This may be advantageously followed by the use of a saturated boric-acid solution for a mouth-wash. Gargles alone are useless, for they can only affect the tops of the dendritic masses. A cure necessitates the destruction of the seat of the growth. Wagnier, of Lille, $_{\text{June,'94}}^{37}$ adds two more cases to those reported last, in which cure followed the application of chromic acid in rebellious pharyngo-mycosis. Cases of pharyngo-mycosis were reported by James Wood, of Brooklyn $_{\text{Oct.7,'93}}^{9}$; Max Stern $_{\text{May 1,'94}}^{136}$; T. K. Hamilton, of Adelaide $_{\text{June 15,'94}}^{267}$; John Dunn, of Richmond $_{\text{July 28,'94}}^{1}$; C. E. Bean, of St. Paul $_{\text{Aug.18,'94}}^{1}$; Bresgen, of Frankfort $^{2172}_{\text{'94}}$; and M. Percepied, of Rouen. $_{\text{Jan.1,'94}}^{203}$ Lesin $_{\text{No.10,'94}}^{586}$ described a case in which meningeal actinomycosis complicated the pharyngeal form. It began in the

right tonsil and extended to the meninges through the blood-current. A marked symptom in the case was a temporo-maxillary ankylosis, due in all probability to the formation of cicatricial tissue in the cellular tissue surrounding the maxillary muscles.

Retropharyngeal Abscess.—Manchot, of Hamburg, $^{14}_{\text{Dec.17,'93}}$ describes the case of a diabetic who suddenly experienced severe pain in the neck, accompanied by marked typhoid symptoms. Seven days later the spleen became enlarged and petechiæ appeared, confirming the diagnosis of typhoid fever. On the tenth day the patient died in collapsus. Autopsy showed absolutely normal intestines, while cultures from the spleen revealed numerous colonies of staphylococcus aureus. A vertical median section of the head and neck, however, demonstrated the true cause of the general disease,—*i.e.*, empyema of the sphenoidal sinus and retropharyngeal abscess. Barjon, of Lyons, $^{211}_{\text{Apr.1,'94}}$ observed a case of acute retropharyngeal abscess in which laryngeal œdema, double pneumonia, and abscess of the abdominal wall followed each other in quick succession. The author attributed these successive conditions to the primary localization of the pneumococcus in the pharynx. Aviragnet $^{118}_{\text{Oct.,'93}}$ reports a case in which, although the tumefaction did not apparently compromise the laryngeal lumen or open suddenly, death suddenly occurred. He ascribed this untoward result to pressure upon the nerves of the region.

Liebert $^{312}_{\text{No.12,'93}}$; $^{996}_{\text{Feb.26,'94}}$ treated a case in which the cause was traced to empyema of the antrum. The retropharyngeal abscess disappeared as soon as the empyema was operated upon.

Contrary to the teaching of Etienne, Watson Cheyne, Burkhardt, and Phocas, who prefer, for the child as well as the adult, opening through the neck, Rochard $^{1181}_{\text{Jan.18,'94}}$; $^{5}_{\text{July,'94}}$ advocates incision through the pharynx, and examines the objections which have been made to this plan of treatment. The hæmorrhage is always moderate when the incision is in the median line, and wounding of the displaced carotid would not be possible except when the abscess was not median, but to the side,—a condition demanding different treatment. The irruption of pus into the air-passages can be avoided, after incision, by rapidly turning the child's face downward. The difficulties in getting the mouth open and making the incision are easily overcome with a little patience. The principal objection remaining refers to the danger of local

infection, which has especially prompted operation by external incision. But, despite the proximity of a focus of infection like the buccal cavity, accidents (detachment, purulent infection) can scarcely be said to occur, so rapid in the child is the cure of a cold abscess opened at the proper time. Opening by way of the neck, on the other hand, requires a most delicate and dangerous operation, which should not be employed except when the abscess is prominent in the neck or when it is very large. H. W. Berg, of New York, [59, Apr. 28, '94] and Belliard [37, July 15, '94] concur with these views in interesting papers reporting cases. Comprehensive reviews were published by Revere H. Herrold, of Chicago [61, Jan. 20, '94]; Estrabault, of Paris [55, Feb. 24, '94]; and W. R. Townsend, of New York. [814, Apr. 15, '94]

Foreign Bodies in the Pharynx.—Of the many instances of this kind reported during the year, but one presents a certain degree of interest from the fact that it is, perhaps, the first time that a billiard-ball plays the part of foreign body. The patient died suddenly after placing it in his mouth. According to his physician, A. F. Voelcker, [2, Nov. 11, '93] the epiglottis was not depressed, but the ball lay over the upper opening of the larynx. All the organs were intensely congested.

Neuroses.—Landgraf, of Berlin, [11, Feb., '94] divides paræsthesia of the pharynx into three groups: 1. Hysterical and neurasthenic patients with but slight changes. 2. Changes are present in the pharynx, but their importance is not in proportion to the intensity of complaints. 3. Patients by no means of a nervous disposition, but who constantly complain about the same feeling in the pharynx. Landgraf observed three cases of the third variety which deserve particular mention. (*a*) A man, 45 years of age, complained of unpleasant sensations in the left palate, especially during ordinary swallowing. The tonsils, especially the upper parts, were hyperplastic. Where the palatine arches diverged a cavity about two millimetres wide, surrounded by a wall, was visible on both sides. Through this it was possible to penetrate to the median line and upward into a pouch. (*b*) A man, 25 years of age, with a similar complaint and a similar condition. Landgraf considered these changes to be tonsilla succenturiata. (*c*) A man, 27 years of age, complained of feeling a foreign body in the left part of the anterior palate. He found under the mucous membrane a movable body the size of a swollen lentil. In the

discussion that followed B. Fraenkel expressed his belief that cases *a* and *b* were branchial fistulæ.

In a paper upon pharyngo-laryngeal and nasal paræsthesia in neurasthenics, Botey, of Barcelona, [37, July, '94] concludes that paræsthesia of the pharynx, in these subjects, is almost always located on a level with the hyoid bone or the base of the posterior pillar. Scheimann, of Berlin, [41, July 5, '94] records a case of slight paresis of the right half of the soft palate and spasmodic contractions (160 per minute) of the left half of the pharynx and larynx, as a result of syphilis. The case is an especially interesting one, owing to the fact that, according to the author, all cases of pharyngeal spasm reported so far were bilateral. In his case the spasm includes the adductors during inspiration; during phonation it cannot be detected.

Reflex Neuroses.—Engelhardt, [2073, '93; 866, June, '94] in 200 individuals in apparently good health, found the pharyngeal reflex normal in 59 per cent., diminished in 17 per cent., and absent in 25 per cent.; the palatal reflex was found in 56 per cent., diminished in 18 per cent., and absent in 26 per cent. In 10 hysterical cases the pharyngeal reflex was constantly present in 7; in the others it was only obtainable upon strong irritation, and then not invariably. As diminution or absence of these reflexes is so frequent in healthy individuals, he supports the view that it cannot be regarded as an hysterical stigma. In none of the 10 cases of hysteria, some of them with considerable disturbance of sensation, was contraction of the visual field to be found.

Joal, of Mont Dore, [87, June, '94] records a case in which œsophageal spasm was combined with hypertrophy of the tonsil. It occurred in a neuropathic young woman in whom œsophagism was very marked; application of the galvano-cautery led to dysphagic accidents, and reduction of the tonsil was followed by cure. A second case was that of a young man attacked with intercostal neuralgia in the course of acute amygdalitis. The reflex origin of the neuralgia could not be doubted, since cauterization of the tonsil, performed afterward, cured the intercostal pains.

TONSILS.

Bacteriology.—A. Veillon, [457, Mar., '94] in an elaborate paper, reached the conclusions that pathogenic microbes may be found in all

forms of non-diphtheritic tonsillitis. The streptococcus pyogenes virulens was present in the twenty-four cases examined, and was usually associated with less virulent pneumococci and sometimes with staphylococci. In seven cases the streptococcus was alone present, and appears to play the most important rôle in all cases. The different kinds of tonsillitis, therefore, though appearing in individual forms, are, nevertheless, of the same nature. The clinical and anatomical differences depend upon (1) whether the organisms affect the surface of the mucous membrane, its deeper layers, or the subjacent cellular tissue, (2) the virulence of the microbes present and the resistance of the subject. E. Buys [1175 Nov.15,'98] also studied the subject in four cases. In the first the pneumococcus was abundantly found in the crypts, and the streptococcus about one-half as much so. A few days later a periamygdalitis appeared, the pus of which contained the streptococcus alone. In the second case he found the micrococcus salivarius pyogenes of Biondi; in the third and fourth, the staphylococcus pyogenes aureus. It is thus shown that, although a microbic origin may be accorded the various forms of tonsillitis, no special organism can be considered as specific in their pathogenesis.

The Tonsils and Remote Disorders.—Buschke, [301 B.38,H.4,5,'98] in a comprehensive article, describes several cases to show the connection between diseased tonsils and suppurative processes in the general system,—tuberculous adenitis, osteomyelitis, etc. Bacteriological examinations showed the presence of streptococci and staphylococci in the crypts of the tonsils and in the blood, as well as in the suppurating focus. The author concludes: 1. That the tonsils may be the points of entrance for pyogenic micro-organisms; it is not necessary that ulceration or diphtheria should prepare the way for lodgment and multiplication of germs. 2. On the basis of experimental investigations it is probable that the tonsils play an important rôle as a means of entrance for pus-producing micro-organisms, and certainly a more important one than the respiratory and alimentary tracts. Very probably the bacteria do not pass the tonsils without causing slight trouble, which, in the majority of cases, is unnoticed. The care of the mouth and throat is not only of local hygienic importance, but is also of value for the prevention of general disease.

H. L. Wagner, of San Francisco, [1 No.280,'98] studied the relation

between tonsillar disease and rheumatism. To the question whether these affections are produced by the germs (staphylococcus albus et aureus, Fraenkel's pneumococcus, etc.) migrating from the tonsillar tissues into other portions of the body, causing rheumatism, or whether they remain in and about the tonsils, sending forth and distributing their ptomaines or poisonous products into the system, he answers that his investigations have shown that a migration of these germs in follicular tonsillitis proves that rheumatism here is not caused directly by ptomaines. Clinical observations show that the joints which are mostly in use are the ones generally affected; for instance, the ary-cartilages of the larynx of singers (five cases), the knee-joints of shoe-dealers—owing to the constant kneeling posture (two cases), and the wrist-joints of violinists (one case) and book-keepers (two cases). Referring to the two cases above, where rheumatism of the knee-joint developed, the bacteriological investigation showed that the synovial fluid obtained by the tapping of the joint contained the same micro-organisms as found in the diseased tonsil. He was also able to identify the same germs in the urine of nearly all the cases. The family and clinical history of all these patients showed no signs of rheumatism before the attack of this tonsillar disease.

J. Hughlings Jackson [189 May,'94] points out that the close analogy which exists between acute tonsillitis and pneumonia is of interest, as cases of the former are not unknown after injuries, whether local or affecting the body generally. Wilson Fox pointed out "a similar intensity of rigor and prostration, a similar sudden invasion of pyrexia, and a similar rapid decline of this before the local inflammation has shown any signs of abatement." Further, there is an equal difficulty in verifying a distinct cause. Some evidence of this is afforded by the circumstance that many cases of quinsy are classified as "rheumatic,"—a term not infrequently suggesting that little or nothing definite is known about the origin. The tonsillar affection prevails epidemically, like pneumonia, and is associated apparently with certain atmospheric states. Individuals are liable to suffer from it repeatedly, and it is known that any cause which produces depression of the general health predisposes to it. As with pneumonia, there have been shown to be in relation with it certain micro-organisms that are found about the tonsil, and, still continuing the similarity, more than one form

has been isolated. The presence of streptococci and staphylococci has been reported, and these are not met with in the mouth and throat under apparently normal conditions or like Fraenkel's diplococcus. The tonsil which has already gone through an attack is, like the lung, more susceptible to this peculiar inflammation; and eventually slight causes, such as indigestion, exposure to cold during the menstrual period, etc., suffice to bring it on. Among these may be included falls and injuries, for he had known quinsy to come on after a fall in an individual who had suffered from former attacks, and it occurred even after trivial throat operations.

A. Thouvenet [1 May 5, '94] observed a case in which nephritis presented itself as a result of acute follicular tonsillitis in a woman aged 45 years. In ten days after the beginning of convalescence she had headache, attacks of vertigo, and intense dyspnœa. The *bruit de galop* was observed, the eyelids and the legs were œdematous, and the urine was highly albuminous. After a month of treatment the albuminuria disappeared, and thenceforward the patient remained well. The author is convinced that many cases of nephritis which are ascribed to cold are in reality consequent on attacks of inflammation of the tonsils which have been overlooked, and that sometimes the nephritis occurs after such an interval that the idea of any relation between the two morbid manifestations is lost sight of.

Garel, of Lyons, [673 Dec., '94] called attention to a form of pharyngitis symptomatic of diabetes or albuminuria. There is at first a slight difficulty in deglutition, a sensation of pressure in the throat, and a deposit of mucus which annoys the patient considerably. An examination of the throat shows the pillar of the fauces and the posterior portion of the pharynx to be reddened, the mucous membrane red, swollen, and frequently covered by a layer of glairy mucus. This condition of the membrane calls for an immediate examination of the urine, in which, in the majority of cases, sugar or albumin will be found. By examination of the throat only, it is impossible to say which of the diseases one has to do with, as most of the patients present but insignificant general symptoms. Joal, in 1882, attributed the same diagnostic value to dry pharyngitis, but recognized that in seven-eighths of the cases neither sugar nor albumin could be found in the urine. In the hyperæmic

form, however, the urine is rarely normal. The reporter had observed 21 cases of this form of angina,—10 with diabetes and 11 with albuminuria. In 3 of the cases the sugar and albumin alternated.

Coradeschi, of Sienna, [505 May 6,'94] described five cases illustrating the connection between inflammatory processes in the tonsils and typhoid fever, easily explained by the analogy of structure between these organs and Peyer's patches.

Follicular Tonsillitis.—Norris Wolfenden, of London, [11 Aug.,'94] studied the nature of follicular tonsillitis and inflammations of the throat due to micro-organisms, together with their relation to general infective disorders. He stated his belief that follicular tonsillitis was a desquamative process in the crypts of the tonsils, the follicles taking no part in the process and only exhibiting a secondary hypertrophy, as recently maintained by Sokolowski and others. He further showed that there were forms of infective tonsillitis associated with the exudation of fibrin, and the presence of streptococci, staphylococci, and pneumococci in such definite proportions as to suggest the inference that each specific organism was associated with characteristic clinical symptoms. Although many of these presented the clinical aspects of diphtheria, Lœffler's bacilli were wanting. He maintained that there was a lacunar tonsillitis and a lacunar diphtheria which could be differentiated only by a bacteriological investigation, since pseudomembranes, in all respects resembling diphtheria, might be produced by other organisms, and albuminuria with glandular enlargements and even paralysis might occur in non-diphtheritic cases. It was manifest therefore that clinical evidence was in itself inadequate for a diagnosis. The author expressed a doubt as to the possibility of contagion in non-diphtheritic tonsillitis. Sendziak, of Warsaw, [136 June,'94] states that histologically the lacunar products presented the same picture as those caused by the Lœffler bacillus, but that bacteriologically they were different.

Lermoyez, Helme, and Barbier, of Paris, [37 Aug.,'94] record a case of tonsillitis characterized by the presence of the bacillus coli, in a boy aged 17 years. The last relapse of a series of attacks left a chronic inflammation of both tonsils, which were hypertrophied and presented numerous white patches. Antiseptic gargles and cauterizations with pheno-sulpho-ricinic acid giving no result,

Lermoyez tried galvano-cauterization without effect. He removed the tonsils by *morcellement* and the cure obtained was final. The coli bacillus was found in the white patches and in the portion of the removed tonsil, their presence being verified by cultures. G. A. Leland, of Boston, [99 Oct.21,'98; 11 Dec.,'98] to prevent recurrence in cases prone to them, divides the tissues between the crypts by knife, scissors, and hooks, removing pieces of tissue and painting the surface with iodine and glycerin. This operation is frequently repeated, and, in the author's hands, is uniformly successful; it is especially of service when tonsillotomy is objected to. He describes two somewhat scythe-shaped knives, which are introduced at one and brought out at another crypt, cutting the tissue between.

Phlegmonous Tonsillitis.—B. F. Westbrook, of Brooklyn, described [1 No.288,'94] a unique case of multiple neuritis due to mental strain, in which, besides other manifestations of multiple neuritis, ulceration of the left tonsil presented itself. The local ulceration gradually spread to the palatine fold and to the base of the uvula above and to the pharyngo-epiglottic fold below. The membrane was crimson, indicating venous stasis. Antiseptics locally and antirheumatic remedies internally brought about recovery in four weeks. Jamsin [454 Dec.,'98] reports a case of phlegmonous tonsillitis in which gangrene occurred as a fatal complication.

Cartaz, of Paris, [421 No.2,'94] observed a case in which frequently-recurring abscesses led to the detection in the cavity of a chicken-bone, the extraction of which procured immediate recovery. The same author refers to another case of recurring abscess in which a fistula was found and freely opened, with successful results. A case of the same kind is reported by Klingel, of Elberfeld. [34 No.10,'98]

Gouguenheim, of Paris, [211 No.26,'94] recommends the following treatment in suppurating phlegmonous tonsillitis, after deprecating too hearty operative measures: 1. Against pharyngeal pain. Applications around the neck of Leiter's tubes (small lead tubes in which a circulation of cold water is maintained). If these fail, ice-bladders or leeches to the angle of the jaw; pharyngeal painting with a 20 to 33⅓-per-cent. solution of cocaine hydrochlorate. 2. Against adenitis. Cold poultices containing laudanum around the neck. 3. Against the local inflammation. Pharyngeal douches and nasal irrigations with warm boric-acid solution. 4.

As an intestinal antiseptic, particularly for preventing the effects of the ingestion of septic products. Naphthol or salol in a daily dose of 2 grammes (31 grains), taken dividedly and continued for several days. He admits surgical intervention only in exceptional cases,—the appearance of a whitish transparent spot revealing the purulent focus.

A valuable review of the subject was published by Babuel-Peyrissac, of Bordeaux, [2164] and by Gouguenheim and Ripault, of Paris, [37] who report five cases of peritonsillar abscess.

Tonsillitis.—Nothing worth reporting was published during the year upon uncomplicated tonsillitis. Many methods of treatment were advocated, practically all including remedies already well known. An exception was presented, however, by the paper of J. Harvey Raymond, of Chicago, [59] who states that he has employed guaiacol topically with great benefit. He recommends that it be applied in full strength to the tonsil by means of a cotton swab, care being taken not to let any run into the larynx. It sometimes causes a good deal of smarting, but the relief obtained more than compensates for this. In many cases a few applications, sometimes only two, are sufficient to abort the attack. The temperature falls shortly after the application. In one case it fell from 103.5° F. (39.8° C.) to normal in four hours. When the guaiacol is applied in a weaker form,—say, 50 per cent.,—it does not act so promptly nor effectively. Cocaine rather aggravates the smarting caused by the guaiacol. The throat may be kept moist by means of troches of althea, guaiac, or gargles.

Hypertrophy of the Tonsils.—Mandragora [1095] published a careful study of the indications for surgical procedures in hypertrophy of the tonsils. Amputation is warranted, according to him, when the enlargement is sufficiently great to interfere with respiration to any degree, or where there is predisposition to recurrences or alteration of the voice and hearing. It should not be resorted to during acute inflammation. The indications for ignipuncture are hæmophilia, plethora, a non-pedunculated growth, or when the patient objects to amputation. Thermo-cautery is to be preferred in adults, galvano-cautery in children. Pedunculated, hard, fibrous growths should be amputated without considering the age of the patient. P. R. W. de Santi, of London, [6] avoids the cutting operation in (1) cases of hæmophilia; (2) cases with apparent or

suspected abnormalities of the vessels; (3) flat and deeply-situated tonsils, and in adults rather than in children.

The latter author, speaking of the danger of bleeding after tonsillotomy, concludes (1) that fatal hæmorrhage is almost unknown; (2) that dangerous hæmorrhage is very rare; (3) that severe hæmorrhage requiring styptics, direct pressure, etc., is very far from common; and (4) that moderate hæmorrhage is very fairly common and generally ceases spontaneously; also that the bleeding is almost entirely confined to adults, and that in many of the recorded cases it has followed the use of the bistoury. Lennox Browne, [6 Jan.20,'94] reported the three cases he had witnessed in which the bleeding was at all serious. In one a persistent oozing was caused by eating toast, but was checked by styptics and pressure. In another it arose while the patient was cleaning door-steps, on the third day after the operation; and in the third the hæmorrhage was arrested by the employment of styptic colloid with pressure, the tannic- and gallic- acid gargle having failed. He advises careful instruction of patients as to their dietary and exercise during several days after the operation. A. Barkan, of San Francisco, [147 Mar.,'94] removed the pharyngeal and faucial tonsils of a strumous boy 6 years old, using the tonsillotome and Gottstein's curette. Although the bleeding immediately after the operation was sufficiently unimportant to warrant the departure of the patient in about one-half hour, subsequent hæmorrhages caused death of the patient about twelve hours after the operation, notwithstanding skillful medical attendance. A case of serious secondary hæmorrhage was reported by S. G. Dabney, of Louisville. [224 Nov.12,'93]

Augustus Caillé, of New York, [673 Aug.,'94] reported a case of tonsillotomy followed by diphtheria and croup. The exudate or pseudomembrane spread rapidly from the fresh surfaces of the tonsils to the glottis. After intubation and forced feeding he recovered rapidly. The cause seemed to be infection from the child's own mouth,—perhaps from decayed teeth, as the instruments used had been carefully rendered aseptic. It is found that 8 per cent. of supposed healthy persons show diphtheria germs in the mouth. Therefore all cases should be thoroughly irrigated with germicides before the operation. During the discussion following the reading of this paper, Jacobi, of New York, insisted that operation during an epidemic of diphtheria often caused a spread of the

epidemic. Scores of times he has seen the disease on resected tonsils, several of them fatal. Koplik states that the Klebs-Lœffler bacillus is often found harbored in the cleft of the apparently normal tonsil. The lacuna amygdalitis is often diphtheritic. A simple swab-culture is not conclusive; a sterilized scoop must be introduced into the crypts. While there undisturbed these germs are soon destroyed by the leucocytes and lose their virulence in the lymph and serum; but on a fresh, bloody surface, however, they flourish. The presence of an epidemic need be no hindrance to operation, if care be taken not to infect the individual case. W. Ward, of New York, $_{\text{Feb.17,'94}}^{9}$ states that deep injections of from 30 to 60 drops of a mixture of 10-per-cent. solutions of cocaine hydrochlorate and of ferrum sulphate in equal parts will render amputation with the amygdalatome practically bloodless.

T. A. de Blois, of Boston, $_{\text{Oct.12,'98}}^{99}$ believes that galvano-puncture, though not a perfect method, is the best means at our command for the reduction of hypertrophied tonsils. F. P. Hudnut, of Needham, Mass., $_{\text{Apr.14,'94}}^{9}$ states that he has used it at least five hundred times; it had never given pain nor caused bleeding, although a stronger solution than 4 to 10 per cent. of cocaine had never been employed. The method is also highly extolled by Edwin J. Kuh, of Chicago, $_{\text{Mar.17,'94}}^{9}$ who states that the operation can be made entirely painless by brushing the tonsils with a 20-per-cent. cocaine solution and by instilling a drop or two of a 4-per-cent. cocaine solution into each lacuna, the patient being cautioned not to swallow any of the drug. It need never require more than two sittings (and generally but one) to shrink the largest tonsils to normal size by the following method: The cautery-point is inserted as deeply as it will go into each lacuna, brought to white heat, and withdrawn in a couple of seconds. After the cauterization of each lacuna, a flat cautery electrode (or the needle electrode curved so as to adapt itself to the tonsil) is passed over the surface of the tonsil and several furrows drawn. There is little or no after-pain. The slough is cast off gradually during the following fortnight, and the tonsil reaches its maximum of shrinkage in about four weeks. A repetition of the painless, bloodless procedure, easily practiced on both children and adults, is rarely necessary. W. K. Simpson, of New York, $_{\text{May,'94}}^{11}$ states that due attention to details and technique will overcome the objections to

the operation. To overcome the pain he injects 5 minims (0.32 gramme) of a 4-per-cent. solution of cocaine (freshly made) into the substance of the tonsil, using as many injections as there are cauterizations to be made, and making the injections in the areas to be punctured. By this means the anæsthetic effect is instantaneous, and the danger of cocaine intoxication is lessened. A heart-stimulant is employed before injecting the cocaine, generally the aromatic spirits of ammonia. For injection, a long hypodermatic needle with a short curve is used. For the punctures, a fairly-strong loop-shaped electrode, curved to suit the angle of introduction. This should be pushed deeply into the tonsil, and a cutting or rotary motion made to increase the area of destruction. This is to be repeated as often as necessary. It is important to confine the cauterizations to the tonsil itself, avoiding the adjacent parts, and especially avoiding the anterior faucial pillars. If necessary, the latter should be pulled away and guarded by a retractor during the operation.

The known means that have found support during the year were Ruault's *morcellement* process, performed with toothed forceps, by A. S. Gerwant, $\frac{1105}{\text{V.2,p.2}}$ and the cold-wire snare by Marcel. $\frac{1045}{\text{Jan.,Feb.,'94}}$ George J. Monroe, of Louisville, Ky., injects a solution composed of 1 drop of liquid carbolic acid and 6 drops of water, by means of a common hypodermatic syringe. Slight soreness, due to inflammatory reaction, follows, and the gland is absorbed in an eminently satisfactory manner when the number of injections has been sufficient. No cocaine is necessary, carbolic acid being itself anæsthetic. A good review of the subject of excision of tonsils was published by T. Mark Hovell, of London $\frac{1077}{\text{July 11,'94}}$; and general reviews by R. Pellicer, of Barcelona $\frac{937}{\text{July,'94}}$; C. C. Rice, of New York $\frac{51}{\text{Feb.,'94}}$; L. S. Givens $\frac{224}{\text{Dec.30,'93}}$; and J. Madison Taylor, of Philadelphia. $\frac{23}{\text{Nov.,'93}}$

Tuberculosis of the Tonsils.—Tussau $\frac{211}{\text{Apr.23}}$; $\frac{2}{\text{May 5,'94}}$ records three cases of tuberculosis of the tonsils. All three were men who used alcohol and tobacco to excess, and Tussau expresses the opinion that this abuse may be a predisposing cause of the tuberculous infection by producing a chronic inflammatory condition, which diminishes the resistance of the glands. He advocates strongly early resort to cauterization, preferably with the galvano-cautery. The aim of the surgeon should be not merely to cauterize the

ulcers, but also the surrounding tissue, so as to obtain the sclerosing zone of fibrous tissue which Lannelongue seeks to obtain in articular tuberculosis. Tussau relates one case in which, after two months of treatment, the tonsillar lesions and the secondary glandular enlargement disappeared. During the treatment the patient suffered much from hectic fever, attributed to septic absorption from the ulcerations. The patient, an inn-keeper, remained well for some time, but resumed his bad habits, was attacked by tuberculous peritonitis eighteen months after he had recovered from the tonsillar affection, and died of generalized tuberculosis. In another case, also, the local lesions disappeared; but the patient, a discharged soldier, continued to live a very irregular life, and died in a few months of general tuberculosis. Sacaze, [243 Jan.,'94] in a case resembling one of follicular pharyngitis, found the bacillus tuberculosis during bacteriological examination of the caseum, having been led to suspect a tuberculous process by a cervical polyadenitis and the absence of the odor usually presented by the follicular caseum.

Syphilis of the Tonsils.—K. Szadek, of Kiew, [569 v.4,No.1,'94] in a series of 272 cases of syphilitic chancre of the tonsils and pharynx collected by him in the literature of the subject, found 200 cases of primary induration of the tonsils. The chancre was located on the right tonsil in 112 cases and on the left in 53; both tonsils were affected in 15 cases; in 20 cases the particular tonsil is not mentioned; in 29 cases the primary induration was situated on the pharynx and in 20 cases on the palate. The patients' ages varied from 3 to 85 years. The primary lesions of tonsils occurred somewhat more frequently in women than in men. To such statistics the author adds 7 cases observed by him during a venereal practice extending over more than ten years. Gradenigo and Peroni [57 No.10,'94; 814 June 15] report the case of a girl, 20 years old, who complained of pains in the throat and dysphagia. A deep ulceration was found in the left tonsil. The edges of the area involved were overhanging, and its base was covered with a pseudomembranous covering. Direct pressure over the area caused intense pain. The removal of the membranous covering showed that the ulcerated base possessed a distinct characteristic copper color. The submaxillary glands were enlarged and quite painful and sensitive to pressure. The diagnosis of syphiloma was confirmed

by the speedy appearance of a diffuse macular syphilide and mucous patches on the genitals. Investigation showed that the method of infection was from the kisses of a lover whose lips were covered with specific lesions. W. F. Chappell, of New York, [59 Jan.27,'94] also described a case in which the ulceration was located upon the left tonsil, the correctness of the diagnosis being proved by the appearance of dermic manifestations and the successful result of antisyphilitic treatment.

Of fifteen cases of chancre of the tonsil, observed by L. Duncan Bulkley, of New York, [26 Oct.2,'96] the sexes were almost evenly divided, there being eight males and seven females. The age of the patients ranged from 11 to 46 years; the youngest, a boy of 11, the son of one of the patients with chancre of the lip; the oldest a gentleman, aged 46, who had not been exposed sexually, and had surely no genital or extra-genital chancre elsewhere; he had very characteristic chancres on both tonsils, with distinct hardness, and a macular syphilide of two weeks' duration, with great malaise, etc.; all of the symptoms yielded very promptly to mercury and chalk, given every two hours. In this case, as has also occurred in a number of others, the physician bringing the case in consultation could not convince himself that the eruption was one of syphilis, because of his inability to find the chancre and because of the absolute absence of venereal exposure. The right tonsil would seem to be more liable to infection than the left. A good *exposé* of the clinical picture of chancre of the tonsil was published by Gaube. [212 Mar.26,'95]

Tumors of the Tonsils.—Sarcomatous growths of the tonsils were reported by J. Solis-Cohen, of Philadelphia [9 Jan.27,'94]; Clinton Wagner, of New York [59 Feb.3,'94]; A. W. Watson, of Philadelphia [59 July 14,'94]; and Schiffers, of Liége. [11 Dec.,'94] In each case the neoplasm was successfully removed through the mouth. Verneuil, of Paris, [673 V.4,p.4] removed a large sarcoma of the tonsil, involving a portion of the tongue, through an opening afforded by an incision starting from the commissure and extending along the lower edge of the maxilla to the perpendicular sinus. The carotid was ligated. Notwithstanding the length of the incision, it did not permit the passage of the tongue; he therefore removed the greater part of the tumor, after which the tongue, thus reduced in size, readily passed through the orifice. The tongue being now easily accessible as far as its

base, he was able to remove the entire tumor, even excising a portion extending somewhat beyond its limits. The parts were then brought together and dressed. Antiseptic solutions of chloral were used daily, and three weeks later the patient returned home, entirely cured. The results of the operation were entirely satisfactory; there was no trace of inflammation, which he attributed to the antiphlogistic influence of the ligated carotid. Eisenmenger [673 Apr.,'94] presented a 53-year-old woman with a slightly-mobile, circumscribed tumor behind the angle of the jaw,—a *melanosarcoma* of the right tonsil, which had been followed by metastases to the internal organs. Melanin and melanogen were found in the urine. Examination of the blood gave negative results. The author stated that it was the first known case of melanosarcoma of the tonsil, although the disease had frequently been observed on the vault of the palate.

Moritz, of Manchester, [2 Nov.24,'93] recommends pyoktanin in the treatment of tonsillar malignant growths. He applied it by injection in a case of sarcoma of the tonsil and upper jaw, in a woman, aged 49, who first noticed a swelling of the right tonsil eighteen months before. There was a second tumor, the size of a plum, in the roof of the mouth, and a third one in the left parotid region. In April last he began to inject, three times weekly, a saturated solution of yellow pyoktanin (auramin) into the tumors; about 0.005 gramme ($\frac{1}{12}$ grain) being injected into each tumor at a time. Since then the tumor of the hard palate had entirely disappeared and the tonsillar tumor had diminished to half its size. Milligan, who had also observed the patient during the course of treatment, was able to confirm Moritz's statement.

S. Marano, [37 Dec.,'93] reported the case of a woman, aged 64 years, in whom histological examination confirmed the diagnosis of primary *epithelioma* of the tonsil. Warren Coleman, of New York, [59 Mar.31,'94] presented before the New York Pathological Society a specimen of *endothelioma* of the tonsil, removed from a lady aged 35 years. Good general reviews of the subject of tonsillar tumors were published by Gulpin and Ripault, of Paris, [100 June 22,'94] and Damieno. [1105 No.4,'93]

Calculus of the Tonsils.—It would seem, judging from the cases reported during the year, that calculi of the tonsils are not

so rare as they are generally thought to be. In the case described by W. B. Johnson, [1018 Jan.,'94] the patient, a man aged 65 years, of a gouty and rheumatic history, coughed up several hard calcareous bodies, followed by hæmorrhages. These were found to come from the tonsils; they were removed and found to be similiar to those expelled by coughing, and after their removal the attacks ceased.

In a case reported by Lecocq [11 Jan.,'94] the calculus was twenty-six millimetres long by eleven millimetres broad, which was lodged in a large space. This calculus resulted from a recurrence, on account of which Lecocq recommends the destruction of the cavity. He vigorously scraped the walls and swabbed them with a strong solution of corrosive sublimate. Cases were reported by J. W. Gleitsmann, of New York [814 Feb.15,'94]; Lange, of Strasburg [301 B.20,H.1,2]; W. A. Larrabee, of Scarborough, Maine [547 May,'94]; and F. A. Campenni and F. Arena, of Naples. [461 July,'94] In the latter case, a chemical analysis showed the concretion to be mainly composed of phosphate of calcium with a trace of phosphate of magnesia.

LARYNX.

Anatomy and Physiology.—B. Fraenkel, of Berlin, [1151 B.1,H.2] comprising in the vocal cord proper not only the inferior thyro-arytenoid ligament, but also all the tissues projecting from the lateral wall of the larynx, divides it into three parts: anterior or sesamoid portion of the cord, owing to its connection with the sesamoid cartilage anteriorly; the median or free; and the posterior or "processal" portion, on account of its relation with the vocal process posteriorly. The stratified pavement-epithelium lining the vocal cord lies immediately over the fibres of the ligament in the median or free portion, while both anterior and posterior portions are furnished with a well-characterized, though thin, mucous chorion. Papillæ are numerous over the inferior surface and over the anterior and middle portions of the cord, but, unlike ordinary papillæ, they assume the form of small longitudinal projections. Glands may be found upon the superior and inferior surfaces, but those of the superior surface cease at a distance of 1.8 millimetres from the free border of the cord. A large number of acini dip into the muscle and are closely connected with the muscular fibres.

Fraenkel also gave a careful description of the ventricles of Morgagni. The lateral wall of each ventricle consists of muscle-fibres which arise from the thyro-arytenoid, of numerous glands lying amongst the muscle-fibres, and of adenoid tissue. The appendix makes use of the cavity of the ventricle as its duct and lies at right angles to the sinus. Its greatest measurements are from downward and from before backward, and its mouth a slit about one millimetre broad, measured from before backward. It is a complex system of hollows and canals possessing only one single duct in common. The position of its upper border varies considerably, generally reaching up into the plica ary-epiglottica. It is partly covered with cylindrical ciliated epithelium, under which is connective tissue containing round cells and also true subepithelial follicles and in many places adenoid tissue. Numerous acinous glands lie to the inside and in front. The one function of the appendix is to secrete a fluid, which keeps the vocal cords flexible. The author compares the appendix with the pockets of the tonsils.

Onodi, of Budapest, $\frac{37}{July,'94}$ severed the medulla of dogs above the nucleus of the vagus and observed that the animal had become aphonic. Although the glottis could open to the extent of from three to four millimetres, no adduction could be produced. Section and isolation of the corpora quadrigemina gave rise to the same results. Sections in the floor of the fourth ventricle above the nucleus of the vagus on one side produced no effect upon the motions of the cords. In the dog important phonation-centres were noted in the cerebral ganglia. As to the cortical centres of the larynx, Onodi reached the same results as Krause and Semon, but he had not been able to verify the experiments of Masini regarding the crossing of the vocal cords in adduction under the influence of slight cortical excitation. The author further maintained that double innervation of the larynx, in Exner's sense, did not exist, and that it only applied to the cricothyroid, which received its innervation from the external branch of the superior laryngeal and the pharyngeal branch of the vagus. Semon in the discussion suggested that further experimentation could alone throw light upon the question, and expressed surprise that section of the tubercula quadrigemina should cause complete loss of reflex phonation, with patent glottis, this point being in contradiction

with clinical observations in acephalic monsters. He, therefore, claimed further evidence.

E. von Navratil, of Budapest, [1130/98] by a series of sixteen experiments, confirmed the views expressed by him twenty-four years ago, to the effect that the muscles of adduction, tension, and abduction were innervated by the inferior laryngeal, the sensory fibres arising from the superior laryngeal. He considers the accessory nerve of Willis as possessing no influence whatever upon laryngeal innervation.

Jaboulay and Villard [211/Nov.12,'98; 126/Jan 15,'94] include in three types the relations between the recurrents and the inferior thyroid arteries: 1. On the right side the recurrent passes in front of all the arterial branches, while on the left it passes behind them. 2. On the right the nerve passes between the subdividing branches of the artery opposite the inferior branch, while on the left it passes behind all the arterial branches. 3. On the right side the nerve always passes more anteriorly as regards the arterial branches than on the left. Of 41 cases of aneurism seen in the clinic of Budapest by Tansk, [622/No.27,'98] he observed hoarseness in 22 and paralysis of the recurrents in 19, most of the latter being aneurisms of the arch. He concluded that paralysis is usually located on the left side, and that bilateral paralysis is very rare in cases of aneurism.

Rethi, of Vienna, [8/No.15,'98; 37/Mar.,'94] studied the rôle of the epiglottis, the arytenoid cartilages, and the inferior segment of the pharynx in the act of deglutition in man, the rabbit, the dog, and the cat. During the act a contraction of the cricothyroid muscles takes place, which approximates them, along with the thyroid and cricoid cartilages, thus causing adduction of the vocal cords. The top part of the arytenoids leans forward, while on each side the lower part forms a groove. The depression of the epiglottis is due to the pressure of the tongue, and is not under the dependence of the laryngeal muscles.

Œdema of the Larynx.—John H. Pryor, of Buffalo, New York, [59/July 28,'94] reports a case of acute supraglottic œdema characterized by the following features: (1) the absence of any known causative agency and constitutional symptoms; (2) the extent of œdema which may occur without marked dyspnœa; (3) the peculiar character of the voice; (4) the marked benefit of prompt treatment without scarification; (5) the possibility of the case belonging to

a group of obscure clinical manifestations known as angioneurotic œdema or allied vasomotor curiosities. In the opinion of F. Barjon, [100] May 19, '94 acute primary œdema of the larynx is an infectious disorder, streptococci and pneumococci having been found in several cases of that affection. Cold and traumatisms are considered as but occasional causes favoring the penetration of germs into the organism.

Chronic Laryngitis.—Krause, of Berlin, [4] Apr. 16, '94 in stubborn cases occurring in singers, recommends a method considerably employed in the United States many years ago,—*i.e.*, minute longitudinal incisions made with a lancet-shaped laryngeal scarificator into the hyperplastic tissues of the cords. The bleeding is slight, and rapid improvement ensues. In the same class of cases Massei, of Naples, [3] No. 22, '94 recommends spraying with a 2-per-cent. solution of lactic acid, used frequently,—eight to ten times daily. Hygienic measures and tonics form important adjuvants.

Chronic Hypertrophic Laryngitis.—Sokolowski, of Warsaw, [87] July, '94 considers this disorder as relatively rare; it is usually observed in peasants. It has no relation with Stoerk's blennorrhœa, but the bacillus of rhinoscleroma sometimes causes it. He recommends laryngo-fissure and thorough extirpation of the vegetations.

Syphilis of the Larynx.—Elsenberg [520] No. 15, '94 discusses an interesting case of a young man, aged 19, in whom the larynx was covered with syphilitic neoplasms, including the muscles. The pharynx was completely destroyed and there were gummata present in many parts of the general system,—the upper and lower extremities, the liver, etc. Notwithstanding active antisyphilitic measures, the patient succumbed. (Report of Corr. Editor Szadek, Kiew.)

In an excellent thesis upon secondary syphilis of the larynx, Mendel, of Paris, [2031] '93 states that, notwithstanding a stay of six months at the St. Louis Hospital of Paris, in which he saw a very great number of cases of syphilis, he only met twenty-six cases of secondary syphilis of the larynx. From a careful study of these he concludes that it may present itself at the onset of the secondary period, but that it is usually between the third and fifth months after the initial lesion that it presents itself. In one case it appeared after eleven months; in a second, after one year; and in a third, after three years. It is less frequent in women than in

men, owing to the diminished local resistance in the latter brought on by smoking. Of the twenty-six cases, nineteen were men. The process only involves the surface of the larynx, affecting phonation only. Dyspnœa and dysphagia were never observed, even when the epiglottis was seriously involved. Jacquin [577 Apr.,'94] mentions a case of secondary laryngitis, with mucous patches over the vocal cords, in which there were condylomata of the palatine and lingual tonsils. In a case seen by Boulay and Mendel [286 July, Aug.,'94; 2 Oct.6] the patient was seized, four years after the primary infection, with simultaneous right-sided paralysis of the face, arm, and leg, and with aphasia. Four months later the hemiplegia had diminished, but he had recently developed a paralysis of the right oculomotor. He spoke in a somewhat hoarse, falsetto voice, and suffered from dyspnœa on exertion. On laryngoscopical examination the cords were found to remain motionless on inspiration; they moved very slightly on phonation and were imperfectly stretched. The palate and tongue were unaffected. There was emotional cerebral disturbance. No evidence of pressure on the recurrents was found. The seat of the disease was diagnosed as in the bulbar or circumbulbar region,—probably syphilitic pachymeningitis. Rueda, of Madrid, [136 No.2,'94] reported a case of syphilitic arthritis which he considers as primary, and which he cured by means of mercury and iodide of potassium. Hale White, of London, [11 Apr.,'94] described a case in which a gumma over the right arytenoid cartilage seriously impaired the motion of the cords,—also cured by mercury. De Havilland Hall [11 Apr.,'94] mentioned a similar case in which tracheotomy was often threatened, but as frequently averted by the administration of iodide of potassium.

Botey, of Barcelona, [87 May,'94] after studying thirty-one cases, including four of his own, of hereditary syphilis of the larynx, concludes that it almost always presents itself in the tertiary form, with ulceration; that it assumes a chronic course; and that it is frequently accompanied by lesions of the nose and pharynx.

Syphilo-Tuberculosis of the Larynx.—G. C. Wilkin, of London, [11 June,'94; 6 June 9,'94] exhibited, before the Harveian Society of London, a married woman, aged 38 years, suffering from syphilitic laryngitis, with consolidation of the apex of the right lung. There was no family history of phthisis. She had had two miscarriages and no children. There was swelling of the epiglottis

and of the false vocal cords, the latter meeting completely in the anterior half. There was dullness in the upper lobe of the right lung, in front and behind, with increased vocal resonance and pectoriloquy above the spine of the right scapula. Three examinations of the sputum were made, and tubercle bacilli were never found. The laryngeal and lung troubles gradually subsided and entirely cleared up under a mixture containing potassium iodide and liquor hydrargyri perchloridi. Damieno, of Naples, [37] is convinced that histology cannot serve to demonstrate the fusion or transformation of one disease into the other; but that, since bacteriology furnishes examples of the simultaneous presence of antagonistic organisms and evidences of the destruction of one germ by another, so, also, can be the case when a tubercular lesion develops on top of a syphilitic one.

Stenosis of the Larynx.—Felix Semon, of London [11] relates two interesting cases of syphilitic stenosis. Case 1. Mrs. G., aged about 55 years. Date of primary affection not exactly known; certainly very many years ago. Throat troubles began more than twelve years ago. In 1883 tracheotomy, on account of steadily-increasing dyspnœa; has worn tube ever since. The arytenoid cartilages were for many years greatly thickened and almost immobile, the glottis reduced to a very small triangle, formed by the internal aspects of the arytenoids and the posterior wall of the larynx, while in its anterior three-fourths the vocal cords were seen to lie close to one another. The voice was quite aphonic in all these years. From time to time superficial ulceration used to occur in various parts of the larynx, which could always be promptly checked by the use of iodide of potassium. Quite recently,—*i.e.*, within the last three weeks,—without any apparent cause, a surprising improvement had taken place in every respect. The glottis had become much larger, the swelling of the arytenoid cartilages had much diminished and their mobility improved; the previously aphonic voice had regained tone, and there was now a fair prospect that the tube could be ultimately dispensed with without any further operation. Case 2. W. M., aged 37 years, contracted syphilis in 1884. In 1891 tracheotomy had to be performed. On February 10, 1893, Stabb performed thyrotomy; excised large quantities of cicatricial tissue, including the right vocal cord and ventricular band, and removed a large piece of the necrosed cricoid

cartilage. Quick recovery and remarkable return of voice, but still considerable narrowness of glottis. In a fatal case reported by R. H. Woods, of Dublin, [16, Sept.1,'94] the stenosis was located at the junction of the larynx with the trachea, and could scarcely admit a goose-quill.

J. Mount Bleyer, of New York, [61, Nov.25,'93] described eight cases of syphilitic stenosis successfully treated by his method. The operation consists in the free division of the occluding cicatricial tissues by means of Lennox Browne's cutting dilator and the immediate introduction of a large hard-rubber intubation tube, which is worn for at least two weeks, only being removed to be cleaned. P. Heymann, of Berlin, [37, Dec.,'93] reports a case in which the rest to the ulcerated parts, procured by tracheotomy, rendered them amenable to the influence of antisyphilitic remedies which had proved useless before the operation was performed. J. E. Weeks, of New York, [11, May,'94] also describes a case illustrating the advantage of tracheotomy in these cases.

Chiari, of Vienna, [11, Nov.,'94] obtained good results with intubation in cicatricial and chronic inflammatory stenoses, and recommends its employment. In a case of stenosis reported by Halasz [622, Oct.1,'93; 451, June,'94] the patient, a man 35 years of age, had become hoarse after an attack of typhoid fever a year previously. When seen, was suffering from dyspnœa and aphonia and had had several attacks of suffocation. The vocal cords were found grown together by quite a firm membrane, except for a small oval opening at their posterior ends. This membrane was divided under local anæsthesia with a concealed laryngeal knife. A catheter was then introduced to dilate the glottis. After-treatment consisted of alum inhalations. The patient obtained a good voice.

Tuberculous Laryngitis.—Cadier, of Paris, [37, June,'94] drew attention to several cases of this affection in which close study of individual etiology revealed that, in cases resulting from cohabitation with tuberculous subjects, the disease generally attacks the upper parts of the larynx first. In many cases the lesions are localized for quite a time, and may be recognized under very carefully conducted laryngoscopical examination, and amenable to appropriate local treatment.

J. H. Woodward [1, Dec.16,'93] expresses doubt as to the actual value of microscopical diagnosis in tuberculous laryngitis, two cases

under his care having recovered under the influence of iodide of potassium, notwithstanding the fact that bacilli had been found in the sputum. Hunter Mackenzie, of Edinburgh, [11] in the course of some clinical observations on the tubercle bacillus, remarked that it "may be taken as a maxim that, the higher up the locus of the bacilli in the respiratory tract, the more unfavorable is the prognosis. Thus, when the larynx is their seat the prognosis is more grave than when the lungs alone are affected, and a pharyngeal implication is the most unfavorable of all." One might expect the opposite to hold good, and that, the more accessible the disease, the more favorable it ought to be. A simple chronic laryngitis may become tuberculous,—an occurrence which, in the first instance, is revealed by the sputum only. In considering the question of the diagnosis of laryngeal phthisis from the laryngoscopical characters, and also from the presence of tubercle bacilli in the sputum, it ought not to be lost sight of that, as one writer (Ruehle) puts it, "the larynx is the locality *par excellence* in which syphilis and phthisis intermingle and intersect each other." The possibility of syphilis being present in apparently pure laryngeal phthisis, with tubercle bacillary sputum, ought always, therefore, to be borne in mind.

J. M. Ball [61] furnishes an excellent translation of the portion of Schnitzler's Atlas bearing upon the pathology of laryngeal tuberculosis, in which that much-regretted teacher argues in favor of bacillary propagation from within, basing his conclusions upon many observed facts, such as (1) cases with scarcely a bacillus in the sputum, but extensive tubercular laryngeal invasion; (2) cases of extensive and rapid pulmonary tuberculosis without laryngeal complications; (3) the correspondence of side between the lung and laryngeal lesion tending to prove blood- and lymph-carriage; (4) the presence of a stratum of healthy tissue between the mucous membrane and the diseased structures. Interesting, in this connection, is the paper by S. E. Solly, of Colorado Springs, [80] [11] in which he also expresses his conviction that the majority of cases of laryngeal infection are of deep origin, and only the minority are infected by the passing sputum. He draws a favorable comparison between the high altitude of the springs (six thousand feet) and low altitudes in these cases. Out of 250 cases of pulmonary disease the larynx was infected in 8 per cent.

The relative positions of the ulcerations are stated. Those on the arytenoids and false cords alone showed an entire absence of improvement. Of the non-ulcerative, 6 were cured, 11 improved, 5 died, and 3 became worse. Of the ulcerative, 2 were cured, 3 improved, and 15 died.

An interesting discussion took place at the International Congress upon the treatment of laryngeal tuberculosis. The President of the Laryngological Section, F. Massei, of Naples, requested a joint report from Gouguenheim, of Paris; Heryng, of Warsaw; and Lennox Browne, of London; but the individual views of these observers were sufficiently dissimilar to render any concerted action impossible, and they therefore concluded to report separately. This result about illustrates the actual position of the subject, and it is quite likely that if a commission of thirty members had undertaken the preparation of the report thirty individual methods of treatment would have prevented its elaboration. Energetic surgical interference rivalled with the old-time measures based upon local medication, each claiming its share of successful results,—a chaos which called forth from Fraenkel, of Berlin, the apropos remark that what was wanted was a proper definition of indications. Sokolowski, of Warsaw, also aptly called attention to the fact that cicatrization of the tubercular process in the larynx could take place under different therapeutic methods whenever the tubercular process had a tendency to stop in its development,—*i.e.*, when the diseased parts, for reasons still unfathomed, could undergo the so-called metamorphosis, thus giving each treatment its due and the palm to none. Gouguenheim expressed himself a strong partisan of energetic surgical interference, recommending nothing less than a punch-forceps to punch off the diseased arytenoid, which, in his hands, has been an effectual means in the relief of the terrible dysphagia from which the cases suffer and all its attending untoward results. "Never," to quote his words, "have the anæsthetics so commonly applied, cocaine and menthol, been able to procure such rapid, efficacious and prolonged therapeutical results," a result explained by the researches of his interne, A. Michel Dansac, $\frac{37}{\text{Dec.,'98}}$ who had studied the nervous legions of tuberculous arytenoiditis and found that the infiltration was always accompanied, in advanced cases presenting stenosis, dyspnœa, and dysphagia as symptoms, by

neoformations in the nerves, with hypertrophy of the cylinder-axis and perineural sclerosis. Gouguenheim uses the instrument in the following manner: Preliminary anæsthesia is commonly made with a very strong solution of hydrochlorate of cocaine of 33 per cent. The pharynx and base of the tongue should be anæsthetized with the greatest care to facilitate the drawing out of the tongue and in order that the application of the laryngeal mirror be easily tolerated. The anterior posterior punch is placed with one branch behind the arytenoid region and the other branch within the larynx. This movement should be conducted with care. When the diseased portion is properly placed between the jaws of the instrument the latter is strongly closed to resect the tissues, which is generally easy if the jaws are sharp. Consecutive hæmorrhage is but slight, and the pain of the operation is about *nil;* it is sometimes possible to operate afterward on the other side at the same sitting. A solution composed of 1 part of β-naphthol to 2 of camphor is then painted over the wound daily. The dysphagia begins to improve on the second day and gradually disappears. Cicatrization occurs in two or three weeks at most.

Heryng based his conclusions upon two hundred and fifty-two cases, to which he has since added eighteen more. In order that they may be properly understood the author's own words will be quoted *in extenso* $^{11}_{\text{Aug.,'94}}$:—

"1. Tubercle of the larynx, or, rather, the laryngeal phthisis induced by it, can heal by itself without any local treatment. Most frequently the ulcers heal on the vocal cords and posterior wall of the larynx. Very rarely the more serious cases with infiltration and proliferation products with deep ulcers, also affections extending to the cartilage, accompanied with aphonia and severe dysphagia, lead rapidly to disintegration and extension to the lungs. 2. Out of about three thousand cases of laryngeal phthisis which I have collected during the last eight years I have observed spontaneous healing in fourteen. These were simple cases of slight laryngeal phthisis without any affection of the epiglottis or the cartilages of Santorini. The ulcers were found most frequently either on the vocal cords or on the posterior wall of the larynx, less frequently on the false cords. These were healed by inhalations only, along with general and climatic treatment without local interference. The healing process required, in some cases,

three to eight years. The patients were nearly all about 40 years of age. The lung affection was mostly of a fibrous nature, not extensive, more often confined to one side; the nourishment as well as strength and appetite were good. The majority of these patients belonged to the better class. The laryngeal affection was of a chronic nature. The treatment was begun in the very first stage of the disease and continued throughout. In these cases dysphagia was very slight; the hoarseness, however, was considerable. 3. Those cases in which the disease shows itself in the form of infiltration or tumor-like excrescences on the posterior wall of the larynx, which become chronic, and in which the epiglottis and cartilages of Santorini are little or not at all affected give the best chance of recovery. 4. Relative results can be gained in many cases of chronic unilateral disease, with concurrent infiltrations which do not tend to break down or with so-called tuberculous tumors of the true or false vocal cords. 5. Cases in which diffuse infiltrations of the larynx appear with rapid breaking down, deep ulcers on the epiglottis and the tumor of Morgagni which extend to the ventricle, necrosis of the arytenoid cartilages, showing symptoms of stenosis and miliary tubercle; these give the worst prognosis. 6. The possibility of recovery depends first on the constitution and power of resistance of the patient, then on the anatomical character and extent of the lung affection, and farther on the age and surroundings of the patient. The condition of the lung affection and of the nourishment of the patient indicate the issue. 7. Tumor-like infiltrations of the intra-arytenoid space lead to the formation of abscesses and general infection. These appear to be, in many cases, of primary origin, but more often they indicate a latent tuberculous condition of the lungs. 8. The chief indication in the treatment of tubercle of the larynx, which almost invariably is accompanied with tubercular disease of the lungs, is hygienic, dietetic, and climatic. 9. As in most cases of phthisis in the larynx, severe dysphagia occurs; it follows that the first and most important indication in the treatment to be considered is the removal of the dysphagia. 10. The second equally-important indication touches the special cases in which the breathing becomes difficult and symptoms of stenosis appear on account of tubercular infiltrations and proliferation products. 11. The third indication has to do with the recovery of the impaired or lost

voice. 12. In order to treat the dysphagia successfully we must endeavor to remove the causes. It is caused by (*a*) tubercular infiltrations of the epiglottis, of the posterior wall of the larynx, of the lateral ligaments, and of the cartilages of Santorini; (*b*) tubercular ulcers arising from breaking down of the infiltrations and occupying the same position; (*c*) inflammatory processes, usually secondary, very often resulting in inflammation of the cartilage and necrosis. 13. The principle of general treatment of dysphagia must be based on resting the diseased organ,—avoiding speaking and anything which stimulates the diseased mucosa. 14. The healing of deep ulcers of the larynx resting on inflammatory infiltrations, surrounded by proliferation products, and certain forms of localized chronic laryngeal tubercle is effected quickest by curetting or, rather, removal of the tubercular tissue. 15. To these methods, the principles of which I published in 1887, I have to add now those of galvano-caustics and electrolysis. 16. Lactic acid is indicated in superficial circumscribed ulcers of a dirty character and covered with spongy granulations, situated on the vocal cords, the false cords, and posterior wall of the larynx; and in isolated superficial ulcers of the posterior surface of the epiglottis. 17. This remedy (lactic acid) is useless in most cases of large, hard, and diffuse infiltrations. 18. The surgical treatment is indicated (*a*) in tubercular tumors of the epiglottis; (*b*) in circumscribed, chronic, tumor-like infiltrations of the posterior wall of the larynx, which show little inclination to break down; (*c*) in chronic tumors resting on an inflammatory base, surrounded with proliferation products, which resist all other methods of treatment; (*d*) in partial disease of the larynx, even when the epiglottis, false cords, and lateral ligaments are affected. 19. Surgical treatment is contra-indicated (*a*) in advanced phthisis of the lungs with hectic and wasting; (*b*) in diffuse miliary tubercle of the larynx, or rather of the larynx and pharynx; (*c*) in all cachectic conditions; (*d*) in severe stenosis of the larynx caused by inflammatory swelling of the affected parts,—in these cases tracheotomy must be performed as soon as possible; (*e*) in patients exhibiting fear and nervous excitability, mistrust of a physician, and who are always changing their doctor, especially those whose condition promises little hope of recovery. 20. The surgical treatment demands, on the part of the physician, the greatest

sacrifice for the patient; patience, great perseverance, thorough knowledge of the operation, and well-made, sharp instruments. The operation must be done in the patient's home or in the hospital. The after-treatment requires the greatest attention and the patients must be kept under observation for months, often years. 21. With the proper application of cocaine the operation itself is not painful. Submucous injection of cocaine is hardly ever necessary. 22. It must be explained to the patients and their friends before the operation that the dysphagia cannot be removed at once by surgical interference, that it is very often increased for a few days, and, further, that the operation does not effect a radical cure. It is also advisable to tell the patients that the radical removal of the accessible parts is very seldom successful in one sitting, that in spite of a successful operation the disease in the larynx may return, and that the physician can give no guarantee of ultimate restoration to health. 23. The galvano-caustic treatment of hard tumors of the false cords—of sclerotic infiltrations of the epiglottis and formation of granulations in the ventricles—is often of use. In patients who are afraid of the knife and who are patient enough, the electrolytic treatment may be tried. The physician must have a thorough knowledge of how to administer it, and the batteries must be accurate and provided with a rheostat and galvanometer. The disadvantages of this are pain and the length of time of the operation. The advantages are avoidance of bleeding. 24. Pyoktanin (1- to 2-per-cent. solution) has proved a very good means of preventing inflammation in the parts operated on. It must be applied to the surface of the wound twice a day. 25. Serious bleeding after the operation is very rare. It can be readily stopped by the application of a mixture of lactic acid and liquid ferri sesquichlor. in equal parts. 26. A dissemination of the tubercle and increase of the lung affection after surgical interference has been observed in some cases. This result has been of extremely rare occurrence in the two hundred and seventy cases collected by me; but it may take place, particularly with those patients who, after the operation, neglect after-treatment and expose themselves to injurious influences, such as taking cold, etc. 27. With proper after-treatment the parts operated on heal in from three to six weeks. 28. Nearly the whole of the upper part of the larynx is accessible to surgical treatment by suitable

instruments. It should be a rule in surgical treatment to excise as much of the affected parts as possible in one sitting. The double curette has the advantage over the single curette in certain cases. 29. Recurrence takes place frequently at the place operated on, sometimes at a little distance from it. It is explained not only by the inaccessibility of certain parts of the larynx for our instruments, but also by the imperfect performance of the operation. In most cases, however, the recurrence is due to the disease spreading to the lungs and the insufficient power of resistance to the infection. 30. The want of success in treating cases of laryngeal phthisis by surgical or therapeutic means is often due to the disease being recognized too late for treatment to be of any use. 31. Bad cases of laryngeal phthisis ought to be treated in climatic establishments set apart specially for consumption. It would be desirable that the physicians in such establishments should acquire the art of operative treatment as long as we are unable to exercise other means which will take the place of the surgical treatment necessary in many cases. 32. The power of absorption in severe tubercular infiltrations, as also the likelihood of healing of even extensive ulcerous processes of the larynx, with complete restoration of the voice, have been proved by anatomical and microscopical preparations as well as by long-continued clinical observation."

The other side of the question was best illustrated by Lennox Browne's paper. [3 Apr.4,'94; 673 May,'94] He quotes Virchow, who once said that the larynx was the most favorable spot in which to observe the alterations of the disease; it is also the most advantageous region for topical applications. The cures, it is true, obtained by this method are exceptional; but it at least arrests the process and is much better than palliative measures. Contrary to general opinion, the improvement of the general health and of the lungs is not the cause, but very often the direct effect and the logical result of local efficacious treatment of lesions of the upper respiratory passages. The indications for topical treatment depend upon (1) the state of the larynx, acute or chronic; (2) the degree of the tuberculous affection, infiltration, superficial or deep ulceration, necrosis or caries of the cartilages and development of neoplasms; (3) the state of the lungs. The results of treatment in 102 cases of laryngeal phthisis studied by eight different observers, grouped in the author's report, show that in 32 cases in which

both lungs were diseased the treatment did not cure, but simply improved the condition; in 31 cases in which the disease was limited to one lung only, but was of a grave nature, cure was obtained in 1 case and improvement in 8 cases. In 24 cases in which the lesions were limited to one side, and were moderate in nature, cure was obtained in 6 cases and improvement in 16 cases; and in 15 cases in which there were no pulmonary symptoms 2 cases were cured and 7 were improved. The author concludes from these statistics, which comprise but a single case of cure (that being one of his own), that the chances of recovery, and even of improvement, depend to a large degree upon the co-existence and extent of pulmonary disease.

As to the methods and limitations of treatment, he does not advise the use of morphine except in hopeless cases; nor cocaine except for intra-laryngeal curettage, for applications of lactic acid, or for the temporary relief of dysphagia. All medicaments (except lactic acid) should be applied as a spray, and not in the form of insufflated powders. Menthol or menthol combined with iodol and dissolved in oil is one of the best remedies in the stage preceding ulceration. The curette may be employed to destroy the hyperplasia, to remove dead matter from the large ulcerations, and to unite the small multiple ulcers into a single large one. The curette may also be of value prior to the application of lactic acid, but its use in this connection is not indicated in more than a fifth of the cases. Lactic acid, to be really efficacious, should be employed with friction. Puncture and incision of the infiltrated tissues, as practiced by Schmidt and Rosenthal, should be avoided, as they produce no favorable result and hasten the development of ulcers. Extirpation of the arytenoid cartilages (Heryng and Gouguenheim) is not to be advised, as these are rarely the seat of morbid alterations; and if such alterations do exist, the disease is at such an advanced state that intervention is contra-indicated. According to the author's observations, tracheotomy should not be performed in tuberculosis of the larynx. While applying the topical treatment the rules of hygiene and internal medication should be considered, as well as the climate best adapted to each patient.

To sum up the conclusions of the three papers just quoted, basing judgment upon the individual experience of their authors

and the results obtained in the past by conservative and surgical means, there is no doubt that the latter merits recognition. The discussion brought forth *pro* and *con* evidence. Sokolowski had seen cicatrization follow the application of various remedies,—lactic acid, iodol, iodoform, methol, and parachlorphenol. Curettement had given him positive and negative results—principally the latter. He considers laryngo-fissure (thyrotomy) with secondary extirpation of the tuberculous parts as the proper surgical treatment when fibrous phthisis is presented. Moure had obtained favorable results by medicinal as well as surgical means, the latter being avoided when the tuberculous process was diffuse and the patient liable to acute attacks. In infiltrations he used galvano-cautery, and gave preference to forceps when surgical procedures were indicated. The latter were not free from danger, however, curetting especially exposing the patient to œdema, and he related two recent cases in which tracheotomy had to be performed. Massei spoke very highly of the application to the larynx of a solution of pure phenol in sulphoricinate of soda, especially after the appropriate surgical treatment by means of curettes or cutting forceps, as introduced and recommended at the same meeting by Ruault, of Paris. Egidi considered tracheotomy preferable to all other forms of surgical treatment, because it gives complete repose to the larynx and prevents the inspiration of tuberculous products and their dissemination in the lungs. He had performed tracheotomy in three grave cases of stenosis, and had seen the local laryngeal form disappear as if by magic. Tracheotomy was also advocated by Garel and Masuci for stenosis, but the former recalled personal statistics indicating that beneficial results could be obtained without surgical procedures. Ruault agreed with him, and spoke in favor of phenol-sulphoricinate, the merit of which consisted in facilitating spontaneous healing by provoking a fibrosclerotic process. The remedy (a 20- to 30-per-cent. solution of phenol in sulphoricinate of soda) was also highly recommended by Trifiletti, especially in the form limited to the vocal cords. Schmidt reviewed the various methods, strongly recommended curetting, then early tracheotomy, and, finally, laryngo-fissure, with extirpation of the whole of the diseased parts, followed by plugging with iodoform gauze, but, of course, only when the lungs were comparatively little involved. He referred to the results obtained from operations on tuberculous

joints. Chiari laid great stress upon the general treatment, and adopted surgical methods only when stenosis and dysphagia occurred in severe cases. In slight cases he removed any easily accessible outgrowths, especially when they affected the voice. For this purpose he employed the curette, the double curette, and very frequently electrolysis, which he recommended very strongly. The choice of method depended on the characteristics of the special case. In cases of stenosis he had tried tubage (with Schroetter's instruments) and intubation frequently with unsatisfactory results. Tracheotomy generally brought about considerable relief. Laryngo-fissure, with extirpation of the diseased parts, appeared to him to come very seldom into the question, just as was the case with resection of tuberculous joints, which surgeons now very seldom practiced.

The literature of the year also contains several papers in praise of tracheotomy, especially as a palliative. J. Macintyre[11, June, '94] relates a case in which a girl whose entire larynx was diseased was operated upon while practically unconscious. The relief, as regards the dyspnœa, was so great that within a week she was able to go about. At the time of her death—due to an accident with the tracheotomy tube—she had grown much stronger and the emaciation had, to a great degree, disappeared. Lohoff, of Würtzburg,[2080, '94] also reports five cases illustrating the influence of the procedure.

C. P. Grayson[9, No. 4, '93] mentions an instance of spontaneous healing of an ulcerative tubercular laryngitis. Sendziak[887, V. 4, '93; 673, Aug., '94] has tried subcutaneous injections of thiosinamin, recommended by Hebra, in ten cases, using a 15-per-cent. alcoholic solution, the dose of the drug being from 0.03 to 0.15 gramme (½ to 2¼ grains). The injections were made in the interscapular region from two to four times a week. After a trial of the drug for two months, he observed no improvement and refrained from further experiment. He is inclined to class thiosinamin with tuberculin, tuberculocidin, cantharidate of potassium, etc., as regards its efficacy. (Report of Corr. Ed. Drzewiecki, of Warsaw.) In a case in which the infiltration of the epiglottis was so great that the man could no longer swallow, Hajek[3, Mar. 14, '94; 673, May] removed the entire epiglottis by means of a galvano-caustic loop and treated the wound with lactic acid. Four weeks later the patient was able to swallow

with ease. Since then he had curetted one of the vocal cords, which was ulcerated. This was also dressed with lactic acid and healed readily. It is now one year since the epiglottis was extirpated, and the cure is maintained. The patient has increased in weight 19 kilogrammes (38 pounds), proving that his general condition is better. Hajec stated that he had already extirpated the epiglottis of three patients. The operation is easy, and there is no great danger of hæmorrhage. It is indicated in cases of infiltration or circumscribed tumors. The case proves, besides, in his opinion, that the prognosis of laryngeal phthisis is not so grave as one would suppose. Schadewaldt[37, July, '94] reports excellent results observed by him in cases in which creolin had been applied by friction for ten minutes only. Stoerk, of Vienna,[1151, B.1, H.2, '93] considers extensive use of creasote as inadvisable, and expresses the belief that, far from acting as a stomachic, it simply lessens the powers of general nutrition, in many cases, and so hastens the patient's downward course.

Leprosy of the Larynx.—Bergengrün, of Riga,[673, Apr., '94] presented several photographs before the Berlin Medical Society showing the alterations occurring in various stages of this disease. In one case, that of an old woman, the entire larynx was involved; the epiglottis was compressed laterally and curved backward; the vocal cords were covered with numerous round nodules; the mucous membrane of the subglottic space was thickened and pigmented, as was that of the aryteno-epiglottic ligaments. A second case showed diffuse generalized pigmentation and a small number of nodules. The third photograph illustrated a case in which the larynx was filled with nodules, occupying especially the free part of the epiglottis; the superior vocal cords were irregular and the inferior left cord thickened. In a fourth larynx the mucous membrane was almost entirely destroyed, the ventricle and vocal cords were covered with many nodules, and there was considerable ulceration of the lower part of the cords. In a fifth case the internal surface of the larynx was completely destroyed, and in the sixth case there was diffuse hypertrophy of the entire mucous membrane, but no nodules.

Erysipelas of the Larynx.—Fasano[11, July, '94] observed the case of a boy, 10 years of age, who, although ill but a few hours when first seen, was in a most serious condition. He had high fever

and experienced difficulty of deglutition. The already-marked dyspnœa was rapidly increasing. The sister was convalescing from an attack of facial erysipelas in the adjoining room. A laryngoscopical examination caused the detection of an enormous tumefaction of the epiglottis and aryepiglottic folds, together with general congestion. Toward evening it became necessary to do intubation. On the fifth day distinct improvement was noted and on the tenth day the child was completely convalescent. A case is also reported by Lounine, of St. Petersburg. [21 No.1,'94; 100 Sept.20]

Laryngoscleroma.—Kobler [673 Mar.,'94] treated a case in a woman aged 24. In 1879 hypertrophy of the vocal cords in the lower portion had been diagnosed. Two years later there was no change in the condition. Twelve years after the first diagnosis the glottis was found partly covered with a membrane involving both cords, while there was also a tumor, the size of a pea, upon the upper part of the right cord. The diagnosis of laryngoscleroma was confirmed by histological examination after removal of the tumor, in which were found the capsulated bacilli of scleroma. The case is remarkable in that the disease was strictly confined to the larynx. Paltauf was of the opinion that inferior hypertrophic chorditis bore a distinct relation to scleroma. Three cases were reported by Secretan. [87 p.675,'94] In a case described by Masuci [87 July,'94] the presence of the Fritsch-Paltauf bacillus alone permitted a proper diagnosis, the case presenting all the appearances of syphilitic infiltration of the cords.

Foreign Bodies in the Larynx and Trachea.—In a study of the cases found in literature Preobraschensky, of Moscow, [382 Aug. to Oct.,'93] divides their number (848) into three groups: (1) cases treated; (2) cases not treated; (3) cases the results of which remained unknown. The first two groups are represented by 770 cases, and the third but 85. Of the 770 245 that were operated externally recovered and 91 died; of 55 submitted to endolaryngeal operation 47 cases were cured and 1 died; 12 cases were treated by the "decline," or prone position, all with success; 12 were given emetics,—10 recoveries and 2 deaths. Of the unassisted cases—that is, those not treated by physicians—more than one-half died (52 per cent.). Beans constituted the foreign bodies in 42 per cent. and bones 38 per cent. of the cases. The larynx was the seat of the foreign body in 60 per cent., the trachea 67 per

cent., and the bronchi in 45 per cent. of the successful cases. The author argues in favor of prompt removal on account of the marked local destruction attending the contact between the foreign body and the mucous surfaces.

So great is the number of cases reported during the year that only unusual instances will be mentioned. In a case treated by Bonan, of Tunis, [211] tracheotomy had to be performed *in extremis*. The rest thus procured caused the vocal cords to sufficiently relax to loosen the foreign body,—a large piece of bone, —and it was easily grasped and removed with forceps. E. J. Macore [136] removed a piece of glass from the post-laryngeal space, where it had lain over a month without causing more than occasional spells of dysphagia and ejection of a little blood and mucus. Seifert [37] mentions, among other cases, that of a child who retained, between the vocal cords, a large piece of bone during a period of six months. Its triangular shape, with base upward, prevented its fall into the trachea, while its thinness and transverse position prevented all interference with breathing. G. Michelmore, of Tiverton, Eng., [6] treated a case of bronchopneumonia in which the cause was ascertained to be a plum-stone which the patient, a boy of 7 years, had inhaled nine months before. It was finally coughed up, after which uninterrupted recovery took place. Sennycy [158] relates an instance in which a child drew a cylindrical piece of wood into the trachea and finally coughed it out during a violent attack of coughing, along with much pus. In the meantime, tracheotomy had had to be performed to relieve threatened dyspnœa, and patient had gone through a severe attack of bronchitis. M. D. Briggs, of Champlain, N. Y., [59] describes a fatal case in a child of 7 years who had accidentally inhaled some dried peas with which he had been playing.

Schliep [116; 2] points out that fish- and other bones are reputed to lose their hardness when acted on by vinegar. By experiment he found that already, after fifteen to twenty minutes, small fish-bones are softened by vinegar at the body-temperature. Fragments of bone require somewhat more time. An even more energetic action was obtained with a 1- to 5-per-cent. solution of hydrochloric acid, and in practice he recommended its repeated application, in a 2-per-cent. strength, by means of cotton-wool

tampons. When the foreign body is situated in the œsophagus or appears to have reached the stomach, repeated swallowing of the solution is advised. In Algeria especially, where they are very common, horse-leeches are occasionally swallowed during careless drinking. In some instances they adhere to the respiratory mucous surfaces, constituting a foreign body, which becomes increasingly dangerous as the absorption of the patient's blood augments the parasite's size. Berthoud, [243 Oct.,'93] in a case of this kind, found that inhalations of the steam of a 1-per-cent. solution of carbolic acid caused the leech to let go its hold. E. N. Heard, of New York, [59 Mar.17,'94] to locate metallic bodies in the upper air-passages, attaches the metallic part of his hypodermatic syringe to the end of one of the bifurcating cords of a telephone-receiver and a silver dollar to the end of the other cord. The dollar being placed in contact with the patient's tongue and the needle of the syringe passed through the tracheal wall, the slightest touch against the metallic foreign body will cause a scratching sound in the telephone-receiver. Felix Semon, of London, [11 Mar.,'94] illustrates the danger of forcibly pushing down angular foreign bodies which have entered the mouth by relating a case in which, a piece of rabbit-bone having been swallowed, a practitioner attempted to push it down and caused dangerous traumatic perichondritis of the larynx. Thyrotomy was performed during the acute stage of the perichondritis and the rabbit-bone successfully removed.

Fracture of the Larynx.—Lipps [336 Nov.6,'94; 100 May 15] studied fracture of the larynx upon dead subjects by submitting these to the traumatisms most usually acting as cause. As to frequency, strangulation with the hand caused fracture of the hyoid bone five times, of the thyroid cartilage six times, and of the cricoid seven times. The laryngeal mucous membrane remained unaffected in all. Fist-blows upon the larynx caused in six cases fracture of the hyoid only once and of the thyroid and cricoid simultaneously five times. In reporting a case, Lipps advocated precautionary tracheotomy and subsequent treatment calculated to prevent contraction of the parts. H. Lockwood, of Sheffield, [22 Feb.21,'94] records the case of a man whose necktie had been caught in revolving belting. Notwithstanding tracheotomy he died three days later. At the autopsy all the organs on a level with the larynx, including the latter, were found either fractured or torn, the epiglottis being

transversely severed from the larynx proper. The tear in the œsophagus had, it was thought, allowed the liquid that the patient had attempted to swallow to find its way into the larynx and trachea, all sensation in the upper larynx having been lost through injury to the superior laryngeal nerve. Laugier, of Paris, described [37] Mar., '94 a case before the Société Anatomique illustrating in a forcible manner the effects of strangulation in causing death without leaving external evidence upon the murdered individual. An old woman was found dead upon the street. Although everything pointed to death from a natural cause at first, the thyroid cartilage and the hyoid bone were found fractured and the pharynx and larynx filled with blood-clots. An interesting case of fracture in which defective union took place is related by Max Schaeffer, of Bremen. [69] Nov. 23, '95

C. B. Campbell, of Washington, D. C., [760] Jan. 27, '94 relates the case of a medical student who was playfully drawn over a desk by a comrade who had grabbed him by the neck, his right thumb being over the great cornu of the hyoid bone on the right side and his index finger over the left. Quick lateral compression caused fracture of the great cornu of the hyoid bone, near its body. Rather active symptoms appeared the second day, but uninterrupted recovery took place without treatment, the patient not having carried out the instructions given him.

Laryngeal Paralysis. — Max Laehr [69] Nov. 9, '95; [2] Feb. 17, '94 reported five cases of abductor paralysis,—three of peripheral and two of central origin. The first case, a man aged 69 years, had malignant disease of the œsophagus, the obstruction being at thirty centimetres from the teeth. Both cords moved outward very slightly during inspiration, but they closed satisfactorily on phonation. On deep inspiration the cords traveled inward and were somewhat flaccid. The second case, a woman aged 50 years, had, shortly after influenza, attacks of difficulty of breathing, which gradually became less frequent and eventually disappeared. When seen she had double abductor paralysis, the cords standing rather nearer the middle line than the cadaveric position. The third patient, a man aged 23 years, had faucial diphtheria. Later he complained of shortness of breath and regurgitation of fluids through the nose. There was no outward movement of the left cord during inspiration, and very little of the right. He improved very considerably,

fluids ceased to regurgitate, and some abduction of the cords was possible. The fourth case, a man aged 66 years, had total recurrent paralysis on one side. He was thought to have multiple sclerosis,—tremor, etc., being present. The fifth patient was a man aged 24 years, with undoubted multiple sclerosis, who had double abductor paralysis, with secondary contracture of the adductors. In three of the five cases there were no laryngeal symptoms. In many peripheral and central affections of the recurrent laryngeal nerve there is not only abductor, but also a total paralysis of the larynx, the cords being in the cadaveric position. The inspiratory stridor with perfect voice is looked upon as due to secondary contracture of the adductors. The author shows how these cases further confirm Semon's views as against the theory of primary contracture of all the laryngeal muscles, the adductors predominating. Post-diphtherial abductor paralysis is uncommon, only a few cases having been recorded. The slight abducens paralysis in this case, the double-sided pharyngeal and laryngeal paralysis, and the rapid improvement are against a central lesion. In the second case there was no reason to assume a central lesion; the condition was probably due to a neuritis following influenza. Abductor paralysis is very rare in multiple sclerosis, but perhaps it will be more frequently found when the larynx is systematically examined. The comparative frequency of laryngeal paralysis in tabes has been distinctly supported in several papers during the year, as will be seen below.

In the course of a study of the laryngeal paralysis occurring in chronic nervous diseases, W. Permewan, of London, [11] examined laryngoscopically 34 cases of general paralysis in the County Asylum at Rainhill. Of these, only 3 were in the well-marked third stage; 9 were in the first stage, while the remaining 22 were in the varying periods of the second stage. The results were as follow: 1. Character of the voice. In some cases it was notably high-pitched and monotonous,—"sing-song" it might be called; in others it was quite normal. In only 1 case, where there was almost complete paralysis of one vocal cord, was any characteristic quality noted. 2. Sensibility of pharynx and larynx. In the early stages mostly normal, but in nearly all the second- and third- stage cases it was notably diminished. In 2 cases there was hypersensitiveness of the pharynx. 3. Paralysis of palate.

In only 2 cases was there any want of power,—1 with a normal larynx, the other combined with bilateral abductor paralysis of the larynx. 4. Laryngeal paralysis. In 7 there was more or less disturbance of laryngeal movement. The author arrives at the following conclusions: 1. That the larynx is not infrequently affected in general paralysis of the insane. 2. That this affects first and chiefly the abductors. 3. That this does not necessarily depend on the association of tabes dorsalis with the more generalized disease, but is the direct result of the degenerative and inflammatory changes which affect the central nervous system in general paralysis. Permewan also examined two cases of disseminated sclerosis and a case of bulbar paralysis. In the former the laryngeal muscles were unaffected. In the case of bulbar paralysis he was able to watch the onset of abductor paralysis becoming absolutely complete, and the supervention on it of affection of the adductors. The other usual symptoms of bulbar paralysis were present in a marked degree.

At a meeting of the Laryngological Society of Berlin, Kroneberg [11 Feb.,'94] showed a patient in whom the diagnosis of tabes was definitely arrived at only after an examination of the larynx. During calm respiration the right ventricular band approached the median line and made only slight abductive movements, whilst the left band moved in a jerking manner. In the last few weeks a tremor had replaced the jerks. This Kroneberg does not consider to be an ataxic symptom, but caused by muscular degeneration. Rosenberg reported two cases of recurrent paralysis in tabes. He deemed it advisable that, from a general medical point of view, those changes in the larynx which so frequently appear among the first symptoms of tabes should be watched with closer attention.

Grabower [136 Jan.15,'94] performed a post-mortem examination in a case which had been considered as one of recurrent paralysis of central origin, and found an aneurism of the aorta which had eroded the first and second dorsal vertebræ and the lower cervical vertebra, the recurrents being in no way involved. Schlesinger, of Vienna, [8 Nos.26,27,'94; 11 Nov.] also had occasion to perform an autopsy in a case of tabes, and found degeneration in the postici. In a comprehensive paper S. Moritz, of Manchester, [90 May,'94; 11 June] classifies the symptoms which precede or accompany the other manifestations

of locomotor ataxy in the following way: 1. Disturbance of coordination in the respiratory function or phonation,—a true ataxy of the vocal cords. 2. Spasmodic affections, the so-called "laryngeal cryses." 3. Motor paralysis of laryngeal muscles. 4. Paræsthesia, hyperæsthesia, or anæsthesia of the laryngeal mucous membrane. An ataxic condition of the vocal cords is, perhaps, one of the earliest laryngeal signs of locomotor ataxy. In some cases the patient suddenly and unexpectedly loses his voice, or at least the power of articulating, and the voice becomes thick, dull, and discordant, as though the vocal cords did not act in unison. Krause, who was the first to observe this interrupted movement of the vocal cords during adduction and abduction, describes the cords as being suddenly approximated, then remaining still in a semi-adducted position, and then approximated in the median position. The cords, after having been driven together with great force, recoiled during abduction into the most extreme inspiratory position. The laryngeal crises are characterized by their spasmodic nature. Occasionally they are attended by vertigo, profuse perspirations, lightning pains in the extremities, pains in the back, etc. The laryngeal crisis is seldom fatal. These attacks may come on very frequently or there may be only one or two during the whole course of the disease. Laryngeal paralyses are frequently met with as signs of locomotor ataxy. Burger, in an analysis of 84 cases of laryngeal paralysis in ataxy, summarizes the results as follows: Abductor paralysis, bilateral 46, unilateral 11; paralysis of abductor and of thyro-arytenoid muscles, 8 cases; complete paralysis of recurrent nerve, 6 cases. In cases where post-mortem examinations have been made, changes have been found in the medulla oblongata. These changes consisted in the presence of foci of degeneration in the nuclei of the spinal accessory and vagus nerve, in the posterior pyramidal tracts, and in the floor of the fourth ventricle. Degenerative changes were also found in the peripheral laryngeal nerves, the vagus, and the recurrent. The laryngeus superior was usually unaffected. In a few cases the postici muscles were found degenerated.

Botey, of Barcelona, $^{918}_{\text{July,'94}}$; $^{26}_{\text{Aug.1,'94}}$ describes several cases of abductor paralysis due to syphilis and shown to be such by the absence of any other cause and by rapid recovery under antisyphilitic treatment. The author concludes that (1) the most frequent

paralysis of the larynx of syphilitic origin is paralysis of the recurrent nerve or of one of the posterior crico-arytenoids; (2) this paralysis is very often bilateral, but many unilateral cases may exist unrecognized, as no effect is produced on respiration and but little on the voice; (3) these paralyses are very rarely accompanied by marked syphilitic lesions of the larynx, and when they exist are quite independent of any syphilitic lesion which may happen to co-exist; (4) they are due almost always to disease of the peripheral nerves or nervous centres, and hardly ever to affections of the muscles or the crico-arytenoid articulation.

In an interesting paper on "The Laryngeal Motor Anomalies, Abductor Tonus, and Abductor Proclivity," James Cagney, of London, [6 June 16,'94] studied the diminished resistance of the abductor muscles. He suggested that, as the nucleus presides over the nutrition of the nerve and muscle, the cause of the peculiarity may be looked for in the nucleus alone. As to the other peculiarities of the abductor system, tonus and absence of a cortical centre, he argues, relying on analogies, that the latter is the cause of all the rest, the peculiarities being thus made to account for each other. This paper gave rise to a spirited discussion with Semon. [6 June 22, July 14,21,'94] Valuable reviews of the subject of laryngeal paralysis were published by A. Fasano [1097 Apr.,May,July,'94] and W. Permewan, of London. [187 July,'94]

Laryngismus Stridulus; Spasm of the Larynx.—In 144 cases of this disease, observed by Stage, [374 p.251] 79 were boys and 65 were girls. In 55 the disease appeared at the age of from 1 to 6 months, in 55 from 6 to 12 months, and in 34 after the first year.

In an interesting paper William Squire, of London, [22 July 28,'94] submits evidence to demonstrate that laryngeal spasm is a consequence and not a cause of rickets in children. Impeded respiration in early life frequently results from the arrest of development and nutrition which constitute rickets. Kassowitz, of Vienna, [84 No.28,'94] reports 172 cases to demonstrate that glottic spasm and tetany in children always depend upon acute rachitis. The treatment should, therefore, mainly consist of phosphorus. In 100 cases—52 girls and 48 boys—studied by Bull, [158 B.14,E.1,2; 51 Apr.'94] 94 showed positive signs of rachitis, 3 were free from this disease, and in 3 the diagnosis was uncertain. The majority of the cases occurred in May and June. Sixty-two were between the ages of 6 and 18 months when the disease developed. M. Scheier, of Berlin [286 Nov.,Dec.,'93]; Lumbau, [87 Oct.,'94]

and Przedborski [312 No. 11, '93] adduce cases to illustrate the connection between hysteria and laryngeal spasm. M. Zancudo [22 May 30, '94] observed two cases in which the spasm was due to the reflex irritation of impacted fæces in the colon, and J. W. Irwin, of Louisville, Ky., [19 Jan. 27, '94] one in which laryngismus stridulus followed a bullet wound in the arm.

Huchard, of Paris, [35 No. 28, '94] ascribes severe stridulous laryngitis in children to inflammation and spasm of the larynx, the spasm constituting the danger. He therefore recommends bromide of potassium in large doses, 60 to 70 grains (4 to 4.65 grammes) per day for a child 4½ years of age, and intubation or tracheotomy in menacing cases. Grazzi, of Florence, [37 July, '94] cured a case of spasm of the glottis in an adult by removing a small piece of the uvula, and speaks with favor of forced dilatation of the glottis by means of graded cylinders and especially-constructed forceps. H. Bidon [46 Jan. 15, '94] successfully tried Leloir's method,—compression of the phrenic nerve with the index finger placed between the two lower attachments of the right sterno-cleido-mastoid, repeated five times a minute.

Tumors of the Larynx.—F. Massei, of Naples, [37 Dec., '93] in view of the fact that *papillomata*, although liable to recurrence, as a rule, nevertheless frequently disappear spontaneously after tracheotomy, thinks that we are warranted in accepting Virchow's view that, while some of these growths approximate fibromata in constitution, others are inflammatory in character. He therefore considers the active measures, thyrotomy and laryngectomy, recently employed, as unwarranted, operation through the mouth, or tracheotomy, sufficing for all cases. The author recommends the curette, followed by local applications of a 10-per-cent. solution of ichthyol and a spray of a 1-per-cent. solution of the same. In case of recurrence, tracheotomy not only serves as a capital palliative, but also as a means of cure. In a case reported by Percy Kidd, of London, [11 Apr., '94] operated by him by thyrotomy, recurrence ensued twice within three months, a thyrotomy being done each time. In the discussion following the reading of the paper, Semon remarked that, while brilliant results were sometimes obtained, recurrence generally took place after thyrotomy. He had known a case in which no less than seventeen thyrotomies had been necessary on account of repeated recurrences. Another element against this

operation is the partial loss of the voice, exemplified in cases reported by W. C. Phillips [11 Nov.,'94] and Abbe, of New York. [462 Dec.,'93] The advantages of tracheotomy, or the transoral operation, were illustrated by a large number of cases reported during the year. R. P. Lincoln, of New York, [1 Dec.20,'93] describes an interesting case of recurrence at a new site of a papilloma, in a case in which an interval of twenty-two years had occurred between the first extirpation by thyrotomy and the second operation, which took place four years ago. A list of thirty-four cases of papillomata recurring after operation is appended.

Chiari, of Vienna, [136 June 15,'94; 451 Oct.] after examining histologically thirty-eight cases of so-called *fibromata* of the larynx, concludes that these growths should be regarded as circumscribed hypertrophies of the superficial parts of the cord, not as fibromata. They are generally situated toward the middle of the free border of the vocal cord, and vary in size up to that of a small bean. They are covered with stratified pavement-epithelium and are made up of a fibrous connective tissue, at times compact, but generally loose, containing cavities with or without an endothelial lining, empty or containing blood-clots or fine granular material. The vessels are generally numerous. It would be more exact, therefore, to designate these growths as polypi. Cases were reported during the year by Dundas Grant, of London [11 Aug.,'94]; Rethi, of Vienna [57 Apr.15,'94]; de Rossi [1105 V.2,'94] and Rousseau, of Brussels. [11 Dec.,'94] The latter author makes a strong plea in favor of galvano-cautery in operations about the larynx. Gevaert [37 V.19,No.10,'94] describes a case in which stricture of the larynx followed the removal of a fibrous polypus by means of forceps six years before. The glottis was found to be occupied by a web or membrane, a small aperture being left near the arytenoid. Incision with Mackenzie's concealed knife and dilatation succeeded in partly overcoming the stenosis.

In a case of large *cyst* of the ventricular band, E. Fletcher Ingals, of Chicago, [1 Sept.1,'94] unsuccessfully tried injections of lactic acid. He then tried deep injections of carbolic acid, which was employed in solutions in glycerin and water of from 8 to 10 per cent. of the acid, from 15 to 20 minims (1 to 1.3 grammes) being used at each injection, and the injections repeated once in from five to seven days. These injections were repeated eight times in all, 20 minims (1.3 grammes) of the 10-per-cent. solution being

used each of the last six times. At the end of this time the tumor had nearly disappeared, and the injections were discontinued with the belief that the cyst had been obliterated. The patient was subsequently seen at intervals of three or four weeks for three months after the last injection, and there had been no return of the growth. The patient felt that his throat was perfectly well, and it presented the appearance of a normal larynx. The especial points of interest in the case consisted of the deeply-seated position of the cyst and the impossibility of removing it without removing a large part of one side of the larynx. Its walls were so thick that crushing, tearing, or cutting operations were out of the question.

Percy Kidd, of London, $^{11}_{\text{Apr.,'94}}$ describes a case of *angioma* in a woman, aged 30, who complained of hoarseness and a sore feeling in the throat which had existed for a period of twelve months. Laryngoscopical examination revealed the presence of a rounded tumor the size of a pea springing from the left vocal cord, about the junction of the anterior and middle thirds. The growth presented a pinkish-gray color and was attached by a broad, flat pedicle which permitted a considerable degree of movement. After cocainization of the larynx the tumor was removed in two pieces with Mackenzie's cutting forceps. No bleeding of any note resulted. Three days later the left vocal cord presented a reddish, irregular appearance, but no trace of the growth remained. The patient ceased attending after this, and had not been seen again.

Felix Semon, of London, $^{11}_{\text{Mar.,'94}}$ reports a case of acute œdema followed by *hæmatoma* of the left half of the larynx in which transitory immobility of the left vocal cord occurred. The patient had received a kick while playing foot-ball, the foot striking the left side of the larynx. F. Marsh, of Birmingham, $^{11}_{\text{Aug.,'94}}$ describes a case of multiple *adenomata* in which the growths were removed by thyrotomy without preliminary tracheotomy. Scheppegrell, of New Orleans, $^{12}_{\text{Nov.,'93}}$ publishes a valuable illustrated review of the subject of non-malignant tumors of the larynx.

Malignant Growths of the Larynx.—D. Bryson Delavan, of New York, $^{1}_{\text{Oct.14,'93}}$ makes an earnest appeal tending to counteract the withholding of reports of operations for the relief of cancer. He rightly recommends that a full, painstaking, and accurate account be given of the history of every malignant growth removed from

the upper air-passages. J. W. Gleitzmann, of New York, [11, July, '94] dilates upon the importance of an early diagnosis of malignant tumors of the throat, the chances of success of operative procedures being thereby greatly increased. Many cases are cited to sustain the point.

Toti [1156, p.1, '94] discusses the sign considered pathognomonic of cancer of the larynx by Semon, *i.e.*, immobility of the affected vocal cord. Although agreeing with Gottstein that this immobility may be met in syphilis, he cites three cases of cancer in which motion is either greatly diminished or completely suppressed.

Virchow, of Berlin, [41, July 30, '94] performed autopsy in two cases in which extirpation of the larynx for *carcinoma* had resulted in permanent cure of the vocal trouble. The first was one of Thiersch's cases operated four and one-half years before death from pneumonia. No evidence of carcinoma could be found anywhere. The other case had been operated on in 1891 by Wolff, and died two and one-half years later of metastases in the lung. Julius Wolff [41, July 30, '94] gave details concerning the case alluded to by Virchow and reviewed the cases that had lived prolonged periods after extirpation. Four were living, respectively, thirty-two months, three and one-half years, four and one-third years, and four and one-half years without the least evidence of recurrence. Three had remained free from recurrence from four and one-half to six years, and had then died of other diseases. Three had died from other diseases, between twenty and twenty-two months after operation, without evidence of recurrence. In a case of Thiersch's there were metastases in other parts,—cervical lymphatic glands, mediastinum, and lungs. Grayson, of Philadelphia, [9, Apr. 7, '94] alludes to the rarity of metastasis in laryngeal cancer. Glandular involvement is a late feature, usually not making its appearance until ulceration has existed for some time.

Stoerk, of Vienna, [8, Apr. 13, '93] publishes an account of a case in which he had, after performing tracheotomy, opened the larynx, extirpated the growth, which occupied the right vocal cord, and, by means of a plastic operation, made up the gap. Six months after there had been no recurrence, the voice was good, and slight motion could be observed in the new cord. In a case observed by Krönlein [214, Jan. 15, '94] preliminary tracheotomy was also performed, but all effort, up to the time the report was made, proved unavailing to

remove the cannula. Rotter[3 Oct.24,'94] described a case in which he had performed extirpation and had applied an artificial larynx. The man now speaks in a loud and intelligible voice. To prevent pulmonary infection by mucus or secretions from the wound, the speaker had formed from the muscles of the pharynx a septum separating the buccal cavity from this wound, thus rendering it unnecessary to feed the patient with a tube or to renew the dressing so frequently. Three weeks after the operation the weight of the patient had increased 3 kilogrammes (6 pounds), and at the time of the meeting, six weeks after the operation, he had increased 9½ kilogrammes (19 pounds).

Cases of carcinoma submitted to operative measures were reported by Gluck[4 No.31,'93]; R. H. Woods, of Dublin[22 Dec.20,'93]; Cotterill, of Edinburgh[36 Jan.,'94]; Krönlein[214 Jan.15,'94]; Eeman, of Ghent[37 Aug.,'94]; and E. Herczel, of Budapest.[827 Dec.14,'93] A review of the subject was published by Dieulafoy, of Paris.[783 Aug.22,'94]

Felix Semon, of London,[11 No.1,'94; 5 May,'94] reported an instance of coexistence of *epithelioma* and of papilloma in several specimens from a growth, and without any evidence of transition into the one from the other. The case was reported as one of pedunculated angioma by Semon and Shattock.[2178 '91] Four months and a half later recurrence of undoubted epitheliomatous nature took place; and so the basis of the growth was entirely removed through the incision of subhyoid pharyngotomy. On the third day after the operation the patient suddenly became comatose, the temperature rose to 107° F. (41.7° C.), and death ensued twenty-four hours later. No clue to the cause of coma and the fatal issue could be determined at the post-mortem examination. The case is important as the first known instance of malignant disease of the larynx beginning in a pedunculated angioma. In a case reported by Charles Phelps, of New York,[1 June 28,'94] the tumor, occupying the whole extent of the left cord, had at first been considered as benign. Two months later Rice, of New York, pronounced it malignant; extirpation followed, but the patient died seventeen days after the operation. Section of the tumor showed a stroma of fibrous tissue covered with stratified epithelium containing nests of epithelial cells, many of which included "pearl bodies." The trouble having started three years before, during a violent spell of coughing which caused a sudden sensation of "rupture," and

total (and permanent) loss of voice, the author considers that there is little doubt that the injury to the cord during the paroxysm of coughing occasioned the benign growth which alternately suffered degeneration. In an histological study of primary epithelioma of the larynx [87 Apr.,'94] Dansac, of Paris, distinguishes (1) a dermoid pavement-epithelioma of the glottic mucous membrane; (2) an epithelioma of a superficial glandular form; (3) a deep glandular epithelioma or carcinoma *en nappe*.

Luc [286 Jan.,Feb.,'94] relates a case of a man of 23 years, in which an epithelioma presented so many features of tuberculosis laryngitis that the diagnosis as such was made. Tracheotomy being performed to relieve intense dyspnœa, the edge of the tracheal wound became fungous and assumed all the characters of cancerous ulceration. Histological examination showed the growth to be one of epithelioma. Several instances were reported during the year of patients who had suffered from epithelioma and had been operated on over a year before, in which the disease had not recurred. The case of Walker Downie, of London, [2 Mar.17,'94] in which the whole of the vocal cord had been removed after thyrotomy, was well seventeen months later; in two of Gluck's cases, [4 Dec.18,'93] operated on in the same manner, one was living seventeen months and the other five years later. In the latter case the raw surfaces had been cauterized with galvano-cautery. Fischer, of Hanover, [301 B.28,H.4,5,'94] operated on a case in 1889, again for recurrence in 1890. In 1894 the patient was still free from recurrence, probably the first instance in which a recurrent operation has proven curative. R. Krieg [1151 B.1,H.2,'93] relates a case in which an epithelioma of six years' standing had in no way affected the patient's general health. Arthur A. Bliss, of Philadelphia, [59 July 14,'94] describes an interesting example of squamous epithelioma.

A case of *sarcoma*, reported by W. R. H. Stewart, of London, illustrates [11 Apr.,'94] the influence of arsenic in this class of cases. The reporter had pushed the arsenic treatment, and within a month the patient was taking liq. arsenicalis, 15 minims (1 cubic centimetre), t. d. s., and sometimes even larger doses. The result, as far as the tumors were concerned, was marvelous. Sarcomatous glands in the neck—the tumor was a multiple one—gradually got softer and disappeared, the edges of the ulcers "seemed to melt away," and the naso-pharynx became fairly free. The swelling in

the tongue, however, did not get less, but it ulcerated and a lump came away from it, which under the microscope proved to be simply a blood-clot. About six weeks after commencing the arsenic his fingers and toes began to feel numb, the feet swelled; his knees began to give way, and he fell on them occasionally when walking. The arsenic was then left off until July 4th, when it was recommenced, but it could not be continued in such full doses again. The trouble in the throat had gradually become worse.

Cases of round-celled sarcoma were reported by Arthur A. Bliss, of Philadelphia,[59] July 14, '94; Pröbsting, of Wiesbaden,[136] Oct. 15, '94; and T. Gluck.[4] Dec. 15, '93 In the case of the last-mentioned operator recurrence had not taken place two years after the extirpation of the growth. A spindle-celled sarcoma was reported by H. S. Birkett, of Montreal.[39] Oct., '93 The patient, a pregnant woman, suffered with dyspnœa, hoarseness, and then almost complete aphonia. Laryngoscopical examination showed a subglottic tumor, dark red in color, nearly filling the larynx; vocal cords free. Tracheotomy was performed; labor induced; the growth diminishing in size. Three weeks later thyrotomy was done and the tumor was removed, its base being touched with chromic acid. It was found to spring from the right side, just below the vocal cord. The wound was closed and recovery followed. F. T. Paul and Middlemass Hunt, of Liverpool,[157] Jan., '94 showed a case of spindle-celled sarcoma of the larynx, occurring in a boy aged 12 years, before the Liverpool Medical Institution. The growth was a very large one, filling the entire larynx. Hunt removed with forceps all the parts of the growth within reach, but thyrotomy became inevitable for a thorough operation. Paul performed it, removed the remaining portions of tumor, and thoroughly scraped the seat of implantation,—the anterior part of the right cord. The boy made an excellent recovery. Paul lays stress upon the utility of thorough removal of these growths and upon a differential recognition of their histological character, previous clinical experience having shown that sarcoma in the larynx is generally mild, thus presenting a modified character of malignancy when compared to sarcoma in other parts.

Pachydermia Laryngis.—After a brief introductory history of pachydermia laryngis and an outline of its pathology by B. Fraenkel, of Berlin, Chiari, of Vienna, read a valuable paper upon

this affection before the Laryngological Section of the International Congress. The following abstract was prepared by the author:—

"The verrucous form of pachydermia is identical with the papilloma of the laryngologist and has no relation to the diffuse form. Diffuse pachydermia may be primary or it may be secondary to some other affection of the larynx, such as tubercle or syphilis. In Chiari's experience typical pachydermia is a very rare disease. He describes several forms.

"I. The most frequent and mildest form is a thickening and loosening of the epithelium of the interarytenoid fold and vocal cords, such as occurs so frequently in chronic catarrh. The treatment is that of chronic catarrh, consisting of inhalations, insufflations, and especially applications by means of a brush, and cauterization. The best applications are those of lactic acid or iodine, but nitrate of silver is apt to cause increased thickening of the epithelium. If there is a well-marked localized thickening ('singers' nodule') it may be removed by means of fine cutting forceps. Small singers' nodules may disappear under the influence of rest or simple applications of nitrate of silver in solution or in the solid stick. If they are of considerable size the forceps is to be preferred.

"II. The typical form of pachydermia laryngis, as it affects chiefly the vocal processes, calls for a plan of treatment varying according to the circumstances of the case, and authors differ greatly in their opinions. Some recommend purely expectant treatment,—avoidance of tobacco, strong drinks, or abuse of the voice; others recommend the internal administration of iodide of potassium, which, though occasionally of some benefit, may also at times produce general impairment of health. Chiari recommends the use of electrolysis, as employed by Moll, of Arnheim,—a current of from 10 to 12 milliampères for from three to five minutes at a time. He considers it the best means for preventing recurrence, but good results have also followed operation by means of any of the ordinary cutting forceps or cold or electro-caustic snares.

"III. Large genuine pachydermic growths in the interarytenoid fold interfere very materially with the voice. Unfortunately, treatment by means of cutting forceps, hot or cold snares, etc., does not guarantee freedom from recurrence.

"IV. The last group includes those circumscribed thickenings, outgrowths, or nodules which accompany tuberculosis, syphilis, chronic perichondritis, and perhaps also lupus, which have been referred to as 'secondary' or 'accessory' pachydermia. Their prognosis depends on their etiology, as also does their treatment, the latter varying according to the nature of the most distressing symptoms. Naturally the syphilitic form is much more favorable than the tuberculous, but it not unfrequently resists treatment by means of the ordinary specific remedies. Operative treatment of the same kind as for the typical primary form is called for in suitable cases,—that is, if the general health is good and the respiration or voice is seriously interfered with by the local disease. The method of treatment which, so far, is most to be recommended is the use of electrolysis by means of a bipolar instrument with a current of from 10 to 15 milliampères. This causes no reaction, and seems to protect against recurrence better than any other treatment.

"'There is no doubt that pachydermia laryngis, whether in the simplest form in the interarytenoid space or in the typical form on the processus vocalis, is only a symptom of chronic catarrh, and not to be looked upon as a disease in itself.'"

Damieno, of Naples, $\frac{11}{\text{July, '94}}$ read a paper upon the same subject, of which the following is also an auto-abstract:—

"I have repeated my histological examination of another piece removed by Professor Massei, by means of Schroetter's forceps, from the left vocal cord, of oval form, grayish color, and a few millimetres in thickness. After the usual manipulation and staining with hæmatoxylin and carmine, under a low power, the sections showed a marginal layer of some thickness, while under a higher power one saw a stratified pavement of epithelium becoming changed into an epidermoidal layer with flattened cells without nucleus. Into this layer entered, like so many digitations, the papillæ; here the preparation appears like a normal section of stratified skin in its epidermoidal layer. To this followed the subepithelial stratum, which was entirely infiltrated with round cells, replacing the connective layer which was wanting in my preparations, perhaps because normally in the cord little or no connective tissue exists—so much so that the mucous membrane may be found almost in contact with the perichondrium. This fact con-

firms, once more, the view that pathological thickening of the laryngeal mucosa is developed only in the parts furnished with pavement-epithelium; and if Flatau has been the first to describe pachydermia of the epiglottis it is because, as Heymann and, more recently, Chiari have shown, in the epiglottis one finds some islands of flattened epithelium.

"From histological studies and clinical observations I feel myself authorized to face the very serious question of the connection of cancer and pachydermia. Not only do I declare myself opposed to the idea of Klebs, but I have arrived at the conclusion that pachydermia and cancer are two different processes. In those cases in which this terrible metamorphosis has been verified I am compelled to hold that the cancer was already in existence from the very commencement, under the superficial form of pachydermia. In cancer there is true epithelial proliferation, the cellular nuclei being most active; the epithelial products penetrate everywhere in the lymphatic vessels and blood-stream. In pachydermia, on the contrary, there is no true proliferation, although there is hypertrophy of the pavement-epithelium such as takes place in a corn; its tendency is rather to push more toward the exterior, and the cellular nuclei become altered and atrophied, and finish by disappearing."

TRACHEOTOMY.

In the opinion of Cnopf, of Nuremberg, [34 May 5, '94] there are two factors to be reckoned with when false membrane is present in the larynx,—(1) irritation of the respiratory centres and (2) narrowing of the larynx. Since the upper lobes of the lungs are under favorable conditions as regards inspiration, and the lower lobes as regards expiration, distension occurs in the former and atelectasis in the latter. The author's observations extend over 130 cases of laryngeal obstruction in children. On admission the position of the diaphraghm was marked out on the chest behind, and. subsequent variations noted. In 67 cases the diaphragm stood at the tenth rib in 3 cases, at the eleventh in 13, under the eleventh in 13, and at the twelfth in 38. The deepest position of the diaphragm was thus observed in a majority of cases, and this at all ages. In 112 out of 126 the deep position was noted by the third day, and usually it was present on admission. In tracheotomized

cases carefully observed the position of the diaphragm was rapidly raised one space in 12 cases and two spaces in 13. In only 4 cases did the diaphragm remain at the same level after tracheotomy. The position of the diaphragm is thus a measure of the laryngeal stenosis. The question of vesicular breathing and of the pulse must be considered, but with the arrival of the diaphragm at its deepest position the time for tracheotomy has come.

In a paper giving the results of 161 tracheotomies performed in the Western Hospital, Haverstock Hill, Eng., W. Gayton [6 Aug.11,'94] calls attention to the excellent results obtained in diphtheria, the mortality being only 26.48 per cent., including cases brought in in a hopeless condition. An earnest appeal is made on behalf of early intervention. Ch. Gevaert [1160 May,'94] gives statistics of 162 cases operated on in Belgium, giving a percentage of 27 per cent. of deaths. The influence of early intervention may be appreciated when comparison is made with Aldibert's results [1068 May 12,'94] in patients tracheotomized only when fears of sudden suffocation were entertained,—a death-rate of 74.83 per cent. Of course, the fact must be borne in mind that some recoveries are credited to tracheotomy in bolder surgeons' statistics that would have taken place without operation, and that Aldibert's statistics are, in reality, based upon cases practically *in articulo mortis*. But that proportion, could it be established, would doubtless not militate in favor of abstention until the last moment. The symptoms indicating the necessity of operating to Gayton were: (1) stridor,—the louder, the more urgent; (2) sucking in of intercostal spaces and bending of costal cartilages; (3) urgency of dyspnœa; (4) cyanosis. Such a picture as that shown by Aldibert is unwarranted, in the light of our present knowledge regarding timely intervention. Statistical articles were also published by Guelliot [577 Aug.,'94] and Schmid, [183 Apr.12,'94] but based on a too small number of cases to furnish satisfactory data.

After tracheotomy Guelpa [73 No.51,'94] irrigates the larynx and trachea of a diphtheritic child every hour with a solution of 1 to 1000 of perchloride of iron, lowering the head and trunk to prevent the ingurgitation of the liquid. The lower extremities are also slightly raised and kept so several days. This position is easily tolerated and is believed by the author to be very efficacious in preventing the occurrence of broncho-pneumonia. Violent and

explosive cough is alleviated, the strength of the patient spared, and the mechanical extension of the malady rendered less probable.

Moussous and Rocaz, of Bordeaux, [673 Dec.,'94] give statistics of the method of treating broncho-pneumonia consecutive to tracheotomy. The first step is to isolate all cases of broncho-pneumonia following diphtheria, whether tracheotomy has or has not been performed. The patients are allowed to remain only for several days in a certain room or ward, which is carefully aired and disinfected before receiving new cases. After tracheotomy has been performed a gauze bandage is placed in front of the cannula, having been previously soaked in the following liquid: Essence of Ceylon cinnamon, 6 grammes (1½ fluidrachms); alcohol (85), 50 grammes (1½ fluidounces); neutral glycerin, 60 grammes (1¾ fluidounces). They prefer this fluid to creasote, the vapor of which is less antiseptic and more irritating than cinnamon. They have thus treated 106 children during a period of two years, with 68 recoveries,—a percentage of 64.1. Chas. L. Scudder, of Boston, [99 p.405,'95; 814 Mar.1,'94] curetted the trachea after tracheotomy in diphtheria in a boy, aged 4 years, who had been ill two days. Owing to progressive dyspnœa tracheotomy was performed. Very little tonsillar or pharyngeal disturbance was noticeable. Two days after operation the secretions from the tube grew sticky. They were softened by a spray close to the tube, but twenty-four hours later they diminished, and the child grew cyanotic and suffered greatly from labored breathing. All of the usual procedures were tried to keep the tube clear, but without avail. Finally a dull, wire, intra-uterine curette was introduced into the wound, gently carried to the bifurcation of the trachea, and all sides of the trachea—its whole circumference—systematically and thoroughly curetted. As the curetting continued, pieces of membrane—one of which made a complete cast of the circumference of the trachea—were withdrawn through the wound. The hæmorrhage was slight. The relief to the dyspnœa was immediate. The tube was replaced and the boy made an uninterrupted recovery; one or two pieces of membrane came away the following day. Scudder says the suggestion to curette the trachea in such conditions was made to him by Wheeler, of Chelsea, Mass. He has not found a similar case previously recorded. In this instance the inflammation was probably qui-

escent and the membrane was beginning to come away. It was an opportune time to curette. In a case treated by Turner, of London, [6] Sept.20,'93; [11] Apr.,'94 the inner tube failed to relieve the dyspnœa, and it was found that the outer tube had become detached from the guard-piece. It had been sucked down, and was only reached after further enlargement of the tracheal wound and inversion of the patient.

Masse, of Bordeaux [164] Nov.16,'93; Denucé, of Bordeaux [70] Oct.5,'93; and Moizard, of Paris, [14] Nov.25,'93 published cases demonstrating the value of Laborde's rhythmic traction of the tongue in the asphyxic symptoms occasionally attending tracheotomy.

Kirmisson, of Paris, [14] July 1,'94 describes the case of a young man, 16 years of age, who had been tracheotomized at the age of 11 years for laryngeal diphtheria and whose cannula had remained in place ever since. The author withdrew the cannula with precaution and was surprised to find that no difficulty in breathing through the larynx existed. He does not know the causes which had prevented the removal of the tube. The fistula was closed by autoplastic operation and cure resulted. The author discusses the varieties of tracheal fistulæ and their treatment. A good thesis upon the subject was published by P. Delassalle, of Paris. [2061] '94

LARYNECTOMY.

J. Solis-Cohen, of Philadelphia, [5] Mar.,'94 publishes the following note of a man, exhibited before the American Laryngological Association in 1893, from whom, fourteen months previously, he had removed the larynx and the first ring of the trachea for carcinoma, and whose second, third, and fourth rings, which had been incised anteriorly in a preliminary tracheotomy, he had stitched to the integument, thus completely shutting off the trachea from the pharynx: "This man had learned to speak with a well-modulated voice audible more than forty feet, and sang before the Fellows a few stanzas in which the changes of pitch of the voice were quite as good as those of a normal voice during hoarseness. The patient distends the integument above the tracheal orifice into a sac of air, which he propels against two folds, at the lower portion of the pharynx, which appear to be portions of the lower constrictor muscles. The modulation of the voice points to muscular tension in the new phonal reeds, which would hardly occur

were they mere favorably located folds of adventitious tissue. At the date of writing this record, eighteen months after the operation, there has been no sign of recurrence. The man is strong and happy, breathes without a cannula, and has been thus far permanently freed from pain, cough, and difficulty in swallowing. Recently, in meeting a patient treated palliatively by tracheotomy, and whose voice is hardly audible, he stated that he would not change conditions for the world, as he would not care to live with his tumor and his tube." In a study of the case Harrison Allen, of Philadelphia, [9 Mar.17,'94] concludes that the voice was created by the presence of an adventitious resonating chamber established in the region of the larynx, and that the utterances were of the nature of whispers re-enforced by the air in this sac.

E. Kraus, of Paris, [283 Nov.19,20,'94] reports a case from which a malignant gland, the cricoid cartilage, and tracheal rings were removed. One year later the laryngoscope showed the larynx to be filled with granulations, the patient being unable to breathe without the cannula. The granulations were destroyed by means of galvanocautery and an artificial larynx inserted. The latter was made of a spiral coil, so that it could be compressed and easily introduced and follow the movements of the neck without causing irritation. The patient could speak with a good voice and expectorate by the mouth.

R. Gordon Macdonald, of Glasgow, [2 Dec.20,'93] also had a very successful case of excision of the larynx, hyoid bone, and five rings of the trachea for cancer. The patient could swallow on the second day, and speaks well with an artificial larynx. In a case reported by Dwight L. Hubbard [11 May,'94] the epiglottis was not removed, and seven weeks after operation an artificial larynx was introduced. With the aid of a reed the man is able to speak fairly well.

Larynectomy in one case was reported by Mackay, of Huelva, Spain, [6 Apr.14,'94] and in four cases by A. Leonardi. [461 Apr.,'94]

Reviews of the subject were published by Perruchet, of Paris, [2031 '94] and Pinçonnat. [230 Oct.,'93]

A new method was described by Henry L. Swain, of New Haven. [59 July 14,'94] The operation was performed on a man, aged 42 years, who had an epithelioma that filled the entire larynx, rendering the use of a general anæsthetic dangerous. Tracheotomy was

therefore under cocaine. Five days later the larynx was removed by W. H. Carmalt. Incision was made from the thyroid bone to sternum. A low tracheal opening was made, and a sponge Trendelenburg cannula introduced. Cross-incision made at top of wound to sterno-cleido-mastoid muscles on either side. The larynx was then laid bare, and, bleeding being checked, a bistoury was inserted back of larynx,—between it and the trachea. The trachea being liberated by a cut from a strong bistoury, the larynx was hooked up and dissection begun from below upward. The anterior wall of the œsophagus was carefully preserved until the arytenoid cartilages were reached. A cross-cut was begun, preserving a part of the mucous membrane of arytenoids and ary-epiglottic folds. The epiglottis was then cut across, its larynx freed, removed, all bleeding checked, and the epiglottis sewed on to the anterior wall of œsophagus, thus closing in the pharyngeal cavity and cutting off all communication from the wound in neck. Subsequently the wound in neck was sewed up tight, except enough of the lower part of median incision to allow of taking in the upper rings of the trachea, which latter were sewed into connection with skin-flap, making a circular opening turned upward and forward. The wound was dressed with plain dry dressing. No tube was left in the trachea. Patient stood operation beautifully, although it lasted two or three hours. The subsequent healing of wound followed without adventure, save a large stitch-abscess above and back of the trachea, which healed in a few days. Temperature reached 101° F. (38.3° C.) the second day and then went down to normal or nearly so and remained there. The internal wound at the base of the epiglottis was observed to heal by first intention and the patient could swallow water from the first, could take fluid nourishment at the end of a week and regular hospital diet at the end of second week. Internal and external wounds are both in healthy condition. The patient could make no audible sounds at first; later, hissing consonants were to be perceived, and now the briefest sentences and single words can be distinctly understood with the back turned; so that lip-reading is eliminated. There is nothing more than a whisper to the voice, but it has gained so much in strength of late as to promise more. The patient is working at his trade of a carpenter, wearing a tube in the trachea most of the time.

TRACHEA.

Compression of the Trachea.—F. G. Finley, of Montreal, [11 July, '94] records a case of Hodgkin's disease of seven years' standing in which, at the autopsy, the trachea was found surrounded by a cluster of enlarged glands of the size of a fœtal head. Intense stridor and dyspnœa had been present in the case, owing to compression of the trachea. In a case treated by Bernard Pitts [6 Nov. 24, '94] a goitre in a boy of 15 years caused nearly fatal dyspnœa. Venesection and opening of the trachea having re-established normal respiration, the goitre was removed, but the patient died, two days later, of broncho-pneumonia. Selter [20 B. 128, H. 1] studied the compression ulcers of the trachea and bronchi in cases of aneurism, and concludes that, notwithstanding the frequency of these ulcers, actual perforation is seldom caused by compression, other factors being the etiological factors in almost all cases.

Ulceration of the Trachea.—W. F. Chappell, of New York, [11 Nov., '94] reports the case of a woman in whom an abscess of the thyroid caused perforation of the trachea. The patient, when admitted to the hospital, was suffering from extreme dyspnœa of about two hours' duration and of sudden onset. Tracheotomy was performed, the opening being made between the thyroid and cricoid cartilages, and on introducing the finger down the trachea a mass could be felt. He then attempted to perform a lower operation, but the woman died. On post-mortem he found an abscess-cavity in the right lobe of the thyroid, which communicated with the trachea through an opening about one and one-half inches below the vocal bands. Previous to the onset of the dyspnœa the woman had had occasional attacks of aphonia.

Lardy and Photiades, of Constantinople, [197 '94] record a case of partial destruction of the cartilaginous trachea and stenosis of the entire lumen of the trachea. An opening was made into the trachea and the latter and the larynx curetted, after which a hard-rubber tracheal tube was temporarily inserted. A plastic operation was then performed to cover the split trachea and the temporary tube finally withdrawn. The patient breathes well and speaks with ease, but he requires frequent tubage.

Tumors of the Trachea.—Pogrebinsky, of Odessa, [136 June 15, '94; 451 Oct.] in a search through the literature of this subject, found only thirteen cases of *primary cancer*, four of which were doubtful. Patients

are more frequently men than women. The duration of the disease is about two years. The age of the patients was from 33 to 62 years. The symptoms were simply those of narrowing and ulceration of the trachea, with no typical characteristics for a differential diagnosis. In the majority of reported cases the diagnosis was not made during life. Only exceptional cases presented conditions favorable for a tracheoscopical examination. In one case of his own the disease was complicated by frequent attacks of perichondritis in the larynx, which made the diagnosis more obscure. Strictures of the trachea are more often syphilitic than cancerous. In syphilitic tracheitis there are generally evidences of ulceration first followed by a cicatricial contraction; whereas, in cancer the tumor causes increasing dyspnœa and, later, when ulceration occurs, there is expectoration. The question of differential diagnosis of primary cancer of the trachea still remains an open one.

Scheuer [2079] published a thesis giving a fair review of the subject of tumors of the trachea, and reported one of his own, an *adenoma*, including the sixth and eighth tracheal rings. The growth was removed by means of deep tracheotomy, and cure resulted.

MISCELLANEOUS.

Roussel [11] systematically perforates the crico-thyroid membrane for treatment of the larynx and interstitial intra-pulmonary injections. He thrusts an exploring needle into the laryngeal cavity and then injects solutions of pilocarpine, strychnine, etc., into the œdematous tubercular tissues. As a topical modifier of diseased tissues, he employs arseniate of strychnine, hypersulphite and phosphate of soda, or a solution of pure carbolic acid in almond-oil. For direct pulmonary absorption he advises spraying the above-mentioned remedies into the trachea, or oily solutions of menthol, thymol. etc. The author states that the perforation of the cricothyroid membrane is not difficult, that it does not disturb the patient very much, and leaves no trace whatever.

ŒSOPHAGUS.

Diverticula of the Œsophagus.—In an interesting study of the subject A. Fraenkel, of Berlin, [11] considered the etiology and pathology of this abnormality. He believes that diverticula

originate, in all probability, through the dilatation of the wall at a spot which, through traumatism, has become yielding. They are seated near the cricoid cartilage upon the posterior wall, and develop to a considerable size (ten to fifteen centimetres), compressing the œsophagus so much that a probang, if introduced, generally passes into the sac of the diverticulum instead of the œsophagus. The diverticula of traction are seated on the anterior wall, at a level with the bifurcation, representing funnel-shaped projections. They originate from a sloughing or shrinkage of bronchial glands, which, by their contraction, draw the anterior wall along with them. Ulceration frequently begins at the point of the funnel, and thus perforation of the wall of the œsophagus is caused. Thus, particles of food find their way into the trachea, the ramifications thereof, or into the pleura or mediastinum. In this manner originate gangrene of the lungs, sanious pleuritis or mediastinitis. Fraenkel showed specimens from two patients who had died in his department from gangrene of the lungs, both illustrating this genesis in the plainest manner. In a third case, also reported by Fraenkel, the same cause is to be found. Here, however, the diverticula of traction would have been overlooked, and the origin of the disease would have remained unrecognized if Zenker's method of dissecting the œsophagus had not been adopted. Cases were reported by Landgraf, of Berlin, [41 June 25, '94] and M. Vigot, of Paris. [14 Aug. 22, '94]

Dilatation of the Œsophagus.—Gustav Liebman, of Boston, relates [99 Dec. 7, '93] a remarkable case of dilatation of the œsophagus, with dysphagia and pneumatosis, in a girl aged 15 years. The trouble began at the commencement of her catamenia, two years before, the first flow being excessive and lasting eight days, and the second a week, when menstruation ceased permanently. The author ascribes the dysphagia and the resulting dilatation to a lack of reflex relaxation of the cardia during the act of swallowing, the great loss of blood having debilitated the nerve-centres in general and the one presiding over the reflex opening of the cardia in particular. The pneumatosis was due to the sucking of air on the part of the patient, who had employed this measure to assist in the downward propulsion of the food. The case ended in death.

Œsophagitis.—Pietkiewicz, of Baku, [520 No. 24, '94; 2 Sept.] describes the case of a laborer, aged 25, who consulted him on the tenth day

after having swallowed by mistake a teaspoonful of a 25-per-cent. solution of caustic soda. The man complained of severe pain about the throat and breast, and of having gradually become unable to swallow even fluids. Examination failed to detect anything abnormal, beyond intense congestion of the throat and white films over the soft palate, tonsils, and posterior pharyngeal wall. Accordingly a glycerin solution of tannin, with cocaine, was prescribed, to paint the throat. On the next day the man stated that after a second painting he had coughed out a "bowel," with the result that deglutition at once became easy. The "bowel" produced by him proved to be the mucous membrane of the gullet, detached as a whole in the form of a cylinder, twenty-two centimetres long, from two and one-half to three and one-half broad, and from one to two millimetres in thickness. The lower end of the cast showed a slight funnel-shaped dilatation, while the upper one terminated in long tongue-like shreds. Notwithstanding the patient's declaration that he was "quite well," the author sent him to a local hospital, suggesting an early gastrostomy as the only means of preventing starvation from consecutive cicatricial narrowing of the gullet. The surgeons, however, declined to operate (the reasons are not stated). Several weeks after the expulsion of the cast the introduction of an œsophageal bougie became very difficult. About six months after the accident the man died from exhaustion. No necropsy was allowed. The author believes that in his case, as in Puech's, [11 Mar., '91] the corrosive fluid gave rise to purulent inflammation of the submucous cellular tissue, undermining the whole mucous membrane and causing necrosis and detachment.

Stricture of the Œsophagus.—Howard Lilienthal, of New York, [1 Apr. 11, '94] describes an ingenious method for the differential diagnosis of stricture of the œsophagus, and relates two cases in which it had been satisfactorily employed. In one of these deglutition was, in reality, not performed as a physiological act, the law of gravitation alone causing the food to descend to the stomach. The patient could not swallow, therefore, when lying on the floor, and food would immediately flow out if, after eating, he assumed the prone position. Physical examination was negative, care being especially taken in palpation of the abdomen. The man was requested to swallow a glass of water, which he did appar-

ently with ease. He then bent forward until his head was about two feet from the floor, when most of the water ran out of his mouth. There was also some mucus and saliva. The conclusion was reached that there existed either a stricture of the gullet with dilatation above, or that there was a diverticulum. Auscultation during swallowing revealed nothing. The attempt to pass a medium-sized whalebone œsophageal bougie failed, and a much smaller instrument was arrested at the same point,—nine inches and one-fourth from the front teeth. The following day, after a half-hour's patient work, a filiform urethral guide passed into the stomach. This was followed by a larger instrument, and so on until a No. 11 French urethral catheter of woven silk was reached. This catheter, though it engaged tightly, was successfully passed. There was no bleeding. In order to make sure that the case was really one of stricture, and in order to exclude the possibility of diverticulum with a small opening into which the instrument might have passed, and to exclude as well regurgitation from the gastric cavity itself, the following method, which Lilienthal believes to be original with him, was resorted to. The patient having fasted for six hours, the No. 11 French catheter was again with difficulty introduced. Three ounces of water, very deeply colored with methyl-violet, were injected with a hand-syringe into the catheter, immediately followed by three ounces of clear water. The catheter was then withdrawn. The patient now drank a glass of water and, in a few moments, caused its regurgitation by lowering his head. The water returned absolutely unstained. He then drank a glass of slightly-stained water, and the stained water returned unchanged in color.

By gradual dilatation with woven urethral instruments passed daily the stricture widened to No. 15 French. The man's condition and ability to swallow greatly improved. Although there was no evidence of syphilis, iodide of potassium, in 20-grain (1.3 grammes) doses, thrice daily, was ordered. In less than a week the patient was obliged to return to his home in the northern part of the State. He had learned to put the instruments into his œsophagus, and he took with him a number of olive-tipped bougies of various sizes. Two months later he reported himself by mail as still doing well, and on October 22, 1892, nearly a year and a half after the last visit, he wrote that, though there was still an

obstruction, he could live as he had always lived, could stand long tramps, and could sleep upon the ground as well as ever.

Reichmann, of Elberfeld, [69 No.15,'94] wrote an article in praise of a sound invented by him. Cases of stricture were recorded by von Hacker, of Vienna [11 July,'94]; Tietze [69 No.16,17,'94]; William Pepper, of Philadelphia [9 Nov.25,'93]; Orrillard, of Paris, [7 No.4,'94]; and E. Spiering, of Kiel. [2174 '94] Abbe, of New York, [96 Jan.,'94] adds a second case to the one reported last year (see ANNUAL, for 1894, page D–100, vol. iv) of cure of an œsophageal stricture by cutting with a string.

Malignant Stricture of Œsophagus.—P. C. Smyly [11 Dec.,'93] records a fatal case in which the constriction occupied what he considers an unusual site,—immediately below and behind the cricoid. Microscopical examination showed it to be very dense fibrous scirrhus, containing cells like those of the deeper strata of the œsophagus, with great preponderance of stroma. Permewan, of Liverpool, [26 Jan.1,'94] in reviewing Smyly's article, states that cases of the kind reported by the latter are by no means so rare as one would gather from the remarks made, and relates two cases seen during the two preceding months to sustain his point. Mayo Collier, of London, [11 Feb.,'94] gives the history of a case in which malignant stricture of the œsophagus had been diagnosed and gastrotomy advised by two surgeons, the same diagnosis having been given by twelve or fifteen medical men. It was accidentally discovered that attempts to swallow were futile. The correctness of the diagnosis was doubted, and a sound was successfully passed to the stomach. The man died of pneumonia. The only disease found post-mortem was a large cancer of the liver. Collier suggests the advisability of great care before affirming a diagnosis of cancer of the œsophagus. W. Oxley, of Rotherham, [6 Nov.25,'93] observed a case of the same kind. Alfred Berrill [6 June 9,'94] published the notes of a case of malignant stricture in which intubation was used to great advantage to nourish the patient. A few days before the first tube was introduced he had had the greatest difficulty in swallowing anything. Intubation was continued for seven months, the patient being able to swallow with comfort up to the time of his death. Cases of malignant stricture of the œsophagus were reported by Sabrazès and Bazin, of Bordeaux [188 Dec.31,'93]; H. P. Loomis, of New York [59 Aug.11,'94]; J. Flintermann, of Detroit [185 Mar.,'94]; W. R. Stewart, of London [11 Apr.,'94]; and M. Jacquemet. [46 May 15,'94]

Syphilitic Stricture of the Œsophagus.—J. Hutchinson, of London, [806 Jan.,'94] refers to the sequel of a case sent him by Beaumont, of Gipsy Hill, two years ago, for suspected malignant stricture. The patient is now in good health and able to swallow easily. On referring to his notes of the case he found that with considerable difficulty, under an anæsthetic, he had got a bougie through a contraction in the lower part of the tube when the patient had consulted him. As the patient had suffered from syphilis, and on account of the absence of some of the symptoms of cancer, the use of bougies and the administration of iodide of potassium were decided upon. It was under these measures that the recovery took place, and for a year past no bougie has been employed.

Tuberculosis of the Œsophagus.—Bauer, of Nuremberg, [136 Oct.15,'94] in a case of stricture occurring in a phthisical patient, doubted that tuberculosis could be the cause of the œsophageal trouble, but autopsy confirmed the diagnosis. Macroscopically the growth looked like a cancer, but microscopically it showed itself to be tuberculous, numerous tubercles and bacilli being found. The author thought that the involvement of the œsophagus was due to the contact of contaminated saliva swallowed.

Varices of the Œsophagus.—Lubimoff, of Kasan, [121 Sept.,'94] relates the case of his colleague, Studenski, who, on the morning of his last illness, appeared to be in good health. In the evening he was attacked by vomiting of blood, continuing during the night. Death took place upon the third day. An autopsy was made by Lubimoff, who discovered the existence of an atrophic cirrhosis of the liver and thickened and dilated veins of the mucous membrane of the œsophagus toward its lower third. The fatal result was caused by hæmorrhage from the varicose veins of the œsophagus. Cirrhosis of the liver was the sequence of the accumulation and stagnation of blood in these vessels. The fact is of interest on account of the rarity of similar cases, and also the latent course of the cirrhosis. A case is also reported by Paul Friedrich, of Leipzig. [13 Apr.,'94]

Rupture of the Œsophagus.—L. Wolff and A. J. Patek, of Philadelphia, [9 May 12,'94] report two cases. In the first no cause could be found, the patient being a strong and young man, barring, perhaps, a copious meal. At the post-mortem a longitudinal rent about one inch in length was discovered on the left side of the

cardiac extremity of the œsophagus and opening into the pleura. The mucous membrane of the latter was perfectly normal, the edges of the rent being plainly defined. There was, however, a very small, round area opposite the line of rupture which seemed devoid of epithelium, but the author considers this as due to ante- or post- mortem maceration. The second case occurred in connection with an aneurism of the descending aorta. H. P. Loomis, of New York, $\frac{59}{\text{Aug. 18, '94}}$ observed a case of perforation of the œsophagus in a sword-swallower. Besides the opening, a clean-cut wound about two centimetres in length, and extending down to the œsophageal opening in the diaphragm, the cardiac end of the stomach presented radiating lines around the œsophageal opening, which seemed to have resulted from injury. All three inner coats were gone, the peritoneum being laid bare.

INTUBATION OF THE LARYNX.

By JOSEPH O'DWYER, M.D.,

NEW YORK.

Ranke, of Munich, [34 No. 44, '96] as the result of a collective investigation on intubation in Germany, reports an aggregate of 1445 cases intubated for the relief of croup, with 553 recoveries, or 38 per cent. Of this number Gaughofner, of Prague, contributed 498 cases, with 213 recoveries,—42.7 per cent.; Ranke, of Munich, 368 cases, with 128 recoveries,—34.7 per cent.; von Muralt, of Zurich, 106 cases and 38 recoveries,—35.8 per cent.; Jaburowski, of Cracow, 165 cases and 73 recoveries,—44.2 per cent.; and Unterholzner, of Vienna, 164 cases, with 55 recoveries,—35.5 per cent. One hundred and twenty-one of the cases were secondary to measles, scarlet fever, pneumonia, etc. Secondary tracheotomy was resorted to in 250 of the cases, with only 20 recoveries, or about 7 per cent. As to the value of these statistics, Ranke speaks as follows: "This number proves for itself that intubation, which at first and until lately was severely fought on all sides, has, in the course of a few years, gained more and more friends on this side of the Atlantic also; and it proves that the dangers which were formerly charged against this operation must have been greatly exaggerated."

And again, in giving the true explanation of the insignificant results obtained by secondary tracheotomy after intubation had failed, as follows: "The extraordinarily-small percentage of recoveries from these secondary tracheotomies is explained in this way: that in the majority of these cases secondary tracheotomy is resorted to after the diphtheritic process has extended to the bronchi, and that under these circumstances it could not accomplish any more than intubation."

Bokai, of Budapest, [366 June 5, '94] in an interesting and instructive paper on intubation in the treatment of croup, quotes numerous authorities on this subject and gives his own individual experience in 500 cases treated by this method. In this large number of cases there was not a single death from pushing down membrane before the tube. When this accident, which was uncommon, did

occur, the obstructing membrane was usually expelled after the withdrawal of the tube. Obstruction of the tube from loose membrane below was of rather frequent occurrence, but never resulted in death, owing to the violent paroxysm of coughing that occurs under these circumstances, by which tube and membrane were expelled. When this failed, the nurse removed the tube by the string, which is always left attached, and thus saved some lives that, without the presence of the string, must have been lost. In this country the string is rendered useless in the majority of the cases, because cutting it by the teeth cannot be prevented. In babies who have no back teeth it is always available, and in older children who are well under control. Various means have been tried to overcome this difficulty, which they do not appear to encounter in Europe, but without success. Passing the braided silk through a piece of fine rubber tubing, which stands a good deal of chewing, has done better than anything else in my hands.

Carstens, of Leipzig, [366 Aug. 6, '94] reports 100 cases of croup treated at the Leipziger Kinderkrankenhause by intubation, with 30 recoveries. Secondary tracheotomy was performed in 7 cases, with 1 recovery. In 3 cases it was found impossible to intubate, and, as nothing was found at the autopsy in one of these cases to explain the impediment to the passage of the tube, it was attributed to spasm of the glottis. In another of the cases not even a very small sound could be inserted, and the difficulty here was supposed to be due to the deposit of very thick membrane. As fully explained and illustrated in the ANNUAL for 1892, there are only two impediments to the introduction of a tube of proper size in any form of acute stenosis of the larynx, —viz., entering one of the ventricles, or a subglottic stenosis. Neither spasm of the glottis, nor pseudomembrane, nor œdema, when situated in or above the chink, ever offers any serious obstruction to the passage of a tube.

Schweizer [366 No. 2, '93] reports 31 recoveries out of 68 children intubated for laryngeal diphtheria, 6 of the cases operated on being under one year. Pabot [211 Feb. 25, '94] gives the results of the diphtheritic cases treated in the Charity Hospital of Lyons in 1893: 93 cases of croup were treated, of which 34 were intubated, with 16 recoveries; 45 cases were tracheotomized, with 19 recoveries; and both operations were performed in 14 cases, with 3 recoveries.

The author predicts that intubation will completely supplant tracheotomy in the treatment of croup.

Wockerle, of Vienna, [366 v.28,No.2,'94] gives his experience in the treatment of diphtheria in the Leopoldstädter Children's Hospital in Vienna. From April, 1891, to July, 1893, 718 cases of diphtheria were treated. Of this number 115 were intubated, with recoveries of 48, or 41.7 per cent.; intubated and tracheotomized, 48 cases, with 11 recoveries,—22.9 per cent.; and tracheotomized alone, 92 cases, with 19 recoveries,—20.6 per cent. Of the total number of 718 cases, 61.1 per cent. were cured.

Whitney, of Boston, [99 Oct.5,'93] in an interesting paper on the advantages of intubation in private practice, gives the results of his own experience in 78 children intubated, of whom 26, or 33 per cent., recovered. The difficulty of removing the tube, as compared with its introduction, is justly emphasized. Whitney prefers an extractor devised by Nichols, of the Boston City Hospital, because the original extractor did not hold the tube firmly enough to prevent it from slipping off when only partially removed. This defect certainly did exist in the first instruments manufactured, but was very soon remedied. No instrument can be devised to make extubation easy, because, whatever form of extractor is used, it must be passed into the small opening in the tube; and herein lies the difficulty, which can be overcome only by a large amount of practice.

Rosenthal, of Philadelphia, [121 Sept.,'94] reports 100 intubations for croup, with 38 recoveries. Rosenthal states that, before he practiced intubation, a recovery from laryngeal diphtheria was rare, and that fully 95 per cent. of his cases died. Since adopting intubation the mortality has been reduced to 62 per cent., and he is therefore an enthusiastic advocate of the new operation.

Waxham, of Denver, [155 Aug.,'94] reports 10 additional cases of intubation in which calomel fumigations were resorted to, which, added to his 466 cases formerly reported, make a total of 476 cases, with 165 recoveries, or 34.6 per cent.

Ground, of West Superior, Wis., [105 Feb.15,'94] is the author of an article on the comparative merits of intubation and tracheotomy in the treatment of croup which contains many instructive features. Ground's individual experience amounts to only 36 cases, out of which 15, or 41 per cent., recovered. One case, that of a

child 20 months old, is of particular interest. A tube was inserted without difficulty and with complete relief, which was expelled at the end of two hours. Three hours later, the dyspnœa having again become urgent, the same tube was tried, but could not be introduced. After repeated attempts the child died, when still further trials were made in order, if possible, to determine the cause of the difficulty, and, notwithstanding the employment of great force, the tube could not be inserted. No autopsy could be obtained to demonstrate the cause of the difficulty, and the operator attributed his failure to intubate—even after death, when ample time could be taken—to a subglottic stenosis which developed after the expulsion of the tube.

This theory is disproved by two facts: (1) the same tube was passed easily five hours before the second attempt was made, and (2) the tube was coughed out, which could not have occurred had any considerable amount of subglottic stenosis been present, owing to its being held so firmly. The fibrinous infiltration of the tissues of the unyielding cricoid division of the larynx, which alone offers any serious impediment to the passage of a tube of proper size, does not take place in a few hours. Notwithstanding that a bulbous-ended tube was used, the failure to intubate was undoubtedly due to entering one of the ventricles, and not a subglottic stenosis. Having the distal end of the tube blunt and rounded instead of the flat oval was designed to minimize the danger of making a false passage,—which usually has its starting-point in one of the ventricles,—a not uncommon accident in the hands of beginners. So far as entering a ventricle is concerned, this device is rendered useless if the obturator extend too far beyond the distal extremity of the tube.

Millard, of St. Paul, [105 Jan. 1, '94] in a presidential address delivered before the Minnesota Academy of Medicine, reviews the early history of intubation and compares it with tracheotomy, which he regards as a most formidable operation, even in the most skillful hands. Millard's individual experience with intubation in the treatment of croup amounts to 63 cases, with 27 recoveries,—42.8 per cent. He attributes his large percentage of recoveries principally to the fact that a mild type of diphtheria had prevailed in St. Paul for several years.

Stanton, of New York, [59 Nov. 25, '93] reports 70 intubations for croup,

with 24 recoveries,—a percentage of 34.3. Of the few accidents encountered, one, which occurred in the case of an infant 21 months old, is of particular interest. The child was doing well until extubation was attempted, on the sixth day. After several unsuccessful trials to remove the tube it was pushed below the vocal cords, the parts having been first dilated by using the old form of extractor, which had no regulating attachment to prevent the nibs from opening to their full extent. The cricoid cartilage not having been injured, the tube could not pass beyond this point. It was allowed to remain in this position for over twenty-four hours, when the vocal cords gradually closed over it, with a return of all the symptoms of severe croup without the characteristic tubal cough.

I was now called to see the case, and, from the symptoms present, added to the fact that the child swallowed perfectly ever since the attempt at removal was made, was in doubt as to whether the tube was in the larynx or not. However, I assumed that it was and passed the extractor carefully between the vocal cords, felt the tube, and removed it without difficulty. The same question, as to whether a tube has been pushed below the cords or lifted out and dropped into the œsophagus during attempts at extubation, no doubt has often arisen and will again. It is important in this connection to remember two things: 1. That when the vocal cords close over a tube in the position referred to, so as to give rise to severe dyspnœa, there is no symptom by which its presence can be detected. It must be felt by some metallic substance,—extractor, sound, etc. 2. That the head of a tube of proper size for age cannot be forced through the subglottic division of the larynx—that is, into the trachea—until the integrity of the cricoid cartilage has been first destroyed. It is also well to bear in mind that the tips of the best extractors are too large to enter in the short diameter of the two smaller tubes, and that the latter may turn, on being pushed down, so as to occupy a transverse position in the larynx.

Day, of Providence, R. I., [99] Apr. 12, '94 reports 31 cases intubated for croup, of which 8 recovered. Day concludes, from his own experience, that the difficulty of feeding after intubation has been overestimated by most writers. In 25 of the cases this point was noted, with the following result: no dysphagia in 10 cases; very

little in 15; much at first, but none later, in 1, and impossible to swallow in 1.

Johnson, of Paterson, $^{61}_{\text{Nov.26,'98}}$ reports 19 cases intubated, with 6 recoveries. In one of the cases tracheotomy was performed because of uncertainty as to the position of an intubation tube previously inserted. A 2-year-old size had been used in a boy 3 years and 4 months old, which gave relief at first, but the dyspnœa returned in a few hours, and, when an attempt to extubate was made, the tube could not be felt in the larynx. Tracheotomy was then resorted to under the belief that the tube, on account of its small size, had slipped below the vocal cords, but it was found in the stools several days afterward. The patient recovered after wearing the tracheal cannula nineteen days.

Patt, of Halle, $^{11}_{\text{June,'98}}$ reports a child, 1½ years old, intubated for spasm of the glottis, with recovery, the tube having been inserted after respiration and cardiac movements had ceased.

Bonain, of Brest, $^{37}_{\text{July 15,'94}}$ has practiced intubation in 23 cases of croup, with 8 recoveries, or 34 per cent. Aasen, of Stockholm, $^{996}_{\text{May 10,'94}}$ reports 18 intubations in children, with 6 recoveries.

INTUBATION IN CHRONIC STENOSIS OF THE LARYNX.

Baumgarten $^{158}_{\text{v.15,No.5,'95}}$ reports 2 cases of chronic stenosis of the larynx treated by intubation: 1. Boy, aged 12 years, had hoarseness for two months, with abductor paresis and chronic subglottic hypertrophy. The case was first treated with Schroetter's tubes for three weeks, when suddenly fever, cough, and severe dyspnœa developed. Intubation was then practiced by Bokai, with complete relief, the tube being left in position sixty-six hours. Intermittent intubation was then continued for eight months, and resulted in permanent cure. 2. Girl, aged 14 years, with history of cough and hoarseness for five years. A stricture of syphilitic origin was found in the upper part of the trachea, which gave rise to severe dyspnœa. At first the patient was intubated every day, later less frequently, with entire disappearance of the dyspnœa.

Chiari $^{57}_{\text{July 8,'94}}$ reports a case of chronic subglottic stenosis, in a woman, in which intubation was practiced for some time and the patient was taught to introduce the tube herself. She then left the hospital; the final result is, therefore, not known.

Cheatham, of Louisville, [1152 Mar.,'94] refers to two adult patients who were wearing intubation tubes at the time the report was made. One was a woman, 45 years old, who was intubated for the relief of dyspnœa due to abductor paralysis thirteen months previously. The tube is removed once in four or five weeks, cleansed, and replaced. He hopes soon to be able to dispense permanently with the tube, as when it is out there is considerable space between the vocal cords. The second case was a man suffering from œdema of the glottis associated with syphilitic perichondritis. Tracheotomy was first resorted to, as it was believed that the swollen tissues at the entrance of the larynx would overlap the head of the intubation tube. Two days later intubation was performed with complete relief, and at the time the report was made the tube had been in the larynx eight weeks without change. It is not stated whether the tube was one of metal or vulcanite. In previous numbers of the ANNUAL I have called attention to the danger of leaving a metallic tube continuously in the larynx for so long a time, on account of the irritation resulting from the calcareous deposits that always take place, to a greater or less extent, and for other reasons.

The supposition that, in extreme cases of œdema of the glottis, from whatever cause, intubation will fail to afford relief, on account of the swollen tissues overlapping the head of the tube, rarely holds true in practice. Occasionally a larger tube than that suitable for the age will have to be used. In an adult female suffering from a severe type of laryngeal diphtheria I inserted a tube of proper size, but the dyspnœa continued as before. Lifting the tube a little higher in the larynx, by pulling on the string, afforded complete relief; but, as it could not be retained in this position, a larger-headed tube was substituted, with permanent relief. Had no other tube been at hand, the head of the one in use could have been enlarged by slipping a piece of large-calibre rubber tubing over it from below and allowing the latter to project slightly above the head of the tube.

Schmiegelow, of Copenhagen, [11 May,'94] in an abstract of a paper on intubation in the treatment of chronic stenosis, read before the Eleventh International Medical Congress, proves that his deductions are derived from practical experience with this operation. Especially is this the case when he speaks of the difficulty of in-

tubating close strictures of the larynx, as follows: "If we find the presence of stricture so great that we cannot introduce tubes large enough to allow the patient to respire, the treatment becomes more complicated: (*a*) We may commence by dilating the stenosis by endolaryngeal operations until large-enough tubes can be introduced. (*b*) We may also commence with the introduction of Schroetter's bougies and continue until the stenosis is so far dilated that the tubes can be introduced. (*c*) We may commence by the immediate performance of laryngo-fissure, in order to remove the obstruction causing the stenosis, and then proceed to intubation. Complete obliteration of the larynx ought to be treated by laryngo-fissure, with excision of the diaphragm; then intubation in order to prevent its reproduction." Massei, of Naples, in discussing Schmiegelow's paper, referred to the fact that in three or four years he had performed as many intubations in adults as he had done tracheotomies in all the rest of his career.

Thorner, of Cincinnati, $\frac{1018}{July,\,98}$ reports a rather sudden death following the removal of an intubation tube that was inserted for the relief of dyspnœa due to chronic stenosis. The tube was removed at the doctor's office, fifteen hours after insertion, and the patient started to walk home, but was attacked with sudden dyspnœa on the street and died before assistance could reach him.

RETAINED INTUBATION TUBES.

In the ANNUAL for 1892 I called attention to the fact that intubation tubes are sometimes retained for many months, and cited the only cases, two in number, that I had observed up to that time. In one of these cases the tube was dispensed with, at the end of ten months, by means of a tube specially constructed for the purpose, an illustration of which is also given in the ANNUAL referred to. The other case was sent to hospital by the attending physician after the tube had been worn for fifteen months. Tracheotomy was performed, a cannula inserted, and death resulted in three days from broncho-pneumonia, the child being in perfect health up to the time of the operation.

In both of these cases the cause of the retention was the presence of exuberant granulations which dropped in the chink of the glottis as soon as the tube was removed.

During the past year I have seen at least half a dozen cases

in which tubes were retained from a few months to over a year, and in no one of them was the retention due to the cause just described. They were all operated on by amateurs, which is equivalent to saying that considerable injury was done to the larynx every time that a tube was inserted or removed, especially the latter. That this was one of the principal causes of the persisting stenosis was demonstrated by the fact that several of these cases were promptly cured after two or three careful removals and re-insertions of the tubes at intervals of from five to seven days.

It is also equally true that an inflammatory thickening of all the tissues of the glottis does sometimes continue for a considerable period of time independent of traumatism. Such appeared to be the cause in one of my own cases, a child less than 2 years old, in which the stenosis persisted for eleven weeks, the tube having been removed and a clean one re-inserted once a week. Out of 454 cases thus far intubated this was the only one in which a tube was retained for more than twenty-nine days.

The impossibility of making a satisfactory laryngoscopical examination in young children often leaves the diagnosis as to the real cause of the obstruction in these cases in doubt. In all probability it is sometimes due to abductor paralysis.

The only treatment necessary to effect a cure in the vast majority of these cases is that indicated above,—viz., the careful removal of the tube at least once a week and leaving it out as long as possible without endangering the patient's life. When it becomes necessary to re-intubate, a fresh tube should, if possible, be substituted, and, above all, one of proper construction.

There is one other cause of retained intubation tubes, or, rather, loss of power to retain them, of which I have seen but a single case, and it teaches an important lesson in regard to the danger of using a tube much larger than is suitable for the age. It was a child, about 2 years old, that was intubated for croup at the New York Foundling Hospital. After a few days the tube was coughed out, when the 3 to 4 size was substituted; but this was also repeatedly expelled, and the 5 to 7 was introduced. A special tube with extra-large retaining-swell was now ordered, but before it could be procured the 8 to 10 size had to be used, as the 5 to 7 would be retained for only a few minutes at a time. The special tube was also rejected several times, and the child finally

died before the house-physician had time to reach it and re-intubate. The autopsy showed complete destruction of the cricoid cartilage, only a few necrotic fragments of which were still in place. The considerable space between the thyroid cartilage and the first ring of the trachea having, therefore, lost its support, collapsed as soon as the tube was displaced, thus preventing the ingress of any air whatever.

No tube can be retained in the larynx under these circumstances, because, the arytenoids having lost their base of attachment, the vocal cords have no power to contract, and it is owing to this contraction mainly that the intubation tubes are retained. Tracheotomy is the only treatment available in this class of cases, which is, fortunately, very rare.

DISEASES OF THE THYROID GLAND.

By J. PAYSON CLARK, M.D.,
BOSTON.

ANATOMY AND PHYSIOLOGY.

Jaboulay and E. Villard [211 Nov. 12, '93] state that the inferior thyroid artery divides into three branches, one following the lower border of the gland toward the median line, a second ascending along the posterior border, and a third, less important, lying on the posterior surface of the gland. The recurrent nerve presents variable relations with these branches. As a result of their researches the writers recognize three types: 1. The recurrent laryngeal nerve passes in front of all the arterial branches on the right and behind on the left. 2. The position of the nerve on the left is the same, while on the right it passes between the first and second arterial branches, in front of the inferior, or largest. This is the most common type. 3. The situation of the nerve is variable, but is always more in front of the arterial branches on the right than on the left. Rare exceptions to this general plan are noted.

Benissowitsch [100 May 29, '94] finds that thyroidectomized dogs succumb on a meat diet, while the number and intensity of the symptoms are diminished on a milk diet. If on the latter the animal present no morbid phenomena, then a consecutive meat diet exercises no injurious influence. From the analogy of the phenomena observed after removal of the thyroid and those caused by the introduction of carbonic acid into dogs which have recovered after thyroidectomy, the writer believes that the thyroid has for one of its functions the decomposition of carbonic acid into urea. Godart [868 Jan. 27, '94] performed the following experiments on three animals with similar results: After removing one thyroid lobe completely he gradually transplanted the other in front of the anterior aponeurosis of the superficial muscles of the neck. This was done in two operations. In the first, one end of the lobe to be transplanted was freed from its surroundings and introduced into the place prepared for it. Some time after, the rest of the lobe was freed from its normal site and left attached in its new position. After some systemic disturb-

ance the animal recovered. On removing the transplanted gland later, the animal died. The writer concludes that the thyroid can have no regulating action on the cerebral circulation, as this operation totally modified its relations to arteries and veins; that, as transplanting irritates the same nerves as does extirpation, the symptoms consecutive to thyroidectomy cannot be due to nerve-lesions. The preservation of the cellular function of the gland appears to be all that is necessary to prevent cachexia or myxœdema. E. Gley [410 Oct.,'98] has removed the thyroid gland from ten dogs, leaving the glandules intact,—a difficult experiment on account of the position of the glandules. Eight of the animals remained perfectly well after the operation, but died when the glandules were also removed. In one case the glandules did not hypertrophy after thyroidectomy and the animal died. Another case was fatal because only one glandule was preserved. In two cases severe symptoms, which gradually diminished and disappeared, came on after the removal of the thyroid. They were probably due to the primary insufficiency of the glandules to fulfill the thyroid function. Extirpation of the glandules alone seems, as in rabbits, to be without effect.

Hurthle's [11 July,'94] experiments show that there are two forms of secretion in the thyroid: first, secretion of the follicular epithelium, colloid formation; second, that formed by destruction of the cells. Faradic irritation of the nutritive nerves of the gland does not influence the secretion. If a large portion of the gland is removed, the remainder shows signs of increased activity. Colloid production is also increased by ligature of the ductus choledochus. The contents of the follicles are absorbed either by rupture of the follicles or through the intercellular spaces. Vassale and Brazza [278 July,'94] have been able to show that the amount of colloid substance in the thyroid lymphatics varies, probably in proportion to the functional activity of the gland and the age of the animal, the gland being more active in youth. The greater functional activity of the thyroid in early life is the most probable explanation of the fact that the ablation of the thyroid in young animals is more injurious than in older ones. M. Zielinska [13 June,'94] found a variable amount of colloid in the thyroids of six newborn puppies and of fourteen adult dogs. The lymph-vessels, however, invariably contained colloid. The most careful examination could discover no connec-

tion of the follicles with the lymph-vessels. Colloid was found in the lymph-vessels in the neighborhood of the thyroid, and in the large lymph-spaces under its capsule. In seven out of twenty thyroids from infants, colloid was found in the lymph-vessels.

Poncet and Jaboulay[14, Feb. 7, '94] state that, immediately after the exposure of the thyroid in exothyropexy, a moisture appears over the surface (except over the great vessels), which remains abundant for several days. With the gland in its normal position this secretion diffuses itself into the lymph-spaces surrounding the gland, and is taken up by the circulation.

GOITRE.

Histology and Histogenesis.—T. Hitzig[13, July, '94] gives the following results of extended researches: 1. Goitre formation apparently begins by a growth of processes of the normal glandular epithelium. 2. The first clearly-visible beginning of the nodular goitre consists of single processes of differentiated epithelium in the secondary lobules. 3. These processes gradually replace, metaplastically, the normal tissue of a secondary or even a primary lobule. 4. The lobules thus changed form, as they increase in volume and displace the surrounding tissue, the smallest true goitrous nodules. 5. Neighboring lobules changed in this way form multilocular goitrous nodules, either blending by a growth through the intervening septa or flattening where they come in contact. Finally, the outer compressed lobules surround the central, more vigorously growing ones like a shell. 6. The metaplastic growth ends when the boundary of the primarily-affected lobule is reached, growth then taking place by displacement of the surrounding tissue. 7. Diffuse goitre consists of a uniform proliferation in all the lobules. 8. Nodular goitre arises through a variation in the vitality of neighboring parts. 9. There exist a great variety of intermediate forms.

Cases.—G. Lion and R. Bensaude[7, No. 11, '94] observed an abscess of the thyroid following pneumonia, the pus containing pneumococci. G. Durante[7, No. 12, '94] reports a similar case. Letulle and Meslay[7, No. 10, '94] describe a cancer of the thyroid followed by cancerous phlebitis of the right brachiocephalic vein. Martin-Durr[7, No. 7, '94] reports an epithelioma of the thyroid with metastases in both humeri and in the pleuræ. Middeldorpf[41, June 23, '94] relates a case of goitre with metas-

tases in various bones. Von Eiselsberg[41, June 22, '94] reports a total thyroidectomy followed by symptoms of cachexia strumipriva, which subsided on the appearance of a hard tumor in the manubrium sterni. The removal of this tumor, a carcinoma, was followed by symptoms of cachexia. This tumor, evidently an accessory thyroid or a metastasis, was apparently vicarious for the thyroid. Simon[31, June 22, '94] describes a case in which death was caused by compression of the trachea and, perhaps, the pneumogastric nerve by a hæmorrhage from the thyroid, followed by considerable effusion of blood into the surrounding cellular tissue. Guhl[214, Aug. 1, '94] reports a case of sudden death from suffocation, resulting from the pressure of a hæmorrhage into an old cystic goitre.

Symptoms.—The majority of symptoms of *endothoracic* goitre are common to other similarly-situated tumors, such as aneurism of one of the large thoracic vessels or tumors of the mediastinal lymph-glands. H. Braun[41, June 14, '94] states that the most characteristic symptom consists of sudden attacks of dyspnœa brought on by certain movements of the head. Of great diagnostic importance is the exacerbation of symptoms at times when the thyroid usually enlarges, as at puberty or during pregnancy. The proof of parenchymatous or connective-tissue attachment of the tumor to the thyroid is important, as endothoracic goitres have, without exception, some such connection with the thyroid.

Treatment.—Garré[22, July 11, '94] has published a series of 140 cases of goitre treated by injections of iodoform,—a method of treatment now apparently very little used. He recommends it as highly practical, almost painless, and free from danger.

Poncet and Jaboulay[14, Feb. 7, '94] have now performed exothyropexy in 14 cases, mostly young people, all of whom recovered; 5 were large parenchymatous goitres, which atrophied more or less rapidly, with relief of all functional disturbances, and 9 were cystic and were absorbed more or less rapidly, according to the nature of the cyst. Old cysts with thick walls may be enucleated secondarily. Exophthalmic symptoms, present in 4 cases, disappeared. Additional procedures to hasten the disappearance of the tumor were tried, as cauterization, excision with the thermocautery, curetting, etc. They were found of no value, and often dangerous. The thyroid was found to be insensible, the arteries alone appearing to cause a painful reaction under cauterization.

Large veins atrophy rapidly after the operation; so that a secondary operation is easy, if necessary. An objection to the operation is the length of time required for the wound to cicatrize and the exposure to infection during this time.

The atrophy of the gland may be due to exposure of the secreting surface, to thrombosis of the veins, or to reflex action from incision of the skin. It is a curative operation and an emergency operation in deep or constricting goitres. It may be a preliminary to excision or enucleation. It applies to all varieties of goitre. Goris[868 July 14, '94] reports an exothyropexy in a young girl, followed, on the fourth day, by a rise of temperature and dullness at the base of both lungs. The pulse rose to 160. Thyroidectomy was performed on account of dyspnœa, and the patient died.

EXOPHTHALMIC GOITRE.

Etiology and Pathology.—A. Maude[47 Summer, '94] concludes a valuable digest of recent literature on this subject as follows: "There is a gradual growth of the opinion that this symptom-complex is due to the production (or non-elimination), in the thyroid itself, of some toxin, which acts on the whole nervous system. This position is adopted in Germany by Möbius, Wette, and Müller; in France, by Joffroy and Renaut; in England, by Bramwell, Murray, and Greenfield. The question of the exact rôle played by the thyroid change is difficult. All cases show two common factors,—cell-proliferation and diminution of colloid. Even so, we are in the dark as to whether this morbid change is primary or secondary to some vasomotor disturbance elsewhere, and also as to whether the alteration in thyroid secretion will produce the same effect in a healthy nervous system; probably some nervous systems are more susceptible than others to the toxic influence, just as they are to alcohol and lead."

P. Marie[40 Apr., '94] takes the view that the *primum movens* of Basedow's disease is probably to be found in an affection or, at least, a disturbance of the nervous system from which results exaggerated activity of the thyroid, causing "*hyperthyroidation*" of the organism, as a consequence of which supervene all the symptoms common to this disease and to thyroid overmedication. He asserts that in no case of myxœdema in which thyroid has been administered has exophthalmos, or von Graefe's symptom, developed, and

declares that the theory of the thyroid origin of exophthalmic goitre does not accord with our present knowledge. Rehn[11, July, '94] believes in the theory of excessive absorption of thyroid secretion. E. A. R. Newman[6, Aug. 11, '94] suggests an origin in a functional disturbance of the brain, manifesting itself through the lower centres in the medulla. Cases where there is a history of fright, heredity, or mental instability in other members of the family support this view. J. J. Putnam[47, Summer, '94] says that the argument drawn from successful results of operation in favor of an origin from excessive or perverted thyroid secretion is not as convincing as it at first might seem, because it often happens that morbid processes are kept up by influences which were not their real cause, and cease when these influences are withdrawn. Nor has the idea that the secretion is altered been substantiated. Many of the symptoms of Graves's disease are met with in simple nervous excitement. Cases in which this disease gives place rapidly to myxœdema make it appear as if the changes in the gland were of a degenerative nature. Even in cases not originating in fright, the assumption of an overstrain of medullary and other centres intimately related to the emotional centres of the brain may throw light on the origin of the symptoms. Joffroy and Achard[457, Nov., '93; 996, Jan. 10, '94] give the result of six autopsies. The different thyroids presented a great diversity of appearance,—as cystic dilatation of the vesicles; disappearance of the colloid material in the vesicles or its replacement by small round cells; formation of new adenomatous tissue; œdematous swelling and infiltration of the fibrous tissue by leucocytes. There is no clear line of distinction between the condition of the thyroid in exophthalmic goitre and in simple bronchocele. Joffroy inclines to the belief that cases in which myxœdema follow are not accidental, but that in such cases (now not rare) an early catarrhal or proliferative stage is gradually succeeded by a progressive fibroid degeneration of the gland. P. Mannheim[13, Feb. 15, '94] believes that only an organic lesion of the central nervous system can explain all symptoms. Vandervelde and le Boeuf,[868, Mar. 3, '94] from an histological study of the thyroid in four cases, reject the theory of increased thyroid activity. The goitres in these cases resembled anatomically ordinary goitres. A careful histological examination of the pons and medulla in three cases gave no definite results.

W. S. Greenfield [2, Dec. 9, '93] considers Graves's disease provisionally as a disease of the thyroid rather than of the nervous system, because of (1) the peculiar proliferation of the thyroid tissue, suggesting increase of secretion; (2) relief afforded by the removal of even part of the gland; (3) the slight wide-spread changes in the nervous system similar to those observed in toxic diseases, and suggesting a toxic origin; (4) the contrast of many of the leading conditions with myxœdema; (5) the correspondence, in important respects, of the phenomena of Graves's disease with those produced by the artificial introduction of thyroid secretion into the organism. Microscopical examination shows the enlargement to be due to enormous hyperplasia of the secreting structure, the epithelium being changed from a cubical to a columnar type, and there being produced a great number of tubules resembling those of a secreting gland. There is a diminution rather than an increase of vascularity. The apparent increase seems due to a relaxed condition of the arteries and engorgement of the veins. Councilman [99, Oct. 26, '93] found, in the specimen from Putnam's case, arborescent, follicular-looking tufts covered by cubical epithelium quite different from the characteristic epithelium of the normal gland. H. Reinhold [814, Aug. 1, '94] and R. L. McAdam [285, Dec. 15, '93] each report a case of exophthalmic goitre following an acute infectious inflammation of the thyroid in a case of *la grippe*. Angiolella [917, Dec. 1, '93; 94, Feb., '94] says that the paraplegia at times associated with Graves's disease is due to a lumbar myelitis, and trembling to a mild inflammatory process extending to the cervical and dorsal cord. These are the result of a toxic substance in the blood from disturbance of the thyroid function. The influence of a neuropathic constitution is not excluded by this assumption.

Symptoms.—Among the psychoses observed in this affection, A. Maude [2, Oct. 21, '93] mentions an oversensitive notion of duty and incoherence of ideas. He favors the hypothesis of a general nerve-poisoning, affecting principally the medulla, by some toxin, perhaps formed in the alimentary canal, remaining in the circulation on account of excessive disturbance of the thyroid. The tremor of exophthalmic goitre exactly resembles that of cachexia thyreopriva. There is often paraplegia of two types,—simple chronic muscular feebleness, and a paraplegia coming on suddenly and resembling the so-called hysterical or functional variety. He supposes [47, Summer, '94] that peripheral neuritis is common because of the

frequent occurrence of "cramp," often assuming the form of tetany; the fact that ordinary sensibility is nearly always increased; symmetrical paresis of the legs is a rule; the patellar reflexes are nearly always lessened or abolished; the varying degree of numbness, tingling, and pain in peripheral nerves; and because of the frequent occurrence of localized œdemas. Henri Brunet [13, May 15, '94] endeavors to prove that the mental disturbances at times observed are not symptoms of exophthalmic goitre, but an expression of mental degeneration, generally hereditary, their immediate cause being the poisoning of the organism by some abnormal condition of the thyroid. Gerhardt [2, Apr. 21, '94] reports the presence of splenic pulsation in several cases.

Treatment.—A. D. Rockwell [59, Sept. 30, '93] reports 45 cases, 27 of which were benefited and 14 fully or approximately cured. Electricity is his chief remedy, both galvanism and faradization. He has also found digitalis useful. J. M. Taylor [9, Dec. 16, '93] says that early recognition of the malady is important. He recommends absolute rest and a tranquilizing diet (milk); for the skin, salt sponge-baths, aromatic vinegar, massage, and wool or silk under-garments. J. J. Putnam [47, Summer, '94] mentions a case in which he gave thyroid extract without increasing the palpitation or nervous symptoms and with relief of some of them. C. S. Jeaffreson [6, Nov. 18, '93] and D. Owen [2, Dec. 2, '93] each had a case improved under similar treatment. H. Power [59, Aug. 11, '94] treated a case by thyroid extract, with improvement at first, followed later by deterioration. The thyroid extract was reduced, then stopped, but the patient died three weeks later. There was great proliferation of the thyroid epithelium.

Brissaud [31, Feb. 24, '94] reports a death following exothyropexy for exophthalmic goitre. No cause could be discovered. A. Poncet [14, Feb. 7, '94] finds that the moisture on the surface of the exposed gland is especially abundant in exothyropexies for exophthalmic goitre. In one case the symptoms returned when the gland was covered by the skin and disappeared when it was again exposed. J. J. Putnam [47, Summer, '94] has collected 50 cases of thyroidectomy with only 3 or 4 deaths, and greater or less improvement and frequently cure in the other cases. He reports [99, Oct. 26, '93] a case showing decided improvement. As there is a great risk of considerable general prostration and of laryngeal paresis, the operation should be regarded as a dangerous one. R. S. Newton [11, July, '94] describes a suc-

cessful case, and A. Schnitzler $_{\text{July,'94}}^{11}$ one in which death occurred half an hour after thyroidectomy. A persistent thymus was found, with hypertrophy of the lymphoid glands and follicles of the tonsils, tongue, and intestines. J. A. Booth $_{\text{Aug.,'94}}^{242}$ reports two cases much improved by partial thyroidectomy. Improvement may be due to a diminution in the functional activity of the thyroid, to relief of irritation of the sympathetic, or to removal of pressure.

Stockmann $_{\text{Feb.8,'94}}^{69}$ reports a case treated by ligature of the thyroid arteries in two operations, followed by improvement. The left lobe enlarged later, and was removed. The patient has steadily improved. Mikulicz $_{\text{Apr.28,'94}}^{59}$ holds that extirpation of the thyroid is indicated in all cases of this affection in which even the slightest signs of tracheal stenosis are present.

Krönlein $_{\text{Aug.1,'94}}^{214}$ reports eight cases treated by partial thyroidectomy, some of whom are cured and the rest much improved. The symptoms benefited were tachycardia, tremor, mental irritability, and sleeplessness. Exophthalmos (von Graefe's and Stellwag's symptoms) shows a less constant improvement.

MYXŒDEMA AND CACHEXIA THYREOPRIVA.

Pathology.—K. Gron $_{\text{Sept.1,'94}}^{2}$ reports a case of myxœdema in which an almost complete atrophy of the thyroid was associated with an hypertrophied pituitary body, completely filling the sella turcica. A. F. S. Kent $_{\text{July 28,'94}}^{2}$ bases the following results on experiments on thirty cats and a smaller number of other animals: In the male, the symptoms following thyroidectomy are more severe than in the female. Castration appears to exert some protective influence. Administration of thyroid extract before operation exerts no protective influence, while after operation the favorable influence of its administration is marked, even when the symptoms are very severe. Specific organisms (a large bacillus and a large diplococcus) occur in animals dying with acute symptoms after thyroidectomy. Further examinations as to the change in resistance to different organisms produced by thyroidectomy appear to be important.

G. N. Dourdoufi $_{\text{Mar.10,'94}}^{31}$ finds that young thyroidectomized dogs receiving injections of either thyroid extract, orchitic fluid, or cocaine live from two to eight days longer than those not injected.

Septic infection was a frequent cause of death. The writer believes increased tendency to septic infection to be a necessary consequence of cessation of the thyroid function. The following are some of the changes observed by d'Amore, Falcone, and Gioffredi [336 June 20,'94] in thyroidectomized dogs: Great diminution in amount of urine, trembling, cramps, analgesia of skin and mucous membrane, diminished frequency of respiration, fæces fluid and diminished, and spots of marked thinning in the walls of the small intestine.

Hofmeister [3 June 12,'94] finds that young rabbits deprived of the thyroid (parathyroids preserved) gradually lose their vivacity, become somnolent, and remain small and poorly nourished. When killed, three to seven months later, they showed no myxœdema, but atrophy of skin and muscles; no hypertrophy of thymus or spleen; hypophysis increased in volume. This enlargement is probably compensatory because several months after thyroidectomy the parathyroids can be removed without causing death. J. Rosenblatt [571 No. 45,'93; 21 Mar. 10,'94] finds that a severe hæmorrhage prolongs the life of thyroidectomized dogs, also a milk diet, while a meat diet hastens the fatal ending. His results agree, in the main, with those of d'Amore and others. The most important post-mortem appearances were: œdema of the brain, increased cerebro-spinal fluid, slight hyperæmia of the meninges, and ecchymoses in the gray as well as the white matter; passive congestion of the liver, spleen, and kidneys, and ecchymoses in the intestinal mucous membrane.

Symptoms.—T. S. Clouston [166 Jan.,'94] finds the general course of mental symptoms in nine cases to be, "first, slowness of mental action, emotional depression, irritability, morbid suspicion, non-restiveness to outward causes of disturbance, general loss of control, enfeeblement with some exaltation in some cases; lastly, lassitude, hebetude, and, just before death, mental negation." F. Vermehren [69 Oct. 26,'93] has experimented on three marked cases of myxœdema. Before treatment it was found that the patients excreted from one-half to two-thirds as much nitrogenous material as was contained in their food. Five days after beginning treatment with thyroid extract the excretion of nitrogen increased to double and treble the previous amount. While before treatment 20 per cent. of the nitrogen in the food was found in the fæces, after treatment

only 11 to 14 per cent. was observed. The great increase of elimination of nitrogen, however, must be the result of increased metabolism. Diuresis showed an absolute increase. The results of similar experiments in six patients suffering from other affections not myxœdema were: in young patients diuresis was affected in two out of three cases; in old patients there was evidently an increased metabolism of nitrogenous elements, and changes in pulse, temperature, and respiration were the same, but not as constant as in myxœdema. This fact leads one to suspect that the changes going on in the tissues in myxœdema are to be found in senile individuals, and that the cause is in one case the pathological, in the other the physiological atrophy of the thyroid.

Treatment.—G. W. Crary [5 May, '94] considers the thyroid of young sheep as better than those of older ones. Buys [868 July 14, '94] finds the anti-myxœdematous principle of the thyroid to be a substance soluble in glycerin and precipitated by alcohol. E. Blake [26 Sept. 1, '94] recommends the following procedure when patients cannot bear even very small doses of thyroid: twice a day, after hot sponging and vigorous rubbing, the body is well anointed with the following mixture: thyroidin, 10 parts; ether, 60 parts; lanolin, 480 parts. A rise of temperature of one degree followed the inunction. The process was well borne and followed by satisfactory results. Poncet [14 Apr. 1, '94] reports two cases of *thyroidoerethism* for myxœdematous idiocy. An aseptic foreign body (a bit of ivory ten to fifteen millimetres long) was introduced into the thyroid. The first case operated on, a year before the time of report, was cured of myxœdema, and the mental state notably improved. The second was nearly cured in three and one-half months, and the intelligence had become remarkably developed. As to the best form for giving the thyroid, H. W. G. Mackenzie [1077 Apr. 26, '94] says that to maintain a cure, or where large doses are required, there are considerable advantages, if only for economy, in giving the fresh gland. A convenient way to prepare it is to mince the gland fine, allow it to stand for half an hour in sufficient cold water to cover it, then express through muslin and add the liquid extract to beef-tea. It is best to begin treatment with a dry extract, as the dose is under more perfect control.

Complications.—W. A. Cross [59 Sept. 1, '94] reports a case of lymphadenoma accompanied by symptoms of myxœdema. The latter improved under thyroid treatment for a time, but the patient died

of Hodgkin's disease. The myxœdema was probably symptomatic, resulting from involvement of the thyroid in the fatal disease. W. M. Campbell [187 July, '94] reports a case complicated with glycosuria. Under antidiabetic treatment the sugar disappeared, but the myxœdema did not improve. Under thyroid treatment the latter was cured and the glycosuria much diminished.

Cretinism.—G. E. Anson, [6 Apr. 28, '94] A. Voisin, [14 Mar. 18, '94] T. Smith, [11 June 2, '94] T. C. Railston, [2 June 2, '94] and others report cases of cretinism and myxœdematous idiocy much improved by thyroid treatment.

LEGAL MEDICINE AND TOXICOLOGY.

By FRANK WINTHROP DRAPER, A.M., M.D.,

BOSTON.

SUICIDE.

It has long been a matter of common observation, says a Paris correspondent,[6] July 28, '94 that the onset of hot weather is synchronous with an increase of cases of mental aberration, often ending in suicide. Some relation appears, also, to exist between lunar development and suicide, for one week in which thirty-one suicides occurred in Paris extended from June 23d to June 30th, and the last quarter of the moon was on June 26th. The largest proportion of suicides took place between 6 A.M. and noon. Self-destruction is of more frequent occurrence in valleys than in elevated regions, and it is noted by the same writer that certain races are more prone to suicide than others, the Teutons taking the first rank and the canny Scots the last. Alexander Haig[15] Nov., '93 has previously pointed out the relation of mental depression and suicide to seasonal variations in temperature, calling especial attention to the excess of suicides in France in July. According to his theory,[6] Aug. 11, '94 the fact is explained by the effect of temperature on urate excretion, the excess of uric acid in the blood causing high arterial tension, which affects, to an important extent, the intra-cranial circulation. His researches show him that there is not only a diurnal fluctuation in the excretion of uric acid, with a maximum excretion in the alkaline tide of the morning and a minimum excretion in the acid tide of the evening and early night, but that there is also, for similar reasons, an annual fluctuation in excretion, with a maximum in the warm months (April to July), when the acidity of the urine is at its lowest and the alkalinity of the blood at its highest point, and a minimum in the cold months (November to March), when the urinary acidity is greatest and the alkalinity of the blood least. In the daily cycle the excessive excretion in the morning is largely dependent on the retention of

the previous evening and night; so in the yearly cycle the excessive excretion in the warm months is largely dependent on the previous retention in the cold months. With the onset of the heat and the first great fall in the acidity of the urine a great rush of stored uric acid into the blood will take place. Then, again, 6 A.M. to 12 noon—the most frequent time for the fatal act—is also just the time of the largest daily excretion of uric acid,—*i.e.*, the time when there is most of it passing through the blood.

In contrast with mental depression and suicide, gout shows us the effect of the opposite, or retention, end of the excretion cycles; for, as regards the day, its temperature is highest and the pain greatest in the evening and night, and lowest and the pain least in the hours of the forenoon; and, as regards the year, Sydenham is very emphatic as to February (toward the end of the retention period) being the month for first or most severe attacks, while he is equally careful to point out that, if attacks are absent or if chronic gout ever relax its hold, it is in the warm summer months.

In commenting on a dozen cases occurring in one week in London, an editorial[6] fails to find a sufficient explanation in season or weather, and believes that premeditated and intelligent suicide is always associated with some physical or moral weakness, and that the criminal and selfish aspect should not be lost sight of either by the law or public opinion. Another editorial writer[59] is of the opinion that suicide depends very largely upon race and temperament. While in Central Europe 1 out of every 4000 kills himself, in New England only 1 out of 25,000 will do it. Although insanity is the leading exciting cause, in these latter days drunkenness is becoming the preponderating factor. It would appear that alcohol depresses the highly-organized nervous systems more than it used to do. Another fact of interest regarding modern suicide is its prevalence among the aged. While absolutely the most suicides occur between the ages of 35 and 40 in New York, yet Thivet declares that at the age-period 60 to 70 the relative number is much greater, being 7.5 per 10,000, as against 4.7 between the fortieth and sixtieth years.

The special increase of suicide in 1893, in New York City, is doubtless due to the hard times, but the increase is not at all proportional to the enormous increase of suffering in that city and

all other parts of the United States. The same writer finds that New York has always been something of a "suicidigenous" centre. The only city that has ever exceeded it in suicidal rates is San Francisco, where 7 out of every 20,000 kill themselves annually.

The number of suicides in France seems to be assuming alarming proportions.[2018 Oct. 29, '92] The number from 1861 to 1865 was 12 per 100,000 inhabitants, while from 1886 to 1890 it was 21. In 1890 the total number of suicides was 8410, 78 per cent. being men and 22 per cent. women. The proportion of child suicides (under 16 years) has also augmented, the annual numbers running as follows: 1871–75, 31; 1876–80, 51; 1881–85, 61; 1886, 62; 1887, 68; 1888, 65; 1889, 77; 1890, 80.

Burt G. Wilder, of Ithaca, New York,[242 Dec., '94] gave an account of the post-mortem examination of the brain of an educated and apparently moral man who committed suicide: W. J. B., aged 35, dentist, shot himself, with a pistol, through the middle of the forehead and through the right temple. The fissures and convolutions of the brain showed the following abnormalities: (*a*) Excessive development of the external occipital fissure, constituting, together with the internal, a deep cleft separating the occipital lobe from the parietal. This corresponds to the *Affenspalte* of anthropoid apes, and is a stigma of defective evolution. (*b*) Duplication of both central fissures (fissure of Rolando); in the left hemisphere these passing into and becoming confluent with the Sylvian (a mark of abnormality which Benedikt has shown to characterize ill-balanced and criminal brains). Other abnormalities are also shown in the left frontal lobe at its posterior part. Further, as was pointed out by Dercum, of Philadelphia, the left parallel fissure pursued a markedly-ascending course, and joined the posterior part of the Sylvian,—another feature of degeneracy. Personal studies in the patient's heredity seem to have shown that suicidal and insane tendencies were present in the ancestors, thus confirming the data of brain morphology.

HANGING.

A. Ignatowsky[311 Oct., '93] studied the cause of death in hanging in dogs previously trephined, thus enabling him to note the changes taking place in the brain. The series of phenomena constantly observed were the following: First, several weak respiratory efforts,

rapidly followed by energetic aspiration; then a rather lengthy respiratory pause; and at the same time an intense venous congestion of the pia mater and cerebral hernia at the orifice of the trephine were observed, succeeded by gradual slackening of the heart-beats until complete cessation occurred. When the heart was almost completely arrested the brain diminished in size, the venous congestion disappearing little by little. A couple of minutes later there were several final inspirations, the heart again began to beat, but without affecting the size of the brain; finally the heart stopped and the animal died. It is thus seen that, contrary to what occurs in asphyxia generally, the opening and closing periods are very short, while the two intervening periods are relatively long. The author attributes the speedy loss of consciousness to increase in cerebral pressure (believing this to be clearly shown in these experiments), and the laceration of the internal tunic of the carotids to sudden traction upon these arteries, and not to their compression, as claimed by Hofmann.

DEATH BY BURNING.

The position of a human body burnt, but not completely destroyed, by fire is, according to Becker, of Colchester, $\frac{2}{\text{June 16, '94}}$ one of considerable interest from a medico-legal stand-point, in cases in which it is necessary to determine whether the body has been burnt before or after rigor mortis has set in. Physiologically, we know that a muscle contracts by heat, and if the action of heat be continued it passes into a state of heat-stiffening or rigor,—a condition beyond recall by the use of any known process. Anatomically, it is interesting to note that the larger a muscle in any one group, the nearer its relation to the surface. The muscles of the human body are not conductors of heat; it follows, therefore, that heat would take a longer time to affect the deeper muscles than it would the more superficial ones, as heat must reach the deeper ones in the first place by convection and radiation through the already stiffened superficial muscles. It follows, therefore, that an intact human body which is subjected to heat in a sufficient degree, and which has not been affected with rigor mortis, will assume a position which is determined by the contraction of all the superficial muscles. This position, being the resultant of all the superficial muscular forces, might be called the position of

superficial muscular equilibrium. If heat-stiffening has taken place, this position is permanent until putrefaction is complete, unless it is destroyed by mechanical means.

The position of such a body clearly has no relation to the position it occupied before being affected by heat. The head must be kept in the middle line of the body, the jaws firmly closed, the chin extended; the head extended back upon the neck, the neck straight; the upper part of the chest in a position of inspiration; the shoulders slightly raised; the arms raised outward almost to a right angle, more backward than forward; the elbow flexed, the forearm in a position of supination, the spine straight and extended, the pelvis very slightly tilted upward; the thigh extended, abducted and rotated outward, and the knee flexed.

In a body in which rigor mortis is fully established in its second stage, or has passed off, the muscles are dead and will not react to heat; so such a body would occupy the same position as it did when heat reached it. Would it not be possible, then, the author asks, to say, from the position of such a body, whether rigor mortis had occurred or not, so as to reach some data as to the time such body had been dead? The factors of rigor mortis being destroyed by heat, rigor mortis would not occur in contracted and heat-stiffened muscles, as it would have had time to declare itself.

Kijanitzin [20 B.131] has concluded from extensive experiments that death from severe burns is to be attributed to a disturbance of nutrition and of the chemical processes in the skin, giving entrance to toxic bodies. He has isolated a ptomaine which he considers characteristic of burns.

ELECTRICITY AS A CAUSE OF DEATH.

According to Hedley, of Brighton, [6 Aug.25,'94] it may be considered that the alternating currents of commerce may cause death in either of two ways: (1) by actual lesion or destruction of tissue, and (2) by arrest of respiration, producing asphyxia. In the former class death is actual, and nothing can restore animation; in the latter, restoration is sometimes possible, the contact being generally of short duration, the tetanic muscular contractions not lasting long enough to induce a fatal elevation of temperature. In a case reported by the author, an alternating current was accidentally short-

circuited through the body of a man, the voltmeter registering 4500 volts and the ampèremeter marking 750 milliampères. The point of entrance was the hand, and that of emergence the buttock, the contact lasting many minutes. More than half an hour elapsed before artificial respiration was commenced, and during that time the man showed no sign of life. Arm-movements were then carried out, without apparent effect; on practicing the Laborde procedure, however, respiratory movements soon appeared, and in about two hours the man could speak. In the course of a few days he had quite recovered, excepting from the burns at the points of entry and exit. In such accidents the line of treatment to be pursued is sufficiently obvious. It is imperative that artificial respiration be promptly and patiently carried out.

In Donnellan's case $_{\text{Aug. 4, '94}}^{9}$ morphine ¼ grain (0.016 gramme) was given hypodermatically about an hour after the accident; and, as the delirium and convulsions did not abate, the injection was repeated in half an hour, when the man soon quieted down. An hour and a half afterward, his respiration becoming alarmingly feeble, he was given strychnine, $\frac{1}{30}$ grain (0.002 gramme), hypodermatically, with excellent results.

In view of the employment of electricity as a method of execution in some States, a case reported by P. S. Donnellan, of Philadelphia, $_{\text{Aug. 4, '94}}^{9}$ is of interest, as showing the high voltage which can be endured without fatal results. The patient, a man of 44 years, while repairing broken telephone-wires, grasped the ends of a wire that had crossed an electric-light wire, conveying 1000 volts. He received the full force of the current through his body and was immediately rendered unconscious and thrown violently to the ground. He was taken to St. Mary's Hospital, and under appropriate treatment made an excellent recovery. He stated that he was absolutely insensible to pain from the instant he received the shock, even the actual discharge of the current causing him no suffering, and, were it not for the burning of his skin, he would not have been aware that he had met with an accident. Donnellan therefore regards the electric current, properly applied and of sufficiently-high tension, to be the most humane method of judicial execution.

D'Arsonval $_{\text{May 9, '94}}^{22}$ related the case of a railway-porter who was rendered senseless by an electric current of 5000 volts. Although

the man was apparently dead for forty-five minutes before help could be brought to him, he was recalled to life by artificial respiration and traction of the tongue as recommended by Laborde. According to the latter, artificial respiration alone would not have sufficed in such a case, and cited the history of two men who were knocked down by an electric current of 2000 volts near Geneva; one was treated exclusively by artificial respiration, the other by traction of the tongue. Only this latter one recovered.

W. S. Hedley, of Brighton, [6] also shows that death in electrocution and in electric accidents may be, and at first often is, only apparent, recovery being still possible and even probable by timely resort to artificial respiration. There is a limit, however, to this possibility of recovery. If the elevation of temperature produced by the passage of such current exceed 45° C. (113° F.) death ensues, as Claude Barnard has shown, by solidification of the muscular fibres of the heart.

SUDDEN DEATH.

A. Legros, [2071] in an elaborate work, reviews the entire field of this subject and lays special emphasis upon the advisability of invariably performing autopsy in all cases of sudden death. To show the importance of this, he describes a case in which, although no external lesions existed, post-mortem examination elicited the fact that the pelvis was crushed, that several ribs were fractured, and that the intestines were severed in several places. External examination had led to a verdict of death by one of the three usual causes,—aneurismal rupture, pulmonary embolus, or apoplexy. His classification does not quite agree with that of classical authors, the sequence as regards frequency being given by him in the following order: heart, stomach, kidneys, lungs, and brain, indicating that sudden death due to brain disorders is comparatively rare, —contrary to the general opinion.

Councilman, of Boston, [99] [5] read an interesting article, before the Massachusetts Medico-Legal Society, upon sudden death due to the heart. Of endocardial conditions which may lead to sudden stoppage of the heart, thrombosis and embolism are considered the most important, though of rare occurrence. By far the most frequent causes of sudden death are to be found in disease of the heart-wall, and the most important of these result from

lesion of the coronary arteries and consequent diminution of blood-supply to the heart-muscle. Since the coronary arteries are "terminal arteries," as a rule having no considerable anastomoses with one another, disease of one of them may seriously impair the blood-supply of that portion of the heart-wall dependent upon it for nourishment. If sudden stoppage of one of the larger branches occur, infarction of the heart-muscle may result. This is, however, rare, and the usual effect of interference with the coronary circulation is the growth of fibrous tissue in that portion of the wall insufficiently nourished,—interstitial myocarditis. The patches of fibrous tissue thus formed are prone to stretch and become thin, in which case a true aneurism of the heart results, and, like aneurisms of the vessels, this may rupture. Other causes of rupture of the heart dependent upon disease of the coronary arteries are the formation of patches of necrosis or of fatty degeneration. Fatty infiltration, in which large deposits of fatty tissue beneath the pericardium and in the myocardium occur, is also an occasional cause of rupture of the heart. In rare cases sudden death may result from pericarditis, where the very rapid accumulation of exudate may overwhelm an already enfeebled heart. The sudden death occasionally observed in cases of aortic stenosis is probably dependent in most cases on the inability of the already overtaxed heart-muscle to cope with a sudden increase of intra-cardial pressure brought about by exertion or by psychical influence.

Luys, of Paris, [14] Aug. 1, '94 examined a section of the brain of a young officer who died during coitus, performed immediately after a copious meal. The white substance especially and the fibres around the Island of Reil in particular were studded with groups of punctiform congestive spots. The vessels and capillaries seemed gorged with blood, giving the appearance of a true hæmorrhage. Closely examined, however, it became evident that no rupture existed, but that the blood had been extravasated through the vessel-walls without rupturing them. The cerebral substance was neither lacerated nor softened, and, under the pressure of a thin stream of water, the spots disappeared, but the perivascular substance was not affected. The same lesions were found in all the other portions of the encephalon, the whole indicating intense congestion of the entire cerebro-spinal vascular system.

W. F. Whitney, of Boston, [99] Apr. 19, '94 reported a case of sudden

death due to hæmorrhagic and gangrenous pancreatitis, which disease must be differentiated from another form of inflammation of the pancreas, associated with the formation of pus (suppurative pancreatitis), usually of long duration.

So far as pancreatic hæmorrhages are concerned, in their relation to sudden death, I think the anatomical diagnosis is not at all a difficult one when the lesser omental cavity is opened, as it always ought to be, for inspection; the case declares itself almost at once; there is no reasonable room for doubt as to what one has before him. The organ itself, normally pale, yellowish-white, is, in these cases, discolored red, and on either side and around the end of it will be found, in the retroperitoneal connective tissue, an infiltration of blood that is unmistakable; so that it is not a matter of difficulty in diagnosis, but ordinarily a matter of neglect in the pathologist, that these cases escape observation. In some 4000 cases of death of all sorts, I have seen 19 cases in which there was some pancreatic hæmorrhage, but not in all those 19 was it to be assigned as the one cause of death. It was in company with other conditions,—conditions relating to the liver or to the kidneys, or the heart or to the lungs,—which were complications, so to speak, making the post-mortem diagnosis a little more difficult; but in some nine or ten cases there was no other cause of death.

DEATH FROM BULLET WOUNDS.

The Mannlicher Magazine Rifle.—The recent adoption of small-calibre rifles by the armies of the principal European nations renders especially interesting a paper read by Fernandez de Ybarra, before the First Pan-American Medical Congress, $\frac{451}{July,'94}$ upon the wounds caused by the Mannlicher rifle, as exemplified by the recent civil war in Chili. This rifle is of two kinds, one being a revolving magazine repeater, the other a detachable magazine repeater. The revolving magazine in the former consists of three joined parallel tubes, each holding a number of cartridges, the whole being automatically revolved on a central axis as each tube is emptied, to bring one after another into the proper position for delivering the cartridges. The magazine is contained in a chamber formed in the butt of the stock, and is loaded through an opening in front of the guard. The cartridges are successively fed forward by a spiral spring, automatically thrown up into an horizontal position, and

forced into the breech of the barrel while placing the lock in the firing position. The cartridges are metallic and central-fire, but are necessarily of very small calibre. The second Mannlicher rifle has a detachable magazine, but the breech-mechanism is the same. The magazine is fixed to the shoe of the breech-action, and, when detached, is used as a cartridge-pouch. Several magazines, each with a certain number of cartridges, can be loaded, and, when needed, successively and quickly attached.

The shape of the bullets has also undergone evolution, the narrow cylindro-conoidal form, with ogival base, of the Mannlicher improved rifle having a penetrating force, even at a distance of six hundred metres from the weapon, sufficient to pass through five human bodies placed half a metre apart, or to at once disable two horses. Owing to the extraordinarily high rate of velocity and rotation, hardness, narrowness, smooth surface, and pointed shape of the projectile, it has no time to stretch the various tissues encountered in its passage, but punches out a narrow passage resembling that made by a powerful drill. The apertures of entrance and exit are almost exactly of the same size, and the wound is thus left in a favorable state for healing by first intention, as no contused parts remain for removal by sloughing. In the Chilian war, careful observation showed that when the bullet struck the soft parts of the body the wound showed a cylindrical track almost the exact size of the ball, usually what is called a "seton wound." There was scarcely any difference between the point of entrance and exit, and no appreciable variation in the time of their healing. This does not happen, as every experienced army surgeon knows, with the common leaden bullet, in which case the wound of entrance heals more slowly. Wounds in the shaft of long bones were as if made with a boring machine,—clean-cut, straight, and regular. Gunshot wounds of long bones, as a rule, cause fractures which are rarely simple. Fissures were usually observed when an epiphysis was struck, although in one instance the bullet passed through without any splintering of bone, the wound healing by first intention in ten days. In wounds of the chest it was remarkable to notice that scarcely any complication resulted, not even pulmonary abscess or purulent pleuritis,—so common in non-perforating gunshot injuries of the thorax. Hæmorrhage was but slight, the projectile actually searing the flesh, and the surface of

the whole wound-track closing spontaneously immediately after the passage of the bullet.

The object of civilized warfare being, theoretically, *not to kill but to disable* the greater number of our antagonists, it appears, from actual trial, that the small-bore rifle accomplishes this humane end, through its greater initial velocity, flatter trajectory, greater accuracy of aim, greater penetrating force, greater range, the lightness of the gun and charged cartridge, the smokeless powder, and the rarity of foul guns after battle. To these advantages must be added the comparatively little harm caused by the projectile, although it remains to be proven to what extent it is desirable that the wounded should not return too soon to the field of battle.

Wagner, [397 '93; 22 Oct. 4, '93] in a contribution upon twenty-eight cases of suicide or self-mutilation with the small-bore rifle, reaches conclusions very similar to those of Ybarra, the prognosis in fractures being especially more favorable than with the weapons formerly used.

Ladreit de la Charrière [6 Mar. 2, '94] comments on the frequent escapes from death after bullet wounds in the neighborhood of the ear. He was recently called upon to treat for some ear trouble a young woman lately recovered from a self-inflicted bullet wound in the ear. The bullet, penetrating somewhat above the external meatus, had found its way into the temporal fossa, and returned into the external meatus, the only injury being perforation of the tympanic membrane. Polaillon had a case where a revolver-bullet penetrated through the ear into the brain, finally lodging in the pons on the opposite side. There it remained for five days without provoking any further symptom than headache. Then encephalitis set in, and death occurred in spite of trephining. Brouardel once performed a necropsy on the body of a maniac in whose cranium and brain there were discovered, in addition to the projectile that had occasioned death, three others, the results of previous attempts to commit suicide. Two had lodged in the temporal bone, and the third was encysted in the brain-substance. On another occasion he made a post-mortem examination of a man who was seen by a crowd to fire into his forehead a ball of 11 millimetres' calibre. He remained standing, and then fired a second ball into the ear. Again he did not fall, and only a third shot, fired from below upward into the mouth, brought him to the ground. Brouardel remarked that had the tragedy not been

witnessed by so numerous an assembly the theory of suicide would hardly have been entertained. It follows that in such cases which terminate fatally it must not hastily be assumed that the penetration of a bullet into the ear is the real or the only cause of death.

SIGNS OF DEATH.

In an article on the diaphanous test of death, B. W. Richardson, of London, [38 v.10,No.38] showed that in a dead person the edges of the fingers transmitted light, as is commonly seen in the living subject, the blood in the same dead body remaining fluid. To ascertain whether the fluidity of the blood accounted for the diaphanous condition of the fingers, he performed the following experiments [38 v.10,No.39]: Having obtained a portion of defibrinated sheep's blood, he allowed it to stand until it became very dark, but not offensive. Over glass tubes, representing fingers, he then stretched fine wash-leather, and immersed them in the blood, leaving them to saturate in the fluid. When they were quite saturated he removed them from the blood, dried them with a soft cloth and bibulous paper on their outer surface, and, putting them together as fingers are, held them up to a very strong light proceeding from a powerful lens. At the points where these artificial fingers came near together light passed through, the red color showing precisely as it does in the living fingers. He then proceeded to set up coagulation of the blood absorbed and held by the leather skin, and first tried to produce the coagulation by exposure to radiant heat, but was not clearly successful. Then he immersed the fingers in heated water at 160° F. (71° C.), under which the skin somewhat shriveled, and another bad effect followed. Finally, he made an acid solution by adding 1 part of nitric acid to 4 of water at the ordinary temperature. After a few minutes of exposure to the acid solution the blood was coagulated throughout, and the surface, as is common under nitric acid, was bleached; so that when the tubes were taken out of the acid solution and dried they very well resembled fingers, the skin appearing flesh-like in color. Now, on being held up to the same degree of light as before, not a trace of red light nor of any light could be seen. There was just the same result as when the dead fingers of the body in which the blood has coagulated are subjected to the same test of light. We may take it, therefore, as corrective of the diaphanous proof of death

that, when in any inquiry the blood in the veins remains fluid,—as will often be the case in cold weather,—the edges of the fingers will transmit light, though the body be dead. The effect of coagulation of fibrinous and albuminous structures is to prevent the transmission of light through them. This is seen in the fibrinous clot and in solutions of albumin, but not in the same degree, however, in gelatinous coagulations or solidifications. What coagulation does to interfere with the passage of light in the first-named class of substances is open to a further inquiry, which may perhaps throw light on the molecular change which constitutes the process and gives it its name.

Nicati [6 Feb. 17, '94] has invented an ophthalmotonometer, by the aid of which he has discovered that the tension of the globe of the eye, which is normally from 18 to 21 grammes, may oscillate, in the physiological state, between 14 and 25 grammes (T. = 0.4 to 1). This tension diminishes with the cessation of the heart-beats to 12 grammes, and the lowering of tension, interrupted by rebounds never exceeding 12 grammes, is afterward progressive, until, after the lapse of half an hour, it has sunk to from 1 to 3 grammes. In two hours it is *nil.* The enucleated eye replaced in the orbit presents the same phenomena. The usefulness of this method in medico-legal practice is self-evident, and Nicati claims, in his paper read before the Académie des Sciences of Paris, a further field of usefulness in general medicine for his instrument, seeing that it can be employed in determining the blood-pressure, the amount of which always bears a constant relation to that of the aqueous humor.

PHYSICAL SIGNS OF VIRGINITY.

H. McNaughton Jones [26 Apr. 2, '94] insists upon the importance of a variety of abnormality of the hymen which, unrecognized, may lead to legal errors. That variety which has several times come under his notice, and to which he gives the name of "*folding*," is the hymen of normal appearance and structure, but of a peculiarly yielding nature, readily admitting the passage of an ordinary vaginal dilator or a fair-sized speculum, in the passing of which it folds back against the vaginal wall, and returns quite intact on the withdrawal of the instrument. To give an instance of the kind of error to which ignorance of this fact may lead, the follow-

ing may be mentioned: A most serious charge is preferred, which is in part rebutted by exculpatory evidence on oath, that a man has had intercourse with a young girl, extending over a considerable period of time. The case is one in which the gravest issues are at stake. The girl's cause is subsequently taken up by powerful friends, and she is submitted to medical examination. The hymen is found complete, and upon this fact medical opinions are elicited that it would have been impossible, or at least improbable, that sexual intercourse could have been continued over such a length of time as that stated.

LATENCY OF GONORRHŒA.

Morel-Lavallée [263 Dec., '93; 112 Aug., '94] has an article with the heading "Can One Acquire Gonorrhœa from a Person Who Has it Not?" He gives a case in which a husband, wife, and lover were involved, and submits the following conclusions: Viewed clinically: 1. The morbific agent of gonorrhœa may rest latent for months, or even years (in one of his observations six years). 2. The blennorrhagic virus may, in the woman, remain absolutely latent for three or four weeks and still preserve its full virulence. 3. The occurrence of the menses seemed to facilitate the outbreak of the affection. Viewed socially: It is impossible to permit marriage in a man that has the slightest drop of discharge until it has been proved by the tests of Neisser (nitrate of silver), or bichloride of mercury, or beer (Janet), to be aseptic. Viewed bacteriologically: 1. The gonococcus can be deposited in the genital tract and not develop, the patient escaping the disease entirely. 2. It may rest in the genital tract and still retain its virulence and capability of transmitting the disease. 3. The gonococcus may remain in the female urethra, at least for several days, without giving rise to any appreciable clinical signs. 4. Menstruation may light up a gonorrhœa which would otherwise have remained latent. The author ends by answering the question with which he heads his article by quoting Ricord to the effect that "the most beautiful girl in the world can only give that which she has."

THE CONTROL OF PROSTITUTION.

In an article discussing the results of State and municipal laws, Aaron M. Powell [June 1, '94] states that the physician, beyond any

and all others, has it in his power to so mold public opinion, especially concerning the sanitary aspects of prostitution, as to make it practicable for wholesome repressive laws, in the interest of morality and health, to be enacted and enforced. It was the irresistible force of medical testimony against the Contagious Diseases Acts, combined with the moral protest, which rendered their final repeal inevitable. It is the weighty condemnation of the regulation system in Continental Europe by eminent physicians and sanitarians, in conjunction with moral power, which already foreshadows its abolition in the near future. So the voice of the medical profession here, directed against State and municipal complicity with vice, may and should so enlighten public opinion as to reduce public prostitution to a minimum, by making possible the enforcement of wholesome legal restraint. There is still abroad the popular heresy that for men vice is a necessity, and that young men must sow "wild oats." What is morally wrong cannot be physiologically right.

An editorial, $\frac{50}{\text{Mar.24,'94}}$ bearing upon the part the medical profession could play in modifying existing conditions, alludes to the many elements tending otherwise to thwart purely legislative measures, and to the fact that no law has yet been found to effectually legislate against immorality based upon perverted or diseased appetite. The liquor laws show this. The individual resents the attempt as a blow at his personal rights, and retaliates in circumventing the law by acts which were not dreamed of before. The prostitution laws also show as much in the increase of clandestinism in direct proportion to the apparent decrease of legitimized wrong. All this proves the complexity and many-sided aspects of the question.

The most perfected inspection that can be at present instituted cannot eradicate venereal diseases, even allowing that both parties are equally subjected to such supervision. No absolute guarantee can be given against infection in persons exposed to the chances of the frequently concealed, the dangerously incubating, and the often unrecognized contaminating influences. The certificate has only an approximative value, which may be entirely annihilated by the first new-comer, who may be the means of transmitting the virus to the next, even in the intervals of the most frequent official inspections. When such facts become more widely known, they may be of themselves an element of control

of this form of licentiousness which will be more powerful than law and more effectual than any other form of appeal. It is here that the medical man can do good in a quiet, admonitory, and telling manner. Let him, on all suitable occasions, combat the idea that sexual indulgence is necessary for health, and maintain, with equal truth and force, that chastity is perfectly compatible with full vigor; that it conduces to strength of mind and body; is the foundation of the purest morality; is the most effectual safeguard against any form of prostitution; and the only and absolute answer to the possibility of controlling this wide-spread vice. If every physician could be a missionary in his own field and would inculcate such a doctrine, especially among the young, the effect upon the coming generation would be beyond calculation for good, and would prepare the way for that perfected education in morals which would strike at the very root of the evil.

G. Bergonzoli [605 v.14,'93; 866 Mar.,'94] finds the following degenerative abnormalities in the crania of 26 prostitutes:—

Wormian bones	in 5 crania	20 per cent.
Platycephaly	in 4 crania	16 per cent.
Plagiocephaly	in 5 crania	20 per cent.
Trochocephaly	in 1 cranium	4 per cent.
Stenocrotafia	in 2 crania	8 per cent.
Acrocephaly	in 3 crania	12 per cent.
Pharyngeal tubercle	in 3 crania	12 per cent.
Facial asymmetry	in 2 crania	8 per cent.
Appendix lemurini	in 9 crania	36 per cent.
Alveolar prognathism	in 6 crania	24 per cent.
Premature disappearance of sutures	in 3 crania	12 per cent.

In 10 of the crania there existed simultaneously 3 of these anomalies (20 per cent.); in 9, 2 existed (36 per cent.); in 10, 1 alone was observed (40 per cent.); and in 1 there were no anomalies.

INSANITY.

Responsibility of the Insane and Criminals.—Benedikt, of Vienna, [166 Oct.,'94] in an address before the Medico-Psychological Association of Great Britain and Ireland, in June, 1894, observed that a state of subtypical intelligence and congenital feeble-mindedness is not sufficient to prove a person of moral perversity to be insane. He submitted the following propositions: 1. Congenital or acquired moral depravity is no reason for exculpation in the case of the criminal or vicious. 2. Exculpation can only be extended to

cases in which criminal or vicious actions have resulted from real insanity,—acute, chronic, or periodic. 3. The combination of depravity with congenital feeble-mindedness does not exculpate. Only those states of so-called irresistibility can be deemed insane, in which the seizures are mere explosions, and not exaltations of normal conditions. For instance, a very irascible person may become furious, but as a general rule the commission of a criminal act at such a time cannot be exculpated. But when a person becomes furious, without sufficient subjective or objective reason, we recognize the pathological nature of the explosion, even if the real reason cannot be assigned. 4. It follows, therefore, that obsessions are necessarily unexpected and unexpectable, and so exculpate. When fits of abnormal conduct appear as exaltations of the usual psychological state they do not exculpate.

Disorders of Pantomime.—Mills $\frac{2094}{'95}$; $\frac{2}{Apr.14,'94}$ observes that pantomime is the representation of ideas by action and movements. Signs and motions may be disordered as well as words and sounds. There may be sensory or motor *amimia.* In nine cases of aphasia notable differences in pantomime were present. If the lesion is in the central ganglia, pantomime is either not lost or is quickly recovered. The usual pantomimic method of expressing assent, etc., may have several interpretations, just like the "yes" and "no" of aphasics. The emotional manifestations of the patient must not be misunderstood. True amimia is an intellectual disorder. In aphasics with serious disturbances of pantomime, the losses shown on the emotional side are seen in meaningless continuations and repetitions, in slow transitions and undue excitement. The author records two cases: 1. In a woman, aged 54, with right hemiplegia and aphasia, chiefly of the motor type: pantomime varied; she at times nodded "yes" when she meant "no"; she would not use her sound arm to signify anything. 2. In a woman, aged 40, with right hemiplegia and aphasia of a mixed type, the amimia was almost complete; she was not word-deaf, or, at any rate, not completely so; her speech and pantomime might be summed up in her "la la" and laugh, and an expression of anger or displeasure, when she covered her mouth with her hand; the facial expression was otherwise always the same; she never nodded her head for "yes" or "no." The medico-legal aspects of disorders of pantomime are emphasized by the author.

Litigiousness in the Sane and Insane.—Ludwig Horn, [650] after a careful review of the literature of the differential diagnosis between litigiousness in the sane and insane, arrives at the following conclusions: 1. Anamnesis reveals nothing of importance in sane litigants; in the querulous paranoiacs, an hereditary taint, peculiarities in childhood and after-life. 2. The sane litigant shows no abnormal somatic symptoms; in the paranoiacs somatic peculiarities are seldom absent. 3. The motives of sane litigious people are pleasure in law-suits, or the desire to obtain a final decision in a particular point of law; in the insane the motive lies in an hereditary defect,—an inability to submit to an unfavorable decision. 4. Characteristics of litigiousness: (*a*) The sane litigant maps out his course of procedure; the paranoiac believes it impossible to lose his case, and does not plan beforehand. (*b*) The sane litigant will not go beyond a certain point, decided upon in the beginning; the paranoiac does not limit himself. (*c*) The sane litigant can end his trial at will; the paranoiac is drawn into new trials by his disease.

Menstruation.—Krafft-Ebing [395] reaches the following conclusions on the importance of menstruation in determining mental irresponsibility: 1. It is useful to consider the mental soundness of women during menstruation from a medico-legal point of view. 2. It is advisable, where a woman is held on a criminal charge, to ascertain whether the commission of the act coincided with the menstrual period; and by "period" is meant not only the days when there is actual flowing, but those before and after as well. 3. It is best to advise examination of the mental condition when such coincidence is established. This is indispensable when there is a personal history of neuropathic defect, of mental disturbance at the time of previous menstrual periods, or when the nature of the act reveals any striking features. 4. When the menstrual process exerts a powerful influence on the mental life of the subject, the accused should be given the benefit of extenuating circumstances in the infliction of the penalty, even although there be no proof of menstrual insanity. 5. When the offense of crime has, in a person whose mind is impaired, occurred during the menstrual period, she must be declared irresponsible, for there is every reason to think the act due to emotional impulse. 6. But individuals who, by reason of menstrual insanity, would benefit

by acquittal on this ground should be considered as dangerous in the extreme and subjected during the times of the menses to close surveillance. It is best to confine them to any asylum for the insane where they will be comfortably cared for and often cured of this menstrual instability of mind.

Handwriting of Criminals and Insane.—Ottolenghi and Carrara [605 v.16,No.8,'94; 278 Jan.,'95] used the Edison electric pen to demonstrate certain peculiarities in the writing of the insane and of criminals. Binet and Courtier having shown that in normal handwriting the fillet that joins the letters is traced more rapidly than the letters themselves, the Italian authors find that this relation is frequently exactly reversed in criminals and in the insane, as shown by the lessened distance between the punctures of the electric pen. It is also met with in various nervous conditions, in cases of tremor paralysis and of spasm, and also of alcoholism and in certain emotional conditions. They claim that this reversed type may exist when the disturbance is not revealed by any other sign, as in incipient alcoholism and in the emotional conditions easily induced in some criminals. Comparing numerous specimens of the handwriting, taken at repeated trials, of five normal individuals, two lunatics, three criminals, two alcoholic cases, one epileptic, and two individuals emotionally excited, the relative frequency of this inverted type was found to be as follows:—

In normal individuals	14 per cent.
In criminals	63 per cent.
In alcoholism	47 per cent.
In epileptics	28 per cent.
In insane	81 per cent.
In emotionally disturbed	60 per cent.

Among normal individuals they found this type occurred in consequence of involuntary disturbance, such as followed making errors in orthography, etc. The communication is given as a preliminary one. The importance of the symptom (if true) is evident in cases of imitation or forgery, as well as in cases of incipient disease.

Identification.—D'Abundo, [589 June 20,'94; 90 Dec.,'94] after studying the digital impressions of 140 criminals, expresses dissatisfaction with the results obtained by Galton, inasmuch as they were incapable of affording an exact idea of the normal type of human digital impressions. He had, therefore, undertaken a methodical investi-

gation of normal digital impressions, but had obtained no positive conclusions, apparently from want of sufficient material, although he was able to state that two facts seemed to be fairly firmly established: 1. That the digital design is well developed at the sixth month of intra-uterine life. 2. That the details of the design are fundamentally the same throughout the whole of life. In his observations upon criminals he found that the impressions were asymmetrical in 44.1 per cent. of the thumbs, 33.3 per cent. index, 14.1 per cent. middle, 34.1 per cent. of the ring, and in 14.1 per cent. of the little fingers. In 10 per cent. of the criminals there were deviations from the normal type, which had presumably arisen from nervous impressions during fœtal life. From the point of view of identification D'Abundo noted the frequency of cicatrices which produced distinctive modifications of the digital design. They occurred in 54.2 per cent. of the cases,—one cicatrix in 37.1 per cent., two in 10 per cent., three in 5.7 per cent., four in 0.7 per cent., five in 0.7 per cent. of the cases examined,—and he referred to the importance of these particulars in establishing the identity of the individual.

Pyromania.—Camuset $\frac{361}{\text{Nov., Dec., '93}}$; $\frac{866}{\text{Mar., '94}}$ examined a man with vesanic heredity, who was mentally debilitated, not neuropathic, but of nervous temperament, emotional, proud, and contemptuous, and who, from infancy had shown himself to be hypocritical and mischievous. At 16 he began to fire places under the influence of angry periods, of very slight origin. He fired without premeditation, always in the evening, and alcoholic excitation had some influence on his incendiarism. Without reference to anything he would become furious, but soon controlled himself and dissimulated his anger. The idea of vengeance permeated his mind, and he avenged himself by firing the property of his enemy. Then he called for help, assisted to put out the fire, and so conducted himself as to disarm suspicion. Camuset found that the man was partially responsible for his acts, and belonged to the born criminals or moral lunatics.

Miscellaneous.—A case of strangulation and suffocation by the mother of a child a year old, suffering from porencephaly; one of accidental suffocation in a child with typhoid fever; and one of fracture of the skull in an alcoholic and quarrelsome man of 67 years, suffering from double acute pneumonia, are reported

by Henry Coutagne, of Lyons. [211, Aug.5,'94] In all three cases the diagnosis of the real cause of death was rendered difficult by the character of the anatomo-pathological lesions present; in the third case the coincidence of acute pneumonia with cranial lesions formed an interesting, though not altogether rare, condition for medico-legal study. The responsibility of hysterical patients as regards crime formed the subject of an inaugural address by A. Velasquez de Castro, before the Royal Academy of Medicine and Surgery of Granada. [2017, '94] The relation of morphological abnormalities to nervous and mental disease is considered by Sommer [68, Dec.,'93] in its legal bearings.

UNSEXING FOR CRIME.

Robert Boal, of Lacon, Ill., [61, Sept.15,'94] in a paper before the State Medical Society of Illinois, made a plea for the emasculation of men and ovariotomy in women for the punishment of crime and for the reformation of criminals, supporting it by the following arguments: 1. That the surgical unsexing of all criminals convicted of offenses that indicate constitutional depravities, that are transmissible by heredity, is both expedient and practicable. 2. That this penalty should be applicable to both sexes. 3. That most of the offenses against society by vicious and defective classes originate in sexual disturbance, whether in deprivation or excess. 4. That it limits the reproduction and transmission by heredity of the defective and criminal classes of society. 5. That it inflicts a penalty that is terrifying and abhorrent without destroying life. 6. That it is applicable to other offenses against person or property, originating from other than sexual causes. 7. That while effective, the punishment is neither cruel nor vindictive. 8. That it is more effectual in changing and improving the nature of the criminal than moral instruction, confinement in prison, or houses of correction.

TOXICOLOGY.

The Blood in Poisoning.—The alterations in the blood in cases of poison have been studied by Ottolenghi, [997, Dec.7,14,'93] who finds that the greatest changes are produced by arseniuretted hydrogen, chlorate and cyanide of potassium, carbonic oxide and phosphorus. Nitric acid produces alterations similar to those of chemical asphyxia, and strychnine changes similar to those caused by mechanical asphyxia. The resistance of the red cells is most usually affected,

and the coagulability of the blood is lessened in asphyxia. Oxidation is less affected, seeming to depend upon a combination of the poison with the coloring matters, the crystallization of the latter being modified by certain substances. These blood changes are not peculiar to poisoning, but are met with in certain pathological states and in premature decomposition of the cadaver. They are entirely absent in death from traumatism; at least, in the first hours. They exercise considerable influence on the process of putrefaction, which is accelerated by the diminution of coagulability, the density of the blood, and the resistance of the cells. These points are to be borne in mind in fixing the date of death in cases of poisoning.

The unequal diffusion of poisons in the organism is discussed by Paul Heger, of Brussels, $^{868}_{\text{Aug.18,'94}}$ who advances the theory that tolerance once being established, a substance originally harmful may be utilized by the organism in its purposes of nutrition, and thus serve to sustain life. He instances caffeine, theine, and theobromine as belonging to this class.

Forced Respiration.—Fell, of Buffalo, $^{130}_{\text{Jan.,'94}}$ advocates forcibly passing atmospheric air or oxygen-gas into the lungs in cases of narcotic poisoning, drowning, and still-birth. He at first employed the apparatus which he used for forcible respiration in physiological experiments on dogs, but afterward devised a more suitable one which could be used by laymen for the resuscitation of persons apparently drowned. He has published forty-four cases, in all of which unmistakable evidence of the value of forced respiration is given.

Foy, of Dublin, $^{22}_{\text{Mar.23,'94}}$ has for a number of years urged the value of oxygen-gas, passed in a full stream from a bottle into the lungs of patients suffering from asphyxia. He regards it as an unequaled method in cases of poisoning by opium, chloroform, ether, and other narcotics.

Benzin.—Rosenthal $^{319}_{\text{Mar.13,'94}}$; $^{2}_{\text{May 19}}$ reports a case in a girl aged 1½ years. The quantity taken was uncertain. When seen, ten to fifteen minutes afterward, the child was in a condition of stupor, with half-open eyes. The radial pulse was small, frequent, and subsequently could not be felt. Respiration, 60 to 70. A tube was passed through the nose and the stomach washed out. The water used for the washing smelt strongly of benzin and contained

blood-stained masses of mucus. In about six hours the child had considerably improved, and subsequently recovered completely. Benzin produces a gastro-enteritis, as, indeed, it has been shown to do in animals. Treatment should consist in washing out the stomach as soon as possible, as benzin is rapidly absorbed. If the breathing fail, artificial respiration should be practiced. Benzin is not identical with benzol, but is a mixture of hydrocarbons, especially hexan and heptan. Sometimes benzin poisoning is caused by inhalation. The author refers to a case of an alcoholic who took to inhaling benzin in place of drinking. He also refers to some instances in glove-cleaners, and observes that this fact should not be overlooked in such cases.

Carbolic Acid.—Langerhans $_{\text{Nov.30,'94}}^{69}$; $_{\text{Jan.6,'94}}^{2}$ discusses the changes found in the air-passages and lungs in a fatal case of carbolic-acid poisoning in a girl of 20 years, who died within twenty-four hours. There was found, in addition to the changes in the alimentary canal, recent myocarditis and parenchymatous nephritis, as well as severe parenchymatous myositis. Throughout the lungs, also, the central portions of the lobules were extensively hepatized. In the larger and smaller bronchi the mucous membrane was reddened, swollen, but not dulled. There was no evidence of any corrosive action of the carbolic acid on the mucous membrane of the air-passages. It would appear as if the smallest bronchi were certainly not affected later than the larger ones, and that by extension downward the central portions of the lobules became affected. Clinically there was no reason to suppose an aspiration or deglutition broncho-pneumonia. The author does not think the time too short for the development of the pulmonary lesion, but that the morbid changes in the lungs were proportionate to those found elsewhere. A diplococcus very like Fraenkel's, and often the staphylococcus, was found in the exudation in the lungs. After referring to other cases seen by himself or others, the author expresses the opinion that the bronchitis is due to an indirect action of the carbolic acid after absorption. H. P. Loomis, of New York, $_{\text{Aug.18,'94}}^{59}$ presented specimens from a similar case, showing very well the extreme congestion and corrosion of the larynx and œsophagus. J. Johnston, of Bolton, $_{\text{Aug.22,'94}}^{22}$ treated a woman of 40 years who had swallowed, an hour before, 10 drachms (38 cubic centimetres) of crude carbolic acid. Owing to the swelling

of the mucous membranes it was impossible to administer remedies by the mouth, and nature seems to have effected a cure unaided in the space of a fortnight. The author's treatment consisted in trying to administer sweet-oil, barley-water, magnesia, and milk, and in promoting and encouraging vomiting by apomorphia, afterward keeping the patient upon milk and giving a mixture of bismuth and soda.

Carbonic Acid.—Our corresponding editor, Levison, of Copenhagen, $\frac{673}{\text{Nov.,'94}}$ gives an account of an interesting case of carbonic-acid poisoning recorded by Holst. A steamer freighted with rye had been shipwrecked on the coast of Norway, and the rye had sunk to the bottom of the sea. After some time it was pumped up, dried, and sold as fodder for cattle. Six months later the master of a small craft was employed to carry a cargo of the damaged rye, which was pumped directly from the bottom of the sea into the hold of the little vessel. The rye was much decayed, and the skipper occasionally felt faint, and was frequently obliged to go on deck to get a breath of fresh air. On board the craft was the master's son, a boy of 11 years, who was employed for two hours and a half to pump out the water from the wet rye. When he had finished this task, he was ordered to go to the cabin and make coffee. Ten or fifteen minutes later he was found there, lying dead on the floor. At the post-mortem examination all the internal organs, lung, brain, etc., were found to be overloaded with blood, and death from suffocation was diagnosed. Holst examined a portion of the rye and found it in a state of active fermentation, bubbles of air being constantly formed, which, by analysis, were shown to contain from 50 to 87 per cent. of carbonic acid, traces of ammonium sulphide and sulphuretted hydrogen, while the remainder was pure nitrogen. Experiments with white mice showed that young animals died sooner than adults when confined in a glass contaminated with carbonic acid, and that fatigued mice were much more liable to a speedy death than well-fed mice that were not fatigued. The hard labor performed by the boy, together with his youth, would therefore explain his death from the inhalations of carbonic acid, while his father and other adult persons employed in the same manner did not suffer to any extent.

Carbonic Oxide.—Brouardel $\frac{6}{\text{Mar.2,'94}}$ calls attention to the state

of stupidity resembling drunkenness caused by carbonic-oxide gas, as being liable to lead to legal errors. Either more or less amnesia may persist for some time, with defects of memory. Hallopeau [14 Dec.13,'98] has observed a convulsive tremor of the limbs in such cases, manifested exclusively at the end of expiratory movements, the rhythm of which it reproduces.

Richardière [100 Sept.5,'94] recommends inhalations of oxygen in coal-gas poisoning, and, if coma be present, traction of the tongue according to Laborde's method, with revulsives, friction, injections of ether and caffeine. Max Gordon [69 Mar.22,'94] relates three cases, two of CO and one of coal-gas poisoning, treated by the intra-venous injection of saline solution after a preliminary bleeding. It is contended that thus (1) some of the poisonous material is got rid of, (2) the circulation is maintained, and (3) the nervous centres protected. A 6-per-cent. solution was used, about 300 grammes (9½ fluidounces), at a temperature of 37° C. (98.6° F.), being injected. Spica and Menegazzi [1147 No.22,'98] suggest the use of oxygenated water, in small doses, injected subcutaneously. An investigation, undertaken by a committee of the British Medical Association, as to the efficacy of oxygen in carbonic-acid poisoning, such as occurs in the form of choke-damp asphyxia in mines, is fully detailed by one of the members, W. Ernest Thomson. [218 Nov.,'98,et seq.] It was ascertained that oxygen is of no greater service than pure air in cases of asphyxia, and the suggestion is made that a few cylinders of air, with nose and mouth-pieces, be kept ready for use in those parts of the workings where men might be most easily imprisoned. The expense of the compressed air would be much less than that of oxygen, and the effect would be equally good. It seems quite reasonable to suppose that when a suffocated person has been dragged through a long passage—itself more or less contaminated as regards its atmosphere—the chances of ultimate recovery will be greater if the effects of this poisonous atmosphere be neutralized at the commencement and during the progress of the work of rescue than if no such attempt is made until fresh air is reached in the ordinary way.

By examination of the blood to establish beyond a doubt the presence of carbon-monoxide poisoning, Wyatt Johnston [282 Oct.,'98] finds that the spectrum of carbon monoxide is practically indistinguishable from that of oxyhæmoglobin, but that, on adding

a reducing agent, the bands of oxyhæmoglobin become altered, while those of carbon monoxide persist. A freshly-prepared solution of ferro-ammonium tartrate works more rapidly than ammonium sulphide as a reducing agent. Edwin A. Down, of Hartford, [59 May 5,'94] states that blood containing carbonic oxide, after being defibrinated and properly diluted, exhibits a characteristic absorption spectrum, consisting of two absorption bands similar to those of oxyhæmoglobin, but located nearer the violet end of the spectrum; and, what is very noticeable, these bands do not disappear after the addition of reducing agents, as is the case with oxyhæmoglobin. The compound crystallizes like oxyhæmoglobin. An excess of a soda salt brightens blood containing carbonic oxide, while it darkens normal blood. The immediate cause of death in poisoning by carbonic oxide he believes to be an exhaustion of the nerve-centres, induced by the prolonged action of the gas which is present in the blood, and which is not eliminated in time to admit of resuscitation. It is an interesting fact that persons suffering from cardiac disease are more susceptible to the poison than persons not so afflicted. One of the remarkable properties possessed by carbonic oxide, the chief constituent of water-gas, is its power of resisting putrefaction in the bodies of those who have died from the effects of its inhalation. The longer the individual has been exposed to its action, the greater will be the interval between the death of the body and its commencing decomposition. This is accounted for by the fact that the carbonic oxide has formed such stable compounds with the various tissues as to retard their oxidation.

Hewetson, of Baltimore, [764 Dec.,'93] states that the direct action of CO on the tissues of the body, in cases of carbon-monoxide poisoning, can no longer be denied; and the fact that rigidity, spasms, and convulsions may persist for some time after the CO has disappeared from the blood points strongly to the implications of the nerve-centres.

In reporting three cases of recovery from asphyxia due to illuminating-gas, J. Mount-Bleyer, of New York, [71 Nov.,'93] expresses the conviction that fresh, pure air, relieved of organic matter and confined in a receiver,—like Gallibert's apparatus,—at a pressure great enough to supply the force normally exercised by the respiratory muscles in getting the air into the alveoli, is all that is

needed to stimulate the respiratory apparatus to resume its function and relieve the blood of the incubus placed upon it. Shaw, of Washington, [81 May, '94] believes that, when practicable, transfusion of blood would be the most rational measure in extreme cases, supplying at once the hæmoglobin needed by the system. In the discussion, E. L. Morgan stated that, as carbon monoxide forms a more stable compound with the blood than does oxyhæmoglobin, oxygen is of little value. Bishop and Bovee were of the same opinion, while the majority of the members favored venesection. Hoffmann [69 No. 50, '93] has employed subcutaneous injections of nitroglycerin with the best of results, injecting from $\frac{1}{120}$ to $\frac{1}{80}$ grain (0.00054 to 0.0008 gramme) every twenty minutes.

Chloral Hydrate.—Selby Plummer, of Durham, [6 Jan. 6, '94] describes the case of a boy of 16 years who swallowed at least 1 ounce (31 grammes) of this drug upon an empty stomach. He became quite unconscious, and remained so until his death, thirty-nine and a half hours later. Tracheotomy was performed at an early stage, and during the first twenty-four hours artificial respiration was necessary, in the aggregate, for twelve hours. The inhalation of oxygen was very evidently beneficial; but this could not be said of either nitroglycerin or strychnine. The rapid rise of temperature and persistent pyrexia are noteworthy in the case, as is also the frequent necessity for artificial respiration after prolonged intervals of natural respiration. The pupils remained contracted throughout.

Chloroform.—Washburn [80 Feb. 15, '94] records a case of a patient who had swallowed 2 ounces (62 grammes) of chloroform with suicidal intent, being found in the street in a condition of profound narcosis. His pupils were wildly dilated and inactive. His respiration was so shallow as to be almost imperceptible, and he had the weak, irregular pulse of a dying man; $\frac{1}{20}$ grain (0.003 gramme) of strychnine was injected hypodermatically, and artificial respiration applied, with the result that after a few minutes the whole aspect of the case changed, the respirations becoming deep and full, and the pulse also improved. After an hour another injection of $\frac{1}{60}$ grain (0.0011 gramme) of strychnine was given. Two hours after being called to the case the author was able to communicate with the patient, and to get him to confess the cause of his

condition. Recovery was complete, the patient, however, passing through a severe attack of gastritis.

Lysol.—Friedeberg $^{319}_{\text{Mar.3,'94}}$; $^{2}_{\text{Mar.24,'94}}$ refers to the non-toxic properties of lysol. Two cases of poisoning, however, have been recorded, and the author now adds a third. A 1-year-old child is said to have drunk as much as 10 grains (0.65 gramme) of lysol in solution. When admitted it was drowsy and its lips cyanosed. The uvula and pharynx were reddened; respiration, 48; pulse, 140. The stomach was washed out, masses smelling strongly of lysol being evacuated; vomiting then occurred. Magnesia was given in suspension through the tube. The child steadily improved, but a grayish-white slough appeared on the pharyngeal wall. Complete recovery subsequently took place. The case represented an intoxication of medium severity. Only a trace of lysol could have been absorbed, as there was no carbolic reaction in the urine. Drowsiness, cyanosis, and rapid cardiac action were the chief symptoms noted.

Melinite.—Gueit $^{195}_{\text{Nov.,'93}}$; $^{6}_{\text{Mar.10,'94}}$ reports an example of mixed melinite and lead poisoning. Melinite poisoning is none other than poisoning by picric acid. The lead absorbed results from the boring of the shell prior to the introduction of a special detonator. The symptoms are: loss of appetite, nausea, frequently-recurring colicky pains; a strong, bitter taste in the mouth, cough, and salivation. The bitter taste is doubtless due to the elimination of melinite by the salivary glands. The skin also secretes it, as it becomes straw-colored. The persistence of these symptoms brings about a state of malnutrition, with consequent wasting. A milk-diet (one litre and a half of boiled milk daily) was found to be an efficacious, curative, and prophylactic treatment. In one instance, however, this treatment failed. In this case there were a foul tongue, desquamative gingivitis, and alliaceous perspiration, all due to picric acid; but other troubles were ascribable to concomitant lead poisoning. They were constipation, nephritis, muscular pains, a blue line, and paralysis of the extensors.

Morphine.—Dufour, of Marseilles, $^{31}_{\text{Oct.14,'93}}$ observed a fatal case in which hæmaturia and hæmatemesis occurred,—both extremely rare symptoms in opium poisoning. A curious fact noted by Carl Johnson, of Denver, $^{9}_{\text{May 19,'94}}$ and his colleague, Wheeler, is that several fatal cases of opium poisoning have, after being unconscious

for a long time, opened their eyes, moved their hands, and shown other signs of returning consciousness, dying almost immediately afterward.

Flintermann, of Detroit, [185 Nov.,'93] records a case of recovery after the ingestion of 20 grains (1.3 grammes) of morphine and 1.8 grains (0.117 gramme) of opium; and Steiner, of Quincy, Ill., [9 June 23,'94] one of recovery after 15 grains (1 gramme) of morphia sulphate had been swallowed. In the case of a girl of 19 years, who had taken hypodermatically 12 grains (0.78 gramme), the usual treatment (atropine, galvanism, etc.) was persisted in for thirty-six hours by Percy Pope, [6 Mar.17,'94] with ultimate good results.

The experiments of William Moor, of New York, [59 Feb.17,'94] showing the efficacy of potassium permanganate as an antidote to morphine, have aroused general interest, and numerous cases are reported in which his method was tried. He points out [186 June,'94] that 1 grain (0.065 gramme) of morphine is decomposed by exactly 1 grain (0.065 gramme) of permanganate of potassium. This should be the basis of the permanganate treatment of opium-poisoning. No matter how much time has elapsed since the taking of the poison, a sufficient quantity of the antidote should be given per os (well diluted), or, if the patient is unable to swallow, the permanganate solution can easily be administered through the nose by means of a catheter, piece of rubber tubing, and a funnel. Hypodermatically, a 1 to 15 solution can be used. The *modus operandi* of hypodermatic injections of permanganate of potassium, in cases of morphine poisoning, is explained by the fact that the permanganate instantaneously selects morphine from amongst albuminous bodies. J. Barker Smith, of London, [22 Mar.7,'94] calls attention to the fact that he brought out, some ten years ago, a carefully-made 1-per-cent. permanganate-of-potash solution as an antidote to opium, morphine, and laudanum, to be used in wineglassful doses. H. C. Wood, of Philadelphia, [112 Aug.,'94] made some experiments upon animals which, combined with the evidence of Moor and others, seem to indicate that potassium permanganate given by the mouth directly after poisoning is a valuable, but not perfect, antidote to the morphine salts; an antidote, however, which should not be relied upon to the exclusion of mechanical or medicinal measures for emptying the stomach. Among those who criticize the method unfavorably, after personal experimental work, are

L. A. Harding, of Fergus Falls, Minn. $^{59}_{\text{Apr.14,'94}}$; J. M. Rector, of Jersey City $^{59}_{\text{Apr.14,'94}}$; Glenn Andrews, of Montgomery, Ala. $^{59}_{\text{Mar.10,'94}}$; and C. Monroe McGuire, of Walsenburgh, Col., $^{59}_{\text{Sept.15,'94}}$ who tried the method without success in one case, being obliged to resort to artificial respiration, atropine, and strychnia. An editorial writer $^{61}_{\text{May 19,'94}}$ deprecates the trial of the new antidote, since the treatment already in general use is efficient and, as a rule, successful; but his position in the matter is characterized as illiberal by J. S. Carpenter, of Pottsville, Pa., $^{9}_{\text{June 22,'94}}$ who regards it as scarcely a debatable question whether humanity is ever poorer for the discovery of any new method, even if it benefit only a few. In a case of his own the established and, "as a rule, successful" treatment for morphine poisoning was instituted with energy, but without effect, and it was only by the use of permanganate of potassium that the patient's life was saved. The method was successfully employed in two cases by A. Erskine, of Memphis, $^{74}_{\text{June,'94}}$ and in four cases by W. L. Pyle, of Washington $^{9}_{\text{May 12,'94}}$; while C. W. Ladd, of Cannelton, Ind. $^{1163}_{\text{Sept.,'94}}$; J. S. Buist, of Charleston $^{186}_{\text{Apr.,'94}}$; H. D. Walker, of Franklinville, N. Y. $^{9}_{\text{Apr.7,'94}}$; E. R. Gregg and G. B. Moreland, of Pittsburgh $^{9}_{\text{May 5,'94}}$; C. E. Johnston, of Atlanta $^{9}_{\text{July 28,'94}}$; J. S. Martin, of Massey, Texas $^{85}_{\text{July,'94}}$; J. L. Gardner, of Groton, Conn. $^{814}_{\text{July 1,'94}}$; J. C. Crossland, of Zanesville, Ohio $^{233}_{\text{Aug.7,'94}}$; C. H. Callender, of New Boston, Mass. $^{59}_{\text{Sept.15,'94}}$; and J. J. Darby, of Americus, Ga., $^{207}_{\text{Sept.,'94}}$—each report a case of recovery following its employment.

C. H. Wilkenson, of Galveston, $^{198}_{\text{Nov.,'93}}$ saved a case by means of artificial respiration. Cruse $^{158}_{\text{B.16,H.2,3}}$ gave ¼ grain (0.015 gramme) of atropine twice, at an interval of half an hour, recovery occurring in thirty-six hours. Ranade, of Sholapur, India, $^{239}_{\text{Dec.1,'93}}$ also finds atropine to work like a charm. H. T. Penny, of Sand Coulee, Montana, $^{820}_{\text{Nov.,'93}}$ in severe cases urges the stimulation of the phrenic nerve by the faradic current, one pole being placed at the side of the neck, and the other over the diaphragm. This can be kept up for hours without danger. Johnson, of Denver, $^{9}_{\text{May 19,'94}}$ relies largely on strychnine sulphate in treatment, giving $\frac{1}{25}$ grain (0.0026 gramme) hypodermatically, repeating this dose in extreme cases every ten or fifteen minutes, until there is twitching of the muscles or the breathing becomes spasmodic. Campbell, of Perth, $^{6}_{\text{Mar.24,'94}}$ used a few teaspoonfuls of common essence of coffee mixed with water, with excellent effect. Ashburn, of Phila-

delphia, $_{July\ 28,'94}^{9}$ reports two cases in which oxygen was markedly beneficial; and Merry, of London, $_{June\ 2,'94}^{6}$ was able, by its timely use, to save a man who had swallowed 2 ounces (62 grammes) of chlorodyne, containing about 8 grains (0.52 gramme) of morphia.

Nitrobenzol.—Max Bondi, $_{Nov.11,12,'94}^{88}$ in connection with a case of poisoning by nitrobenzol in von Jaksch's clinic at Prague, carefully considers the condition of necrosis observed in such cases. Eugen Cissel, of Vienna, $_{June\ 16,'94}^{6}$ describes the case of a woman who had taken 100 grammes (nearly 3½ ounces), of this substance, and who was admitted to hospital in a highly-cyanotic condition, with small pulse, superficial respiration, and dribbling of urine, which contained nitrobenzol. Artificial respiration and camphor injections restored consciousness and the patient recovered. On the fourth day the urine resembled that of a case of cystitis. B. Graselli and F. Giaroli $_{No.14,'94}^{505}$ saved a case by washing out the stomach and excitation.

Phosphorus.—The disordered metabolism produced by acute phosphorus poisoning gives rise to certain alterations in the composition of the urine, especially as regards the excretion of nitrogen. Many observers have found that there is a much larger proportion of nitrogen than in the normal condition, and the question arises: Is the excess of ammonia the result of an attempt on the part of the system to reduce the abnormal acidity of the tissues and the blood, or is it due to an imperfect synthesis of urea? The frequency with which, in Austria, the heads of lucifer matches are swallowed for the purpose of committing suicide enabled Münzer $_{B.52,H.3,4;\ June,'94}^{326\ \ 90}$ to very fully investigate, as to changes in metabolism, no less than fifteen cases of acute phosphorus poisoning. He found that during the first two or three days after the poison is swallowed there is a marked diminution in the total amount of nitrogen present in the urine, which he attributes not to the specific action of the phosphorus, but to the persistent vomiting and consequent state of starvation. On the second or third day after the poison is taken a marked increase in the excretion of nitrogen takes place, attributable to excessive destruction of tissue-proteids caused by the phosphorus. Usually death quickly occurs as soon as the amount of nitrogen has become very great; but in many cases there is a diminution both of nitrogen and of the quantity of urine excreted during the last hours of life. As regards the

percentage of urea, if it is below 85 to 90 per cent. of the total amount of nitrogen excreted, disease of the liver, of such a kind as to interfere with its urea-forming function, is thereby indicated, the absent urea being replaced by excess of ammonia, which ought to have been converted into urea. But in some of the cases observed by Münzer the quantity of urea excreted, after having been reduced very low, was subsequently increased threefold, although the condition of the liver was progressively becoming worse. The view taken is that the excess of ammonia is solely due to development of acid products in the tissues, caused by the toxic action of the phosphorus, and not to arrest of the urea-forming function of the liver. In support of this view it is stated that the administration of alkalies by the mouth, to a patient suffering from acute phosphorus poisoning, materially lessened the amount of ammonia excreted in the urine. The alkali partaken of tended to neutralize the excess of acid in the tissues, and thus to diminish their need for ammonia, and consequently to diminish the amount of ammonia salts in the urine. In addition to the increase in ammonia there is excess of uric acid excreted in cases of acute phosphorus poisoning during the stage of rapid proteid metabolism, and also of nitrogenous extractives. Münzer failed, with one exception, to find peptones in the urine; other observers have frequently obtained evidence of their presence or of some body which yielded the same reactions. The chlorides of the urine are rapidly diminished after the acute toxic effects of phosphorus develop. The excretion of phosphoric acid is increased during the first few days; afterward it progressively diminishes until death. Münzer attributes the increase of phosphoric acid to rapid splitting up of phosphorus-containing metabolic products, and not to oxidation of the swallowed phosphorus, or at least only to an inappreciable degree. The excretion of sulphuric acid, upon the whole, runs the same course as that of phosphoric acid; ether sulphates are increased. No fatty acids—tyrosin, leucin—nor sarcolactic acid were found, nor any diamines. Chemical analysis of the brain-substance showed an increased percentage, and of the liver a decreased percentage, of phosphoric acid.

Lo Monaco and Trambusti, $\frac{376}{p\,26,'94}$ having observed that frogs, after receiving small poisonous doses of phosphorus, increased in weight and died early if allowed to remain in the presence of

moisture, but diminished in weight and lived longer if kept dry, made a number of experiments with a view of ascertaining the cause of this difference. Frogs were taken, and each, after being carefully weighed, had a small dose of phosphorized oil injected into its dorsal lymph-sac; it was then placed on a plate and covered over with a glass funnel. Some of plates were kept dry, others had some water poured on to them. Every twenty-four hours the frogs were weighed. The results showed that the frogs kept dry lived longer than those surrounded by moisture, and that they progressively diminished in weight, whereas those surrounded by moisture increased in weight. An analogous series of experiments was made with dogs, some of which were kept without food and water; others were kept without food, but were allowed 250 cubic centimetres (8 fluidounces) of water daily. Each dog received daily a small dose of phosphorized oil injected subcutaneously. Under the first-named condition the animals progressively lost in weight and died in from six to eight days, receiving in one case 2.03 cubic centimetres (31½ minims) phosphorized oil per kilo (2⅕ pounds), and in the other 3.11 (47¾ minims). The animals supplied with water lost less weight and died on the fourth day, after receiving in one case only 1.26 cubic centimetres (19½ minims) per kilo (2⅕ pounds), and in the other 1.62 (25 minims). Microscopical examination of the organs after death showed that both in the dogs and in the frogs fatty changes had taken place, but that the changes were more advanced in those of the animals which had imbibed water. It is well known that when dogs kept without food are allowed to drink water the elimination of nitrogen is increased. One explanation of this is that the water simply washes the tissues out, and so brings away the urea already formed: the other explanation attributes an increased formation of urea to the water. In favor of the latter hypothesis is the fact that when water is given to fasting animals the elimination of sulphur compounds is increased, which is supposed to be due to greater consumption of the albuminoids. The introduction of water into the system favors the interchange of materials, and thus helps to augment cellular metabolism. The toxic action of phosphorus is to hasten decomposition of the albuminoids and to give rise to vastly-increased fat-formation; by promoting molecular interchange in the albuminoids water intensifies the action of the phos-

phorus, and thus augments the formation of fat. This is probably the chief way in which water helps to form fat, but it is not to be denied that in itself it may possess some chemical activity in this direction. The authors favor the view that in acute phosphorus poisoning death is probably due to the toxic action of certain products of cellular metabolism, which the liver and kidneys are unable to eliminate on account of the profound changes that have taken place in them.

Gurrieri $_{\text{v.19,p.415,'98}}^{591}$; $_{\text{Mar.17,'94}}^{2}$ made researches into the minute histology of the organs and spinal cord of a dog gradually poisoned with phosphorus. The sections were, for the most part, stained in either osmic acid or with Vassale's hæmatoxylin, the formula for which is for the first time published by him: Hæmatoxylin and orange, of each 0.20 gramme (3 grains); 10-per-cent. chrome-alum solution, 50 cubic centimetres (1½ fluidounces); 2-per-cent. arsenious-acid solution, 50 cubic centimetres (1½ fluidounces). The liquid should be at least two months old, and gives results far exceeding those obtainable with other formulæ. The author's actual observations were as follow: Stomach: nuclei of gastric glands stain badly, cell-protoplasm fatty. Pancreas: nuclei stain badly, cell-bodies often fatty. Liver: general fatty degeneration, nuclei will not stain, degeneration least advanced toward the centres of the acini. Heart: fatty degeneration of many fibres, general loss of striæ. Kidneys: granular and fatty degeneration of epithelium of the convoluted tubules, and especially of Henle's loops. Epithelium lining Bowman's capsules does not stain. Frequently there were masses of granular *débris* between the capsule and the capillary tufts. The other organs were normal. In sections of the cord, hardened with Müller's fluid, the crossed pyramidal fasciculi appeared less colored by the liquid than in the normal cord along the whole of their course. Commencing at the lower third of the dorsal region, there was also evident degeneration in the columns of Goll and Burdach. The degenerations were confirmed on microscopical examination. The author calls attention, however, to the fact that the degenerated tracts did not take on the characteristic coloration of degenerated nerve-fibres with osmic acid. He points out that this difference serves to distinguish primary slow degenerations resulting from the gradual action of a poison from secondary rapid degenerations the result of central mischief,

these latter staining well with osmic acid. The difference thus observed may be of importance in medico-legal examinations.

E. Harnack [4 No.17,'93] believes that the substance resembling peptone observed in the urine of dogs poisoned with phosphorus is not completely identical with peptone, but is properly a result of the separation of albumin due to fatty degeneration of the cellular protoplasm. Corin and Ansiaux [311 Jan.,Apr.,'94] find that fluidity of the blood is found only in cases of phosphorus poisoning which have followed a subacute course; the plasma after sedimentation of the hæmatins then contains no fibrinogen or substance coagulable at 57° C. (134.6° F.).

The pathological conditions in phosphorus poisoning are studied at length by Warfvinge, [373 v.10,p.1272] and an interesting case is reported by Seydel [311 Oct.,'93] of a woman who swallowed match-heads for the purpose of procuring abortion. Six days later spontaneous delivery of two dead fœtuses occurred, and the woman died during the artificial delivery of the placenta. In two cases of a similar nature observed by Parisot, of Nancy, [184 Mar.,'94] one of which was fatal, treatment had no influence on the termination.

Freyhan [69 Jan.18,'94; 6 Jan.27] describes the curious case of a young man, a performer at fairs, who was in the habit of exhibiting the strength of his digestion by eating shavings, glass, leather, soap, coals, blacking, etc., and added matches to this already sufficiently miscellaneous list, selecting those tipped with phosphorus. For a time, in consequence of the small number taken, he suffered no inconvenience, but, business becoming brisk in this department, he had occasion to give twenty to thirty performances daily, and in a little more than a week symptoms of phosphorus poisoning occurred, which ended fatally.

In a case of match-head poisoning treated by S. T. Beard, of Masterton, New Zealand, [557 Jan.,'94] the satisfactory termination was attributed to a strict non-fatty diet and perseverance in large doses of turpentine. Adolf Kelemen [622 No.3,'94] cured one case by giving 2 quarts (litres) of a 1-per-cent. solution of permanganate of potassium, the patient drinking a glassful every three or four minutes.

Prussic Acid.—Contrary to the assertions of Geppert, that this substance acts directly upon the tissues, the symptoms being due to arrest of oxidation, G. Corin and G. Ansiaux, [52 Dec.20,'93; 673 Mar.,'94] of Liége, find that the acid exercises no influence upon the organic

tissues, but that it is a typical bulbar poison, and that any arrest in oxidation is due to its intense action upon the central nervous system. The symptoms observed by them in experiments upon animals were identical with all those produced by bulbar poisons.

Experiments with dogs have shown Kóssa [1130 B.2.H.1,'92; 9 July 7,'94] that animals to which were administered toxic doses of potassium cyanide could be saved by the immediate administration of potassium permanganate; in one instance even a dose ten times the lethal one failed, under these conditions, to induce toxic effects. An animal that received a dose twenty times as large as the lethal dose, and afterward potassium permanganate, lived for a longer period of time than one given an ordinary lethal dose alone. If toxic doses of the cyanide were mixed with potassium permanganate, and the mixture permitted to stand for a few hours, no bad results followed its administration. The cyanide, under the influence of the permanganate, is converted into an hydrocarbonate, then into a carbonate, and finally into urea. Johann Antal [6 June 16,'94] claims nitrate of cobalt to be a most efficacious antidote in cases of poisoning by cyanide of potassium or by prussic acid. The antidote is stated to have been first tried upon animals and afterward upon forty living persons who had been accidentally poisoned with prussic acid, and it is said that in not a single case did the antidote fail. We fear there is but little chance of this discovery being of much service, since cases of poisoning by prussic acid usually run a very rapid course.

Stramonium.—Two cases of poisoning by the common thorn-apple are recorded,—one by C. O. Maisch, of New York, [59 Oct.21,'93] in a woman who took a small quantity of infusion of dried leaves, and the other by Streit, of Teufenthal, [214 Jan.15,'94] in a lad of 8 years, who ate a handful of the fresh seeds. In the latter case the first measures consisted in the administration of a good dose of ipecacuanha, castor-oil with croton-oil, a glycerin enema, and cold affusions. About sixty datura-seeds were found in the vomited matter, but none could be detected in the stools (passing four hours afterward). Notwithstanding the treatment, all the symptoms persisted unabated for twelve hours, which induced the author to resort ultimately to morphine in 0.01-gramme ($\frac{1}{6}$ grain) doses. After four doses (one of which was administered hypodermatically, the others internally) the delirium and cramps began slowly, but steadily, to subside,

disappearing completely next evening. The author points out that his case illustrates the fact of daturine being very different from atropine with regard to biological effects, since in his patient the pulse was strong and full, the secretion of saliva and mucus remained intact, and there were present typical opisthotonos and tonic convulsions with predominating cramps of extensors.

Strychnine.—Allerton S. Cushman $_{V.6,No.17,'94}^{2093}$ finds that the greatest difficulty which presents itself in the post-mortem detection of strychnine is the separation of the alkaloids from the various extractive, fatty, sugary, and pigmentary matters derived from the stomach-contents or organs under examination. The danger of error has also been noted from the formation of cadaveric alkaloids or ptomaines in decomposed bodies, which may in some of their reactions simulate those of strychnine. While this is probably true, it is not likely that any alkaloidal substance other than strychnine itself could be mistaken for it, if all possible tests—chemical, physiological, and morphological—be tried. It is important that the quantity of strychnine should also be determined, and a method of analysis is presented by which it is believed that 84 per cent. of the strychnine present in complex organic mixtures can be recovered.

The points of interest in a fatal case of strychnine poisoning reported by Percy T. Adams $_{Feb.15,'94}^{2}$ are: 1. Quantity of drug taken, —13½ to 18 grains (0.87 to 1.17 grammes) in the readily assimilable form of liq. strychninæ, B. P. 2. Relatively slow speed (namely, fifteen to twenty minutes) at which so large a dose killed when taken upon an empty stomach, for the man drank it directly out of the bottle before breakfast. 3. This solution had been kept, often exposed to light, for probably six years, but was apparently unaltered as regards its potency. The infarction in the left kidney is interesting, as is also the faintly "cold tone" of the cerebral tissues, as perhaps it may throw some indication upon the action of the drug on the cerebro-spinal nerve-centre, and possibly also the corresponding vasomotor sympathetic nerves. For if such violent stimulation of the vasomotor centres take place (as appears certain regarding the cerebro-spinal nerves), the arterial walls would become contracted, and their calibre so constricted as to cause this excessive pallor of the cerebral tissues, and the bluish tint from the color of retained venous blood. This might also

explain the hæmorrhage into the kidney; the vessels in and around the Malpighian tufts and capsules, by reason of their engorged condition (naturally) and their resistance in becoming rapidly emptied, when subjected to sudden tonic contraction of their walls, together with the tortuosity of their finer capillaries in the glomeruli, appearing to be most liable to rupture when such extraordinary *vis a tergo* and sudden lateral pressure are suddenly brought to bear upon their practically incompressible contents.

J. Augustin and P. Flor [660 Nos.11,12,'94] report the second case of suicide by strychnine recorded in Roumanian literature, the patient swallowing a pill containing 0.10 gramme (1¾ grains) of the drug. Apomorphine, cutaneous frictions, cold douches, chloral hydrate, and bromide of potassium brought about recovery. Perry, of Birmingham, [32 May, '94] reports a fatal case, death occurring in spite of vigorous treatment. Acute nephritis and ascending motor paralysis were noted during the four days which he survived. Grigorescu finds, [410 No.1,'94] by experiments on frogs, that butyl-chloral is a physiological antidote of strychnine. Lazzaro [1147 v.10,p.295] advocates inhalations of chloroform and chloral or paraldehyde by the mouth or rectum. Fleming, of St. Arnaud, Australia, [285 Oct.15,'93] reports one fatal case, and another in which bromide of potassium and chloral hydrate successfully combated the ingestion of 10 grains (0.65 gramme), the patient aborting a week later.

(See article on "General Therapeutics," vol. v, A, for poisoning from drugs used medicinally).

MEDICAL DEMOGRAPHY.

By F. LEVISON, M.D.,
COPENHAGEN.

POPULATION AND DEPOPULATION.

France.—The decrease of the population of France continued through the year 1892, although at a somewhat slower rate. The official report for that year [153 Mar.5,'94] gives the following result:—

	1892.	1891.	Increase.	Decrease.
Marriages	290,319	285,458	4,861	
Divorces	5,772	5,752	20	
Births	855,847	866,377	. . .	10,530
Deaths	875,888	876,882	. . .	994

Foreigners living in France have, with the exception of the English, shown a surplus of births over deaths, the excess being 7617.

Legrain, [22 June 13,'94] chief physician of a Paris asylum, maintains that, among the many causes of depopulation in France through mortality, alcoholism is of great importance. Hitherto France was considered a sober nation, but this is not now the case, as, in 1892, 1,735,369 hectolitres, or nearly 40,000,000 gallons, of alcohol were consumed. The author, in order to show clearly the effect of this vast consumption of spirits, has collected statistics of 215 alcoholic families, represented by 819 descendants, with the following results: 37 premature births; 16 still-born; 121 premature deaths (generally convulsions); 38 cases of physical debility; 55 cases of tuberculosis; 145 cases of mental derangement. In all, 412. The remainder comprised a large number of epileptics, hysterics, idiots, etc.

Lagneau [996 Dec.8,'93] furnishes information to the effect that the enormous mortality in Paris among newborn children is largely due to the custom of putting infants out to nurse, and that the increase of the population of Paris is caused only by immigration.

The Paris-born people keep to themselves and only excep-

tionally intermarry with immigrants; and it is the rule that these families become extinct in three, four, or, at most, five generations.

Dumont, [996 Jan.10,'94] Chervin, [14 Aug.22,'94] and Jeannel [1088 Apr.1,'94] have studied the movement of population in the different departments of France, and have found that almost everywhere the natality, and with it the population, is decreasing. The statistics of Marseilles [46 Sept.15,'94] show that the hygienic conditions of that city are constantly improving. In the year 1884 the mortality was 33.9 per 1000, but in 1892 and 1893 it had diminished to 27.9 and 28.9 per 1000 inhabitants.

Fleury [33 Oct.,'93] presented a paper to the International Health Exposition at Chicago concerning a new method of calculating the mortality of infants put out to nurse, with regard to their age, sex, method of nursing, etc., by which a thorough knowledge of the cause of the great mortality can be gained, and thus, he hopes, a remedy for the condition be found.

England.—Fosbroke [2 July 28,'94] insists on the fact that the crude death-rate reports in England cannot be used without great precaution, and that it is necessary to consider them both individually and collectively, as well as to weigh various other points, before drawing inferences as to the state of local sanitation. A special difficulty encountered in inquiring into the influence of sanitary conditions upon the death-rate is that the actual enumeration of the population is made only once in ten years. He therefore proposes that a quinquennial census be taken, such as is already introduced in other countries. The author notes the fact that deaths from cancer seem to have increased materially during the last twenty years, the statistical tables appearing to prove that cancer is more prevalent in water-logged soil than in high-lying districts. Power [2 June 9,'94] has also observed that cancer frequently appears repeatedly in certain houses.

Corfield [2 Aug.11,'94] states that the year 1893 was very hot and dry in England, and during it the death-rate of the thirty-three largest towns of England was 21.6 per 1000,—a little higher than the average of the previous ten years. The death-rate of London shows a still greater increase, being from an average of 20.4 to 21.3, or nearly 1 per 1000 higher than during the last ten years.

Diphtheria caused more than double the average number of deaths as compared with previous years, and the death-rate from

diarrhœa increased 43 per cent.; while, on the other hand, the death-rate from measles, scarlet fever, and whooping-cough diminished. Although the death-rate has been augmented, the natural increase of the population in the United Kingdom by excess of births over deaths exceeded 400,000, of which no less than 345,000 occurred in England and Wales. [6 Aug. 7, '94]

Italy.—In Italy [429 No. 44, '94] the natality for 1891 was 37.31 per 1000 inhabitants, as against 35.91 per 1000 in 1890, and the mortality amounted to 26.21 per 1000 as against 26.39 per 1000 in 1890, the excess of births over deaths being 336,812, or 11 per 1000.

Germany.—Wernich and Wehmer [2051] state that the natality in Berlin has been decreasing since 1881. In 1889 it was 39.01 per 1000 inhabitants, in 1890 it was 31.37, while in 1891 it increased to 32.10. The mortality in 1889 was 22.56, in 1890 21.21, and in 1891 20.85 per 1000. Phthisis pulmonalis caused about 13.41 per cent. of all deaths, and diphtheria 2.58 per cent., as against 4.47 per cent. in 1890. In Hamburg [2052] the year 1892 showed an extraordinarily great mortality, reaching 39.8 per 1000 inhabitants; this was due to the epidemic of cholera, which attacked 16,956 persons and caused 8605 deaths.

General.—The sanitary conditions of a series of the larger towns of Europe and America in 1893 are shown by the following table [2053; 2054]:—

Towns.	Per 1000 Inhabitants. Births.	Deaths.	Towns.	Per 1000 Inhabitants. Births.	Deaths.
Gottenborg,	31.5	16.1	Antwerp,	33.0	19.90
Christiania,	16.8	18.0	Amsterdam,	35.8	20.20
Malmoë,	30.1	18.1	New York,	27.1	23.40
Copenhagen,	29.9	20.3	Chicago,	—	18.95
Hamburg,	36.7	20.4	Philadelphia,	—	21.93
London,	30.9	20.8	Brooklyn,	—	21.81
Berlin,	27.4	20.8	St. Louis,	—	18.47
Paris,	25.2	21.8	Boston,	—	23.88
Rome,	26.7	22.7	Baltimore,	—	21.10
Vienna,	33.1	23.5	San Francisco,	—	18.21
Rotterdam,	30.1	23.8	Cincinnati,	—	19.67
Danzig,	32.6	26.3	Cleveland,	—	18.19
Munich,	35.8	26.4	Buffalo,	—	16.28
Budapest,	36.1	26.7	Pittsburgh,	—	22.92
Dublin,	28.5	26.9	New Orleans,	—	28.72
Triest,	32.0	27.9	Milwaukee,	—	16.00
Stettin,	37.6	28.6	Louisville,	—	14.80
St. Petersburg,	31.6	30.6	Minneapolis,	—	9.60
Stockholm,	28.3	19.1	St. Paul,	—	9.61
Brussels,	25.9	19.8	Denver,	—	11.61
Edinburgh,	28.0	19.8	Rochester,	—	17.87

The death-rates of the American towns are calculated from the statistical reports of the first six months of 1893, while they are registered for the whole year for European towns.

India.—Barnes [2] Mar. 3, '94 has drawn up a general report of the census of India, taken in February, 1891, and including almost the whole of the British Empire in that country. The population amounted to 287,223,431, which is spread over an area of 1,560,-160 square miles. The inhabitants of Hindostan constitute about one-fifth of the population of the world, located in an area covering about 3 per cent. of the estimated land-surface of the globe. The census of 1891 revealed a gain of some 28 millions of population over that of 1881, or 10.96 per cent.; this gain is almost entirely due to the large birth-rate, which is estimated at 48 per 1000, while the death-rate was 41 per 1000. The average duration of life in India is 24 years, against nearly 44 years in England. There are some one hundred and fifty languages spoken in India, of which 75 per cent. belong to the Indo-Aryan type, 20 per cent. to the Dravidian type, or language of the aboriginal tribes, and the remaining 5 per cent. to all others. English is represented by 9 in 10,000. Brahminism is the faith of 72.3 per cent. of the population, 20 per cent. profess the Mohammedan faith, 3.2 are worshippers of spirits, 2.5 are Buddhists, and Christianity is acknowledged by 8 per 1000 of the population.

Occupation and Mortality.—Osborn [2] May 19, '94 reports the fact that phthisis has become alarmingly prevalent in the English flax-mills and linen-factories. In Belfast, for example, it was accountable in 1891 for 241 out of 528 deaths which took place among the artisans of all trades, and, if other diseases of the respiratory organs be taken into account, only 173 deaths remain attributable to other causes.

George Reid [6] Apr. 7, '94 has noted a relation between the infant death-rate and the occupation of the mother. In certain manufacturing centres of England where no women were employed in factory labor the infant death-rate was 152, where some women were so employed it was 166, and in others, where female labor was much in demand, it reached 195.

Newholme [2] Feb. 3, '94 also calls attention to the relations of consumption to in-door occupation, especially when involving the inhalation of irritating dust. Occupations inducing the abuse of

alcohol are particularly unhealthy, the death-rate among publicans between 20 and 45 years of age being about four times as high as among clergymen of the same age.

Marriage, Fecundity, etc.—Körösi [31 Mar.13,'94] has made a calculation of the fecundity of the two sexes at different ages, as shown by the statistics of Budapest. A man at the age of 30 years has, in marriage with a woman of 20 years, a chance of paternity of 31 per 100; in marriage with a woman of 30 years, 20 per 100. When the husband is 40 years of age, his chances of offspring are 27 per 100 with a woman 35 years old; when the wife is 40 years old, only of 17 per 100; and, when she has reached 45 years, of 2½ per 100. For each period of life there exists two kinds of fecundity,—physiological, or virtual, and positive, or real, fecundity. The first depends only on the physiological sexual functions, and is alone in vigor in newly-married couples; the second—real fecundity—depends on the physiological functions controlled by views of prudence and circumspection. After the birth of the first child the fecundity decreases in a very manifest manner. In mothers 30 to 35 years old the decrease is 78 per cent. When the woman is 43 years old 98 per cent. of fecundity is lost after the birth of the first child. The reduction of fecundity in man is also manifest, but not so great as in woman.

It is not only in France and other countries of the Old World that the decline of maternity attracts the attention of physicians and statisticians. Powell [147 June,'94] asserts that in the United States maternity is rapidly decreasing. The natural increase of population has decreased from 28.2 per cent. from 1831 to 1840 to 22.78 per cent. from 1871 to 1880, while during the ten years from 1860 to 1870 the natural increase was only a little over 15 per cent., showing a decline during that period of nearly 13 per cent. (The War of the Rebellion, however, was an important factor in this falling off.) In the United States, in 1880, the average number of children to each family, including all under 21 years of age, was only 2.51. In the opinion of the author this result is due to a rather general adoption of the Malthusian doctrine, in connection with the increasing prevalence of fœticide.

Damanion [186 May,'94] maintains that, although the Mohammedan people are permitted by their religion to marry with their near

relations,—cousins, cousins-german, etc.,—generally in one family and often in the same house, still their offspring is strong when there is not a taint of disease in one or both parties.

Degeneration and Atavism.—Shuttleworth $_{\text{Sept.8,'94}}^{2}$ and Fletcher Beach $_{\text{Sept.8,'94}}^{2}$ comment on Warner's report on the mental and physical condition of English school-children. Of 50,000 children (26,287 boys and 23,713 girls) seen in schools, from 1892 to 1894, 8941 were noted, of whom 5112 were boys and 3829 girls; 103 abnormal points or signs were noted, which were afterward classed under (1) defects of development; (2) abnormal nerve signs; (3) low nutrition; (4) mental dullness; (5) defects of eyes; (6) cases of rickets; (7) exceptional children.

Defects of development were observed in 3926 cases, and among these were 1328 children with defective crania,—either too large or too small, asymmetrical, dolichocephalic, or hydrocephalic. The large head may be due to abnormal development of the brain. In 8 cases of imbecile children the brain was weighed and found to exceed the average normal weight for the age of the child.

Defective ears were observed in 474 cases and defective palates in 820 cases. An arched or vaulted palate is often found in cases of idiocy and imbecility.

Asymmetry, especially of the face, was observed in 610 cases; abnormal nerve sign in 4868 cases (2853 boys and 2015 girls). Altogether there were 3774 children mentally dull and 1489 presented defects of the eyes.

Deane $_{\text{Jan.,'94}}^{77}$ reports a case of atavism, or, rather, degeneration involving three generations, the members of which are carefully described, and in all of whom there were manifest and increasing symptoms of degeneration, with only one exception, and that a doubtful one.

Morgan, $_{\text{Nov.4,'93}}^{61}$ Andrews, $_{\text{Oct.21,'93}}^{61}$ and other authors discuss the interesting question, "Are the American Women Physically Degenerating?" The answer, however, cannot yet be said to be conclusive.

ANTHROPOLOGY AND ETHNOLOGY.

Theo. Duke $_{\text{Sept.8,'94}}^{6}$ delivered an address at the Congress of Budapest, on tropical and especially Indian medicine, and insisted on the fact that typhoid fever in India attacks the European more frequently than the colored races, although cases may occasionally

occur among the latter, as shown by the following report of 1892, which contains a comparison of the admissions and death-rate per 1000 from typhoid fever among the European troops, native troops, and prisoners in jails in India.

	1882–91.		1892.	
	Admissions.	Deaths.	Admissions.	Deaths.
European troops . . .	14.7	4.18	22.1	5.52
Native troops	0.3	0.09	0.4	0.13
Jail population	0.2	0.10	0.3	0.15

Neither the Hindoo, who, as a vegetarian, eschews meat, nor the Mohammedan, who does not drink alcohol, is much exposed to typhoid fever; but when cases do occur they ordinarily take place among the Goorkas, the military and dominant race of Nepaul, who live on very much the same food as Europeans, drink alcoholic beverages, and eat meat.

Navarre [211 Oct.8,'94] maintains that Europeans have never succeeded in becoming acclimated in tropical regions; the exceptions which have been mentioned as "*les petits blancs*" in Guadaloupe and Réunion are only able to live in the more elevated portion of the island, where the climate is not so hot; neither can the white men in the Spanish Antilles do hard work, being forced to employ colored or black workmen. They are, moreover, a very small minority of the population, and most of those who boast of being pure Spaniards are but half-blooded.

Ripoli [1016 Aug.8,'94] presents a carefully-elaborated communication concerning the meteorological conditions of the province of Entre-Rio, in the State of Argentina, from which it appears that the climate is temperate and well adapted to the acclimation of Europeans. Zaborowski [208 Nov.,'93] has studied the distribution of the cultivated plants in Africa, and finds that only a small portion of those which are now in common use among the different negro tribes are autochthonous in Africa, but that most of them have been introduced relatively late, either from America or from Asia, and especially from India. As examples of the first he mentions the earth-nut, maize, tobacco, etc.; while from the East have been introduced millet, buckwheat, etc. The negroes have learned the culture of these either from foreigners or from slaves who, after liberation or escape, have returned to their tribes. In this way the slave-traffic has been a means of civilization in Africa. In many parts of central

Africa only the Arabians, who settle there to traffic in slaves, cultivate wheat, which is not yet in use among the indigenous tribes, although the soil and climate are well adapted to its culture.

Cunningham [9 Feb.2,'94] states that, among negro and mulatto convicts in Georgia prisons, the mortality is nearly three times greater than among the white convicts, this large death-rate being especially due to thoracic diseases, and most of all to tuberculosis. Ball [9 Apr.7,'94] mentions the same facts as regards the negro prisoners in the Eastern Penitentiary of Pennsylvania, where four times as many colored adults are subject to pulmonary tuberculosis as whites.

Regnault [31 June 23,'94] writes that the habit of carrying children on the left arm is not general among half-civilized nations and savages, where the women are obliged to work in the fields. The French peasants leave their children in the cradle, and, if necessary, tie them in; this is also the custom in Armenia, Morocco, and Tartary. In Russia and among the Ostiaks the baby is put into a light willow-basket, which is carried on the back and held firmly by means of straps. Among the negroes the child is carried directly on the back and held firmly in place by means of a piece of cloth, which is fastened in front of the mother's chest. This is also a common practice among the Japanese. Among other nations the hip, usually the left one, supports the child's feet, and in some cases a band holds the infant in place.

Martin [208 May 24,'94] states that the "couvade," the singular custom in which, after the birth of a child, the father takes to bed and nurses the child while the mother goes to work, is in common practice among a people living in the mountains of Kouitchon, near the province of Yunnan.

Risley [9 Sept.1,'94] found, by examination of the form of the nose among the natives of northern India, that the proportion of the greatest width to the length, from above downward, or what is called the nasal index (not to be confounded with Broca's nasal index defined upon the skull), furnishes a sort of racial test. Not only are the Dravidian tribes of India separated from the Aryan by this test alone, but the close correspondence of racial types indicated by the nasal index is even more striking. If we take a series of castes in northern India and arrange them according to their nasal index, so that the caste with the finest nose is at the top and that

with the coarsest at the bottom of the list, this order will substantially correspond with the accepted order of racial procedure. The casteless tribes occupy the lowest place in both systems; the fisher castes are a trifle higher; the pastoral, or cultivating, castes follow in due order; and from them we pass, in both systems, to the upper classes of Hindoo society.

Regnault [14 Dec. 12, '95] has measured the teeth in various races, and found that in the negro the incisors are triangular, in the white man quadrangular. The difference between the breadth of the free edge of the incisor and of its neck is 1.27 millimetres in the Hindoo, 2.0 millimetres in the Australian, 2.39 millimetres in the negro, and 3.04 millimetres in the higher apes. As in the apes, the canines of the inferior races are very pointed, while the body of the teeth is larger than in the higher races.

Siren Hansen [374 May 15, '94] has communicated a very interesting paper on trepanation in prehistoric times and as a treatment in popular medicine in our own days. When Broca first drew attention to the fact that traces of trepanation were often found in crania from prehistoric times, he believed that the operation had generally been performed on children in order to relieve internal diseases, especially epilepsy, and that the individuals having survived this operation were considered as being in possession of mystical qualities, and therefore, after their death, round pieces were cut out of their crania and used as amulets. Hansen, on the contrary, maintains that the operation was commonly performed on adults and had been employed in quite a rational manner in the treatment of wounds and fractures of the skull; nevertheless, the skulls bear evidence that the patients very rarely survived the operation, even for a short time, as no signs of reparation or suppuration can be seen where the piece has been cut out. The author refers to some crania found in Bohemia, France, etc., but gives a more detailed description of specimens found in Denmark or preserved in the museums of the country. In one skull, found by Varpeleo in Denmark, evident signs exist of a wound made by a sword or similar sharp weapon. The wound was partially cut through the bone and extends on the left side from the coronal suture to the orbit. From the upper side of this wound a fracture extends, at an obtuse angle, two inches downward, backward in the parietal bone. Another fracture is seen going from the lowest part of the

wound backward through the temporal portion of the frontal bone. A portion of bone is in this way circumscribed and partially loosened, and the upper part removed by a cut with a saw, so that a triangular hole is found in the skull. That the cut was made with a saw is proved by the fact that a furrow is seen extending beyond it and also below it, showing where the saw must have slipped. The patient could not have survived the operation, as neither in the circumference of the hole nor elsewhere are there traces of suppuration. Similar evidences of trepanation can be seen on several skulls found in prehistoric sepulchres in Denmark.

Among half-civilized or uncivilized races trepanation is also commonly practiced for the relief of surgical lesions. In the Ethnographical Museum at Copenhagen is a Papuan skull showing evidence of trepanation made during life and manifest signs of tertiary syphilis. Among the Polynesian tribes trephining is done by scraping the bone with the tooth of a shark or with a piece of glass. In one district of Algeria, in the province of Constantine, the operation is frequently performed by indigenous surgeons, mostly for fractures of the skull, which are very common among these people. A quite different form of trepanation was employed in ancient Peru, where a quadrangular piece of bone was removed by four cuts, as shown in a specimen described by Broca.

BACTERIOLOGY.

By HAROLD C. ERNST, A.M., M.D.,
BOSTON.

GENERAL METHODS.

Albuminous materials and their influence upon the reaction of nutrient media is studied by Timpe, [50] who emphasizes the uncertainty of neutralization with litmus, as well as the necessity for using phenolphthalein, toward which all albuminous substances ordinarily used react very sharply, as do the lime-salts. The nutrient gelatin should be neutralized with carbonate of soda until a drop of the mixture will produce a red spot on filter-paper soaked with an alcoholic solution of phenolphthalein. Alkalinity of culture-media and its influence upon growth of bacteria (nutrient agar and cholera spirillum) is shown by Hesse [58] to be marked, an excess appearing to be as deterrent in its effect as an insufficient quantity.

The cultivation and study of anaërobic bacteria have received considerable attention of late. The methods commonly employed may be classified as (1) removal of the oxygen by the aid of reducing agents added directly to the culture-medium; (2) exclusion of the air by means of impermeable coverings; (3) growing the bacteria *in vacuo;* (4) substitution of innocuous gases (hydrogen) for the air; (5) growing the bacteria in the depths of culture-media; (6) removal of the oxygen by means of aërobic bacteria. In an elaborate paper upon the subject, Novy [50] states that he used the following media with the best results: (1) beef-bouillon, with the addition of 0.5 per cent. salt, 2 per cent. grape-sugar, 2 per cent. peptone; (2) the same, with 2 per cent. gelatin; (3) 10 to 15 per cent. nutrient gelatin, with the addition of the same proportions of salt, peptone, and grape-sugar; (4) 0.5 to 2 per cent. nutrient agar with the same addition of salt, peptone, and grape-sugar. An apparently very practical method of plate culture is described by Arens [50] as follows: The floor of an ordinary

exsiccator is covered with medium-sized quartz sand, with which some dry pyrogallic acid (no exact quantity) has been mixed. The nutrient material, already inoculated, is poured into Petri dishes, which are placed, uncovered, in the exsiccator, a 10-per-cent. solution of caustic potash being previously poured rather freely over the sand and pyrogallic acid; the cover is then sealed down with melted paraffin. Zettnow $_{\text{May 1,'94}}^{50}$ submits an apparatus that does not seem to have much advantage over the preceding, while Lubinski $_{\text{July 2,'94}}^{50}$ describes a still more elaborate one used by him in the work for which he obtained the gold medal and Pirogoff prize. Sanfelice $_{\text{R.14,'94}}^{58}$ gives the methods and results of a series of investigations upon the anaërobic bacteria, and Novy $_{\text{Oct.7,'93}}^{1}$ describes a new anaërobic bacillus of malignant œdema possessed of extraordinary powers of vitality. It is unquestionable that very much of value is to be learned by further and more elaborate studies than have yet been made in this direction.

The usefulness of blood-examinations has been studied by Canon $_{\text{Nov.9,'94}}^{4}$ in about seventy cases of septic infection. The cases are grouped as (1) pure sepsis, *i.e.*, bacteria in the blood, with no metastases; (2) bacteria in the blood, with metastases; (3) no bacteria in the blood,—metastases only, *i.e.*, pure pyæmia. He does not consider the practical value of such examinations as great, except sometimes in determining whether amputation should be undertaken with the idea of cutting off septic poisoning; if bacteria are found in the blood, it is safe to conclude that the time for amputation is past (?). A new method for examining blood-stains for bacteria, including phagocytosis and malaria, is proposed by Inghilleri. $_{\text{May 25,'94}}^{50}$ It consists in placing the cover-glass prepared in the usual way (or sections) in chloroform for thirty minutes, and then straining with a fluid consisting of 40 parts of a 1-per-cent. solution of eosin in 70-per-cent. alcohol and 60 parts of a saturated aqueous solution of methylene-blue. The preparation is then gently heated for from two to three minutes, washed in water, and mounted as usual. Another, somewhat more complicated, is given by Vincent. $_{\text{July 4,'94}}^{22}$ It is especially valuable for bacteria that do not stain by Gram's method and for malaria. It is based upon the principle that the coloring matters fix themselves in the hæmoglobin, not in the protoplasm, and that, if the former be removed, the blood-corpuscles themselves disappear and the

bacteria alone are stained, standing out very sharply. The solvent tried leaves no deposit and striæ. It is as follows: 5-per-cent. aq. sol. carbolic acid, 6 parts; sat. aq. NaCl, 30 parts; glycerin, 30 parts. Mix and filter. The cover-glasses are treated with this fluid for from one-half to two minutes, then drained, washed, and stained with carbolized methylene-blue with 1- to 2-per-cent. aqueous solution of methyl-violet. The details of a method for obtaining sterile blood-serum are given by Kuprianow, [50 Apr.7,'94] and the method of preparing Löffler's "sugar-serum" for diphtheria by Ohlmacher. [9 Mar.31,'94]

Cellulose has been demonstrated by Dreyfuss [83 v.28,No.2,'93] in bacilli and certain molds, and its existence proved by the most delicate tests known (hydrolysis dextrose).

Cilia and flagella staining has been taken up by several authors. Richmond [2 Apr.28,'94] recommends the method of Nicolle and Morax [202 p.555,'93] with which he has obtained the best results, and quotes interesting observations as to the number of flagella observed in cholera spirilla from various sources. Bunge [58 No.12,'94] uses for a mordant 3 parts of a concentrated aqueous solution of tannin to 1 part of a 1 to 20 aqueous solution of liq. ferri sesquichlor. To 10 cubic centimetres (2½ fluidrachms) of this are added 1 cubic centimetre (15½ minims) of concentrated aqueous solution of fuchsin. It is much better if exposed to the air from a few days to several weeks. It is allowed to remain on the cover-glass for five minutes (warming toward the end), then washed, drained, and strained with carbol-fuchsin. The author claims that in the hands of even unskillful workers this gives extremely satisfactory results. Hessert [50 Sept.6,'94] suggests a method for demonstrating cilia without a mordant, which appears to be very promising. The fixation of the preparation, dried in the air, is accomplished as usual (by passing three times through the flame, or, better, by saturated alcoholic solution of sublimate). Then the preparation (after washing in water if sublimate be used) is stained thirty to forty minutes, warming slightly, washed, dried, and mounted in Canada balsam. For staining fluid he recommends alcoholic fuchsin, and as the best material a twenty-four-hour agar culture at 37° C. (98.6° F.) diluted with tap-water.

A method for a more exact estimation of bacteria in such materials as butter, fæces, and decomposing organs, mentioned by

Ferrin, [50 B.14,No.19] consists in marking a perfectly-straight platinum needle with a file, plunging it into the material up to the mark, and then running it into gelatin up to the mark about ten times in the same tube. Three tubes are thus inoculated, the gelatin is melted and poured into plates, and the mean of the number of colonies that develop furnishes a very accurate idea of the number of bacteria in the original material.

A very useful and cheap counting-plate for plate cultures in Petri dishes is given by Lafar, [887 No.24,'98] and a similar method is described by Lamière. [220 Feb.24,'94]

Cleaning cover-glasses and slides is an important matter in most laboratories, and the following methods are, both of them, effective. Zettnow [50 Apr.17,'94] employs the following method: 200 grammes (6½ ounces) of red chromate of potash are added to 2 litres (quarts) of hot water, and then slowly and with constant stirring 200 cubic centimetres (6½ fluidounces) of crude sulphuric acid. This is sufficient for cleaning one hundred and fifty to two hundred slides and three hundred cover-glasses. The free chromic acid oxidizes the resins. Two or three days in this fluid, then washing in water and wiping dry, will complete the cleansing. Another method is that of Funck. [50 July 22,'94] The cover-glasses and slides are placed in a wide beaker and 2 to 3 knife-points of chlorate of potash, with about 30 cubic centimetres (1 fluidounce) of hydrochloric acid, are added. The whole is warmed in a water-bath for a moment, covered with a glass plate until the material is decolorized, then washed with hot water, and a mixture of equal parts of powdered soda, talc, and sifted saw-dust, with enough water, is added to make a thick, pulpy mass. This is warmed for one-half hour in a water-bath, with continuous shaking, washed with hot water, and a cubic centimetre of strong hydrochloric or acetic (not sulphuric) acid is added. It is again washed with hot water, dried, and wiped with a white towel. Subsequent heating on an iron plate is not necessary.

The following useful suggestions in regard to methods are made by Miller [50 Jan.9,'94]: 1. The drying of cover-glasses after staining may be readily and safely accomplished by using a dentist's air-syringe. 2. The annoying condensation-water on the lid of Petri plate cultures may be avoided by inverting them and placing a third and larger dish over the whole. 3. A thin layer of agar

may be placed over a part of the line of a culture on the surface of the plate so that a portion of the colonies will grow above and a part below the surface. This is especially useful in photography, for both are sure to be secured at once. 4. To destroy mold-spores a small quantity of chloride of calcium is put in, covered with HCl, and the culture shaken; in a few seconds the spores are dead.

The usefulness of hæmoglobin and its derivatives as culture-mediums for pathogenic bacteria and their behavior under such conditions have been studied and confirmed by Filipowsky.[1101 No. 1, '94] Merkel[34 Feb. 27, '94] and Hasterlik,[57 Nov. 26, '93] following Hauser's suggestion,[84 Nos. 20, 25, '93] preserved cultures of bacteria for purposes of illustration by means of formalin. The method is to put 10 to 15 drops of formalin on the under surface of the cotton plug and then place the tube in a tall, air-tight glass to which have been added a few drops of formalin. In this way cultures, liquefying and non-liquefying, may be preserved for some time. An exceedingly important modification of preparing albuminous culture-media is suggested by Smith.[2 June 2, '94] If an alkali be added to an albumin it endows the latter with the power of solidifying, at or over 100° C. (212° F.), as a clear, transparent medium; thus, if 0.1 to 0.15 per cent. of caustic soda be added to ox-serum and the solution be raised to 120° C. (248° F.), the result is a transparent jelly. Too little alkali gives a grayish mass. Egg-albumen may be treated as follows: The white is broken up with an egg-beater until it loses its consistency; 40 per cent. of water is added; the preparation is well mixed, passed through muslin to remove any shreds, and 0.1 per cent. of caustic soda added, the whole being then solidified in an autoclave. If care be exercised a substance almost like gelatin can be obtained.

A culture-medium for the bacillus tuberculosis is suggested by de Schweinitz,[1 Feb. 2, '94] as follows: Distilled water, 1000 cubic centimetres (32 fluidounces); magnesium sulphate, 0.2 gramme (3 grains); acid potassium phosphate, 1 gramme (15½ grains); ammonium phosphate, 10 grammes (2½ drachms); sodium chloride, 10 grammes (2½ drachms); asparagin, 2 grammes (31 grains); glycerin, 70 cubic centimetres (2¼ fluidounces). The bacilli develop more slowly, but equally characteristically as on the more common nutrient media. Another non-albuminous

nutrient medium is suggested by Uschinsky, [50 Sept. 9, '93] upon which cholera, diphtheria, swine-erysipelas, tetanus, and typhoid grow as well as upon bouillon: Water, 1000; glycerin, 30 to 40; sodium chloride, 5 to 7; calcium chloride, 0.1; magnesium sulphate, 0.2 to 0.4; dipotassium phosphate, 2 to 2.5; ammonium lactate, 6 to 7; sodium aspartate, 3 to 4 parts. Kruse [50 Mar. 24, '94] suggests a method for improving plate cultures by allowing the nutrient medium to harden in the Petri dishes and then painting the surface with a diluted culture; and Freudenreich [50 May 1, '94] details a modification of the procedure. Wesener [854 Jan. 31, '94] states that a modification in the preparation of egg for nutrient purposes is to shake thoroughly (to mix white and yellow before breaking the shell), to place it in a water-bath at 75° to 80° C. (167° to 176° F.) for an hour, and finally in a sublimate solution. The egg being cut in slices, its advantages are alkalinity, richness in albumen, and its being unfavorable to the growth of molds.

A new method for staining the gonococcus is given by Lanz. [530 No. 22, '94] Cover-glasses are placed one-half to one minute in a solution of trichloracetic acid 5 and distilled water 20, when a white color is assumed. They are then washed in water, dried, and stained from two to five minutes in a solution of methylene-blue,—distilled water, 30 cubic centimetres (1 fluidounce); 1 to 2 drops of 5-per-cent. potash solution, and sufficient saturated solution of methylene-blue to produce a dark-blue color in the fluid. A very lasting and deeply-stained preparation is thus obtained.

The acid reaction appearing in cultures of the pneumococcus is due to formic acid, and their rapid loss of vitality is also due to this acid; this formation can be prevented, according to Wurtz and Mosay, [14 Jan. 31, '94] by the addition of a little carbonate of chalk to the culture-medium.

Unna [28 B. 14, No. 9, '93] suggests a new differential stain for the bacilli of leprosy and tuberculosis in sections, as follows: 1. Polychromic methylene-blue (Grubler), ten minutes to one hour; washing in water; 33 per cent. watery tannin solution, two to five minutes; careful washing in water; absolute alcohol; oil of bergamot; Canada balsam. An exceedingly interesting method for the demonstration of protozoa and spirilla in drinking-water is that described by Beyerinck, [50 Feb. 24, '94] while an apparently excellent method for obtaining pure cultures of protozoa is given by Ogata. [50 Aug. 7, '93]

The following staining solution, according to Ilkewitsch, [21 June 30, '94] gives very effective results for photography: Distilled water, 450; alcohol (85 per cent.), 100; glycerin, 50; tannic or pyrogallic acid, 30.

Staining spores with the help of maceration is advocated by P. Ernst, [50 Aug. 11, '94] an example of the method used being as follows: Bacillus subtilis, 3 days in agar at 37° C. (98.6° F.); 13 to 15 minutes in 5 per cent. chromic acid; water; 18 hours in gentian-violet aniline-water: 2 to 3 millimetres of Lugol's solution; Gunther's acid alcohol; 96 per cent. alcohol; water; Bismarck-brown. Another is: Anthrax cultures, 24 hours on agar at 37° C. (98.6° F.); 24 hours at 20° C. (68° F.), and 24 hours at 19° C. (66.2° F.); 23 minutes in 5 per cent. chromic acid; 18 hours in Ehrlich's solution; 33 per cent. nitric acid; water; aqua methylene-blue.

An electric-alarm thermo-regulator is described by Barille. [243 Jan., '94] G. Roux, [211 Dec. 24, '93] by painting colonies with steresol, prevents the liquefaction that is so annoying in the study of many forms of plate cultures. The use of the amount of gas produced by the addition of peroxide of hydrogen to suspected water, as a rough method of estimating the contained bacteria,—recommended by Gottstein, [20 B. 128, H. 2]—is said by Lasar [50 Aug. 11, '94] to be entirely untrustworthy.

SPECIAL BACTERIA.

Actinomycosis.—The various species of this genus that have already been described are given by Gasperini [50 May 7, '94] as eighteen. The author summarizes the characteristics of the genus under twelve headings.

Amœbæ.—Celli and Fiocca [589 Mar. 22, '94] give very interesting accounts of the various forms of amœbæ already cultivated, as follow: (1) *Amœbæ labosa*, with its varieties of guttula, oblonga, undulans, coli; (2) *A. spinosa*; (3) *A. diaphana*; (4) *A. vermicularis*; (5) *A. reticularis*; (6) *A. arborescens.* They state that more than one variety is found in the intestines, and Nasse [112 June, '94] gives an interesting account of the amœbæ found in a case of liver-abscess. Quincke and Roos [4 No. 45, '93] support the statements of Celli and Fiocca.

Anthrax.—Sabrazès and Rivière [70 Mar. 25, '94] show that, contrary to Sclavo's assertion, [2135 '92] the spore-bearing bacillus of anthrax preserves its virulence in neutral glycerin. The nuclei of anthrax spores

are demonstrated by Ilkewicz $^{50}_{\text{Mar.2,'94}}$ by the following method: Cover-glasses are fixed in the flame (free from the nutrient material) and stained one to two minutes in the warmth with ½-per-cent. aq. sol. osmic acid, 7 cubic centimetres (1¾ fluidrachms); formic acid, 3 cubic centimetres (46 minims). The osmic acid is deoxidized in reducing agent *a* or *b*, which are prepared as follows: Tannin, 30 grammes (1 ounce); water, 100 cubic centimetres (3¼ fluidounces); allow to stand twenty-four hours in open vessel, filter, and add to filtrate pyrogallic acid, 30 grammes (1 ounce); dissolved in distilled water, 100 cubic centimetres (3¼ fluidounces). To this mixture add glycerin, 50 grammes (1½ fluidounces); alcohol (95 per cent.), 100 cubic centimetres (3¼ fluidounces); water, 250 cubic centimetres (8 ounces). Reducing fluid *a* is made from equal parts of above solution, with pyrogallic acid, 8; citric acid, 3; sodium sulph., 17; aq. dest., 150. Reducing fluid *b*, from 10 cubic centimetres (2½ fluidrachms) of this last mixture (the second part of *a*); alcohol, 3 cubic centimetres (46 minims); tannin solution (tannin, 20; water, 80), 2 cubic centimetres (31 minims); glycerin, 1 cubic centimetre (15½ minims). Either of these may be used when the other fails, warming until the steam rises, washing in water, and then repeating the whole process.

Pane and Lanciano $^{506}_{\text{Sept.,'93}}$ lay stress upon the individual resistance of guinea-pigs to the virus of anthrax and pneumonia, the result of such inoculations depending, first, upon the quantity injected, and, second, upon the resistance of the particular animal used. Gratia $^{52}_{\text{Apr.28,'94}}$ studies the diagnostic characteristics of the bacillus of anthrax in the microscopical examinations of the blood, summarizing them as follows: (1) the anthrax bacillus has the form of a rod of varying length from 5 μ to 20 μ, and 1 μ to 1.5 μ broad, broken up into short articulations from 1.5 μ to 2 μ long, placed end to end, like the sections of a tænia; (2) the ends of each articulation are slightly swollen, giving the appearance of a bamboo cane; (3) clear spaces, mostly like a biconcave lens, exist between the ends of the articulations, resulting from the slight concavity of these ends; (4) a capsule, frequently distinctly marked, surrounds the rod, seeming to form a protoplasmic support of the individual articulations. Johne $^{930}_{\text{Nov.1,'93}}$ emphasizes the same points. Pinna $^{50}_{\text{May 25,'93}}$ studies the decrease of the virulence of the anthrax bacillus in sea-water. Sirena and Scagliosi $^{589}_{\text{May 5,'94}}$ give some very remarkable

instances of prolonged vitality of anthrax spores in dry or moist earth; drinking-, sea-, and sewer- water; and Inghilleri $^{50}_{\text{May 25,'94}}$ studies the behavior of the anthrax bacillus in unsterilized milk. Sanarelli demonstrates $^{262}_{\text{Dec.,'93}}$ its destruction under the skin of sensitive animals, in capsules of collodion; and Gramatchikoff, $^{262}_{\text{Dec.,'93}}$ the influence of thymus and testicular extracts upon the same virus. Werigo $^{262}_{\text{Jan.,'94}}$ presents an elaborate study of the development of anthrax in the rabbit, and Roger $^{410}_{\text{No.1,'94}}$ shows the disappearance of the glycogenic function in the rabbit in accordance with the progress of the disease. Bard $^{44}_{\text{Apr.,'94}}$ refutes the statement of Sternberg, [2136] that anthrax does not exist in the United States, by describing its ravages in California. The results of the inoculations against anthrax and swine-erysipelas (Chamberland $^{262}_{\text{Apr.,'94}}$) appear to show, by the statistics given, a great diminution in the percentage of deaths from these diseases, and, as a result, an enormous saving to the wealth of the country. Burri $^{934}_{\text{No.5,'94}}$ describes an anthrax-like bacillus, found in South America in American meal, that killed a number of oxen that were fed on it, and Müller $^{54}_{\text{Nos.4,5,'93}}$ presents an elaborate study of the anthrax of rats.

Cancer.—The amount of work done in the investigation of the various processes that may be classed under this head has been very large during the past year. In point of time, the first place is to be given to J. Jackson Clarke's very complete summary $^{22}_{\text{Aug.13,Oct.11,'93}}$ of the work done by himself and others, and on the protozoa considered in relation to disease, especially cancer, sarcoma, and other morbid growths. Korotneff $^{2137}_{\text{H.1,'93}}$ gives the result of much work and special methods. Mayet $^{920}_{\text{V.116,p.1316}}$ details some successful results in the inoculation of cancer. Snow $^{6}_{\text{Nov.11,'93}}$ writes upon and against the so-called "parasitic" protozoa of mammary carcinoma, while Cattle and Miller $^{6}_{\text{Nov.18,'93}}$ present an elaborate article upon certain gregarinidiæ and the possible connection of allied forms with tissue changes (cancer) in man. Nepveu, $^{457}_{\text{No.1,Jan.,'94}}$ in considering the parasites of cancer, classifies what he sees under high powers at the edges of the lesion as (1) spores, (2) sporiferous cells, (3) sporoid cells, contained in (4) amœboid cells. Burchardt $^{20}_{\text{B.131,H.1}}$ found in a myxosarcoma of the ovary, with the intracellular parasitic forms of other authors, a similar body surrounded by a distinct capsule which he considered a coccidium, and Schuberg $^{50}_{\text{B.14,No.4}}$ takes exception to this conclusion. Kurloff $^{50}_{\text{Mar.16,'94}}$

publishes an interesting article upon carcinoma parasites. Cornil gives $_{\text{May 5,'94}}^{59}$ a very interesting paper upon "the modification of cancerous cells and nuclei that may be mistaken for parasites,"—a matter of very considerable importance. Sippel, $_{\text{Apr.2,'94}}^{5}$ Kinscherf and Bartsch, $_{\text{Aug.,'94}}^{13}$ Boinet, $_{\text{June 12,'94}}^{3}$ and Moran, $_{\text{Sept.5,'94}}^{3}$ all present articles showing experimentally the possibility of the transmission of cancer in the lower animals; while Baker and Hardmann $_{\text{June 23,'94}}^{2}$ gives instances of its apparent transmission in human beings. An editorial $_{\text{Aug.11,'94}}^{1}$ calls attention to the inheritance of the disease, based on the paper of Howlitt. $_{\text{July,'94}}^{824}$

Of general articles upon the etiology of cancer, there may be noted, among the most prominent, those of Wassilieff, $_{\text{Nos.15,16,'94}}^{73}$ on the origin of neoplasms in general, and of cancer in particular; of McFarland, $_{\text{Apr.7,'94; June 30,'94}}^{9}$ $_{\text{Apr.7,'94; June 30,'94}}^{1}$ Ribbert, $_{\text{Apr.12,'94}}^{69}$ Cattle, $_{\text{Apr.21,'94}}^{2}$ Schürmayer, $_{\text{Apr.7,14,'94}}^{399}$ Binaud, $_{\text{July 25,'94}}^{25}$ and Grasset. $_{\text{Aug.11,'94}}^{100}$ Barwell $_{\text{July 28,Aug.25,'94}}^{6}$ writes on "The Improbability of a Parasitic Origin of Malignant Diseases," summarizing the theoretical objections to it. Kahane $_{\text{B.15,No.12,'94}}^{50}$ finds irregular amœboid bodies in the blood of cases of carcinoma, which he considers to be parasites. Adamkiewicz $_{\text{Apr.,'94}}^{360}$ writes upon the *Coccidium sarcolytus*, and Ribbert $_{\text{Apr.24,'94}}^{34}$ gives a very interesting comparative study of cancer and tuberculosis. If the majority of observations made are correct, the conclusion is inevitable that the parasite of cancer, if it exist at all, is multiple in form, and that either there is more than one parasite concerned in the production of the various processes or there are very varying forms of this one parasite. Of special work, in addition to those already spoken of, may be mentioned the following: Reinback, $_{\text{B.46,H.3,'93}}^{226}$ on "The Behavior of the Leucocytes in Malignant Tumors"; Petrow, $_{\text{Nos.1,5,'94}}^{859}$ "The Micro-organisms of Sarcoma," from a study of nineteen cases; Kurlow, $_{\text{No.1,'94}}^{586}$ on "The Doctrine of the Parasite of Cancer," one case showing Korotnew's *Rhopalocephalus carcinomatosus;* Kourloff, $_{\text{No.1,'94}}^{586}$ "A Contribution to the Study of the Parasites of Cancer." Pamlowsky $_{\text{B.183}}^{20}$ states that he found parasites (protozoa) in cells of sarcomatous tissue, but not so frequently as in carcinoma. Clausen $_{\text{B.14,H.1,'93}}^{768}$ thinks that the so-called parasites should not be definitely classed until better and more exact methods of staining are devised. Busse $_{\text{Aug.11,'94}}^{50}$ gives methods of study and results, and Okuschko, $_{\text{Sept.17,'94}}^{41}$ after studying forty cases, concludes that the so-called parasites are probably degeneration

products of cells. A valuable article in connection with the general subject is that of Cadiot, Gilbert, and Roger $_{\text{July 14,'94}}^{1158}$ on malignant tumors in animals. Perhaps not exactly in the line of parasites of cancer, but very interesting, is a general review upon the specific power of cells and its principal consequences, $_{\text{Mar.10,'94}}^{8}$ and the communication of Foa $_{\text{June 30,'94}}^{997}$ on cellular proliferation. The same author $_{\text{Nos.5,6,'94}}^{739}$ gives a method for successfully staining the parasites of cancer. Ribbert $_{\text{B.135,H.5,'94}}^{20}$ gives the results of his studies upon the histogenesis of carcinoma, and Griffiths $_{\text{Aug.11,'94}}^{1}$ describes an extremely poisonous ptomaine (?) which he extracted from the urine of women affected with cancer of the uterus, and to which he gives the name of "cancerine." The work upon the parasitic nature of cancer has led to no unanimous opinion in the matter. The discussion is not likely to be ended until such simplicity of method and constancy of result is obtained as will easily serve to convince the skeptical.

Cholera.—As with cancer, cholera has been the subject of an enormous amount of investigation; so that it is almost impossible to make a satisfactory selection of the work published. C. Fränkel and Klipstein $_{\text{Oct.4,'93}}^{399}$ study the behavior of the bacteria of cholera and typhoid in turf-mold. The conditions lengthening the vitality of the cholera spirillum are detailed. Data as to the toxicity of the spirillum are given by Inghilleri and Rolando. $_{\text{Nos.16,17,'93}}^{915}$ Kiessling $_{\text{B.8,'93}}^{2138}$ describes a new cholera-like spirillum. Zambaco $_{\text{Mar.31,'94}}^{232}$ takes strong ground against the power of the cholera spirillum to produce cholera, basing his conclusions upon much of the work done in the last two or three years. Ivanoff $_{\text{Dec.30,'93}}^{58}$ gives a very complete account of a new variety of vibrio resembling that of cholera. Kowalski $_{\text{Dec.10,'93}}^{57}$ describes vibriones found in cases of *foudroyant* cholera, which Paltauf and Weichselbaum both consider to be the same as those described as far back as 1884, and found in normal fæces as well as in cholera. The discussion is carried on farther by Abel, $_{\text{Feb.15,'94}}^{50}$ Escherich, $_{\text{Mar.24,'94}}^{50}$ Lustig and Giaxa, $_{\text{B.15,Nos.19,20}}^{50}$ and Kowalski. $_{\text{Sept.6,'94}}^{50}$ Kutscher $_{\text{Dec.7,'93}}^{69}$ gives a very interesting summary of methods of differentiation of the various cholera-like bacteria found in water and of one possessed of phosphorescent properties, and Dieudonné $_{\text{Sept.6,'94}}^{50}$ reviews all the "cholera-like" vibriones described in the last two years. Sorena and Scagliosi $_{\text{Apr.28,'94}}^{589}$ give a very clear summary of the similarities

and differences between the various spirilla found in different localities in the epidemic of 1893. Wiltschow $_{\text{Apr.15,'94}}^{50}$ presents new data in the bacteriology of cholera. The diagnosis of cholera by bacteriological methods is treated by Koch, $_{\text{Nov.18,'93}}^{6}$ who advises the use of peptone solutions for the beginning of the separation of the spirilla from the suspected material. Voges $_{\text{Apr.7,'94}}^{50}$ does not consider that enough has been done to prove the value of Uschinsky's fluid $_{\text{B.14,No.10}}^{50}$ for practical use in the diagnosis of cholera, but suggests a modification of it. Zabolotny $_{\text{No.51,'93}}^{69}$ advises the use of egg-albumen for the rapid diagnosis of cholera vibriones, and Massen $_{\text{p.122,'94}}^{2138}$ advises blood-serum (solidified) for the same purpose. Bleisch $_{\text{B.14}}^{58}$ speaks of sources of error in obtaining the "cholera-red" reaction, and suggests the use of a culture-medium of pure peptone, with salt and nitrate of potash added, with which the reaction can be obtained, in from four to six hours, at 37.5° C. (99.5° F.), instead of twelve to fourteen hours. Gruber $_{\text{July 7,14,'94}}^{6}$ has a very admirable communication upon the best methods to adopt in the bacteriological diagnosis of cholera.

Dempster $_{\text{May 26,'94}}^{2}$ discusses the influence of different kinds of soil upon the cholera and typhoid bacteria, showing that peat is very active in preventing their transmission. Blachstein $_{\text{Apr.28,'94}}^{4}$ studies the virulence of the cholera spirillum in its relationship to the soil upon which it grows, and Metschnikoff $_{\text{May,'94}}^{262}$ the artificial variation of the cholera spirillum. These variations of the cholera spirillum coming from different sources have been studied by many observers, notably Finckelnberg, $_{\text{B.12,No.4}}^{50}$ Celli and Santori, $_{\text{May 25,'94}}^{50}$ and Claussen. $_{\text{Sept.6,'94}}^{50}$ Blachstein $_{\text{June 25,'94}}^{41}$ and Klemperer $_{\text{June 21,'94}}^{41}$ have studied the specific virulence of the cholera spirilla in the effort to determine what produces great effects when cultures show the presence of a comparatively small number of bacteria. Gamaleia shows $_{\text{No.51,'93}}^{69}$ that cholera spirilla may retain their vitality for five weeks when moisture is present. Wernicke, $_{\text{June 9,'94}}^{50}$ because of the short vitality on tobacco-leaves, shows the slight danger of the spread of cholera on tobacco and cigars. Wnukow, $_{\text{Dec.9,'93}}^{50}$ Montefusco, $_{\text{V.8,No.1,'94}}^{727}$ and Renk $_{\text{V.9,No.10,'94}}^{54}$ study the effect of low temperatures and of ice upon the cholera spirillum, demonstrating that it may withstand extremely low temperatures for a long time without losing its vitality. Haan and Huysse, $_{\text{Mar.2,'94}}^{50}$ Weigmann and Zurn, $_{\text{Mar.2,'94}}^{50}$ and Zenthöfer $_{\text{Mar.2,'94}}^{58}$ present interesting studies upon the

reactions of cholera spirilla in milk, milk-products, and egg-albumen; and Salus $_{B.19,H.4,'98}^{324}$ studied their action in pigeons, failing to confirm the results of Pfeiffer and Nochet; $_{B.7,'99}^{58}$ on the contrary, seeming to demonstrate an especial susceptibility of pigeons to cholera, and the possible securing of immunity. Terni and Pellegrini, $_{Jan.,Feb.,'94}^{468}$ in studying the cholera bacteria found in the epidemic of 1893 at Livorno, confirm other results as to the varying virulence of the bacteria. Hesse $_{June\ 2,'94}^{50}$ shows the alterations of milk necessary to make a good culture-medium for the cholera spirilla. Afanassiew $_{Mar.10,'94}^{21}$ explains how the cholera spirilla were demonstrated in the water of the Neva. Sormani $_{June\ 2,'94}^{50}$ has done some important work upon the neutralizing materials to be used in cholera cultures, and Inghilleri and Rolando $_{May\ 25,'94}^{50}$ formulate their results upon the activity and method of action of the cholera spirilla in the body, while Bayet $_{Dec.9,'94}^{868}$ gives an elaborate study of the bacteriological study of choleraic affections. Kolle $_{Mar.2,'94}^{58}$ has studied carefully the methods and results of the experimental use of cholera cultures in guinea-pigs; Uffelmann concludes that the spirilla can, under certain conditions, be transported through air from earth and sweepings, and Craig $_{July\ 14,'94}^{59}$ emphasizes the transmission of the bacteria by the dejecta of the common house-fly. Immunity against cholera is studied by Klein $_{Mar.,'94}^{15}$ and Sobernheim, $_{No.22,'93}^{930}$ both of whom found that many bacteria besides those of cholera conferred immunity against intra-peritoneal cholera. Pfeiffer and Wassermann $_{B.14,p.46,'98}^{58}$ claim that immunity against cholera is something aside from the general question of immunity. Subolotny $_{Feb.5,'94}^{50}$ carried out his experiments upon the *Spermophilus guttatus*,—a rodent common in South Russia. A summary of the general question of "Experimental Immunity against the Spirillum of Asiatic Cholera" is given by Issaef. $_{Apr.15,'94}^{860}$ Klein $_{B.14,No.19,'93;\ Feb.10,'94}^{50}$ uses the following for staining the flagella of cholera in stools: A flocculus from the rice-water discharges is placed for from five to ten minutes in equal parts of absolute alcohol and aniline-water gentian-violet, washed well, pressed between cover-glasses, dried, and mounted in Canada balsam. The bacilli appear a deep violet, the flagella a lighter, but are stained sufficiently to photograph well. (This does not show flagella in cultures.)

Chromogenic Bacillus.—A new bacillus (*B. violaceus saccari*), giving a deep-blue color, only, on agar-agar, is described by

Ager, [1] and Casabo [459] gives a new chromogenic cladothrix. The general subject of the permanent or facultative chromogenic properties of various bacteria cultivated upon egg-albumen is studied by Teissner. [457]

Coli Communis Bacillus.—Lehmann [50] gives a very interesting study of the relationship between this bacillus and the various bacteria concerned in leavening processes. Walliczek [50] shows that it has comparatively slight resisting powers to drying. The motility and cilia of a number of bacilli of the group of the bacillus coli communis are studied by Stœcklin. [13] Stillman and Barlow [868] give notes of a case in which the bacillus was found in the blood of a patient; Dmochowski and Janowski [13] record two cases of suppuration of the gall-bladder produced by the bacillus, and Escherich [50] discusses it as the cause of cystitis. The variations in virulence are studied by Dreyfus, [273] and its pathogenic action by Oker-Blom. [50]

Diphtheria.—The "antidiphtherin" of Klebs is spoken of at some length, [2] but its use has been obscured by the results announced from the employment of the "antitoxin." Kossel [69] and Roux [262] both give results that seem to be most encouraging. Kossel, speaking for Koch and of the results obtained in the Institute for Infectious Diseases at Berlin, declares that no uncomplicated case that was treated in the first or second stage of the disease was lost, and that the mortality of all cases was reduced to 16 per cent. Roux reports the reduction of the mortality in the Hospital for Sick Children in Paris from 50 to less than 25 per cent., and, excluding cases dying within thirty-six hours of entrance, to less than 4 per cent. Certainly, if these results are borne out, a specific has been obtained against this dreadful disease,—the result of work upon purely bacteriological lines and one of the greatest triumphs of medicine. This, however, but serves to emphasize the necessity for the bacteriological diagnosis of diphtheria, and in this connection the recommendation of Schloffer [50] of "urine-agar" for the cultivation of the bacillus is of value. The mixture consists of meat-water-peptone-agar, 2 parts; sterile urine, 1 part. Abel [50] traced the source of infection of a case under his care to a wooden toy, finding the bacilli there. Ledoux-Ledard [457] finds that light has a very powerful action upon the vitality of the bacillus, sunlight being much more fatal

and rapid than diffused light. Enriquez and Hallion [14 Apr.16,'94] caused an experimental myelitis by means of the toxin of diphtheria, which is exceedingly interesting in connection with the post-diphtheritic symptoms occurring clinically. The same authors [14 Dec.27,'93] speak of a very frequent gastric ulceration produced by their experiments with the diphtheria toxin. Sormani [50 June 2,'94] presents an exceedingly important research upon the neutralizing materials to be used in diphtheria, the most active of which are ichthyol-vasogen, iodoform-vasogen, creolin-vasogen, and creasote-vasogen. He does not find Klebs's "antidiphtherin" of much value. Hudelo and Bourges [14 Jan.31,'94] failed to find the diphtheria bacillus in the diphtheroid membranes of certain syphilitic processes.

Glanders.—Bonome, [589 May 26 et seq.,'94] in an elaborate series of articles upon the behavior of the glanders bacillus under cultivation and the value of mallein as a diagnostic and curative agent, shows that the bacillus is diffused in the urine and milk of affected animals, as well as in the exudations; that it is sensitive to complete drying, but resists high temperatures with comparative vigor. He does not consider mallein as an absolutely diagnostic reagent, while its curative properties are not yet perfectly demonstrated, though he records the case of a boy, 16½ years old, who recovered from the disease after its use.

Gonococcus.—Immerwahr [41 Jan.29,'94] describes a new diplococcus obtained from gonorrhœal pus, similar in form, situation, and staining reaction to the gonococcus, but differing from it in its appearance under cultivation in the media ordinarily employed. He considers it identical with the diplococcus described by the French, believed by them to be the cause of epididymitis and called "orchococcus" (bacterium of orchitis). Finger [June 6, Aug.29,'94] gives a review of our knowledge of the gonococcus. Kratter [50 Aug.15,'94] summarizes the work of his assistant, Ipsen, upon the length of time that the gonococcus can be recognized after drying, declaring that it is not difficult to observe it after days, weeks, and even a year, but that its virulence is not kept so long. Touton [50 Sept.6,'94] describes the localization of the gonococcus in the organism in pleurisy and arthritis, while Mazza [739 Mar.,'94] claims to have found it in the exudate of pleurisy following gonorrhœa. By the work of Turro [494 May 15,31,'94] it is shown, and confirmed by Wood, [99 Aug.2,'94] that pure cultures of the gonococcus can be obtained with ease upon

ordinary nutrient gelatin not made alkaline. It has been known that acid media were the best for cultures, but this simple expedient seems to promise a great advance in our knowledge of the process. Caneva [589 Jan.31,'94] recommends the following method for staining the eosinophilic cells of gonorrhœal pus: Cover-glasses dried in air; three times in flame; five to ten minutes in a saturated alcoholic solution of eosin; water; two to five minutes in a dilute aqueous solution of methylene-blue; water; drying; then Canada balsam. Lanz [69 No.9,'94] gives the following method: The cover-glasses are immersed for one-half to two minutes in a 20-per-cent. aqueous solution of trichloracetic acid, washed in water, and placed for three to five minutes in the stain (water, 30 cubic centimetres—1 fluidounce; 1 to 2 drops of a 5-per-cent. aqueous solution of carbolic acid; saturated alcoholic solution of methylene-blue, q. s. ad deep-blue color). A very effective contrast may be obtained by using Bismarck-brown for one-half to one minute.

Immunity.—It cannot be said that much that is new has been added to our knowledge of the theories of immunity. Buchner [34 June 12,19,Sept.11,'94] publishes a good paper upon the newer advances. Dividing immunity into natural and acquired, he states that natural immunity is brought about by the presence of a bactericidal body and alexin in the blood-serum. This alexin differs from an antitoxin in that it acts upon bacteria, red corpuscles, and even leucocytes belonging to animals of other species; while an antitoxin acts only upon the bacteria or the toxins produced by them. An alexin is easily decomposed, while an antitoxin is not. The effects of an antitoxin are the same whether coming from an animal of the same or of a different species, and only depend upon the degree of acquired immunity possessed by the animal. He concludes that there is no such thing as curative serum, but that there exist merely immunizing substances by means of which we may, under favorable circumstances, so speedily produce immunity as to arrest the further progress of pathological disturbances. There is necessary, besides this immunizing substance, the capacity for reaction on the part of the cells of the body, and Behring's experiments seem to show that it is no longer possible in cases of advanced disease. Buchner considers the so-called antitoxins to be bacterial proteids related to the toxalbumins; for practical purposes the great point is to

obtain the antitoxin as pure and free from toxin as possible, and, according to him, it is quite unnecessary to prepare it in the form of serum by passing the cultivation through the animal body,—an opinion directly opposed to that of Behring. Exceedingly interesting summaries are written by Matignon $^{70}_{\text{Jan.26,Feb.4,'94}}$ on heredity and immunity; Chéron, $^{17}_{\text{Mar.3,26,Apr.,'94}}$ and Hervouet, $^{127}_{\text{May 12,'94}}$—all valuable for the reason that our ideas of the subject are so new that constant summarizing is the only way of rendering it complete. Gley and Charrin $^{410}_{\text{Jan.,'94}}$ seem to demonstrate a slight amount of hereditary transmission of immunity, and Vaughn $^{1}_{\text{Sept.28,'93}}$ presents an important paper upon the general subject of the methods of production of immunity and cure of the infectious diseases. Denys and Havet have $^{795}_{\text{V.10}}$ studied the importance of the leucocytes in the bactericidal power of the blood of the dog, reaching the conclusion that neither phagocytosis nor the humoral theory, taken separately, can explain immunity. Both phagocytosis and humors work together in varying measure, and undoubtedly—according to the species of animal as well as the nature of the attacking agent—to preserve the organism from the invasion of the bacteria. Under special progress in immunity, Egasse $^{67}_{\text{Dec.15,'93}}$ summarizes much of the work done in securing immunity against cholera, without, however, showing that very much advance has yet been made in obtaining it in human beings during a time of epidemic. The work of the Klemperers $^{4}_{\text{Nos.2,4,25,'94}}$ and that which it has called out are summarized by Ely, $^{1}_{\text{Mar.5,'94}}$ the results thus far being sufficient to demonstrate the harmlessness of the treatment and very forcibly to suggest a relationship of cause and effect between the treatment and the amelioration of the symptoms. Rummo $^{589}_{\text{Oct.9,'93}}$ details some important results in the production of immunity by chemicals, notably in tetanus with strychnia,—experiments that should certainly be tried farther. Flexner $^{9}_{\text{Aug.4,'94}}$ publishes the results of an experimental study of the pathological changes caused by certain so-called toxalbumins, which seem to show an analogy between the results thus produced and chronic interstitial changes occurring in man. Cantani and Bruschettini $^{69}_{\text{No.12,'94}}$ have continued their previous investigations $^{69}_{\text{Nos.44,45,'93}}$ upon the causes of the fever in infectious diseases. Having reached the conclusion that the "pyrotoxin" producing it is the same for all bacteria, they used the serum of rabbits immunized against the influenza bacillus, and

succeeded in allaying the fever produced by it by using injections of other bacteria. Klein $_{\text{Apr.27,'94}}^{50}$ continues his work upon the nature of the intra-cellular bacterial poison, and Belardi $_{\text{Jan.2,'94}}^{589}$ gives a valuable contribution to the study of auto-intoxication.

Infection.—The activity of atmospheric agencies—wind, heat, cold, etc.—upon bacteria is emphasized by d'Arsonval and Charrin $_{\text{Jan.17,'93}}^{14}$ and pointed out as explaining many of the facts in regard to epidemics. Chauffard $_{\text{July 4,'94}}^{3}$ demonstrates the method by which infection usually occurs, and speaks at length upon the "lymphatic-halting" places of the process.

Influenza.—Huebner $_{\text{Dec.30,'93}}^{50}$ considers cultures of the influenza bacillus necessary for diagnostic purposes, while von Jaksch $_{\text{No.30,'93}}^{88}$ regards the microscopical examination as unsatisfactory, concluding that careful clinical examination is the best present means for diagnosis. Kahn $_{\text{June 2,'94}}^{31}$ gives a very complete study of the present knowledge of the bacillus of influenza. Coronado $_{\text{Sept.,'93}}^{459}$ confirms its presence in Cuba and its clinical importance, and Hajech records $_{\text{Apr.21,'94}}^{319}$ a case of pseudomembrane formation in which the influenza bacillus was present, but not that of diphtheria.

The *Leptothrix buccalis*, of which Miller distinguishes four varieties, is said by Iliine $_{\text{May 19,'94}}^{31}$ to play the principal part in the formation of "tartar" upon the teeth.

Light and its effect upon bacteria have been studied by Khmelevsky $_{\text{No.66,'93}}^{2112}$ and Ward, $_{\text{May 5,'94}}^{2}$ who show the inhibitory action of many forms of light.

Malaria.—The plasmodium and its behavior toward cold is very carefully studied by Sacharoff. $_{\text{Feb.5,'94}}^{50}$ Marchiafava $_{\text{May 5,'94}}^{59}$ insists especially upon the pathogenic properties of the form described by him, in causing the pernicious fevers.

Milk.—Knochenstierna $_{\text{Mar.2,'94}}^{50}$ finds that the milk from a healthy woman with sound breasts is practically sterile. Gernhardt $_{\text{Mar.2,'94}}^{50}$ studies the qualitative bacterial contents of milk, while Weigmann and Zirn $_{\text{Apr.7,'94}}^{50}$ and Bochicchio $_{\text{Apr.17,'94}}^{50}$ describe the bacteria found in "soapy" milk, and a new micro-organism concerned in decomposing cheese.

Plague.—The plague at Hong Kong has been studied by Kitasato and Yersin, $_{\text{Aug.11,'94}}^{6}$ both of whom have succeeded in isolating and cultivating a special bacillus which is supposed to be the cause of the disease and is found especially in the enlarged

inguinal glands,—its most marked accompaniment. The bacillus is usually arranged in pairs, is very small, and stains easily with gentian-violet, but does not stain by Gram's method. It may be cultivated upon gelatin and agar at the ordinary temperature of the room, but better at blood-temperature. The two observers named worked independently and equal credit is due to each for the isolation and description of this new bacillus.

Pneumonia.—Casati $_{V.47,No.4,'98}^{376}$ does not find the diplococcus constantly present in the blood of pneumonia patients. Arloing $_{Dec.18,'98}^{14}$ finds that "pneumobacillin" is as effective in producing a rise of temperature in glanders as is mallein. Foà $_{Dec.30,'98}^{58}$ presents an extremely valuable paper upon infection with the diplococcus lanceolatus, especially from the point of view of serum therapeutics. The usual number of cases of suppurative inflammation, accompanied by the bacillus of pneumonia and occurring in various parts of the body, have been reported during the year. The relationship between this bacillus, that of the lactic ferment, and of certain other bacteria with the bacillus lactis aërogenes and the bacillus of typhoid is discussed by Denys and Martin. $_{V.9,No.1}^{795}$ Dmochowski $_{Apr.27,'94}^{50}$ found the pneumobacillus of Friedländer in a case of suppurative disease in the nose.

Protozoa.—The relationship of protozoa to disease processes is taken up by Ruffer $_{Nov.1,'98}^{22}$ and Delépine and Cooper, $_{Oct.14,'98}^{2}$ the former claiming that a crucial point has been proved in these bodies by the demonstration of a reproductive process. The latter authors are not quite ready to accept this point, but express a great desire that it should be demonstrated.

Pyocyaneus Bacillus.—This bacterium has attracted as much attention as usual. Jakowski $_{Dec.30,'98}^{58}$ studies a new variety obtained by him. Kossel $_{Mar.2,'94}^{58}$ demonstrates that the bacillus may be extremely pathogenic for human beings (children), following out the experimental knowledge that it is extremely pathogenic for the young of the lower animals. A similar case is detailed by Williams. $_{July,'94}^{282}$ Mühsam and Schimmelbusch $_{V.46,No.4}^{226}$ demonstrate the prevention of the color-production by culture with other bacteria.

Scurvy.—A bacillus appearing in the gingivitis and hæmorrhages of scurvy has been isolated by Babès, $_{No.9,'98}^{457}$ who thinks it is one that occurs in healthy mouths, but takes no pathogenic properties in a weakened condition of the system.

Serum.—The possibility of neutralizing the microbicidal properties of the blood-serum are shown by Pansini and Calabrese. [589 Jan. 2, '94] Vaughn and McClintock [9 Dec. 22, '93] discuss the nature of the germicidal constituent of the blood-serum, which they regard as a nuclein.

Staphylococcus.—Maurel [1088 Oct. 29, '93] gives the general conclusions that follow as the result of his study of the action of iodoform upon the staphylococci: 1. From a general point of view it is necessary to recognize for various bacteria, and for the staphylococci in particular, several distinct properties, and not to confound them in one property,—that of virulence. In the present condition of science there are at least three,—virulence, reproductive power, and vitality. For the staphylococci, his experiments prove the necessity for distinguishing virulence from reproductive power, since the one modifies the other, while cultures in blood prove the necessity for separating the reproductive power from the vitality. Virulence itself is only the combination of many properties; we should at least separate that of its toxins from that inherent in the bacterium itself. Among these latter, one of the most important is its hæmocyticidal power. 2. From a special point of view it seems as if it could be definitely concluded that the efficacy of iodoform against the staphylococci, so clearly shown by clinical experience, is to be explained by the combined actions of the increase of the energy of our own leucocytes and the attenuation of the virulence of the staphylococci. Schnitzler [50 Mar. 2, May 2, '94] records a case seeming to him to demonstrate the renewed activity of the staphylococcus pyogenes aureus after lying dormant a long time, apparently for thirty-five years. Salvioli [4 Mar. 28, '94] believes that the physiological action of the soluble products of the bacteria, especially of pyogenic staphylococci, is aided by the action of other bacteria. Cesaris-Demel [589 May 1, '94] does not think the virulence of the staphylococcus pyogenes aureus is necessarily proportionate to the severity of the case. Davalos [459 June, '94] reports a case of association of the diphtheria bacillus and the staphylococcus pyogenes albus in a case of impetigo.

Streptococcus.—Streptococci and the septicæmias produced by them are elaborately studied by Cipollone. [531 Nov., '93] Lindström describes [498 B. 26, No. 11, '93] the streptococcus ruber isolated from a case of cystitis.

Pasquale [768 v.12,No.5,'98] divides the streptococci into the following classes:—

1. Short, saphrophytic streptococci.

AT LOW TEMPERATURES.	AT HIGH TEMPERATURES.
Fæces and other excretions.	Mouth and respiratory membranes.

2. Long, non-virulent streptococci.

Fæces (*e.g.*, *S. coli gracilis*).	Mouth-membrane.

3. Long, pathogenic streptococci.

Erysipelas.	Sputum of pneumonia.
Pus.	
Pneumonia.	
Diphtheria.	
Scarlet fever.	

4. Short, extremely infectious streptococci.

Tuberculosis, etc. (mixed infection).	Pneumonia.
Diplococcus pyogenes.	Diplococcus pneumoniæ.

Ch. Monod and Macaigne [91 Feb.10,'94] thus summarizes our present knowledge of the streptococcous infections: 1. Generalized streptococcous infection presents itself under two principal forms,—streptococcous septicæmia, and streptococcous pyæmia. Septicæmic infection can be easily determined by bacteriological examination upon the cadaver, and it is easy to establish that the presence of bacteria in the organs is not of cadaveric origin. Streptococcous septicæmia is sometimes primary, but most frequently secondary, as in general affections with local manifestations (diphtheria, scarlet fever, variola, etc.), where it is one of the principal causes of death, as a complication of a localized and usually curable streptococcous affection to which it gives a serious aspect, and which it brings to a fatal termination. It is in such cases that bacteriological examination of the organs demonstrates its existence. If this examination is negative, it is because death in such a local streptococcous infection is the result of an intoxication, of a toxæmia favored by the extension of the suppuration and the poor condition of the organs of elimination (liver and kidneys). From the anatomical point of view, there is found in the organs of septicæmic cases, aside from the lesions common to infectious diseases in general, only masses of streptococci producing no leucocytic

reaction in their neighborhood, and simply altering the cellular elements which surround them; when less virulent, the streptococcus carried by the blood localizes its hurtful action in a single organ (endocardium, vessels, kidneys), which reacts in its own way. Generally this localization is a suppuration either in one locality (phlegmon, arthritis) or in several; this is the purulent infection, or streptococcous pyæmia. The cause of streptococcous infection appears to be, in general, the great virulence of the bacterium.

Experimental and clinical observations demonstrate that this possible increase in the hurtful power of the streptococcus is due either to the medium (putrefaction) or to its association with other bacteria, especially with saprophytes. The place of entrance is usually easy to determine, being a cutaneous wound or lesion of the mucous membrane, traumatic or inflammatory (an angina, broncho-pneumonia, etc.). Sometimes it is indeterminate (suppuration of traumatic origin without wound, spontaneous pyæmia). The prognosis of a generalized streptococcous invasion is well known to be grave. The presence of the streptococcus in the blood, determined during life, does not imply an absolutely fatal prognosis, as spontaneous cure may occur or surgical interference bring about recovery. The gravity of the prognosis appears to depend upon the virulence of the pathogenic agent and the resistance of the organism,—this depending upon the integrity of the organs. Attention may again be called to the differentiation of the streptococci by Marot [2031 '98] into two classes that do and do not produce any visible colonies upon plates. (See ANNUAL, 1894.) Babès and Broca [1045 V.1,No.8,'94] describe streptococci concerned in cirrhosis of the liver and hæmorrhagic septicæmia. Heim [84 May 29,'94] describes his studies upon the streptococcus longus pyothorakos, Waldvogel [50 June 2,'94] the growth of the streptococcus longus in bouillon, and Widal and Besançon [14 July 29,'94] the normal and pathogenic streptococci of the mouth. Goldscheider and Reyschoot [114 B.26,H.1,2,'94] study very carefully the conditions under which the streptococci produce disease. Pasquale [50 p.116,'94] speaks of the streptococci occurring in tuberculous infection, and Pane [50 Aug.15,'94] the conditions under which the streptococcus pyogenes liquefies gelatin.

Sulphuretted hydrogen, as a bacterial product, has been studied by Orloosky, [586 No.48,'93] who emphasizes the fact that the typhoid bacillus develops it most abundantly in the presence of the lead

and iron salts, while the bacillus coli communis is most active in media containing nitroprussiate of sodium. He thinks that this biological difference settles in the negative the question of the identity of the two.

Suppuration.—Ceppi [214 Dec.1,'96] studied the action of a number of antiseptics upon one of the bacteria of suppuration, the albus, and lays especial stress upon the non-antiseptic action of carbolized oil and similar fatty mixtures with carbolic acid. Netter [14 May 20,'96] describes the lesions produced by inoculation of the pus from an old osteomyelitis, and discusses the possibility of the transformation of the streptococcus pyogenes albus into the aureus. Arloing [211 May 20,'96] considers the pathological and morphological variations of the active bacteria in purulent infection. Nannotti, [589 p.24,'96] in experimenting with the sterile products of suppurative bacteria, found fatty degeneration of kidneys and liver and, in general, analogous changes to those in septicæmia. Bernabeo, [50 Apr.27,'96] studying the means of defense of the organism against the bacteria of suppuration, concludes as follows: A suppurating spot lessens the physiochemiotactic power of the leucocytes for a definite distance from its edges; suppuration lessens the resisting power of the tissues to other infectious bacteria; the body has strong need of leucocytes and arms the blood against invasion by an increase of leucocytosis. Mueller [50 May 19,25,'96] gives an elaborate review of the present knowledge of suppuration, and concludes that, while pus has apparently been produced artificially by other agencies than bacteria, these results are of no importance practically, for the reason that suppuration never occurs in man except as the result of the activity of micro-organisms [a position also taken by me several years ago].

Tetanus.—Tizzoni and Centanni [4 B.50,No.51,'96] have made some important additions to our knowledge of the immunizing power of the antitoxin of tetanus, which they say can be used, either in the serum or after precipitation with alcohol. It can be kept as a dry powder and used, when needed, in solution. Buchner, [4 No.4,'96] in discussing the action of the tetanus antitoxin, states that this is not a product of the reaction of the tissues against the poison, but a bacterial product closely allied to the poison in its composition. Frothingham [5 May,'96] describes a new method for cultivating the tetanus bacillus, and Hewlitt [6 July 14,'96] another, either one of which may

be successfully employed. Righi [589 Sept.5,'94] publishes an interesting study of the biology of this bacterium.

Trichomycosis nodosa is again spoken of by Bergonzini [59 May 5,'94] in connection with a second case which he has studied, and in which he has found the fungus described by Behrend in 1866 and Juhel-Renoy in 1888, and which he wishes to call *Monidia tricophila.*

Tuberculosis.—A writer [22 Nov.1,'93] emphasizes the importance of using "tuberculin" in pure cases of tuberculosis *only.* Fever is produced by septic bacteria, and when it appears the case is one of mixed infection and tuberculin is quite entirely out of place. Marpmann [50 Aug.25,'93] has demonstrated the presence of the bacillus of tuberculosis in street-dust. The curative value of tuberculin in guinea-pigs affected experimentally with tuberculosis is studied by Czaplewski and Roloff. [50 Mar.16,'94] Kuehne [391 B.20,p.221,'94] has made some elaborate researches upon the proteids of tuberculin, and Kresling [69 Aug.20,'94] studies the biology and chemistry of the bacillus of tuberculosis and of glanders. Roth [214 Sept.1,'94] makes some observations on the presence of the bacillus of tuberculosis in butter. Lacour, [747 Jan.,'94] Ilkewitsch, [50 Feb.5,'94] and Van Ketel, [324 V.15,p.108] all give new or modified methods for staining the bacillus of tuberculosis. Of these we have had no experience, but a very fine result is to be obtained by using the method of Buttersack. [2138 '94]

Typhoid.—Comparatively little of importance has been produced upon this subject during the past year. Hintze, [50 Oct.10,'93] after a study of the vitality and pus-producing power of the typhoid bacillus in the human body, reaches the conclusions that (1) it can retain its vitality ten months in the human body; (2) long-continued post-typhoid suppuration may be produced by it; (3) it can cause a suppurative meningitis. Almquist [58 Oct.20,'93] says that the typhoid bacillus has two forms: the usual broad form, the other narrower; both can pass into each other, but usually remain the same. The bacteria develop not only by length, but also by lengthwise division. It does not grow so well in pure sand as when mixed with manure, and often does not retain its vitality for a long time; narrow rods and degeneration forms are often seen in this medium. In sand mixed with sufficient manure the bacillus retains its vitality for a long time and produces many spore-like bodies which can develop into new rods. Azro [996 Dec.10,'93] attempted to

determine if the bacillus coli communis assumed pathogenic powers in the presence of genuine pathogenic bacteria in the intestine, and concludes that, under normal physiological conditions, it is non-pathogenic, either because it cannot penetrate the intestinal wall or because its products are not absorbed any faster than they are excreted; but that this is changed when a bacterium capable of influencing the physiological functions of the body intervenes. A more rapid absorption then occurs and the bacillus coli communis may be capable of great damage. Especially did this appear to be the case with typhoid fever. Vincent $_{\text{Dec.21,29,'98}}^{164}$ presents a good review of the relation between the bacillus coli communis and the typhoid bacillus, and Schild $_{\text{Dec.2,'98}}^{50}$ emphasizes the use of formalin solutions as a means for the differential diagnosis between the two. Germano and Maurea $_{\text{v.12,No.2,'94}}^{768}$ lay stress upon the diagnostic value of the amount of gas-production in agar-agar with 2-per-cent. grape-sugar (this being better than cane) or milk-sugar mixtures. Fremlin $_{\text{v.19,No.3}}^{324}$ says the differentiation of the typhoid bacillus may be made by the motion of the typhoid bacillus, which is more active and extensive, shows a much greater tendency to form threads, while its growth on gelatin is distinctly slower. Colonies are almost invisible on potato, while the bacillus coli communis forms distinct orange streaks. The typhoid bacillus has no fermenting action, while the bacillus coli communis has; it does not curdle milk, as does the bacillus coli. It has many cilia, which may be shown in a week, while the bacillus coli has few,—which can be stained only with difficulty. The typhoid bacillus does not give the indol reaction with potassium nitrate, while the bacillus coli does. Other important studies have been made by Uffelmann, $_{\text{Feb.2,'94}}^{50}$ who concluded that it was possible for the typhoid bacillus to be carried by the air, and Dmochowski and Janowski, $_{\text{Feb.15,'94}}^{50}$ who show that under certain conditions it may produce pus.

Vaccine Virus.—The nature of vaccine immunity is studied by Kramer and Boyer $_{\text{Nov.4,'98}}^{2}$ in experiments upon the blood-serum of calves, and Juhel-Renoy $_{\text{Jan.10,'94}}^{31}$ takes up the same subject. Antony $_{\text{Mar.,'94}}^{245}$ studies the vaccinal micrococcus of Maljean, $_{\text{'98}}^{363}$ with non-confirmatory results. Danchez $_{\text{Apr.13,'94}}^{152}$ attempts to ascertain the duration of vaccine immunity and the causes of non-success in revaccinations. Levin, $_{\text{May 25,'94}}^{50}$ in considering the factors producing the specific and pathogenic activity of vaccine virus, tends to

the belief that it is in the nature of a serum treatment. Ernst reports the work of S. C. Martin, now deceased,[2139 M] which certainly has come nearer to the true solution of the problem than anything else yet published.

INDEX TO VOLUME FOURTH.

By N. I. DEVEREUX,

PARIS.

Acne....A- 1
necrotica....A- 2
rosacea....A- 7
treatment....A- 4
varioliformis, pilaris....A- 1
vulgaris....A- 6
Actinomycosis, bacillus....I- 7
Adenoid vegetations....D- 50
Adenoma sebaceum....A- 7
Albuminuria, retinitis in....B-144
Alcoholism and depopulation....H- 1
Alopecia....A- 8
areata....A- 9
from nasal treatment....D- 35
treatment....A- 10
Amaurosis, quinine....B-126
Amblyopia, tobacco....B-126
Ametropia....B- 24
Amœba....I- 7
Anæmia, optic neuritis in....B- 15
Anaërobic bacilli....I- 1
Angiokeratoma....A- 10
Angioma serpiginosum....A- 11
Anomalies of eye (see Eye)....B-
of nose....D- 1
Anophthalmos....B- 1
Anosmia....D- 33
Anthrax bacillus....I- 7
Antrum of Highmore, diseases....D- 37
empyema....D- 37
foreign bodies....D- 42
tumors....D- 41
Aphasia, disorders of pantomime in....G- 17
Asthenopia....B-27, 43
Asthma....D- 33
Astigmatism (see Eye)....B- 27
Atheroma....A- 11
Atrophy of skin....A- 12
Auricle, diseases....C- 1

Bacteriology....I- 1
actinomycosis....I- 7
amœba....I- 7
anaërobic bacilli....I- 1
anthrax....I- 7
blood....I- 2
carcinoma....I- 9
cellulose....I- 3
cholera....I- 11
chromogenic bacillus....I- 13
coli communis....I- 14
diphtheria....I- 14
general methods....I- 1
glanders....I- 15
gonorrhœa....I-6, 15
immunity....I- 16
infection....I- 18
influenza....I- 18
leprosy....I- 6
leptothrix buccalis....I- 18
light....I- 18
malaria....I- 18
methods of culture....I- 1
milk....I- 18
plague....I- 18
pneumonia....I-6, 19
protozoa....I- 19
pyocyaneus, bacillus....I- 19
serum....I- 20
staphylococcus....I- 20
streptococcus....I- 20
sulphuretted hydrogen....I- 22
suppuration....I- 23
tetanus....I- 23
trichomycosis nodosa....I- 24
Bacteriology, tuberculosis....I-5, 6, 24
typhoid fever....I- 24
vaccine virus....I- 25
Basedow's disease....F- 5
Baths, influence of, on microbes of skin....A- 54
Benzin, poisoning by....G- 22
Blepharitis....B- 56
Blindness, congenital....B-162
Blood, bacteriology....I- 2
in skin diseases....A- 54
in poisoning....G- 21
Blood-stains, bacteriology....I- 2
Brain, and aural disease....C-38, 50
tumors and ocular disease....B-155
Burns, death from....G- 4
Butter, bacteria in....I- 3

Cachexia thyreopriva....F- 9
Calculus, of soft palate....D- 60
of tonsils....D- 83
Carbolic acid, poisoning by....G- 23
Carbonic acid, poisoning by....G- 24
Carbonic oxide, poisoning by....G- 24
Carcinoma, bacteriology....I- 9
of skin....A- 13
Cataract....B- 92
Cellulose in bacilli....I- 3
Chalazia....B- 57
Chilblains....A- 14
Chloral, poisoning by....G- 27
Chloroform, poisoning by....G- 27
Cholera, bacteriology....I- 11
Cholesteatoma....C- 4
Chorea, ocular symptoms....B-160
Choroid, diseases (see Eye)....B-104
Chromogenic bacilli....I- 13
Ciliary body, diseases (see Eye)....B- 84
Coal-gas poisoning....G- 24
Coli communis, bacillus....I- 14
Color-blindness....B- 19
Conjunctiva, diseases (see Eye)....B- 61
Cornea and sclerotic, diseases (see Eye)....B- 75
Coryza (see Nasal cavities, diseases)....D- 4
Cretinism....F- 12
Crime, unsexing for....G- 21
Croup, intubation in....E- 1
Culture methods....I- 13
Cuneus, visual function....B- 21
Cysticercus, of eye....B-108
Cysts, of nasal cavities....D- 18

Dacryocystitis....B- 42
Darier's disease....A- 42
Deaf-mutism....C- 52
Deafness, traumatic....C-21, 50
Death, signs of....G- 12
sudden....G- 7
Degeneration and atavism....H- 6
Demography....H- 1
Depopulation of France....H- 1
Dermatitis....A- 14
exfoliativa....A- 17
herpetiformis....A- 14
medicamentosa....A- 15
of surgeons....A- 15
Dermatology (see Skin, diseases)....A- 1
Diabetes mellitus, and ocular disease....B-144
and pharyngitis....D- 74
and xanthoma....A- 54
Diaphanous test of death....G- 12
Diphtheria, bacteriology....I- 14
conjunctival....B- 66
Diphtheria, bacteriology, of auditory canal....C- 3
Distichiasis....B- 56

Ear, diseases....C- 1
external....C- 1
auricle....C- 1
diphtheria....C- 3
exostosis....C- 3
foreign bodies....C- 4
furuncles....C- 4
injuries....C-2; G- 11
Ear, internal....C- 47
brain-abscess....C- 50
deaf-mutism....C- 52
deafness, traumatic....C- 50
Ménière's disease....C- 47
tests for hearing....C- 51
Ear, mastoid....C- 22
cholesteatoma....C- 40
ligation of jugular....C- 39
mastoiditis....C- 41
necrosis....C- 36
points in diagnosis....C- 46
Stacke's operation....C- 22
Ear, middle....C- 5
deafness, traumatic....C- 21
excision of ossicles....C- 5
nasal disease and....D- 37
otitis media....C- 13
complicating infectious diseases....C- 17
from syphilis....C- 18
neurasthenic....C- 18
of influenza....C- 16
suppurative, operations....C- 13
therapeutics....C- 21
Ectropium....B- 59
Eczema....A- 19
seborrhœic....A- 19
treatment....A- 19
Electricity, death from....G- 5
England, mortality....H- 2
Entropium....E- 58
Epilepsy, from nasal disease....D- 34
ocular conditions....B-157
Epistaxis....D- 30
Epithelioma of the skin....A- 25
Erysipelas....A- 26
of larynx....D-101
Erythema....A- 28
elevatum diutinum....A- 28
induratum....A- 29
multiforme....A- 29
persistent....A- 29
Ethmoidal sinuses (see Nasal cavities, diseases)....D- 44
Exophthalmic goitre....F- 5
Exophthalmos....B- 35
Extra-ocular muscles (see Eye, diseases)....B- 43
Eye, diseases....B- 1
anomalies, embryology, histological anatomy....B- 1
anophthalmos....B- 1
coloboma, of choroid....B- 7
of fundus....B- 6
of iris....B- 4
conjunctiva....B- 9
lens, congenital dislocation....B- 6
nerve-fibres....B- 9
microcephalus....B- 1
muscles....B- 9
persistent pupillary membrane....B- 5
retina....B-9, 10
symmetrical zonular opacity....B- 5

Eye, diseases, choroid, diseases....B-104
choroiditis....B-104
coloboma....B-104
sarcoma....B-105
conjunctiva....B- 61
abscess....B- 66
absorbent power....B- 61
amyloid degeneration....B- 74
angioma....B- 72
chemosis....B- 62
conjunctivitis, bullous....B- 62
in newborn....B- 63
pseudomembranous....B- 66
purulent....B- 64
fibrosarcoma....B- 73
lymphosarcoma....B- 73
papilloma....B- 73
pemphigus....B- 62
pterygium....B- 74
sarcoma....B- 73
syphilis....B- 72
trachoma....B- 68
cornea and sclerotic....B- 75
blennorrhœa....B- 75
episcleritis....B- 81
epithelioma....B- 82
foreign bodies....B- 75
herpes....B- 80
keratitis....B- 76
aspergillar....B- 80
filamentary....B- 77
hypopyon....B- 78
interstitial....B- 78
parenchymatous....B- 78
punctate....B- 76
strumous....B- 79
keratoconus....B- 80
keratomalacia....B- 78
keratoplasty....B- 83
papilloma....B- 84
polypus....B- 84
scleritis....B- 83
ulcer....B- 81
extra-ocular muscles....B- 43
asthenopia....B- 43
cyclophoria....B- 47
heterophoria....B-43, 47
instruments....B- 54
paralysis....B- 51
strabismus....B- 49
glaucoma....B-133
instruments....B-171
iris and ciliary body....B- 84
corectopia....B- 85
ectropion of uvea....B- 84
foreign bodies....B- 85
iridodialysis....B- 87
iritis....B- 85
syphilis....B- 88
tubercle....B- 89
tumors....B-88, 90
lachrymal apparatus....B- 40
actinomycosis....B- 42
dacryocystitis....B- 42
fistula....B- 41
infection....B- 40
kerato-conjunctivitis....B- 41
obstruction....B- 43
stricture....B- 42
tumor....B- 41
lens....B- 91
cataract....B- 92
congenital....B- 92
incipient....B- 94
senile....B- 93
traumatic....B- 97
dislocation....B- 97
lenticonus....B- 92
opacity....B-103
removal of lens for myopia....B- 97
spontaneous absorption....B-104
lids, diseases....B- 56
blepharitis....B- 56
blepharo-phimosis....B- 59
chalazion....B- 57
chancre....B- 56
cylindroma....B- 60
distichiasis....B- 58
ectropium....B- 59
entropium....B- 58
epicanthus....B- 57
epithelioma....B- 61
foreign bodies....B- 56
ptosis....B- 60
sarcoma....B- 61
trichiasis....B- 58
medical ophthalmology....B-138
albuminuria....B-144
anæmia....B-151
Eye, diseases, medical ophthalmology, blindness, congenital....B-162
cardiac diseases....B-140
cerebral disease....B-147, 153
chorea....B-160
dental affections....B-36, 119
diabetes....B-144
diphtheria....B-140
epilepsy....B-156, 160
exposure to sun....B-161
general paresis....B-157
genito-urinary disease....B-139
Gerlier's disease....B-150
goitre....B-148, 162
herpes....B-148
hysteria....B-151
icterus....B-140
impetigo contagiosum....B-139
influenza....B-145
lactation....B-147, 161
lead poisoning....B-147
malaria....B-140
menstruation....B-146
nasal diseases....B-138; D- 36
neurasthenia....B-151
paralysis....B-148
pharyngeal disease....B-138
puerperal fever....B-147
sclerosis....B-161
septicæmia....B-144
syphilis....B-141, 157
tabes....B-156
tape-worm....B-139
tuberculosis....B-143
varioloid....B-144
optic nerve, diseases....B-119
and cranial deformity....B-124
atrophy....B-119
choked disc after tooth extraction....B-119
hyaline formations....B-120
neuritis....B-120
retrobulbar....B-125
quinine amaurosis....B-126
toxic amblyopia....B-126
tumors....B-121
orbit, diseases....B- 34
cellulitis....B- 36
cyst, dermoid....B- 38
exophthalmos....B- 35
foreign bodies....B- 34
injuries....B- 35
necrosis....B- 40
phlebitis....B- 38
proptosis....B- 37
tumors....B- 38
physiology....B- 11
accommodation....B- 15
ametropia, emmetropia....B- 19
cuneus....B- 21
examination of color-sense....B-17, 19
exit of fluid....B- 11
eye-movements....B- 13
light-sense....B- 18
orbicularis palpebrarum....B- 12
secondary images....B- 21
temperature of conjunctival sac..B- 11
refraction and accommodation....B- 24
ametropia....B- 33
asthenopia....B- 27
astigmatism....B-27, 29
myopia....B-25, 31
retinoscopy....B- 28
skiascopy....B- 29
retina, diseases....B-108
detachment....B-111
eclipse blindness....B-108
emboli....B-116
glioma....B-117
hæmorrhage....B-111
retinitis, albuminuric....B-113
circinata....B-114
hæmorrhagic....B-113
pigmentosa....B-116
syphilitic....B-113
thrombosis....B-116
tumors....B-117
varicose dilatation of veins....B-115
therapeutics....B-163
vitreous, diseases....B-106
anomalies....B-107
cysticercus....B-108
filaria....B- 95
foreign bodies....B-106
wounds, injuries, and foreign bodies....B-127

Favus....A- 48
Folliculitis....A- 30
France, depopulation of....H- 1
Frontal sinus, diseases (see Nasal cavities, diseases)....D- 43

General paralysis, ocular conditions.B-157
Gerlier's disease, ocular symptoms...B-150
Germany, mortality....H- 3
Gland, thyroid (see Thyroid gland)..F- 1
Glanders, bacteriology....I- 15
Glaucoma....B-133
Glycosuria in urticaria....A- 52
from nasal disease....D- 34
Goitre....F- 3
cases....F- 3
eyes in....B-149
histology and histogenesis....F- 3
symptoms....F- 4
treatment....F- 4
Goitre, exophthalmic....F- 5
etiology and pathology....F- 5
symptoms....F- 7
treatment....F- 8
Gonorrhœa, bacillus....I-6, 15
latent....G- 14
Graves's disease (see Goitre, exophthalmic)....F- 5

Hanging....G- 3
Hay fever....D- 32
Heart affections, ocular manifestations....B-140
sudden death in, legal aspects....G- 7
Hemianopsia....B-153
Herpes corneæ....B-80, 146
Herpes ophthalmicus....B-148
Herpes zoster....A- 31
Heterophoria....B- 43
Hodgkin's disease, myxœdema in....F- 12
Hydroa vacciniforme....A- 32
Hymen, unruptured....G- 13
Hyperidrosis....A- 32
Hysteria and ocular affections...B-139, 151

Ichthyosis congenita....A- 33
Icterus and keratomalacia....B-140
Identification of criminals....G- 19
Immunity....I- 16
Impetigo contagiosum and ocular disease....B-139
India, population....H- 4
Infant mortality....H- 2
Infection....I- 18
Influenza, and eye diseases....B-145
goitre following....F- 7
otitis media in....C- 16
Insanity and crime....G- 16
Intubation of the larynx....E- 1
in chronic stenosis....E- 6
retained intubation tube....E- 8
Intussusception and purpura....A- 44
Iodoform dermatitis....A- 16
Irido-choroiditis....B-104
Iris and ciliary body, diseases (see Eye)....B- 84
Italy, population....H- 3

Keloid....A- 33
Keratitis....B- 77
Keratoconus....B- 80

Lachrymal apparatus, diseases (see Eye)....B- 40
Lactation, blindness during....B-146
optic neuritis during....B-160
Larvæ in nose....D- 21
Laryngismus stridulus....D-109
Larynx, diseases....D- 84
anatomy and physiology....D- 84
erysipelas....D-101
foreign bodies....D-102
fracture....D-104
laryngectomy....D-122
laryngismus stridulus....D-109
laryngitis....D- 87
chronic....D- 87
chronic hypertrophic....D- 87
tuberculous....D- 90
laryngo-scleroma....D-102
leprosy....D-101
œdema....D- 86
pachydermia....D- 79
paralysis....D-105
stenosis....D- 89
syphilis....D- 87
syphilo-tuberculosis....D- 88
tracheotomy....D-119
tumors....D-110
Larynx, intubation of....E- 1
for croup....E- 1

Larynx, intubation of, for stenosis...E- 6
retained tubes...E- 8
Larynx, trachea, and œsophagus, diseases...D- 1
Lead poisoning, eyes in...B-147
Legal medicine...G- 1
burning...G- 4
electricity as a cause of death...G- 5
hanging...G- 3
insanity...G- 16
disorders of pantomime...G- 17
handwriting...G- 19
identification...G- 19
litigiousness...G- 18
menstruation...G- 18
pyromania...G- 20
latency of gonorrhœa...G- 14
prostitution...G- 14
signs of death...B-163; G- 12
signs of virginity...G- 13
sudden death...G- 7
suicide...G- 1
unsexing for crime...G- 21
wounds...G- 9
Legal medicine and toxicology...G- 1
Lens, diseases (see Eye)...B- 91
Leprosy...A- 33
bacteriology...I- 6
of larynx...D-101
Leptothrix buccalis...I- 18
Lichen, planus...A- 35
scrofulosorum...A- 35
simplex acutus...A- 36
Lids, diseases (see Eye)...B- 56
Light, effect of, on bacteria...I- 18
Lingual tonsil, diseases...D- 60
Lupus, erythematosus...A- 37
of nasal cavities...D- 12
vulgaris...A- 38
Lysol, poisoning by...G- 28

Malaria, bacteriology...I- 18
blindness in...B-140
Marriage and fecundity...H- 5
Mastoid, diseases...C- 22
Medical demography...H- 1
anthropology and ethnology...H- 6
degeneration and atavism...H- 6
general statistics...H- 3
marriage, fecundity, etc...H- 5
occupation and mortality...H- 4
pathology of tropics...H- 6
population and depopulation...H- 1
Meibomian glands, epithelioma...B- 61
Melinite, poisoning by...G- 28
Ménière's disease...C- 47
Menstruation, and ocular affections...B-146
mental responsibility during...G- 18
Microcephalus...B- 1
Milk, bacteria...I- 18
Morphine, poisoning by...G- 28
Mycosis of pharynx...D- 68
Myiasis nasalis...D- 21
Myopia...B- 24
Myxœdema...F- 9
complications...F- 11
pathology...F- 9
symptoms...F- 10
treatment...F- 11

Nævus...A- 39
Nasal cavities, diseases...D- 1
accessory cavities...D- 37
empyema of antrum...D- 37
iritis from...B- 36
ethmoidal sinus...D- 44
foreign bodies in antrum...D- 42
frontal sinus...D- 43
sphenoid sinus...D- 45
tumors of antrum...D- 41
anæsthetics...D- 58
anatomy and physiology...D- 1
anterior cavities...D- 1
cysts...D- 18
epistaxis...D- 30
foreign bodies...D- 20
lupus...D- 12
miscellaneous...D- 57
myiasis...D- 21
papilloma...D- 19
polypus...D- 15
rhinitis, acute...D- 3
atrophic...D- 7
fibrinous...D- 13
hypertrophic...D- 5
syphilitic...D- 10
tuberculous...D- 20
rhinoliths...D- 20
rhinoscleroma...D- 13
Nasal cavities, diseases, anterior cavities, sarcoma...D- 20
septum, diseases...D- 22
abscess, perichondritis, perforations...D- 23
congenital occlusion...D- 29
deviations, crests, spurs...D- 23
tumors...D- 27
tuberculosis...D- 11
bacteriology...D- 2
histology...D- 1
neuroses...D- 32
anosmia...D- 33
asthma...D- 33
aural...D- 36
cutaneous disorders...D- 34
epilepsy...D- 34
glycosuria...D- 34
hay fever...D- 32
ocular...B-138; D- 36
psychoses...D- 34
torticollis...D- 34
Nasal and accessory cavities, pharynx, larynx, trachea, and œsophagus...D- 1
Naso-pharynx, diseases...D- 47
adenoid vegetations...D- 50
tuberculosis...D- 47
tumors...D- 47
Negroes and disease...H- 8
Nephritis from tonsillar disease...D- 74
Neurasthenia, eyes in...B-151
aural...C- 18
Neuritis, optic...B-120
Newborn, mortality...H- 2
Nitrobenzol, poisoning by...G- 31
Nose as a racial test...H- 8
Nose, diseases of (see Nasal cavities).D- 1
Nystagmus congenital...B-150

Œsophagus, diseases...D-126
dilatation...D-127
diverticula...D-128
œsophagitis...D-127
rupture...D-131
stricture...D-128
malignant...D-130
syphilitic...D-131
tuberculosis...D-131
varices...D-131
Ophthalmia neonatorum...B- 63
Ophthalmology (see Eye, diseases)...B- 1
Ophthalmoplegia...B-141
congenital external...B-148
Optic nerve, diseases (see Eye)...B- 34
Orbit, diseases (see Eye)...B- 34
Ossicles, excision...C- 5
Otitis media...C- 5
Otology (see Ear, diseases)...C- 1
Ozæna (see Rhinitis, atrophic)...D- 7

Pachydermia laryngis...D-116
Palate, soft, diseases...D- 58
anatomy and physiology...D- 58
calculus...D- 60
neuroses...D- 59
tumors...D- 59
Pancreatitis, sudden death from...G- 9
Papilloma of nasal cavities...D- 19
Paralysis, general, eye symptoms...B-157
of larynx...D-105
ocular...B-51, 148
Perichondritis of septum...D- 22
Permanganate of potassium, in opium poisoning...G- 29
Pharynx, diseases...D- 61
anatomy...D- 61
foreign bodies...D- 70
membranous pharyngitis...D- 62
mycosis...D- 68
neuroses...D- 70
retropharyngeal abscess...D- 69
rheumatic pharyngo-tonsillitis...D- 65
syphilis...D- 63
tumors...D- 67
tympanic suppuration after operation...C- 20
Phosphorus, poisoning by...G- 31
Pityriasis rubra...A- 39
Plague, bacteriology...I- 18
Pneumonia, bacteriology...I-6, 19
purpura complicating...A- 44
thyroid abscess following...F- 3
tonsillar disease and...D- 73
Prostitution, control...G- 14
Protozoa...I- 19
Prurigo...A- 40
Prussic acid, poisoning by...G- 35
Psoriasis...A- 40
Psorospermosis...A- 42
Psychoses from nasal disease...D- 34
in Graves's disease...F- 7
Pterygium...B- 74
Ptosis...B- 60
Puerperal fever, choroiditis in...B-147
Purpura...A- 43
hæmorrhagica...A- 43
Pyocyaneus, bacillus...I- 19
Pyromania...G- 20

Refraction and accommodation (see Eye)...B- 24
Retina, diseases (see Eye)...B-108
Retinoscopy...B- 28
Retropharyngeal abscess...D- 69
Rheumatism and tonsillar disease...D- 73
Rhinitis...D- 3
acute...D- 3
in children...D- 3
atrophic...D- 7
hypertrophic...D- 5
syphilitic...D- 10
tuberculous...D- 11
Rhinoliths...D- 20
Rhinoscleroma...D- 13
Ringworm...A- 47

Scleroderma...A- 44
Sclerosis, disseminated, eyes in...B-161
Septum, diseases (see Nasal cavities)...D- 22
Serum, bactericidal action...I- 20
Sign of death...B-163; G- 12
Skin, bacteria...A- 54
Skin, diseases...A- 1
acne...A- 1
necrotica...A- 2
rosacea...A- 7
treatment...A- 4
urticaria...A- 3
varioliformis, pilaris...A- 1
vulgaris...A- 7
adenoma sebaceum...A- 7
alopecia...A- 8
areata...A- 9
treatment...A- 10
and nasal disease...D- 34
angiokeratoma...A- 10
angioma serpiginosum...A- 11
atheroma...A- 11
atrophy...A- 12
blood in...A- 54
burns...A- 12
cancer...A- 13
chilblains...A- 14
dermatitis, exfoliativa...A- 17
herpetiformis...A- 14
of surgeons...A- 15
eczema...A- 19
seborrhœic...A- 19
treatment...A- 20
epithelioma...A- 25
erysipelas...A- 26
from ear-piercing...C- 2
erythema, elevatum diutinum...A- 28
induratum...A- 29
multiforme...A- 29
persistent...A- 29
favus...A- 48
folliculitis...A- 30
herpes zoster...A- 31
hydroa vacciniforme...A- 32
hyperidrosis...A- 32
ichthyosis congenita...A- 33
impetigo contagiosum and ocular disease...B-139
keloid...A- 33
leprosy...A- 33
lichen, planus...A- 35
scrofulosorum...A- 35
simplex acutus...A- 36
lupus, erythematosus...A- 37
from ear-piercing...C- 2
vulgaris...A- 38
nævus...A- 39
pityriasis rubra...A- 39
versicolor...A- 40
prurigo...A- 40
psoriasis...A- 40
psorospermosis...A- 42
purpura...A- 43
scleroderma...A- 44
tinea...A- 44
capitis...A- 49
tonsurans...A- 45
tricophyton...A- 45
tylosis...A- 49
ulcers...A- 49

Skin, diseases, urticaria....A- 51
xanthoma....A- 53
Soft palate, diseases....D- 58
Sphenoidal sinus, diseases (see Nasal cavities, diseases)....D- 45
Staphylococcus....I- 20
Strabismus....B- 49
Stramonium, poisoning by....G- 36
Streptococcus....I- 20
Strychnia, poisoning by....G- 37
Suicide....G- 1
Sulphuretted hydrogen, from bacteria I- 22
Syphilis, and eye disease....B-141
of larynx....D- 87
of nasal cavities....D- 10
of pharynx....D- 63
of tonsils....D- 81
otitis media from....C- 18

Tabes dorsalis, eye complications....B-156
Tape-worm and ocular affections....B-139
Teeth, and ocular affections....B-36, 119
in different races....H- 9
Tetanus, bacillus....I- 23
Thyroid gland, diseases....F- 1
anatomy and physiology....F- 1
cretinism....F- 12
goitre....F- 3
cases....F- 3
histology and histogenesis....F- 3
symptoms....F- 4
treatment....F- 4
goitre, exophthalmic....F- 4
etiology and pathology....F- 5
symptoms....F- 7
treatment....F- 8
myxœdema and cachexia thyreopriva....F- 9
complications....F- 11
Thyroid gland, diseases, myxœdema and cachexia thyreopriva, symptoms....F- 10
treatment....F- 11
Tinea....A- 44
capitis....A- 49
tonsurans....A- 45
trichophyton....A- 45
Tonsil, lingual, diseases....D- 60
abscess....D- 61
hypertrophy....D- 60
tumors....D- 61
Tonsils, diseases....D- 71
and remote disorders....D- 72
bacteriology....D- 71
calculus....D- 83
hypertrophy....D- 77
syphilis....D- 81
tonsillitis....D- 77
follicular....D- 75
phlegmonous....D- 76
tuberculosis....D- 80
tumors....D- 82
Torticollis from nasal disease....D- 34
Toxicology....G- 21
benzin....G- 22
blood in poisoning....G- 21
carbolic acid....G- 23
carbonic acid....G- 24
carbonic oxide....G- 24
chloral hydrate....G- 27
chloroform....G- 27
forced respiration....G- 27
lysol....G- 28
melinite....G- 28
morphine....G- 28
nitrobenzol....G- 30
phosphorus....G- 31
prussic acid....G- 35
stramonium....G- 36
Toxicology, strychnine....G- 37
Trachea, diseases....D-125
compression....D-126
tumors....D-125
ulceration....D-125
Tracheotomy (see Larynx)....D-119
Trachoma....B- 68
Trepanation in prehistoric times....H- 9
Trichiasis....B- 58
Trichomycosis nodosa....I- 24
Trichophyton....A- 45
Tropics, demography....H- 6
Tuberculosis, and occupation....H- 4
bacteriology....I-5, 6, 24
of eye....B-89, 143
of larynx....D- 90
of nasal cavities....D- 11
of naso-pharynx....D- 47
of œsophagus....D-131
of pharynx....D- 64
of tonsils....D- 80
Tylosis of palms and soles....A- 49
Tympanum, suppuration after pharyngeal operation....C- 20
Typhoid fever, bacteriology....I- 24
and Europeans in India....H- 6

Ulcers....A- 49
Urticaria....A- 51
Uvula, diseases....D- 60
papilloma....D- 60

Vaccine virus....I- 25
Varices of œsophagus....D-131
Varioloid, chorio-retinitis in....B-144
Vertigo, aural....C- 48
Virginity, signs of....G- 13
Vitreous, diseases (see Eye)....B-106

Xanthoma....A-53

REFERENCE LIST.

JOURNALS.

1. New York Medical Journal.
2. British Medical Journal, London.
3. La semaine médicale, Paris.
4. Berliner klinische Wochenschrift, Berlin.
5. American Journal of the Medical Sciences, Philadelphia.
6. Lancet, London.
7. Bulletin de la Société anatomique, Paris.
8. Wiener klinische Wochenschrift, Vienna.
9. Medical News, Philadelphia.
10. Bulletin de l'Académie de médecine de Paris.
11. Journal of Laryngology, London.
12. New Orleans Medical and Surgical Journal, New Orleans.
13. Schmidt's Jahrbücher, Leipzig.
14. Le bulletin médical, Paris.
15. Practitioner, London.
16. Dublin Journal of Medical Sciences.
17. L'Union médicale, Paris.
18. L'Encéphale, Paris.
19. Medical and Surgical Reporter, Philadelphia.
20. Virchow's Archiv für pathologische Anatomie und Physiologie und für klinische Medicin, Berlin.
21. St. Petersburger medicinische Wochenschrift, St. Petersburg.
22. Medical Press and Circular, London.
23. Annals of Gynæcology and Pædiatry, Philadelphia.
24. Journal de médecine, Paris.
25. Archives cliniques de Bordeaux.
26. Provincial Medical Journal, Leicester, England.
27. American Journal of Obstetrics, New York.
28. Monatshefte für praktische Dermatologie, Hamburg,
29. Archiv für mikroskopische Anatomie, Bonn.
30. Annali di ottalmologia, Pavia.
31. La médecine moderne, Paris.
32. Birmingham Medical Review, Birmingham, England.
33. Bulletin médical des Vosges, Rambervillers.
34. Münchener medicinische Wochenschrift, Munich.
35. Revue gén. de clin. et de thér. jour. des praticiens, Paris.
36. Edinburgh Medical Journal, Edinburgh.
37. Annales des maladies de l'oreille, du larynx, du nez et du pharynx, Paris.
38. Asclepiad, London.
39. Canadian Practitioner, Toronto.
40. Gaillard's Medical Journal, N. Y.
41. Deutsche medizinal-Zeitung, Berlin.
42. Internationales Centralblatt für Laryngologie, Rhinologie, und verwandte Wissenschaften, Berlin.
43. North Carolina Medical Journal, Wilmington, N. C.
44. Southern California Practitioner, Los Angeles.
45. Archiv für Dermatologie und Syphilis, Vienna.
46. Marseille-médical, Marseilles.
47. Brain, London.
48. Annales de gynécologie et d'obstetrique, Paris.
49. British Gynæcological Journal, London.
50. Centralblatt für Bakteriologie und Parasitenkunde, Jena.
51. Archives of Pediatrics, Philadelphia.
52. Bulletin de l'Académie royale de médecine de Belgique, Bruxelles.
53. Cincinnati Lancet-Clinic, Cincinnati.
54. Fortschritte der Medicin, Berlin.
55. Gazette médicale de Paris.
56. Indiana Medical Journal, Indianapolis.
57. Internationale klinische Rundschau, Vienna.
58. Zeitschrift für Hygiene und Infectionskrankheiten, Leipzig.
59. Medical Record, New York.
60. Mittheilungen aus der dermatologischen Klinik der Charité, Berlin.
61. Journal of the American Medical Association, Chicago.

62. Annales de la polyclinique de Paris.
63. Revue pratique d'obstétrique et d'hygiène de l'enfance, Paris.
64. Medical Abstract, New York.
65. St. Louis Courier of Medicine.
66. Archives of Otology, New York.
67. Bulletin général de thérapeutique, Paris.
68. Centralblatt für Nervenheilkunde, Psychiatrie und gerichtliche Psychopathologie, Coblenz.
69. Deutsche medicinische Wochenschrift, Leipzig.
70. Gazette hebdomadaire des sciences médicales de Bordeaux.
71. American Therapist, New York.
72. Kansas City Medical Index, Kansas City, Mo.
73. Le progrès médical, Paris.
74. Memphis Medical Monthly, Memphis, Tenn.
75. Neurologisches Centralblatt, Leipzig.
76. Ophthalmic Review, London.
77. Pacific Medical Journal, San Francisco.
78. Revue générale d'ophtalmologie, Paris.
79. Sanitarian, New York.
80. Therapeutic Gazette, Detroit.
81. Virginia Medical Monthly, Richmond.
82. Medical Review, St. Louis.
83. Zeitschrift für physiologische Chemie, Strassburg.
84. Wiener medizinische Wochenschrift, Vienna.
85. Texas Courier-Record, Dallas, Tex.
86. Southern Practitioner, Nashville, Tenn.
87. Revue médico-pharmaceutique, Constantinople.
88. Prager medicinische Wochenschrift, Prague.
89. Archivos de ginecol. y pediat., Barcelona.
90 Medical Chronicle, Manchester.
91. Revue de chirurgie, Paris.
92. Revue de médecine, Paris.
93. Sanitary Journal, Glasgow.
94. Archives de neurologie, Paris.
95. Archiv für Gynækologie, Berlin.
96. Annals of Surgery, Philadelphia.
97. Mesdunarodnaja klinika, Warsaw.
98. Alienist and Neurologist, St. Louis.
99. Boston Medical and Surgical Journal.
100. Gazette des hôpitaux, Paris.
101. International Journal of Surgery, New York.
102. Kansas City Medical Record, Kansas City, Mo.
103. Medical Classics, New York.
104. Maryland Medical Journal, Baltimore.
105. Northwestern Lancet, St. Paul, Minn.
106. Omaha Clinic, Omaha, Neb.
107. Pacific Record of Medicine and Surgery, San Francisco.
108. Revue de thérapeutique médico-chirurgicale, Paris.
109. St. Louis Medical and Surgical Journal, St. Louis.
110. Texas Health Journal, Dallas, Tex.
111. União médico, Rio de Janeiro.
112. University Medical Magazine, Philadelphia.
113. Wiener medizinische Presse, Vienna.
114. Zeitschrift für klinische Medicin, Berlin.
115. Western Medical Reporter, Chicago.
116. Therapeutische Monatshefte, Berlin.
117. Southern Medical Record, Atlanta.
118. Revue mensuelle des maladies de l'enfance, Paris.
119. Philadelphia Polyclinic.
120. Nashville Journal of Medicine and Surgery, Nashville, Tenn.
121. Medical Bulletin, Philadelphia.
122. L'Union médicale du Canada, Montreal.
123. Korrespondenzblatt der aerztlichen kreis- und bezirks- Vereine im Königreich Sachsen, Leipzig.
124. Anti-Adulteration Journal, Philadelphia.
125. Hall's Journal of Health, New York.
126 Revue des sciences médicales en France et à l'étranger, Paris.
127. Gazette médicale de Nantes.
128. Medical Era, St. Louis.
129. Dosimetric Medical Review, N. Y.
130. Canada Medical Record, Montreal.
131. Bristol Medico-Chirurgical Journal, Bristol, England.
132. Archives of Gynæcology, N. Y.
133. Medicinisches Correspondenz-Blatt des württembergischen ärztlichen Landesvereins, Stuttgart.
134. The Doctor of Hygiene, New York.
135. The Analyst, London.

136. Revue de laryngologie, d'otologie et de rhinologie, Paris.
137. Practice, Richmond, Va.
138. New England Medical Monthly, Bridgeport, Conn.
139. Medical Standard, Chicago.
140. Annali de freniatria, Torino.
141. Herald of Health, London.
142. Gazette médicale de l'Algérie, Algiers.
143. Texas Medical Journal, Austin, Tex.
144. College and Clinical Record, Philadelphia.
145. Revista de medicina y farmacia, Paris.
146. Abstract of Sanitary Reports, Washington, D. C.
147. Occidental Medical Times, Sacramento, Cal.
148. Revue médico-chirurgicale des maladies des femmes, Paris.
149. Abstract and Index, Weston, Vermont.
150. Medicinische Monatsschrift, N. Y.
151. Epitome of Medicine, New York.
152. La France médicale et Paris médical, Paris.
153. Journal d'hygiène, Paris.
154. Gazette de gynécologie, Paris.
155. Denver Medical Times, Denver, Col.
156. Chemist and Druggist, London.
157. Brooklyn Medical Journal, Brooklyn.
158. Archiv für Kinderheilkunde, Stuttgart.
159. Sanitary News, Chicago.
160. Revue médicale de Toulouse.
161. Pittsburgh Medical Review, Pittsburgh.
162. Nouvelles archives d'obstétrique et de gynécologie, Paris.
163. Medical Missionary Record, New York.
164. La tribune médicale, Paris.
165. Journal de l'anatomie et de la physiologie normales et pathologiques de l'homme et des animaux, Paris.
166. Journal of Mental Science, London.
167. Druggists' Bulletin, Detroit.
168 Gazette médicale de Strasbourg, Strasbourg.
169. Centralblatt für die gesammte Therapie, Vienna.
170. Buffalo Medical and Surgical Journal.
171. Annales d'oculistique, Paris.
172. Sanitary Era, New York.
173. Recueil d'ophtalmologie, Paris.
174. Ceylon Medical Journal, Colombo.
175. Nice-médical, Nice.
176. Medical Summary, Philadelphia.
177. Le praticien, Paris.
178. Journal of Physiology, Cambridge, England.
179. Gaceta médica de México.
180. Centralblatt für die gesammte Medicin, Leipzig.
181. Bulletin médical du nord, Lille.
182. Archiv für Physiologie, Leipzig.
183. Sanitary Inspector, Augusta, Me.
184. Revue médicale de l'est, Nancy, France.
185. Physician and Surgeon, Ann Arbor, Mich.
186. Medical World, Philadelphia.
187. Liverpool Medico-Chirurgical Journal, Liverpool.
188. Journal de médecine de Bordeaux.
189. Gesundheit, Frankfurt a. M
190. Centralblatt für praktische Augenheilkunde, Leipzig.
191. Journal de la santé publique, Paris.
192. Chicago Medical Times.
193. Moniteur de thérapeutique, Paris.
194. Bulletins et mémoires de la Société obstétricale et gynécologique, Paris.
195. Archives de médecine navale, Paris.
196. Southern Clinic, Richmond, Va.
197. Revue médicale de la Suisse romande, Geneva.
198. Progress, Louisville, Ky.
199. Medical Brief, St. Louis.
200. Sei-I-Kwai Medical Journal, Tokyo.
201. Journal de la Société de médecine de l'Isère.
202. Medical Age, Detroit.
203. La normandie médicale, Rouen.
204. Archiv für Ophthalmologie (Gräfe), Leipzig.
205. Centralblatt für allgemeine Gesundheitspflege, Bonn.
206 Indian Medical Gazette, Calcutta.
207. Atlanta Medical and Surgical Journal.
208. Revue scientifique, Paris.
209. Pharmaceutische Zeitschrift für Russland, St. Petersburg.
210 Medico-Legal Journal, New York.
211. Lyon médical, Lyons.

212. Journal de médecine et de chirurgie pratiques, Paris.
213. Glasgow Medical Journal, Glasgow, Scotland.
214. Correspondenz-blatt für schweizer Aerzte, Basel.
215. Studies from the Biological Laboratory of Johns Hopkins University, Baltimore.
216. Albany Medical Annals, Albany, New York.
217. Beiträge zur Augenheilkunde, Hamburg.
218. Milwaukee Medical Journal, Milwaukee, Wis.
219. La clinique, Bruxelles.
220. Journal des sciences médicales de Lille.
221. Gazette médicale de Montréal.
222. Cleveland Medical Gazette, Cleveland, Ohio.
223. Bulletin de la Société des médecins et naturalistes de Jassy, Roumania.
224. American Practitioner and News, Louisville, Ky.
225. Le Poitou médical, Poitiers.
226. Archiv f. klinische Chirurgie, Berlin.
227. Leonard's Illustrated Medical Journal, Detroit.
228. La Loire médicale, Saint-Etienne.
229. Journal of Medicine and Dosimetric Therapeutics, London.
230. Gaz. médicale de Picardie, Amiens.
231. Cook County Hospital Reports, Chicago.
232. Gazette médicale d'Orient, Constantinople.
233. Columbus Medical Journal, Columbus, Ohio.
234. American Lancet, Detroit.
235. China Medical Missionary Journal, Shanghai.
236. Archives de tocologie et de gynécologie, Paris.
237. American Journal of Pharmacy, Philadelphia.
238. Chemical News, London.
239. Indian Medical Record, Calcutta.
240. Virchow und Hirsch's Jahresbericht über die Fortschritte der Anatomie und Physiologie, Berlin.
241. Revue de l'hypnotisme et de la psychologie physiologique, Paris.
242. Journal of Nervous and Mental Disease, New York.
243 Archives de médecine et de pharmacie militaires, Paris.
244. L'électrothérapie, Paris.
245. Journal of Cutaneous and Genito-Urinary Diseases, New York.
246. Archiv für die Gesammte Physiologie, Bonn.
247. The Journal of Pathology and Bacteriology, Edinburgh and London.
248. Journal of Morphology, Boston.
249. Archives of Ophthalmology, New York.
250. Archives de l'anthropologie criminelle et des sciences pénales, Paris.
251. Annals of Hygiene, Philadelphia.
252. Zeitschrift für Medicinalbeamte, Berlin.
253. Journal d'oculistique et de chirurgie, Paris.
254. Archiv für Augenheilkunde, Wiesbaden.
255. Jäger's Monattsblatt, Stuttgart.
256. Journal d'accouchements, Liége.
257. Canada Lancet, Toronto.
258. Medical Temperance Journal, London.
259. Clinica Chirurgica, Milan.
260. American Monthly Microscopical Journal, Washington, D. C.
261. Journal of the New York Microscopical Society, New York.
262. Annales de l'Institut Pasteur, Paris.
263. American Journal of Psychology, Worcester, Mass.
264. Nursing Record, London.
265. Centralblatt für Physiologie, Vienna.
266. Annales des maladies des organes génito urinaires, Paris.
267. Australasian Medical Gazette, Sydney.
268. O correio médico, Lisbon.
269. Journal of the National Association of Railway Surgeons, Fort Wayne, Ind.
270. L'organe de la confraternité médicale, Bruxelles.
271. Biblioteka Vracha, Moscow.
272. South African Medical Journal, Cape Colony, S. A.
273. Archiv für experimentelle Pathologie und Pharmacie, Leipzig.
274. Archives d'ophtalmologie, Paris.
275. The Scalpel, Calcutta.
276. Al Shifa, Cairo.

277. Journal of Anatomy and Physiology, London.
278. American Journal of Insanity, Utica, N. Y.
279. Medical Herald, Louisville, Ky.
280. Annales de la Société d'anatomie pathologique, Bruxelles.
281. Medical Advance, Chicago.
282. Montreal Medical Journal, Montreal.
283 Allgemeiner Wiener medizinische Zeitung, Vienna.
284. Maritime Medical News, Halifax, N. S.
285. Australian Medical Journal, Melbourne.
286. Archives Internationales de laryngologie, de rhinologie et d'otologie, Paris.
287. Annales de dermatologie et de syphiligraphy, Paris.
288. La presse médicale belge, Bruxelles.
289. Archives roumaines de médecine et de chirurgie, Paris.
290. La pratique médicale, Paris.
291. Archives de médecine et de chirurgie, Paris.
292. La Médecine Scientifique, Paris.
293. Annales de la Société médico-chirurgicales, Liége.
294. Bulletin de la phthisie pulmonaire, Paris.
295. Allgemeine Zeitschrift für Psychiatrie und psychisch-gerichtliche Medicin, Berlin.
296. Les nouveaux remèdes, Paris.
297. Allgemeine medicinische Central-Zeitung, Berlin.
298. Gazette hebdomadaire des sciences médicales, Montpellier.
299. Annales de chimie et de physique, Paris.
300. Annales de physiologie, normale et pathologique, Paris.
301. Deutsche Zeitschrift für Chirurgie, Leipzig.
302. Jahrbuch für Morphologie, Leipzig.
303. L'abeille médicale, Paris.
304. La province médicale, Lyons.
305. L'année médicale de Caen.
306. Petit moniteur de la médecine, Paris.
307. L'impartialité médicale, Paris.
308. Journal de la Société de médecine et de pharmacie de la Haute-Vienne, Limoges.
309. Charité-Annalen, Berlin.
310. Jahrbuch für praktische Aerzte, Berlin.
311. Vierteljahresschrift für gerichtliche Medicin und Sanitätswesen, Berlin.
312. Monatshefte für Ohrenheilkunde, Berlin.
313. Monatshefte für Anatomie und Physiologie, Berlin.
314. Zeitschrift für Psychiatrie und gerichtliche Medicin, Berlin.
315. Archiv für Pathologie und Physiologie, Berlin.
316. Anatomischer Anzeiger, Jena.
317. Centralblatt für Gynækologie, Leipzig.
318. Anzeiger über Novitäten und Antiquar der Medicin, Leipzig.
319. Centralblatt für klinische Medicin, Leipzig.
320. Archiv für Anatomie und Physiologie, Leipzig.
321. Annales d'orthopédie, Paris.
322. Archiv für Anthropologie, Braunschweig.
323. Mittheilungen aus der ophthalmologischen Klinik in Tübingen.
324. Archiv für Hygiene, Munich.
325. American Analyst, New York.
326. Deutches Archiv für klinische Medicin, Leipzig.
327. Journal des connaissances médicales pratiques et de pharmacologie, Paris.
328. Archiv für Ohrenheilkunde, Leipzig.
329. Journal de médecine, de chirurgie, et de pharmacologie, Paris.
330. Médecin clinicien, Paris.
331. Der praktische Aerzt, Wetzlar.
332. Oesterreichische Badezeitung, Vienna.
333. Blätter für Gesundheitspflege, Berlin.
334. Annales de l'hospice des Quinze-Vingts, Paris.
335. Biologisches Centralblatt, Erlangen.
336. Centralblatt für Chirurgie, Leipzig.
337. Quarterly Journal of Inebriety, Hartford, Conn.
338. Jenäische Zeitschrift für Natürwissenschaften, Jena.
339. Detroit Emergency Hospital Reports, Detroit.
340. Gazette d'ophtalmologie, Paris.
341. Medizinisch-chirurgisches Centralblatt, Vienna.
342. Journal des sages-femmes, Paris.

343. Monatsblatt für öffentliche Gesundheitspflege, Braunschweig.
344. Zeitschrift für Ohrenheilkunde, Wiesbaden.
345. Annales de thérapeutique médico-chirurgicales, Paris.
346. Annales d'hygiène publique et de médecine légale, Paris.
347. American Journal of Ophthalmology, St. Louis.
348. Nouveau Montpellier Médical, Montpellier, France.
349. Bulletin de la Société de médecine de Rouen.
350. "Hygiea." Zeitschrift für Balneologie, Climatologie, etc. Vienna.
351. Friedrich's Blätter für gerichtliche Medizin und Sanitäts-Polizei, Munich.
352. Allgemeiner deutsche hebammen-Zeitung, Berlin.
353. Zehender's klinische Monatsblätter für Augenheilkunde, Stuttgart.
354. Der Frauenarzt, Berlin.
355. Revista de terapéutica y farmacia, Madrid.
356. Archives de biologie, Gand
357. Therapeutische Blätter, Vienna.
358. Journal de chimie médicale, de pharmacie, de tocologie et revue de nouvelles scientifiques, nationales et étrangères, Paris.
359. Journal de Pharmacie et de chimie, Paris.
360. Archives générales de médecine, Paris.
361. Annales médico-psychologiques, Paris.
362. Répertoire de pharmacie, Paris.
363. Gazette hebdomadaire de médecine et de chirurgie, Paris.
364. Medical Fortnightly, St. Louis.
365. Centralblatt für die medicinischen Wissenschaften, Berlin.
366. Jahrbuch für Kinderheilkunde und physische Erziehung, Leipzig.
367. Irrenfreund, Heilbronn.
368. Archiv für Psychiatrie und Nervenkrankheiten, Berlin.
369. Norsk magazin for lægevidenskaben, Christiania.
370. Hygiea, Stockholm.
371. Nordiskt medicinskt arkiv, Stockholm.
372. Lakäreförenings forhändlingar, Upsala.
373. Hospitals-tidende, Copenhagen.
374. Bibliothek for laeger, Copenhagen.
375. Ugeskrift for laeger, Copenhagen.
376. Lo sperimentale, Florence.
377. Gazeta médica de Granada.
378. Gazette médicale de Liége.
379. Braithwaite's Retrospect, New York and London.
380. Giornale per le levatrici, Milan.
381. Morphologisches Jahrbuch, Leipzig.
382 Wiener Klinik, Vienna.
383. Memorabilien, Heilbronn.
384. Good Health, Battle Creek, Mich.
385. Monatsschrift fur Ohrenheilkunde, Berlin.
386. Deutsche Vierteljahresschrift für öffentliche Gesundheitspflege, Braunschweig.
387. Jahresbericht über Leistungen und Fortschritte der Ophthalmologie, Tübingen.
388. British Guiana Medical Annual and Hospital Reports, Georgetown.
389. Bulletin de la Société d'ethnographie, Paris.
390. Deutsches Wochenblatt für Gesundheitspflege und Rettungswesen, Berlin.
391. Zeitschrift für Biologie, Munich.
392. Medizinisch-chirurgisches Rundschau, Vienna.
393. Zeitschrift für Gebürtshülfe und Gynækologie, Stuttgart.
394. Health, Belfast, Ireland.
395. Jahrbuch für Psychiatrie, Berlin.
396. Archiv der Pharmacie, Berlin.
397. Klinische Zeit- und Streitfragen, Vienna.
398. Journal of the Anthropological Institute of Great Britain and Ireland, London.
399. Medicinische Neuigkeiten für praktische Aerzte, Munich.
400. Journal of the Royal Microscopical Society, London.
401. Zeitschrift für wissenschaftliche Mikroskopie und für mikroskopische Technik, Braunschweig.
402. Jahresbericht über Leistungen und Fortschritte der gesammten Medicin. Virchow and Hirsch, Berlin,
403. Mind, London.
404. Volkmann's Sammlung klinischen Vorträge, Leipzig.
405. Zeitschrift für Heilkunde, Berlin.

406. Medizinische Jahrbücher der Gesellschaft der Aerzte in Wien.
407. Sanitary Record, London.
408. St. Bartholomew's Hospital Reports, London.
409. Archives italiennes de biologie, Turin.
410. Archives de physiologie normale et pathologique. Brown-Séquard, Paris.
411. Der aerztliche Practiker, Berlin.
412. St. George's Hosp. Reports, London.
413. L'Art médical, Paris.
414. Bulletin de la clinique nationale ophtalmologique de l'hospice des Quinze Vingts, Paris.
415. Courrier médical, Paris.
416. L'électricien, Paris.
417. Aerztliches Vereinsblatt für Deutschland, Leipzig.
418 St. Thomas's Hospital Reports, London.
419. Bulletins et mémoires de la Société de chirurgie, Paris.
420. Bulletins et mémoires de la Société médicale des hôpitaux, Paris.
421. Bulletins et mémoires de la Société française d'otologie et de laryngologie, Paris.
422. Shurnal akuscherstwa i shenskich bolesnej, St. Petersburg.
423. Royal London Ophthalmic Hospital Reports.
424. Clinical Reporter, Chicago.
425. American Annals of the Deaf, Washington, D. C.
426. Ohio Medical Journal, Cincinnati.
427. Bulletin de la Société de médecine d'Angers.
428. Guy's Hospital Reports, London.
429. Veröffentlichungen des kaiserlichen Gesundheitsamtes, Berlin.
430. Kansas Medical Catalogue, Fort Scott, Kansas.
431. Journal du magnétisme, Paris.
432. Journal of Comparative Medicine and Veterinary Archives, Phila.
433. Concours médical, Paris.
434. Gazette des Eaux, Paris.
435. Revue clinique d'oculistique, Paris.
436. Journal of Heredity, Chicago.
437. Schweizerische Blätter für Gesundheitspflege, Basel.
438. Gazette française de médecine et de pharmacie, Paris.
439. Revue obstétricale et gynécologique, Paris.
440. The Microscope, Trenton, N. J.
441. Revista de sanidad militar, Madrid.
442. Gazette médicale et pharmaceutique de France.
443. Revue d'hygiène et de police sanitaire, Paris.
444. Journal of Surgery, Gynæcology, and Obstetrics, Atlanta.
445. Zeitschrift für Schulgesundheitspflege, Hamburg.
446. Revue speciale de l'antisepsie médicale et chirurgicale, Paris.
447. Revue d'anthropologie, Paris.
448. Aerztlicher Central-Anzeiger, Hamburg.
449. Archives d'anatomie pathologique, Paris.
450. Bulletin de la Société clinique, Paris.
451. International Medical Magazine, Philadelphia.
452. Nouvelle iconographie de la Salpêtrière, Paris.
453. Annales de la reale Academia de ciencias medicas fisicas y naturales de la Habana.
454. Archives médicales belges, Bruxelles.
455. Bulletin de la Société de médecine de Gand.
456. Revista de ciencias médicas, Barcelona.
457. Archives de médecine expérimentale et d'anatomie pathologique, Paris.
458. Archivio de la Sociedad de Estudios Clinicas, Madrid.
459. Cronica médico-quirúrgica de la Habana.
460. Archivio per le scienze mediche, Torino.
461. Archivii italiani di laringologia, Naples.
462. The Post-Graduate, New York.
463. Annales de obstetricia ginecopatía y pediatría, Madrid.
464. Revista di ostetricia e ginecologia, Torino.
465. Der Thierarzt, Wetzlar.
466. Archivio di ortopedia, Milan.
467. Bulletin de la Société royale de pharmacie de Bruxelles.
468. Revista d'igiene practica e sperimentale, Naples.

469. Boston Journal of Health.
470. Annali clinici dell' Ospedale degli Incurabili in Napoli.
471. Bulletins de la Société de médecine pratique, Paris.
472. Bullettino delle scienze mediche, Bologna.
473. American Druggist, New York.
474. Cronaca del manicomio di Ancona.
475. Berliner Klinik, Berlin.
476. Dominion Med. Monthly, Toronto.
477. Annali di chimica e di farmacologia, Milan.
478. Bulletin du service de santé militaire, Paris.
479. Journal des maladies cutanées et syphilitiques, Paris.
480. Annali universali di medicina e chirurgia, Milan.
481. Boletin di medicina y farmacia, Barcelona.
482. Canadian Pharmaceutical Journal, Toronto.
483. The Climatologist, Philadelphia.
484. Bullettino della reale Accademia medica di Roma.
485. Archivio di patologia infantil, Naples.
486. China Imperial Maritime Customs Medical Reports, Shanghai.
487. Correspondenzblatt des allgemeinen mecklenburgischen Aerztevereins, Rostock.
488. Archiv for Pharmaci og technisk Chemi, med deres Grundvidenskaber, Copenhagen.
489. El Dictamen, Madrid.
490. Atti e rendiconti della Accademia medico-chirurgica di Perugia.
491. Journal de micrographie, Paris.
492. Baltimore Med. and Surg Record.
493. El observador médico, Madrid.
494. Gaceta médica catalana, Barcelona.
495. Deutsche militärärzliche Zeitschrift, Berlin.
496. Correspondenzblätter des allgemeinen aerztlichen Vereins von Thüringen, Leipzig.
497. Il Morgagni, Milan.
498. Finska Läkare-sällskapets handlingar, Helsingfors.
499. Journal of Microscopy and Natural Science, London.
500. Boletin de la Revista de medicina y cirugía prácticas, Madrid.
501. Bollettino d'oculistica, Florence.
502. Der Naturarzt, Dresden.
503. El siglo médico, Madrid.
504. Journal of Hydrotherapy, London.
505. Gazzetta degli ospitali, Naples.
506. Journal of the Arkansas Medical Society, Little Rock.
507. Giornale italiano delle malattie veneree e della pelle, Milan.
508. Skandinavisches Archiv für Physiologie, Upsala.
509. Ejenedêlnaya klinicheskaya Gazeta.
510. Alma Mater, Aberdeen, Scotland.
511. Blätter für Kriegsverwaltung, Berlin.
512. Gyógyászat, Budapest.
513. Il progresso medico, Naples.
514. Ohio Journal of Dental Science, Toledo.
515. Gazzetta medica di Roma.
516. La independencia médica, Barcelona.
517. Vaccination Enquirer and Health Review, London.
518. Bullettino della Commissione speciale d'igiene del municipio di Roma.
519. Journal of Materia Medica, New Lebanon, N. Y.
520. Gazeta lekarska, Warsaw.
521. Journal of Comparative Pathology and Therapeutics, Edinburgh.
522. Bullettino medico cremonese, Cremona.
523. Kinesithérapie, Paris.
524. La médecine contemporaine, Paris.
555. Zeitschrift der Tokio medicinischen Gesellschaft, Tokyo.
526. Giornale della reale Società italiana d'igiene, Milan.
527. Bulletins et mémoires de la Société de thérapeutique, Paris.
528. L'écho médical, Toulouse.
529. Bulletins et mémoires de la Société française d'ophtalmologie, Paris.
530. Meditzinskoje Obozrenije, Warsaw.
531. Giornale medico del realo esercito e della reala marina, Roma.
532. Les nouveaux-nés, Paris.
533. Medical and Professional Review, London.
534. Gaceta de oftalmologia y de otologia, etc., Madrid.
535. La médecine illustrée, Paris.
536. Medical Reformer, Agra City, India.

537. Giornale internazionale delle scienze mediche, Naples.
538. Le Scalpel, Liége.
539. Bulletins de la Société anatomique de Nantes.
540. L'Osservatore, Torino.
541. Aerztliche Mittheilungen aus Baden, Karlsruhe.
542. La crónica médica, Lima.
543. Bulletin de la Société anatomo clinique de Lille.
544. La correspondencia médica, Madrid.
545. Ciencia médico-escolástica, Barcelona.
546. Cincinnati Medical Journal, Cincinnati.
547. Massachusetts Medical Journal, Boston.
548. Clinical Register, Knoxville, Tenn.
549. A medicina contemporanea, Lisbon.
550. Cronaca del manicomio di Siena.
551. Medycyna, Warsaw.
552. Clinique, Chicago.
553. El progreso médico-farmacéutico, Madrid.
554. Ottawa Medical World.
555. Meditzinisko Spisanië, Budapest.
556. National Druggist.
557. New Zealand Medical Journal, Dunedin.
558. O Brazil-medico, Rio de Janeiro.
559. Orvosi hetilap, Budapest.
560. Pharmaceutische Post, Vienna.
561. Quarterly Therapeutic Review, London.
562. Pharmaceutical Era, Detroit.
563. Orvosi heti szemle, Budapest.
564. Progrèsul médical roumain, Bucharest.
565. Quarterly Journal of Medical Science, London.
566. Revista practica de pediatrica, Madrid.
567. Sanitary Engineering, London.
568. Medical Herald, St. Joseph, Missouri.
569. Przeglad lekarski, Krakow.
570. Quarterly compendium of Medicine, Philadelphia.
571. Russkaïa meditzina, St. Petersburg.
572. Tidsskrift for praktisk medicin, Christiania.
573. Terapeutica medica, Naples.
574. El restaurador farmacéutico, Barcelona.
575. Pharmaceutische Centralhalle für Deutschland, Berlin.
576. Gesundheits-Ingenieur, Munich.
577. Union médicale du nord-est, Reims.
578. Revista médica de Chile, Santiago, Chili.
579. Vereinsblatt der pfaelzischen Aerzte, Frankenthal.
580. Revue sanitaire de la Province, Bordeaux.
581. Pharmaceutical Record, London.
582. Journal da Sociedade das sciéncias medicas de Lisbon.
583. Nederlandsch Tijdschrift voor Geneeskunde, Amsterdam.
584. World's Medical Review, Phila.
585. Revue scientifique et administrative des médecins des armées de terre et de mer, Paris.
586. Wratsch, St. Petersburg.
587. Répertoire de thérapeutique, Paris.
588. Wiadomosci lekarskie, Lwow.
589. Riforma medica, Naples.
590. Wjestnik klinitscheskoj i ssudebnoj psychiatrii i neiropatologii, St. Petersburg.
591. Rivista sperimentale di freniatria e di medicina legale in relazione con l'antropologia e le scienze giuridiche e sociali, Reggio-Emilia.
592. Zeitschrift für die Behandlung Schwachsinniger und Epileptischer, Dresden.
593. Kjobenhavenske medicinske selskabs förhandlingar, Copenhagen.
594. Revista veneta di scienze mediche, Venice.
595. Zeitschrift für Geburtshülfe und Frauenkrankheiten, St. Petersburg.
596. Rivista clinica e terapeutica, Naples.
597. Bulletin de la Seciété médicale de l'Yonne, Auxerre.
598. Zeitschrift für Wundärzte und Geburtshülfer, Hegnach.
599. L'actualité médicale des sciences médicales et des intérêts professionels, Paris.
600. Mittheilungen für den Verein Schleswig Holsteinischer Aerzte, Kiel.
601. Rivista clinica. Archivio italiano di clinica medica, Milan.
602. American Anthropologist, Washington, D. C.
603. Revue d'anthropologie, Paris.

604. Il raccoglitore medico, Forli.
605. Archivio di psichiatria, scienze penali ed antropologia criminale, Torino.
606. L'Homme, Paris.
607. Revista especial de oftalmologia, sifilografia y dermatologia, Madrid.
608. Revue internationale scientifique et populaire des falsifications des denrées alimentaires, Amsterdam.
609. Archiv für Anatomie und Entwickelungsgeschichte, Leipzig.
610. La medicina contemporánea, Madrid.
611. Medical Current, Chicago.
612. Archivios de medicina y cirurgia de los niños, Madrid.
613. Revista Balear de ciencias médicas, Palma de Mallorca.
614. Giornale di farmacia, di chimica e di scienze affini, Torino.
615. La rassegna di scienze mediche, Modena.
616. Gazzetta medica lombarda, Milan.
617. Indian Medical Journal, Calcutta.
618. Crónica médica de Valencia.
619. Revista médico-farmacéutico de Aragon, Zaragoza.
620. El monitor médico, Lima.
621. Ejenedelnaya, St. Petersburg.
622. Pester medicinisch-chirurgische Presse, Budapest.
623. Der Militärarzt, Vienna.
624. Bollettino delle malattie dell' orecchio, della gola e del naso, Florence.
625. Gazetta di medicina publica, Naples.
626. Annales de la Société d'hydrologie médicale de Paris.
627. Mittheilungen aus der Vereins der Aerzte in Steiermark, Graz.
628. Bollettino delle cliniche, Milan.
629. La medicina preventiva; Gazzetta mensile d'igiene clinica e terapia, Naples.
630. Coimbra médica, Coimbra.
631. Minnesota Med. Monthly, St. Paul.
632. Revista de medicina y cirujica prácticas, Madrid.
633. Revista de laringologia, otologia y rinologia, Barcelona.
634. Revista médica de Sevilla.
635. Revista dos cursos practicos et theoreticos da Faculdade de medicini do Rio de Janeiro.
636. Dnevnik obshestva vrachei pri Imperatorskom Kazanskom Universitetie, Kazan.
637. Annali della Universita libera di Perugia.
638. Revista Médica de Bogotá.
639. Revista argentina de ciencias médicas, Buenos Ayres.
640. Kronika lekarska, Warsaw.
641. Annales de la Société de médecine d'Anvers.
642. Gazeta medica da Bahia.
643. Revue médicale, Paris.
644. Semskij wratsch, Tchernigoff.
645 Texas Sanitarian, Austin, Texas.
646. Doctor's Weekly, New York City, N. Y.
647. Alabama Medical and Surgical Age, Anniston.
648. Journal des Sociétés scientifiques de la France et de l'étranger, Bordeaux.
649. Zeitschrift der Bakterienkunde, Leipzig.
650. Wiener medicinische Blätter, Vienna.
651. Mittheilungen aus der medicinischer klinik zu Königsberg.
652. Giornale di neuropatologia, Naples.
653. La médecine russe, St. Petersburg.
654. Revista de médico-farmacéutica, Castellón.
655. Bolletino della Poliambulanza di Milano.
656. Revista Brazileira de medicina, Rio de Janeiro.
657. International Review of Medical and Surgical Technics, Palatka, Fla.
658 Bulletin international des Sociétés de la Croix Rouge, Geneva.
659. Vôz de Hipocrates, Mexico.
660. Spitalul, Bucharest.
661. Annales da Academia de medicina do Rio de Janeiro.
662. Revista médico-quirùrgica, Buenos Ayres.
663. Medical Mirror, St. Louis.
664. Moniteur du praticien, Paris.
665. El progresso ginécologia y pediatria, Valencia.
666. Revista de medicina cirujia y farmacía, Barcelona.
667. Journal de pharmacia e chimica, Lisbon.

668. Medical Visitor, Chicago.
669. Memorie della reale Accademia médica di Genova.
670. Mémoires de la Société de médecine de Nancy.
671. Revue médicale de Moscou.
672. Der Fortschritt, Geneva.
673. Universal Medical Journal, Philadelphia.
674. Le mouvement hygiénique, Brussels.
675. Mitth. a. d. anthrop. Gesell., Wien.
676. Osaka Medical Journal, Japan.
677. Japanese and Foreign Medical News, Tokyo.
678. Eira, Stockholm.
679. Centralblatt für Kinderheilkunde, Leipzig.
680. Revue Inter. de Rhinol., d'Otol., de Laryngol. et d'Ophtal., Paris.
681 Mittheilungen aus der medicinischen Facultät der kaiserlich-Japanischen Universität, Tokyo.
682. Entomologisk Tijdskrift, Stockholm.
683. Novosti Terapii, Budapest.
684. Annales de la Société de Médecine de Gand.
685. Bulletin de la Société de médecine mentale de Belgique, Gand.
686. Commentario clinico delle Malattie cutanee e Genito Urinarie, Siena, Italy.
687. Journal of the Army Medical Society, Japan.
688. Psychiatrische Bladen, Amsterdam.
689. Reports of the Psychical Research Society, London.
690. Bulletin de la Société de psychologie physiologique, Paris.
691. Revue illustrée de polytechnique médicale, Paris.
692. The Hospital, London.
693. Revue de la masso-électrothérapie, Paris.
694. Public Health, London.
695. Hospital Gazette, London.
696. Chirurgitcheskij westnik, St. Petersburg.
697. British Journal of Dermatology, London.
698. Chemiker Zeitung, Berlin.
699. Revista clinica de Barcelona.
700. Revue micologique, Paris.
701. Zoologischer Anzeiger, Leipzig.
702. Kozégeszségügy és törvényszéki orvostoi, Budapest.
703. Westnik obschtschestwennoj gigieny, ssudebnoj i praktitscheskoj medizini, Moscow.
704. Westnik oftalmologii, St. Petersburg.
705. Journal ophtalmologique du Nord, Lille.
706. Bulletin de statistique démographique et médicale de Bruxelles.
707. Journal de pharmacie d'Anvers.
708. Bulletin de la Société anatomo-pathologique de Bruxelles.
709. Bulletin de la Société belge de microscopie, Bruxelles.
710. Bulletin de la Société royale de médecine publique de Belgique, Bruxelles.
711. American Journal of Dental Science, Baltimore.
712. Bulletins et publications de la Société de médecine du Luxembourg.
713. Bulletin de la Société de médecine de Reims.
714. Archivio Bizzozero, Naples.
715. Bulletin de la Société de médecine du département de la Sarthe.
716. Los Avisos, Madrid.
717. Bulletins et publications de l'Académie des Sciences de Belgique, Brussels.
718. Bulletin de l'Institut de Statistique, Paris.
719. Western Druggist, St. Louis.
720. Revue internationale de l'électrothérapie, Paris.
721. Dental Headlight, Nashville.
722. Jahresbericht über die Fortschritte der Geburtshülfe und Gynäkologie, Erlangen.
723. The Medical Pioneer, Enfield, England.
724. Gynäkologisches Centralblatt, Berlin.
725. Moniteur d'ophtalmologie, St. Petersburg.
726. Vestnik oftalmologii, St. Petersburg.
727. Annali dell' Istituto d'igiene sperimentale dell' Università di Roma.
728. Manhattan Eye and Ear Hospital Reports, New York.
729. Transcaucasian Lying-in Hospital Reports.
730. Bollettino scientifico, Pavia.
731. Wiener medicinisches Jahrbuch, Vienna.

732 Rivista clinica dell' Università di Napoli.
733. Annales de médecine thermale, Paris.
734. Australasian Journal of Pharmacy, Melbourne.
735. La médecine hypodermique, Scéaux.
736. Il Sordomuto, Naples.
737. L'Anomalo. Gazettino antropologico psichiatrico, medico-legale, Naples.
738. Centralblatt für orthopädische Chirurgie und Mechanik, Berlin.
739. Giornale della reale Accademia di medicina, Torino.
740. Archiv für Wissenschaften und praktische Thierheilkunde, Leipzig.
741. Ephemeris, Brooklyn.
742. Apotheker-Zeitung, Berlin.
743. Het Maandblad voor Apothekers, Amsterdam.
744. Pharmaceutical Journal and Transactions, London.
745. Zubovratchebnyi Vestnik, St. Petersburg.
746. Bulletins des travaux de la Société de pharmacie de Bordeaux.
747. L'Union pharmaceutique, Paris.
748. Zeitschrift für Krankenpflege, Bern.
749. Bulletin de la Société d'anthropologie de Paris.
750. Giornale florentina d'igiene, Florence.
751. Bulletin de la Société de biologie, Paris.
752. The Amer. Doctor, Richmond, Va.
753. Deutsche Zeitschrift für praktische Medicin, Berlin.
754. Wojenno Ssanitasnoje, St. Petersburg.
755. Archives générales d'hydrologie, de climatologie et de balnéothérapie, Paris.
756. Fort Wayne Journal of Medical Science.
757. Giornale di medicina pubblica, Naples.
758. Časopis lékařů českých, Praze.
759. American Journal of Chemistry.
760. Times and Register, Philadelphia.
761. Beiträge zur klinischen Chirurgie, Tübingen.
762. Archivio italiano di pediatria, Naples.
763. Archives de Sociologie, Paris.
764. Johns Hopkins Hospital Bulletin, Baltimore.
765. La salute pubblica, Perugia.
766. Studies in Clinical Medicine, Edinburgh.
767. La Medicina practica, Madrid.
768. Beiträge zur pathologischen Anatomie und zur allgemeinen Pathologie, Freiburg i. B.
769. Dominion Dental Journal, Montreal.
770. Meditzinskoie Preglëd, Budapest.
771. Hot Springs Medical Journal, Hot Springs, Ark.
772. La Sicilia médica, Palermo.
773. Revista de ciencias médicas, Havana.
774. Boletin de medicina y cirugia, Madrid.
775. Mittheilungen der naturforschenden Gesellschaft in Bern.
776. Journal of Ophthalmology, Otology, and Laryngology, New York.
777. Szemézet, Budapest.
778. Nordisk ophthalmologisk Tijdskrift, Copenhägen.
779. North Amer. Practitioner, Chicago.
780. Annales de la Polyclinique de Bordeaux.
781. L'odontologie, Paris.
782. Journal d'électricité médicale, Paris.
783. Nowiny lekarske, Posen.
784. Revista médica de México.
785. El tula médica de Valladolid.
786. St. Louis Clinique.
787. Lehigh Valley Medical Magazine, Easton, Pa.
788. Il Progreso de gynecologia y pediatria, Madrid.
789. Le progrès dentaire, Paris.
790. Nederlandsch Tijdschrift voor Verloskunde en Gynæcologie, Haarlem.
791. Γαληνὸς Ἀθῆναι.
792. El Estudio, Mexico
793. Journal of the Quekett Microscopical Club, London.
794. Memorie della reale Accademia della scienze dell' Istituto di Bologna.
795. La cellule, Brussels.
796. Archives de zoologie expérimentale et générale, Paris.
797. Alger médical, Algiers.
798. Revue mensuelle des maladies des yeux, Paris.
799. Zeitschrift für Ethnologie, Berlin.

800. Mediizinskija pribawlenija k morskomu sborniku, Moscow.
801. Kansas Medical Journal, Topeka.
802. Lo spallansani, Rome.
803. Internationale Monatsschrift für Anatomie und Physiologie, Leipzig.
804. Monatsschrift des Vereins deutscher Zahnkünstler, Leipzig.
805. Dental Cosmos, Philadelphia.
806. Archives of Surgery, London.
807. Journal für Zahnheilkunde, Berlin.
808. International Dental Journal, Philadelphia.
809. Zeitschrift für angewandte Chemie, Berlin.
810. Quarterly Journal of Microscopical Science, London.
811. Toledo Medical and Surgical Reporter, Toledo, Ohio.
812. Biologiska föreningens förhandlingar, Stockholm.
813. Mississippi Med. Monthly, Meridian.
814. American Medico-Surgical Bulletin, New York.
815. Sanitary World, London.
816. Bollettino della Società florentina d'igiene, Florence.
817. Canada Health Journal, Ottawa.
818. Journal of British and Foreign Health Resorts, London.
819. La terapia moderna, Padua.
820. Medical Sentinel, Portland, Oregon.
821. Revista médico-quirurgica, Cadiz.
822. Southern Dental Journal, Atlanta.
823. Archivio della riforma medica, Naples.
824. Quarterly Medical Journal, Sheffield, England.
825. Annales des sciences psychiques, Paris.
826. Notes on New Remedies, New York.
827. Le mercredi médical, Paris.
828. Untersuchungen aus dem physiologischen Institut der Universität, Halle.
829. Pharmaceutical Journal of Australasia, Sydney, N. S. W.
830. Revista internazionale d'igiene, Naples.
831. Revista de higiene y policia sanitaria, Barcelona.
832. Sbornik lékarskí, Praze. Archives bohémes de médecine.
833. L'anthropologie, Paris.
834. La psichiatria, Naples.
835. Revista de medicina dosimetrica, Madrid.
836. Annalen der Physik und Chemie, Leipzig.
837. Zeitschrift für Nahrungsmittel-Untersuchungen und Hygiene, Vienna.
838. Duodecim, Helsinki.
839. Bollettino della Societá Lancisiana, Rome.
840. Bulletin de la Société impériale des naturalistes, Moscow.
841. British Journal of Dental Science, London.
842. Journal of the British Dental Association, London.
843. Journal de médecine pratique, Paris.
844. Oesterr-ungar. Centralblatt für die medicinischen Wissenschaften, Vienna.
845. Medical Magazine, Lahore, India.
846. Harper Hospital Bulletin, Detroit.
847. Der oesterreichische Sanitäts-Beamte, Vienna and Berlin.
848. Mémoires couronnés et autres mémoires publiés par l'Académie royale de médecine de Belgique, Bruxelles.
849. Quarterly Atlas of Dermatology, St. Louis.
850. Northwestern Medical Journal, Minneapolis.
851. Wojenno meditzinskij shurnal.
852. Laitopisj chirurgitscheskago obschtschestwa, Moscow.
853. Revue d'orthopédie, Paris.
854. Centralblatt für allgemeine Pathologie und pathologische Anatomie, Freiburg i. B.
855. Modern Medicine and Bacteriological World, Battle Creek, Mich.
856. Western Medical and Surgical Reporter, St. Joseph, Mo.
857. Annales de la Asistencia Publica, Buenos Ayres.
858. Johns Hopkins Hospital Reports, Baltimore.
859. Bolnitchnaja gazeta Botkina.
860. Revue générale des sciences pures et appliquées, Paris.
861. Oesterreichische aerztliche Vereinszeitung, Vienna.
862. Bulletin médical de l'Algérie.
863. Der Kinder-Arzt, Worms.
864. American Medical Journal, St. Louis.

865. Bulletin de la Société française de dermatol. et de syphiligraphie, Paris.
866. Review of Insanity and Nervous Disease, Wauwatosa, Wis.
867. Kowalewskij's Archiv.
868. Journal de médecine, de chirurgie, et de pharmacologie, Bruxelles.
869. American Chem. Jour., Baltimore.
870 Balneologisches Centralblatt, Munich.
871. El criterio médico, Madrid.
872. Farmacia moderna, Madrid.
873. Il faro médico, Milan.
874. Gazette des Hôpitaux de Toulouse.
875. Helsovännen. Tidskrift for allmän och enskild helsovård, Göteborg.
876. L'idrologia e la climatologia medica, Florence.
877. Klinicheskij sbornik gospitalnoi terapevticheskii kliniki imperatorskago Varschavskago Universlteta. Nabloudenija i izsliedovanija, Warsaw.
878. New England Med. Gazette, Boston.
879. Revue d'hygiène thérapeutique, Paris.
880. Zeitschrift für analytische Chemie, Wiesbaden.
881. Zeitschrift für Fleisch- und Milchhygiene, Berlin.
882. Wiadomosci farmaceutyczne, Warsaw.
883. Diario del San Benedetto in Pesaro.
884. Tidskrift i militär Helsovård, Stockholm.
885. Sanitarnõe Dielo. Organ obchestvennoi i chastno higienij, St. Petersburg.
886. Rassegna critica internazionale delle malattie del naso, gola e orecchio, Naples.
887. Pamietnik towarzystwa lekarskiego Warszawskiego, Warsaw.
888. Das oesterreichische Sanitätswesen, Vienna.
889. New York Medical Times, N. Y.
890. American Ophthalmological Monographs, Cincinnati.
891. Maandblad uitgegeven door de Ve reeniging tegen de Kwakzalverij, Amsterdam.
892. Journal of the Anthropological Society of Bombay.
893. Le petit médecin des familles, Paris.
894. Anales de la Academia de medicina de Medellín.
895. Le Dauphiné médical, Grenoble.
896. Journal de médecine et de pharmacie de l'Algérie, Algiers.
897. Zeitschrift für Psychologie und Physiologie der Sinnesorgane, Hamburg.
898. Toledo Med. Compend, Ohio.
899. Sbornik rabot hygienicheskoi laboratorii Moskovskago Universiteta, Moscow.
900. Rivista generale italiana di clinica medica, Pisa.
901. Medical Times and Gazette, London.
902. Journal für praktische Chemie, Leipzig.
903. Schweizerische Wochenschrift für Pharmacie, Schaffhausen.
904. Bulletin de la Société impériale et centrale de médecine vétérinaire.
905. La Clinique Internationale, Paris.
906. Journal of Balneology, New York.
907. Revista clinica de los hospitales, Madrid.
908. Bulletin de la Société de chirurgie, Paris.
909. Revue odontologique, Paris.
910. Oesterreichisch-ungarische Vierteljahresschrift für Zahnheilkunde, Vienna.
911. New York Journal of Gynæcology and Obstetrics.
912. Dental Record, London.
913. Archivio per l'anthropologia e la etnologia, Florence.
914. Jour. of Electro-Therapeutics, N. Y.
915. Rivista d'igiene e sanità pubblica con Bollettino sanitario amministrativo compilato sugli atti ufficiali del ministero dell' interno, Rome.
916. Anales de la real Academia de medicina, Madrid.
917. Boletin de medicina naval, Madrid.
918. Arch. internacionales de laringologia, otologia, rinologia, Barcelona.
919. Deutsche Revue, Breslau and Berlin.
920. Comptes rendus hebdomadaires des séances de l'Académie des sciences, Paris.
921. Il policlinico, Rome.
922. Correspondenzblatt der Aerztekammer und der Aerztevereine der Provinz Brandenburg und des Stadtkreises, Berlin.
923. Semanario farmacéutico, Madrid.

924. Reichs-Medicinal-Anzeiger, Leipzig.
925. Anales del circulo medico argentino, Buenos Ayres.
926. Beiträge zur Kinderheilkunde aus dem I. öffentlichen Kinderkrankeninstitut in Wien.
927. Comptes rendus hebdomadaires des séances et mémoires de la Société de biologie, Paris.
928. Studies from the Laboratory of Physiological Chemistry, Sheffield Scientific School of Yale College, New Haven, Conn.
929. Repertorio medico-farmacéutico y de ciencias auxiliares, Havana.
930. Hygien. Rundschau, Königsberg i. P.
931. Gaceta sanitaria de Barcelona.
932. Journal der pharmacie von Elsass-Lōthringen, Strassburg.
933. Onderzoekingen gedan in het physiologisch Laboratorium, der Leidsche Hoogeschool, Leiden.
934. Rivista italiana di terapia e igiene, Piacenza.
935 Andalucía médica, Cordova.
936. Bollettino della Associazione medica lombarda, Milan.
937. Revue biologique du nord de la France, Lille.
938. Onderzoekingen gedan in het physiologisch Laboratorium derUtrecht'sche Hoogeschool, Utrecht.
939. Revista de enfermedades de la infancia, Barcelona.
940. L'Orosi. Giornale di chimica, Florence.
941. Journal de pharmacologie, Bruxelles.
942. Gazette médico-chirurgicale de Toulouse.
943. Annali di ostetricia e ginecologia, Milan.
944. Bollettino dell' Associazione nazionale dei medici comunali, Rome.
945. Bulletin de pharmacie de Lyon, Lyons
946. Dietetic and Hygienic Gazette, New York.
947. Bollettino farmaceutico, Rome and Milan.
948. California Med. Jour., San Francisco.
949. Chemisches Centralblatt, Leipzig.
950. Maandblad tegen de vervalschingen, Amsterdam.
951. Medicina cientifica basada en la fisiologia y en la experimentacion clinica, Mexico.
952. Revista farmacéutica, Buenos Ayres.
953. Pharmaceutische Zeitung, Berlin.
954. Nederlandsch militair geneeskundig Archief van de Landmacht, Zeemacht, het Oost- end West-Indisch Leger, Leiden.
955. Archives néerlandaises des sciences éxactes et naturelles, Haarlem.
956. Bollettino del manicomio provinciale di Ferrara.
957. Gazzetta delle cliniche, Naples.
958. Archiv für öffentliche gesundheitspflege in Elsass-Löthringen, Strassburg.
959. Revue d'hypnologie théorique et pratique, Paris.
960. Physiological Laboratory, Harvard Medical School, Boston.
961. Organ der Taubstummen-Anstalten in Deutschland und den deutschredenden Nachbarländern, Friedburg.
962. Bollettino della reale Accademia medico-chirurgia di Napoli.
963. Corréo médico castellano, Salamanca.
964. Gazzetta del manicomio della provincia di Milano in Mombello
965. Wochenschrift für Thierheilkunde und Viehsucht, Munich.
966. Physio-Medical Journ., Indianapolis.
967. Ny pharmaceutisk Tidende, Copenhagen.
968. Monthly Sanitary Record, Columbus, Ohio.
969. Kriegerheil. Organ der deutschen Vereine zur Pflege im Felde verwundeter und erkrankter Krieger, Berlin.
970. Journal da Sociedade pharmaceutica lusitana, Lisbon.
971. Il manicomio moderno. Giornale di psichiatria, Nocera Inferiore.
972. Gyógyszereszi hetilap, Budapest.
973. Fraternidad médico-farmacéutica, Alicante.
974. Il monitore terapeutico. Raccolta mensile di rimedi nuovi e ricette, Naples.
975. Bollettino della Società d'igiene della provincia di Reggio Calabria.
976. Index Medicus, Detroit.
977. El progreso medico, Havana.
978. Freies hygienisches Blatt, Vienna.
979. Gynækologiske og obstetriciske Meddelelser, Copenhagen.

980. Il Pisani. Gazzetta sicula di freni atria e scienze affini, Palermo.
981. Johns Hopkins University Circulars, Baltimore.
982. Monitore medico marchigiano. Bollettino dell' Associazione medica marchigiano, Loreto.
983. Cronaca del regio manicomio di Alessandria.
984. Bulletin de la Société d'anthropologie de Bruxelles.
985. Bollettino della Società italiana dei microscopisti, Acireale.
986. Czasopismo towarzystwa aptekarskiego, Lwow.
987. Geneeskundige Courant voor het Koningrijk der Nederlanden, Tiel.
988. Western Mental Journal, Kansas City, Mo.
989. Il Segno. Revista mensile di semeiologia e patologia speciale medica, Florence.
990. Medicinische Revue nebst Curorte-Zeitung, Karlsbad.
991. Russkii estestvoispytatelei i vrachei, St. Petersburg.
992. De praktizeerende Geneesheer, Hertogenbosch.
993. Bulletin de la Société de médecine d'Anvers.
994. Therapeutic Analyst, Norwich, Connecticut.
995. Archiv psichiatrii, neirologii i ssudebnoj psichopatologii, St. Petersburg.
996. Revue internationale de bibliographie, Beyrouth.
997. Gazzetta Medica di Torino.
998. Medical and Surgical Observer, Jackson, Tenn.
999. Zeitschrift für Orthopädische Chirurgie, Würzburg.
1000. Oesterr. Zeitschrift für Pharmacie.
1001. Blätter für klinische Hydrotherapie und verwandte Heilmethoden, Vienna.
1002. Giornale speciale di Farmacia Sperimentale e chimica clinica, Naples.
1003. Veterinary Journal, London.
1004. Archives d'obstétrique et de gynécologie, Paris.
1005. Deutsche Zeitschrift für Nervenheilkunde, Heidelberg.
1006. Journal of Comparative Neurology, Granville, Ohio.
1007 Ophthalmic Record, Nashville, Tenn.
1008. Monatshefte für Chemie.
1009. Giornale del Assoc. Napolitana di Med., etc.
1010. Climatoterapia, Barcelona.
1011. Fortschritte der Geburtshülfe und Gynækologie, Wiesbaden.
1012. Therapeutic Review, New York.
1013. International Clinics, Philadelphia.
1014. Boletin de sanidad militar, Buenos Ayres.
1015. Annales d'hypnologie et de psychiatrie, Paris.
1016. Anales del departamente nacionale de higiene, Buenos Ayres.
1017. American Dermatologist, Indianapolis.
1018. Annals of Ophthalmology and Otology, Kansas City.
1019. Bulletin of Pharmacy, Detroit.
1020. Gaceta Medica Quezalteca, Quezaltenango, Guatemala.
1021. Bibliographie der klinischen Helminthologie, Munich.
1022. Gl' Incurabili, Giornale di Clinica e di Terapia, Naples.
1023. L'Ingegnaria sanitaria, Torino.
1024. Boletin del hospital general de Puebla.
1025. Bulletin de médecine et de pharmacologie d'Athènes.
1026. International Centralblatt für die Phys. und Path. der Harn und Sexualorgane.
1027. Chicago Medical Journal.
1028. Dental Office and Laboratory, Philadelphia.
1029. Eurèka. Revue scientifique et industrielle, Paris.
1030. Medical and Surgical Record, Madison, Neb.
1031. New York Medical Examiner.
1032. National Popular Review, San Diego, Cal.
1033. The Prescription, Danbury, Conn.
1034. Revue chirurgicale, Paris.
1035. Revue de thérapeutique générale et thermale, Paris.
1036. Wochenschrift für Chemie und Pharmacie.
1037. Bulletins de la Société française d'hygiène, Paris.
1038. Le Languedoc Médical, Toulouse.
1039. Annali di nevrologia, Naples.

1040. Internationale Beiträge zur wissenschäftliche Medicin.
1041. Tidskrift f. Sundhedspleje.
1042. Annales de chirurgie, Paris.
1043. Archives provinciales de chirurgie.
1044. Revue du Dispensaire du Louvre, Paris.
1045 La Roumanie Médicale, Bucharest.
1046. Utchenyia Zapiski Kasanskaho Veterinärnaho Instituta.
1047. Pharmaceutische Centralblatt.
1048. Practitioners' Monthly, Syracuse, N. Y.
1049. Zeitschrift des allgemeinen œsterreichischen Apotheker-Vereines, Vienna.
1050. Revista de la Sociedad medica Argentina, Buenos Ayres.
1051. Revue de la Tuberculose, Paris.
1052. Chicago Medical Recorder.
1053. Bulletin of the Harvard Medical School Association, Boston.
1054. The General Practitioner, St. Louis.
1055. Indian Medical Reporter, Calcutta.
1056. Hygieia, Stuttgart.
1057. Journal d'hygiène populaire, Montreal.
1058. Food, New York.
1059. Chicago Lancet.
1060. Climates and Resorts, Chicago.
1061. Archives d'électricité mèdicale, Bordeaux.
1062. Revista de Higiene, Bogotá.
1063. Charlotte Medical Journal, Charlotte, N. C.
1064. The Corpuscle, Chicago.
1065. Florida Medical and Surgical Reporter.
1066. La Revista Médico-Quirúrgica, New York.
1067. The Alkaloid, Chicago.
1068. Tablettes mensuelles de la Société royale de médecine publique de Belgique, Bruxelles.
1069. The Medical Press, New York.
1070. Health and Home, Louisville, Ky.
1071. Revue Théorique et Pratique des Maladies de la Nutrition, Paris.
1072. Ontario Medical Journal, Toronto.
1073. Journal of State Medicine, London.
1074. Psychiatrische Jahrbucher.
1075. New York Polyclinic.
1076. American Journal of Surgery and Gynæcology, Kansas City.
1077. The Clinical Journal, London.
1078. Yüjno-Rüsskaia Meditzinskaia Gazeta, Odessa.
1079. Sanative Medicine, Westerville, O.
1080. Chicago Clinical Review.
1081. Revista médico-social, Madrid.
1082. Budapester Hygienischer Zeitung.
1083. Revue médicale de la Franche-Comté.
1084. Aerztliche Rundschau.
1085. Archivii ed atti della Sociéta Ital. di Chirurgia.
1086. Medicinsk Revue, Bergen.
1087. Shurnal russkago obschtschestwa ochranenija narodnago sdrawija, St. Petersburg.
1088. Le Midi Médical, Toulouse.
1089. Zeitschrift für Hypnotismus.
1090. Revue Neurologique, Paris.
1091. Leeward Islands Medical Journal.
1092. Indian Medico-Chirurgical Review, Bombay.
1093. Medical Magazine, London.
1094. Boletin del Consejo Superior de Salubridad de Guadalajara.
1095. La Puglia Medica, Bari.
1096. Revue générale de médecine, de chirurgie et d'obstétrique, Paris.
1097. Archivio internazionale delle specialita med. chirurgiche, Naples.
1098. Woman's Medical Journal, Toledo.
1099. Gross Medical College Bulletin, Denver.
1100. Magyar Orvosi Archivum, Budapest.
1101. Archives des Sciences biologiques, St. Petersburg.
1102. Gazzetta Medica di Pavia.
1103. Dental Practitioner, Buffalo.
1104. Le Trimestre Médical, Brüssels.
1105. Archivio italiano di otologia, rinologia, e laringologia, Turin.
1106. La Médecine Nouvelle, Paris.
1107. Annales für Hydrographie, Berlin.
1108. Abeja Medica, Havana.
1109. Anatomische Hefte, Giessen.
1110. Annales de le Policlinique de Lille.
1111. Bolétin del Manicomio de San Baudilio de Llobregat, Barcelona.
1112. Electricidad Médica, Barcelona.
1113. Gazzetta medica delle puglie, Bari, Italy.
1114. Gaceta Medica Municipal, Havana.
1115. Heraldo Medico-Farmaceutico, Madrid.

1116. Internationale Monatschrift zur Bekämpfung der Trinksitten, Bremerhaven.
1117. L'Univers Médical, Paris.
1118. La Higiene, Havana.
1119. Medicinische Novitäten, Leipzig.
1120. Odontoskop, Budapest.
1121. Prensa Medica de Malaga.
1122. Veshukdorpon (Mirror of Medicine, Bengali), Calcutta.
1123. Western Medical Record, Chicago.
1124. Wisconsin Medical and Surgical Journal, Waukesha, Wis.
1125. Zeitschrift für Nervenheilkunde, Erlangen.
1126. Revue internationale de Thérapeutique et de Pharmacologie, Paris.
1127. El Agricutor, Bogotá.
1128. Revue Médico-chirurgicale du Brésil.
1129. Annales de l'Institut de Pathologie et de Bactériologie, Bucharest.
1130. Ungarisches Archiv für Medicin, Budapest.
1131. Giornale dello istituto Nicolai, Milan.
1132. Annales médico-chirurgicales du Cercle médical borain, Paturages.
1133. McCaskey's Clinical Studies, Fort Wayne.
1134. Journal médical de l'Armée, Athens.
1135. St. George's Hospital Gazette, London.
1136. Northumberland and Durham Medical Journal, England.
1137. Rhode Island Medical Science Monthly, Providence.
1138. St. Joseph Medical Journal, St. Joseph, Mo.
1139. Journal de Chirurgie et de Thérapeutique infantile.
1140. Hospital Bulletin of the Second Minnesota Hospital.
1141. Balneologische Rundschau.
1142. La Pædiatria.
1143. Boletin de Medicina de Santiago.
1144. The Tri-State Medical Journal, Keokuk, Ia.
1145. Le Limousin Médical.
1146. Chugai Ijishimpo, Tokio.
1147. Archivis di pharmacologia e terapeutica.
1148. Gyógysz Kozl, Hungary.
1149. Annales de la Policlinique de Toulouse.
1150. Mathew's Medical Quarterly.
1151. Archiv für Laryngologie.
1152. Louisville Medical Monthly.
1153. La Presse Médicale, Paris.
1154. New York State Medical Reporter, Rochester.
1155. Revue Mensuelle de Stomatologie, Paris.
1156. Rivista di Patologia e Terapia delle Malattie della Gola, del Naso e dell' Orecchio, Florence.
1157. Dermatologische Zeitschrift, Berlin.
1158. Gazette hebdomadaire de la Russie Meridionale, Odessa.
1159. Teratologia, London.
1160 La Flandre Médicale, Ghent.
1161. The Refractionist, Boston.
1162. German-American Medical Journal, St. Louis.
1163. Louisville Medical Monthly, Louisville.
1164. The Railway Surgeon, Chicago.
1165. La Lancetta, Cienfuegos.
1166. Revista Estomatologica, Madrid.
1167. Archivio italiana di clinica medica.
1168. La Clinique, Montreal.
1169. Monatschrift für prakt. Wasserheilkunde, etc., Munich.
1170. Medicine, Detroit.
1171. New York Eye and Ear Infirmary Reports.
1172. The National Medical Review, Washington.
1173. Annali di Medicina Navale, Rome.
1174. The Colorado Climatologist, Denver.
1175. La Policlinique, Bruxelles.
1176. Vratchebnyia Zapisky.
1177. Cronica di clin. med. di Genova.
1178. Deutsche Monats. f. Zahnheil.
1179 Pacific Druggist and Physician, San Francisco.
1180. Journal Odontologique.
1181. La Médécine Infantile, Paris.

BOOKS, MONOGRAPHS, THESES, ETC.

2000. Proceedings of the Royal Society of Edinburgh.
2001. Transactions of the American Gynæcological Association.
2002. Transactions of the Royal Society of Edinburgh.
2003. Verhandlung d. zehnten Versamml. d. Gesellschaft für Kinderheilkunde in Nürnberg.
2004. H. Barth. Thérapeutique des maladies des organes respiratoires. 1894.
2005. Raynaud. Troubles oculaires de la Malaria. Paris, 1892.
2006. De Wecker, L. Réminiscences historiques concernant l'extraction de la cataract. 1893. Paris.
2007. Transactions of the Ophthalmological Society of the United Kingdom. Session 1892–93. London, 1893.
2008. Thorner. Pathological Conditions following Piercing of the Lobules of the Ear. 1894.
2009. Du Fougeray. Note sur quelques points de l'anatomie chir. de la caisse du Tympan. Paris.
2010. Contribuzione alla istologia patologica, etiologia e patogenesi del Condiloma Acuminato. Naples, 1893.
2011. Cîte. Va Cazuri de Sancre extragenitale, de Dr. G. Bogdan, Jassy.
2012. Un caz de gangrenà a ambelor testicule complicand blenoragia. Dr. G. Bogdan, Jassy.
2013. Transactions Texas Medical Association.
2014. Mount Bleyer and Weil. The Primary Action of the Galvanic Current.
2015. Baruch, S. Practical Data on the Application of Water in Some Intractable Diseases. 1893.
2016. Näcke. Verbrechen und Wahnsinn beim Weibe, mit Ausblicken auf die Criminalanthropologie überhaupt. Wien u. Leipzig, W. Braumüller. 1894.
2017. Velázquez-de-Castro. La Responsabilidad en las Histéricas. Granada, 1893.
2018. Journal Officiel. Rapport sur l'administration de la justice. Paris.
2019. Burney Yeo. Clinical Therapeutics. 1886.
2020. Pavy. The Physiology of the Carbohydrates. Churchill & Co., London, 1894.
2021. Sandwith. Egypt as a Winter Resort.
2022. Transactions Eleventh International Medical Congress.
2023. Verhandlungen der deutschen Gesellschaft für Chirurgie.
2024. Transactions Tennessee State Medical Society.
2025. Transactions American Neurological Association.
2026. Mueller. Handbuch der Neurasthenie.
2027. Gilbert. Baden-Baden und seine Thermen. Braumüller: Wien und Leipzig, 1893.
2028. Thèse de St. Petersbourg.
2029. Cornell University Bulletin.
2030. Thèse de Genève.
2031. Thèse de Paris.
2032. Transactions Massachusetts Medical Society.
2033. Melchior, Max. Clinical, Experimental, and Bacteriological Studies on Cystitis and Urinary Infection. Copenhagen, 1893.
2034. Kœlliker's Festschrift.
2035. New York Eye and Ear Infirmary Reports.
2036. Transactions of the American Philosophical Society, Philadelphia.
2037. Ber. ü. d. Versamml. d. ophth. Gesellsch. Stuttgart.
2038. Transactions of the College of Physicians. Philadelphia.
2039. Burr. A Primer of Psychology and Mental Disease. Detroit, 1894.
2040. Binswanger. Die pathologische Histologie der Grosshirnrinden-Erkrankung bei der allgemeinen progressiven Paralyse mit besonderer Berücksichtigung der acuten und frühformen. Jena, 1893.
2041. Magnan and Sérieux. La paralysie génerale. Paris.
2042. Piper. Zur Aetologie der Idiotie. Berlin, 1893.

2043 Transactions of the American Association to Promote the Teaching of Speech to the Deaf. 1894.
2044. Pinkerton, S. H. A Synopsis of Clinical Surgery during the Service of Holy Cross Hospital, Salt Lake City.
2045. Kellogg, J. H. Displacements of the Uterus.
2046. Annual Report of the Maryland Hospital for the Insane.
2047. Proceedings of the Royal Society.
2048. Transactions of the American Physiological Society.
2049. Brubaker. American System of Dentistry.
2050. Inaugural Dissertation. St. Petersburg, 1894.
2051. Sechster Gesammtbericht über das Sanitätsund Medicinalwesen in der Stadt Berlin.
2052. Bericht der Medicinalinspectorats.
2053. Bulletin annuel de statistique sanitaire comparée.
2054. Scientific American.
2055. Berliner Physiologische Gesellschaft.
2056. Jordan, Seth N. Contributions to Operative Surg. Columbus, Ga.
2057. Proceedings of the Medical Association of Alabama.
2058. Proceedings of the Southern Surgical and Gynæcological Association.
2059. Text-Book of the Theory and Practice of Medicine.
2060. Laboratory Reports of the Royal College of Physicians, Edinburgh.
2061. Dublin Quarterly Journal.
2062. Inaugural Dissertation. Berlin, 1894.
2063. Rosenblatt, T. On the Hereditary Taint in Tabes Dorsalis. Dissertation, Berlin, 1893.
2064. Hitzig. Festschrift zur 200 jährigen Jübelfeier in Halle, 1894.
2065. Dejerine. Sur le névro-tabes, etc. Paris, 1893.
2066. Ströbe. Tageblatt f. 66 Versamml. deutsche naturforscher.
2067. Arbeiten aus dem Institut für Anatomie und Physiologie des Centralnervensystems in Wien.
2068. Inaugural Dissertation, Königsberg, 1894.
2069. Inaugural Dissertation, Zurich, 1893.
2070. Rummo, G. Lezioni di Clinica Medica, Naples, 1894.
2071. Thèse de Lyon, 1894.
2072. Inaugural Dissertation, Leipzig, 1894.
2073. Inaugural Dissertation, Bonn.
2074. Sottas. Contribution to the Anatomical and Clinical Study of Spinal Syphilitic Paralysis. Paris, 1894.
2075. Freud. Zur Kenntniss der cerebralen Diplegia des Kinderalters. Vienna, 1893.
2076. Sjukhuset's Arsberättelse, 1893.
2077. Oppenheim. Lehrbuch der Nervenkrankheiten. Berlin, 1894.
2078. Louvovitch. Mémoires Médicaux. Moscow, i, ii, 1894.
2079. Inaugural Dissertation, Munich.
2080. Inaugural Dissertation, Würzberg.
2081. Chipault. Etudes de Chirurgie Médullaire. Paris.
2082. Inaugural Dissertation, Halle.
2083. Sternberg. Die Schnenreflexe. Wien, 1893.
2084. Raymond. Maladies du Système Nerveux. Paris, 1892.
2085. Medical and Surgical History of the War of the Rebellion.
2086. Proceedings of the Society for the Study of Inebriety. London.
2087. Ringer's Therapeutics.
2088. Kerr. Treatise on Inebriety. London.
2089. Byrom Bramwell. Remarks on Intra cranial Surgery.
2090. Morgan. A New Trajector.
2091. Hartmann. Note sur un Procédé d'Ablation des Retrécissements du Rectum par les Voies naturelles. Paris, 1893.
2092. Proceedings of the Omsk Medical Society.
2093. Transactions of the Academy of Science of St. Louis.
2094. Philadelphia Hosp. Reports, 1893.
2095. Greenlees. On Poisoning by Medicinal Doses of Bromide of Potassium. Cape Town.
2096. Warfvinge's Festschrift.
2097. Kobert. Intoxicationen.
2098. Compte-Rendu de la Société d' Hypnologie. Paris.

2099. Brunnberg. L'hypnotisme, jugé par des spécialistes. Upsala, 1893.
2100. Congrès de Lyon.
2101. Mannaberg, J. Die Malaria-parasiten auf Grundfremder und eigener Beobachtungen dargestellt. Wien, 1893. A. Hölder.
2102. Atti della Accad. dei Fisiocratici in Siena.
2103. Thèse Yourieff.
2104. Thesis. Berlin.
2105. Thèse de Fribourg.
2106. Thorner. Zur Behandlung der Lungentuberculose mittels Koch'scher Injectionen. Berlin: S. Karger. 1894.
2107 Leuckart. Parasites of Man. F. C. Winter, Leipzig.
2108. Veterinary Magazine.
2109. Veterinary Review.
2110. Nachricht v. d. Kais. Univ., Tomsk.
2111. Ruiz. Enfermidades endémicas que se observan en la Republica Mexicana. Mexico.
2112. Inaugural Dissertation. Greifswald.
2113. Revue Vétérinaire.
2114. Hager. Hand-book of Pharmaceutical and Medico-Chemical Practice. Russian Translation.
2115. Bulletin de la Société Zoologique de France.
2116. China Customs Gazette.
2117. Davidson. Hygiene and Diseases of Warm Climates.
2118. Insect Life.
2119. Proceedings of the Entomological Society of Washington.
2120. Entomologists' Monthly Magazine.
2121. Taylor, Thomas. Twelve Edible Mushrooms of the United States, with Directions for their Identification and Preparation as Food.
2122. Orvañanos. Medical Geography of Mexico.
2123. Denmark: its Medical Organization, Hygiene, and Demography.
2124. Mills. Disorders of Pantomime Occurring among Aphasics, with Particular Reference to their Medico-Legal Bearing.
2125. Erik Müller. Zur Kentniss der Labdrüsen der Magenschleimhaut. Stockholm.
2126. Bayer. Grundriss der chirurgischen Operationstechnik.
2127. Retzius. Biologische Untersuchungen. Stockholm.
2128. Edinger, L. Verhandlung d. Anatomische Gesellschaft.
2129. Kölliker. Sitzungsbericht d. Würsb. Phys. Med. Gesellschaft.
2130. Henson, S E. Om Synbanans anatomi ur diagnostic synpunkt.
2131. Rabl, H. Sitz. Ber. d. k. Akad. d. Wiss. in Wien.
2132. Tageblatt der 54 Naturforvcherversammlung, Salzburg.
2133. Nägeli. Theorie der Gährung.
2134. Jahresbericht über die Fortschritte auf dem Gebiete der Geburtshilfe und Gynækologie.
2135. Publicazione della direzione di Sanita. Rome.
2136. Sternberg. Manual of Bacteriology.
2137. Korotneff. Sporozoen als Krankheitserreger. Berlin.
2138. Arbeitung aus der Kaiserliche Gesundheitsamte.
2139. Transactions of the Association of American Physicians.
2140. Proceedings of the Arkhangelsk Medical Society.
2141. Thèse de Königsberg.
2142. Inaugural Dissertation. Moscow.
2143. Priestley. Experiments and Observations on Different Kinds of Air.
2144. McManus. Notes on the History of Anæsthesia.
2145. Boas. History of Medicine. Translated by H. E. Henderson. Vail & Co., New York.
2146. Journal of Science and the Arts.
2147. Hon. Truman Smith. An Inquiry into the Origin of Modern Anæsthesia.
2148. Snow. Chloroform. London, 1858.
2149. Buxton. Anæsthetics. London, 1892. Second Edition.
2150. Hewitt. Anæsthetics and their Administration.
2151. George Oliver. Pulse-Gauging. London: Lewis, 1895.
2152. Parker. Post-Nasal Growths. London: Lewis, 1894.
2153. Proceedings of the Royal Medico-Chirurgical Society, London.

2154. Holmes's System of Surgery.
2155. Illustrated Medical News.
2156. Transactions of the Pirogovian Surgical Society, St. Petersburg.
2157. Sabouraud, R. Les Tricophyties humaines. Avec Atlas. Edition Rueff. 1894.
2158. Korotneff. Untersuchungen über den Parasitismds des Carcinoms.
2159. Haviland. Geograph. Distribution of Dis. in Gt. Britain. Lond., 1892.
2160. Critzmann. Le Cancer. Collection Léauté. Paris : Masson.
2161. Réthi. La rhinite polipoïde. Leipzig and Vienna, 1894.
2162. Martinez. Rinitis atrofica. Habana, 1894.
2163. Zuckerkandl. Norm. u. path. Anat. d. Nasenhöhle.
2164. Thèse de Bordeaux.
2165. Manhattan Eye and Ear Hospital Reports.
2166. Dissertation Inaugurale. Saverne.
2167. Inaugural Dissertation. Breslau.
2168. Inaugural Dissertation. Marburg.
2169. Molinié, J. Asthma des Foins et le Coryza Spasmodique.
2170. Verhandlungen der Berliner Laryngol. Gesellschaft. 1894, Bd. 4.
2171. Jahrbuch des Hamburgischer Stadtskrankenhaus.
2172. Bresgen. Diagnostisches Lexicon für praktische Aerzte.
2173. Transactions of the London Pathological Society.
2174. Thèse inaugurale. Kiel.
2175. Transactions of the American Laryngological Association.

3 vol.
121+